may attain a fairly great size. It is evident that this different quality, regarding a greater energy of growth, is connected with the embryonic cells.

The sacrococcygeal region is the most frequent site of dermoid cysts, owing to its complicated embryology. The theories of their genesis are numerous, being described in detail by CEDERBAUM, HUBLY and THOMASON. Their origin is generally ascribed to the complicated evolutional and involutional processes at the caudal extremity on the earliest embryonal stages. According to BARDEN and CORNING the ectoderm of the medullary plate is changed direct into the entoderm at the canalis neurentericus. This change occurs immediately after the formation of the amnion cavity at the beginning of the pinching off of the medullary plate from the navel vesica. Accordingly, this canal connects the amnion cavity direct with the caudal gut, or the primitive gut. Later, at the development of the primitive streak from the cloacal membrane, it forms a direct communication between the medullary tube and the cloaca, whose caudal sinuation, the caudal gut, later is transformed into rectum. By the fourth fetal month, during the involution of the protruding genetic caudal formation, which contains the distal portion of the spinal cord, the canalis neurentericus, the caudal gut, and the caudal bud, with its undifferentiated masses of cells, a wrong storing of tissual elements frequently occur, which, later, gives rise to fistulae and cysts in the regio sacrococcygea.

The sacrococcygeal region is the most frequent site of dermoid cysts. While they are closed in other parts of the body, they often communicate, in this region, with the outer world through small fistulae. When the buttocks are separated, many orifices of the size of the head of a pin, may be seen, which often end blindly, but which, occasionally, communicate with the cyst. Some of the fistulae are congenital tubes lined with epithelium, others may arise after an inflammation and a perforation of the cyst wall. A cyst which has never been infected, affords no symptoms and the patient is unconscious of its presence. An inflammation always arises from impurities from the anal region. The fistulae close owing to inflammation of the tissue and epithelial plugs, and the cyst is transformed into an abscess, rising close to the side of the midline, perforates and discharges, passes into a latent stage, but, sooner or later, it will again become an abscess. In the pus scenting like the contents of a dermoid cyst, or stinking with coli, lanugo-

Vol. XCIII (93).

ACTA CHIRURGICA SCANDINAVICA

*

SUB TITULO

NORDISKT MEDICINSKT ARKIV

CONDIDIT MDCCCLXIX AXEL KEY

*

REDACTORES:

R. FALTIN
Helsingfors

AAGE NIELSEN
Aarhus

J. HOLST
Oslo

EINAR KEY
Stockholm

S. KJÆRGAARD
København

F. LANGENSKIÖLD
Helsingfors

G. PETRÉN
Lund

CARL SEMB
Oslo

G. THORODDSEN
Reykjavik

REDIGENDA CURAVIT

EINAR KEY
Stockholm

ACCEDENTE

J. HELLSTRÖM
Stockholm

COLLABORANT:

IN DANIA: O. Chievitz, Fabricius-Möller, J. Foged, J. Ipsen, E. Dahl-Iversen, L. Kraft, A. Lendorf, H. Retlev-Abrahamssen, C. Wessel.

IN FENNIA: M. Hämäläinen, T. Kalima, A. R. Klossner, L. Lindström, P. E. A. Nylander, A. J. Palmén, V. Seiro, A. Snellman.

IN NORVEGIA: N. Backer-Grøndahl, A. Berg, A. Brekke, P. Bull, H. F. H. Harbitz, R. Ingebrigtsen, E. Platou, A. Sunde.

IN SUECIA: F. Bauer, G. Bohmansson, C. Crafoord, K. H. Giertz, O. Hultén, S. Johansson, N. Liedberg, E. Ljunggren, G. Nyström, H. Olivecrona, I. Palmer, E. Perman, S. Rödén, O. Schuberth, J. P. Strömbeck, G. Söderlund, A. Troell, H. Waldenström, J. Waldenström, A. Westerborn, H. Wulff, J. Åkerman.

STOCKHOLM 1946. P. A. NORSTEDT & SÖNER

risk of overlooking a prolapse in development, and if, on the other hand, an incision is made in the annulus, we have considered in our clinic that later on there is an increased risk of a prolapse on the spot of the incision. It will, however, seem as if this risk is not very great.

No case with mortal issue has occurred in the whole material, consisting of 550 cases. In the postoperative material reported in this paper there has been performed no operation for relapse or prolapse in another disc. On the other hand, two explorations have later on been reexplorated. No fusion has been performed on any of the 44 patients, whether in connection with the operation or later. It is, however, a question open to discussion whether a fusion should not have been indicated in the cases showing remaining low back pains. A report published some years ago by the Mayo clinic on the experience from disc prolapses in the lumbar region showed that a combination of operation — exstirpation-fusion is being used in a greater and greater extent, and preferably in cases of disc degeneration. During the last few years it had been used in 14 % of the prolapse cases. The question of whether fusion is to be applied or not in prolapses is a subject of frequent discussion. We have, in a consistent way, avoided using fusion in connection with exstirpation, and for the following reasons: The patient wanting above all to get rid of the severe sciatic pains, we have considered the fusion as an unnecessarily great operation with regard to the considerably longer postoperative treatment, and we have reserved the stabilizing operation for those patients operated for prolapse which have complained of low back pains causing invalidity. In the material reported in this paper, many patients state that during the first year resp. the first three years after the operation they suffered from certain insufficiency pains in the low back, but that these pains ceased later on. The ceasing of the pains is, in our opinion, partly the result of a cicatrization round the disc, partly the unintentional result of the laminectomy and the damage on the soft tissues. The tissue produced by the postoperative cicatrization acts to some degree as a fusion and decreases the tendency towards instability and abnormal mobility of the disc. In this connection the fact ought to be stressed that the authors, basing themselves on such a scant material, have not been able to observe any difference in the functional results of laminectomy performed on one resp. two vertebras.

STOCKHOLM 1946
KUNGL. BOKTRYCKERIET. P. A. NORSTEDT & SÖNER
454787

"hour-glass vertebra" cannot be expected to appear. Trauma may be excluded, infectious processes as well. No destructing processes are at hand. It may not be thought that an atrophy of the bone-substance of an earlier normally developed vertebra could lead to this deformity, besides, no roentgenological signs of a bone-atrophy could be detected. In a case of neurofibromatosis it is rather tempting to suppose that the deformation of the back is due to a neurotic bone-atrophy, but the hypothesis is in this case not supported by facts. I accept the explanation that this strange vertebral deformity may have originated as a disturbance in the growth of probably originally normal vertebrae.

This disturbance in the growth may be considered to be on the same plane as earlier related disturbances in neurofibromatosis in the development of flat as well as of long bones in cranium, face, pelvis and extremities. That the disturbance in the growth is due to the neurofibromatosis seems certain, it may be the question of a tropho-neurotic disturbance. According to M. B. SCHMIDT (1937) already VIRCHOW described an arrest of the development of the extremities in congenital or acquired diseases of the nervous system. Even if no measurable disturbance of the motory or sensory nerve functions usually arises in multiple neurofibromatosis, the thought that tropho-neurotic disturbances were the sequel of this system disease may certainly not be dismissed. We have de facto no possibility to explain in any other way the disturbances in the growth of the skeletal system in neurofibromatosis.

Summary.

After a general review of what is known about the multiple neurofibromatosis and the skeletal changes connected with this disease, 105 cases of deformities of the spine in neurofibromatosis collected from the literature are analysed in detail. — The author describes a case of multiple neurofibromatosis with grave dorso-lumbar kyphoscoliosis in which a strange hour-glass shaped deformity of the three first lumbar vertebrae was roentgenologically ascertained. The explanation of this unique deformity of the vertebral bodies is supposed to be a trophoneurotic growth disturbance. This explanation is probably valid for the growth disturbances observed in other flat and long bones in neurofibromatosis.

From the Orthopedic Hospital, Copenhagen.
(Chief Surgeon: POUL GUILDAL).

On the Treatment of Dupuytren's Contracture.

By
FRIDRIK EINARSSON.
Copenhagen.

D upuytren's contracture was described by Sir ASTLEY COOPER in 1822 and by DUPUYTREN in 1832.

Etiology and Pathogenesis.

The cause of the disease has not yet been fully elucidated, but a number of different factors seem to be responsible. In numerous cases heredity no doubt plays a part. Extremely varying figures (6—72 per cent.) have, however, been stated by the various authors reporting its frequency as a causative factor. KEEN found a family history in 50 out of 198 cases. BUNCH observed the lesion in father, son, and grandson of one family, the male members of which were said to have been affected with Dupuytren's contracture for a period of 300 years. Several reports have been published of the disease encountered in identical twins.

Various authors attach much importance to manual work as well as trauma, a single injury or repeated minor traumata. JANSSEN takes the view of a fibroplastic diathesis and LOEWY considers "an hereditary tendency to fibrous hyperplasia" to be the essential factor.

The importance of focal infection has been emphasized, especially by American authors.

KROGIUS has advanced an extremely interesting theory, viz. that the contracture arises in consequence of a disturbance in the development of the superficial muscles of the hand (musculi flexores breves manus superficiales) no more present in man or the ape, but demonstrable in the human embryo.

levant le 2e mc., selon PERTHES, méthode opératoire qui, à mon avis, a paru être la plus appropriée dans les cas en cause. En effet, dans les cas en question l'index ou une partie du 2e mc. ont manqué, de façon que l'enlèvement du 2e mc. pour ainsi dire s'offrait à mon procédé de traitement. Dans tous les deux cas l'opération a résulté en un pouce fort, très mobile et sensible, le moignon de la main assez maladroite se modifiant en un organe de préhension et de tâtement propre à servir.

II. Les opérations plastiques éloignées.

5. *E. H.* Un employé de bureau de 31 ans. J. N:o 789. Opérateur: LANGENSKIÖLD. — Le 17. 2. 40 il a gelé les deux mains dans la guerre. De la main gauche le pouce seulement est resté intact, des autres doigts est restée une partie des premières phalanges. De la main droite il manque les doigts et des os du mc. il ne reste que des petits moignons, dont le 1er mc. était le plus long. Une petite partie de la première phalange est restée du pouce. Le 14. 6. 40 *Phasis I. Applicatio stil. rotund. cutano-ossealis ut fiat pollex ad modum Nicoladoni I.* De l'éther. Deux incisions parallèles d'une longueur de 15 cm. env. au-dessus et en-dessous de la crête iliaque. La peau et le tissu dermien sont détachés jusqu'au bord de la crête iliaque. Un morceau long de 6 cm. env. est ciselé de cette crête, lié au pont de la partie molle. Celui-ci est suturé bord à bord en forme d'une saucisse. Le 23. 8. 40 le transplant osseux s'est nécrosé. On l'enlève. Le 14. 10. 40 *transplantatio oss. libera ad stil. rotund.* De l'éther. Un morceau d'os avec périoste est pris du tibia et introduit dans la saucisse. Le 25. 11. 40. *Phase II.* De l'éther. Le bout latéral de la saucisse est détaché et on constate un épanchment de sang émanant de la surface du transplant osseux. Par conséquent il vit. On découvre le capitulum du 1er mc., où l'on enfonce le bout du transplant osseux. La peau de la saucisse est soigneusement suturée dans la peau du 1er mc. — Le 12. 12. 40. *Phase II.* De la novoc. On détache la moitié du bout médial de la saucisse et la ferme bien. — Le 23. 12. 40. *Phase IV.* De la novoc. On détache finalement la saucisse de l'abdomen et plâtre la main.

Le 18. 7. 45, *examen ultérieur.* Le pouce est devenu ferme à la fin de l'année 1941. Le malade travaille comme contrôleur de taxation. Il se débrouille bien tout seul, même si les doigts manquent des deux mains. La main gauche est meilleur et la main droite fonctionne comme son aide. — Un pouce long de 4.5 cm. cosmétiquement bon, qui sent un contact fort, la partie volaire sent aussi un point d'aiguille, ayant aussi une sensation thermique faible. Les mouvements sont bons, la force est assez grande.

6. *E. L.* Agriculteur de 28 ans. J. N:o 434. Opérateur: LANGENSKIÖLD. — Le 30. 8. 41 il se fut blessé à la main droite par un projectile explosif. Au milieu du troisième métacarpien il y a une dé-

Dupuytren's contracture is about 7 times as common among men as among women (Table I).

Table I.

Sex.

Author	Cases	Males	Females
KEEN[1]	227	187	40
ANDERSON[1]	39	25	14
BLACK[1]	240	221	19
BYFORD[1]	38	35	3
KANAVEL, KOCH, MASON	29	27	2
MEYERDING	273	241	32
Writer's Material	111	101	10
	957	837	120

The frequency increases with advancing age. 25 out of 90 cases reported by KEEN had acquired the deformity before the age of 30, but severe cases seldom are observed before the age of 40. In MEYERDING's material the mean age was 54.

Some authors emphasize the common occurrence of Dupuytren's contracture in labourers engaged in hard manual work. Among 1,021 brewery workers in Copenhagen BONNEVIE *and co-workers* observed the disease in 20.9 per cent. It was found to be twice as common among the workmen who had been handling cases containing filled bottles for a long period as among their colleagues. NIEDERLAND observed the deformity in 17.8 per cent. of textile workers, more than 40 years of age, engaged in especially hard manual work, whereas an examination of 112 clerks above the same age only revealed 0.9 per cent. to be affected with the disease.

Hospital statistics do not, on the other hand, indicate the significance of hard work suggested by the investigations mentioned above (Table II).

LUND found Dupuytren's contracture to be 2—3 times more common among epileptics than among a control material consisting of old and elderly labourers in Copenhagen. NOBLE SMITH found a percentage of 18.3 among the men of the London Workhouses.

According to the literature Dupuytren's contracture occurs with

[1] Quoted from KANAVEL, KOCH & MASON.

tissue, under the undamaged skin, was extensive. On admission the patient's temperature was high and he complained of severe pains in his thigh which was extremely swollen. The circulation in the limb was intact. Palpation revealed gas crepitus; from the splinter wound gas and blackish-red tissue fluid emerged. A bacterial specimen was taken from the tissue liquid through undamaged skin by way of a special incision. The specimen contained grampositive cocci and grampositive granulated rods. In the cultivation [illegible] and clostridium anaerobically. The species was [illegible]gnose. In guinea-pigs it was pathogenic anyhow. Gas was seen to press between the muscular fibres, in the X-ray picture. The treatment of the patient comprised sulphonamide drugs, gas oedema serum and incisions. Gas formations did not progress after the treatment. The patient recovered. In the wound cavity a suppurative mixed infection appeared gradually and clostridium disappeared.

Case 3. E. S., 27 years, private. Wounded by numerous small shell splinters in back and right gluteal region. First treated 20.8—21.8 44 at FH A/24. 3000 units of tetanus antitoxin was administered. Transferred to WH 13 on 21.8.44. General condition good. Temperature 36.8. About 24 hours after being wounded severe strain in the whole of the right gluteal region at entries of splinters. Brownish-violet circle of discoloration of the skin around the splinter wounds. The whole region exceedingly tender. When pressed a gas crepitus was felt and blackish-red foamy tissue fluid oozed out of the wound. The X-ray picture showed gas pressed between the fibres of the gluteal muscles. In the bacteria sample, taken through the undamaged skin there were grampositive cocci and grampositive granulated rods in the tissue fluid. In the cultivations there grew staphylococci and anaerobically clostridium which was pathogenic in guinea-pig. The diagnosis of species was cl. welchii. The patient was treated with sulphonamide drugs, gas oedema serum, by incisions and by oxidizing rinses. In the beginning the patient had a low body temperature and not until the infection had become pyogenic and the clostridium had disappeared did the temperature rise. The patient recovered. In connection with the incision I took histological samples from the gas-containing tissues. The preparations were tested by the military pathologist Professor O. JÄRVI, who also tested all other histological preparations mentioned in my report.[1] The histological picture corresponded to what we consider essential in gas oedema. The pathologic-anatomical diagnosis was gangraena aerogenes. The muscular tissue was scattered and completely necrotic and the inflamed cells were very scarce. The connective tissue and the fatty tissue was not necrotic; they contained numerous split nucleated leucocyte agglomerations. No bacteria were visible in the histologic preparations.

Case 4. T. K. 24 years, private. Wounded 5.8.44 by small shell splinters in the bend of the left knee and slightly on the inside of the

[1] My thanks are due to Professor JÄRVI for his kind assistance.

striking frequency in association with certain other diseases, viz. plantar fibroma, periarthritis of the humerus, plastic induration of the penis, helodermia. The causal relationship is unknown.

Table II.

Occupation.

Author	Cases	Manual Work	Immaterial Work
KEEN[1]	123	49	74
BLACK[1]	131	63	68
BYFORD[1]	38	24	14
KANAVEL, KOCH, MASON	29	10	19
MEYERDING	273	123	150
Writer's Material	111	57	54
	705	326	379

Pathological Anatomy.

The disease starts in the palmar aponeurosis, especially in the superficial, longitudinal layers. Most authors agree that inflammatory changes and ordinary scar tissue may be ruled out. The initial stage is characterized by increased vascularization (JANSSEN) and a proliferation of connective tissue with a round cell infiltration almost reminding of sarcomatous changes. A tendon-like connective tissue containing few cells is a peculiarity of the more advanced stage. The aponeurosis is subject to a shrinkage and shortening causing the contracture. The subcutaneous fat is reduced or entirely lost. As the disease spreads to the deeper layers of the aponeurosis and its extensions, the digital arteries and nerves become embedded in the fibrous tissue. In severe cases they may become displaced as much as a fingerbreadth (MASON), a fact which should be kept in mind during an operation, if any.

The flexor tendons are never involved in the pathological process.

Symptoms.

In mild cases the disease manifests itself in the form of firm nodules, approximately the size of a pea, below the palmar skin, as a rule localized to the base of the ring or little finger, less frequently

[1] Quoted from KANAVEL, KOCH & MASON.

men clinique avait démontré la présence de gaz. Dans tous ces cas, on révéla la présence d'un clostridium de caractère pathogène. Le matériel fut prélevé à travers la peau saine dans du tissu musculaire contenant du gaz. Dans trois cas il s'agissait d'infection monomicrobienne.

Les cas suivants sont des exemples de trois types différents d'infection.

1. Empyème à clostridium; il se produisit dans ce cas un pneumothorax consécutif à la pression gazeuse. Le malade se rétablit après opération. Ce fut le seul cas d'empyème à clostridium dans un grand hôpital d'évacuation parmi de nombreux cas d'empyème à anaérobies. Il s'agissait dans le cas de clostridium septique.

2. 2 cas de phlegmons gazeux provoqués par des clostridium pathogènes (clostridium Welchii et une autre famille dont manque le diagnostic exact) dans des cas de dilacération musculaire. On réussit à limiter le phlegmon et le malade se rétablit. Traitement: incision, sérum contre gangrène gazeuse et sulfonamides.

3. 2 cas de phlegmons gazeux étendus dans les extrémités inférieures avec ischémie traumatique. Bacille: clostridium Welchii. L'un d'eux était un cas remarquable d'embolie par fragment de grenade dans l'artère tibiale postérieure. Le blessé survécut deux jours à sa blessure. Pendant ce temps on n'observa aucune inflammation grave dans le canal d'une blessure allant de l'aisselle gauche à travers le poumon jusqu'à l'oreillette gauche. Par contre il se développa un phlegmon gazeux très grave dans le tissu musculaire ischémique de l'extrémité inférieure gauche. Le blessé ne mourut pas de sa lésion cardiaque mais de son phlegmon gazeux.

Sur l'Isthme carélien, les phlegmons gazeux furent rares, sauf dans les cas d'ischémie traumatique qu'il faut par conséquent considérer comme le facteur pathogène le plus important. Cette pathogénie doit être prise en considération lors de l'usage de plâtres et dans les cas où l'on utilise des pansements compressifs. On peut provoquer l'apparition de phlegmons gazeux même dans les cas où la virulence du clostridium est faible, ainsi que c'était le cas sur l'Isthme carélien. Une question qui vaut la peine d'être examinée: l'administration systématique de sérum anti-tétanique joue-t-elle un rôle dans la faible virulence de la bactérie?

Il existe des formes bénignes de phlegmon gazeux où l'on trouve cependant de l'histolyse du tissu musculaire et l'un ou

the middle finger. A situation at the base of the index finger or the thumb is rare in the initial stage. At this stage the patient is not embarrassed by the deformity, there is no pain or tenderness, and the mobility is still free. The disease progresses, however, though generally slowly. The skin becomes involved early, the nodules gradually merge, forming hard cords projecting above the level of the skin and extending from the palm on to the finger in question. At the same time the disease spreads to other parts of the aponeurosis and often, though not always, to other fingers. A flexion contracture results, first preventing an active extension of the finger, later even a passive extension. As the aponeurosis shrinks and shortens, the finger is flexed more and more, ending in pronounced cases in a maximum flexion with the finger-tip in contact with the palm. In a few cases the patient experiences pain and tenderness, because the normal protective tissue of the palm — skin, aponeurosis, and subcutaneous fat — has degenerated into fibrous tissue. As a rule, however, the inconvenience is due to the fact that the patient is unable to extend the finger which is in the way of the movements.

The deformity generally is bilateral, but sometimes is localized to one hand only, as a rule the right one (Table III).

Table III.

Hand Affected.

Author	Cases	Bilateral	Right hand	Left hand
Keen[1]	184	103	58	23
Anderson[1]	39	24	10	5
Hume[1]	118	40	57	21
Black[1]	240	104	89	47
Byford[1]	38	25	9	4
Kanavel, Koch, Mason	29	17	4	8
Meyerding	273	175	69	29
Writer's Material	111	53	35	23
	1032	541	331	160

Similar changes are sometimes encountered in the plantar aponeurosis. It is a peculiar feature that the lesion has been localized to the *tibial part* of the aponeurosis in all the published cases (Klossner).

[1] Quoted from Kanavel, Koch & Mason.

d'élastoplaste, selon les figures publiées ici. La durée du traitement est de 5—6 semaines dans les cas ordinaires, s'il a été mis en oeuvre à temps. Ses resultats sont bons.

Bibliography.

Böhm: Der kongenitale Plattfuss. Zbl. Chir. 1932. 2987. — Hohmann: Fuss und Bein. München. 1934. — Küstner: Über die Häufigkeit des angeborenen Plattfusses mit Bemerkungen über die Gestalt des Fusses des Neugeborenen überhaupt. Arch. clin. Chir. 25. — Lake: The Foot. London. 1935. — Mercer: Orthopaedic Surgery. London. 1937. — Spitzy: Der Pes planus. Z. ortop. Chir. 12. — Spitzy: Bau und Entwicklung des kindlichen Fusses. Jb. Kinderheilk. 57. — Wallgren, G.: En praktisk metod för den kongenitala plattfotens behandling. Finl. Läkarförb. Tidskr. 6. 1939.

Treatment.

DUPUYTREN himself realized that the contractures did not yield to *extension treatment*. If instituted at an early stage energetic *massage* and *redressing exercises* may counteract, or at least postpone the contracture (JONES & LOVETT). Emollient *ointments*, *medical diathermy* and other forms of *thermotherapy*, *iontophoresis*, *radium* and *roentgen therapy* have been tried without definite results. A. A. DAVIS, KLAPP and a few others consider *fibrolysin injections* to be of a certain effect, alone or better in connexion with operation.

For the sake of completeness it should be mentioned that STAHNKE obtained good results treating 12 cases with injections of molten human fat (from lipomata etc.). Although the thickening remains unchanged, the function improves. The treatment may be tried in inoperable cases and in very old patients (LEXER).

The *operative treatment* follows three principles: *excision of the palmar aponeurosis*, *division of the palmar aponeurosis*, and *digital amputation*.

Dupuytren's operation consisted of transverse incisions, $2^1/_2$ cm. in length, through the skin and fascia in numbers necessary to straighten the finger. He left the wounds to granulate and splinted the hand with stretched fingers.

Subcutaneous division of the palmar aponeurosis or *Adams' operation* (suggested by Sir ASTLEY COOPER as early as 1822). 10—15 incisions may be required in order to straighten the fingers completely. The operation is not an easy one, it being difficult, without the aid of the eyes, to avoid injuring vessels and nerves, a factor of immense importance, if a satisfactory result is to be obtained.

A thorough excision of the palmar aponeurosis followed by adequate post-operative measures is, however, the best and most radical method of treatment. The earlier the operation is done, the better are the results. According to KANAVEL, MOURE and others a recurrence is best avoided by removing not only the contracting cords, but as large a portion of the aponeurosis as possible. It is especially important that all the fascial slips to the interosseous membrane, metacarpal bones, and phalanges have been removed. Most authors also recommend the removal of skin areas exhibiting pathological changes which should be replaced

Krankenhaus aufgenommen worden war. Pat. kam kurze Zeit danach an einer zerebralen Affektion ad exitum. Die Obduktion ergab ein apfelsinengrosses Hypernephrom. Der SR-Wert war 18 mm. Die andere Kranke war eine 73jährige Frau, welche wegen eines hühnereigrossen Hypernephroms operiert wurde. Die SR war vor der Operation 97 mm. Einen Monat nach derselben war die SR auf 28 mm gesunken. Möglicherweise hätte man noch niedrigere Werte verzeichnen können. Diese Kranke ging ein Jahr später an Lungenmetastasen zugrunde.

Schliesslich habe ich das Material mit Rücksicht auf das Einwachsen des Tumors in die Vena renalis durchgesehen. Bei 12 der Fälle liegen diesbezügliche Angaben vor. Ein bestimmter Typus der SR ist bei diesen Fällen nicht zu konstatieren: die Werte schwankten zwischen 3 und 100 mm.

Die Untersuchungsergebnisse lassen sich in folgende Punkte zusammenfassen:

1. Fast $^1/_3$ der Fälle, 31,2 %, hatten eine niedrige SR, unter 20 mm. Fälle mit normaler SR sind häufiger (20 Fälle) als solche mit extrem hoher SR, über 100 mm (17 Fälle).
2. Die SR ist nicht proportional der Tumorgrösse. Nicht selten findet man eine niedrige SR bei sehr grossen Tumoren. Kleine Geschwülste können mit einer hohen SR einhergehen.
3. Alte Tumoren werden oft von einer ziemlich niedrigen SR begleitet.
4. Fälle mit Fieber (ohne Infektion der Harnwege) haben in der Regel eine wesentlich erhöhte SR. Der Wert kann bei den Fieberfällen im Laufe der Entwicklung stark schwanken.
5. Bei Metastasen ist die SR gewöhnlich beträchtlich erhöht, es kann aber eine niedrige SR vorkommen.

Zusammenfassung.

Das Vorkommen extrem hoher SR-Werte beim Hypernephrom dürfte allgemein bekannt sein. Nicht so bekannt scheint der Umstand zu sein, dass eine niedrige oder sogar normale SR vorkommen kann. Verf. hält die Kenntnis dessen für bedeutungsvoll und berichtet über die SR bei 109 Fällen von operierten, pathologisch-anatomisch verifizierten Hypernephromen. Die Untersuchungsergebnisse lassen sich in folgende Punkte zusammenfassen:

by skin grafts of full thickness. LEXER removes the skin in all cases (shaded area in drawing), whereas a few authors systematically preserve it (GILL, DESPLAS).

Various cutaneous incisions have been employed. Some authors consider the form of incision to be of great importance, whereas others regard it as subordinate to a thorough removal of the aponeurosis.

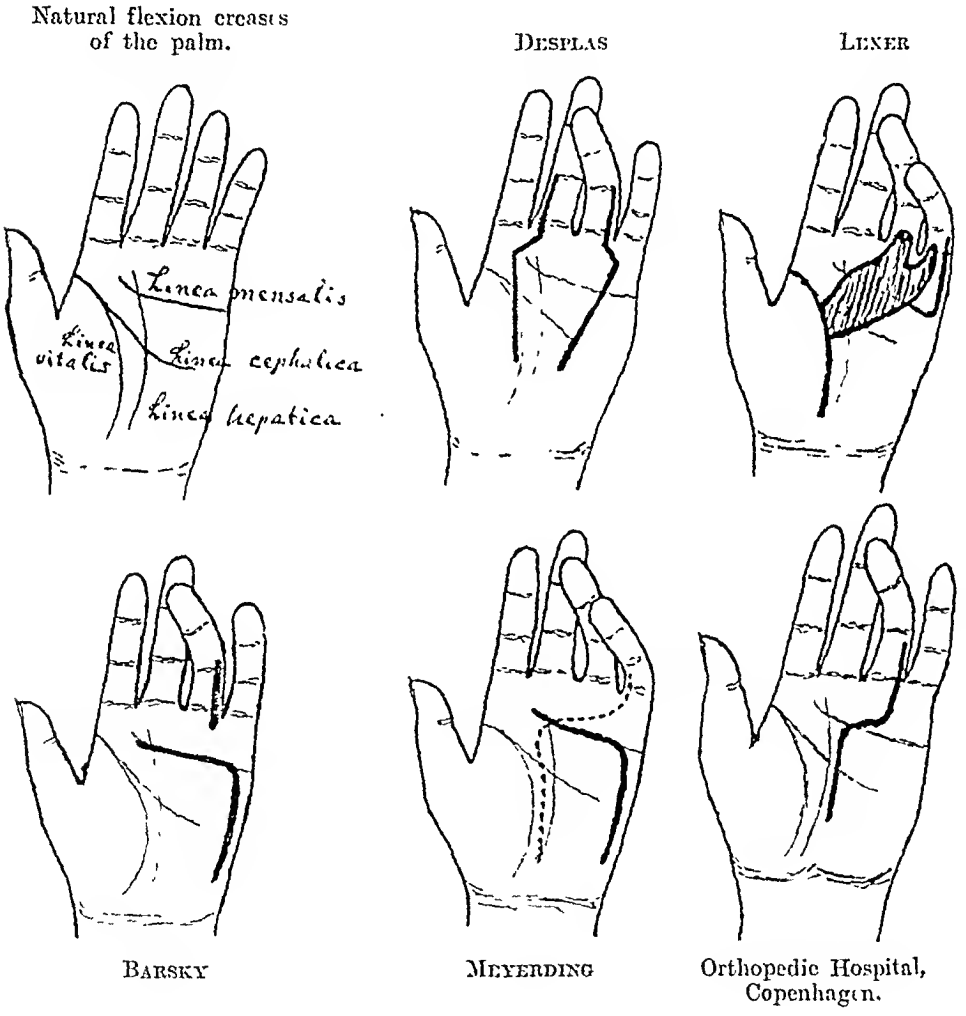

Fig. 1. Various forms of incision.

KANAVEL employs longitudinal as well as transverse incisions, according as the nodules extend in a longitudinal or transverse direction.

KOCH also adapts the cutaneous incision to the individual case,

According to HAUGSETH, OEHME described the first case in 1907. In 1934, SKARBY reviewed 70 cases of rupture of hydronephrotic cysts from the literature.

As I personally have had an opportunity to study two cases of rupture in diseased kidneys — in the one instance bursting of a malignant kidney tumour of Grawitz's type, in the other a rupture of a large hydronephrotic cyst —, and as I have been unable to find any mention of similar cases in the Scandinavian literature other than the papers by HAUGSETH and SKARBY, a report on these two cases seems to be justified. The cases furthermore present features of interest from several points of view.

Case Reports.

Case 1. (994/1937.) T. K., aged 51. The wife of a train conductor in Kuopio. The patient was treated at the Kuopio County Hospital from March 6th to March 27th, 1937, on a diagnosis of *ruptured hypernephroma of the left kidney.* In the autumn of 1936 she had had symptoms of high blood pressure. She had consulted a doctor about a year before for "kidney trouble". The nature of her disease is not stated in this physician's records. In other respects, she had been healthy. On March 6th, 1937, she fell down in the street, knocking the left side of her body against the edge of the pavement. Immediately after the accident she experienced pains in the region of the left kidney. As her symptoms became gradually worse she came to the hospital.

She was found at the physical examination to be in good general health. Her temperature was 36.2°C. in the axilla and 37.1°C. in the rectum. Her pulse was even and fairly full, with 72 beats per minute. She was noticeably pale. No abnormal signs were obtained from the heart or lungs. There was considerable abdominal tenderness on the left side, under the infra-costal angle. In this area one could palpate an indistinct tumour. The urine contained albumin but no sugar; no microscopical haematuria. The patient was admitted for suspected rupture of the spleen. As her condition had deteriorated the next day (March 7th) *explorative laparotomy and nephrectomy of the left kidney* were done. (Ether narcosis. Hublin and Nyström.) A short curved incision was made under the left infra-costal angle. A little blood was present in the abdominal cavity. The spleen was normal. The left renal sinus was distended. The left kidney felt enlarged and lumpy. The wound was closed exactly. The patient was then turned into the position for a kidney operation and an ordinary lumbar incision was made on the left side. The renal sinus was filled with fluid blood and coagula and numbers of loose pieces of tumour. The kidney was greatly enlarged, lumpy, and showed a certain degree of disintegration. The kidney vessels were ligated and the kidney removed. It was not possible to establish with certainty that the tumour had not grown into the renal vein. The wound

but points out that it should be made along the natural creases of the palm.

ROUTIER, BUSCH and others use V-shaped or Y-shaped incisions.

DESPLAS applies the cutaneous incision shown in the drawing. The incisions form a bridge of skin which is raised during the dissection, whereupon it is replaced and sutured.

GILL makes an incision parallel with the linea mensalis and transversely on the base of the finger. He "has never found it necessary to remove the skin".

HUTCHINSON's operation (1917). After the aponeurosis has been excised the base of the 1st phalanx is removed through a dorsal section and the extensor tendon is shortened.

The utmost caution should be exercised during the operation. One must be especially careful not to injure blood vessels and nerves which have become embedded in the fibrous tissue. Possibly blood vessels and nerves have to be sectioned separately and pulled aside. A wound heals more slowly in the palm than anywhere else except on the sole of the foot. The healing may be hastened by exerting an even pressure upon the entire surface of the wound. The best means of obtaining this end is the "sea sponge compression" suggested by BLAIR.

Most authors fix the stretched fingers with a splint for some time, about 3 weeks, and go on using the splint for the night for a period up to several months. KANAVEL, however, has reduced the splinting to 8—10 days which procedure in his opinion secures a quicker return of function.

Prognosis.

In 1932 DESPLAS had operated upon 8 patients, with excellent results in 5 and fair results in 3. In 1934 he had operated upon 32 and obtained "excellent results".

Up to 1932 A. A. DAVIS had performed excision of the palmar aponeurosis on 31 hands. On after-examination only 12 of them were excellent, 10 had a partly and 3 a fully developed recurrence. In 6 cases the anatomical result was good, but the function was poor on account of tenderness or insensibility of the fingers.

Besides, he applied subcutaneous division of the palmar aponeurosis in 8 cases, 6 with excellent results, 1 with a partly, and 1 with a fully developed recurrence. The follow-up extended over a period of 1—5 years.

myelocytes, 6 per cent; rod or band forms, 32 per cent; polymorphs, 48 per cent; lymphocytes, 10 per cent; large monocytes, 4 per cent; eosinophils, 0 per cent. Unfortunately, sternal puncture was not carried out.

Roentgen examination of the abdomen (LÖNNERBLAD). July 24, 1939. The colon meteorism was less pronounced. Kidney shadows indistinguishable. The outline of the left psoas muscle was visualized but not the right. The interpreting of the conditions in the flank fat was difficult in this relatively lean patient. The subperitoneal fat was less clearly visualized on the right side than on the left, possibly due to the fact that there was still an increased amount of fluid in the fat (incomplete absorption of the hematoma?). As the patient was not strong enough to stand a barium enema no further attempt was made to investigate the position of the caecum and the ascending colon, and the outlines of the mucous membranes in these segments of the intestine. A bladder stone almost as large as a plum was observed. The right side of the diaphragm was still high but the movements were good. There was no noticeable enlargement of the spleen.

The patient's condition improved and on July 29, 1939, he was discharged with a normal temperature and relatively symptom-free.

In October 1940 the bladder stone began to give trouble, and he was *admitted to a hospital in Stockholm on Nov. 5, 1940.*

Roentgen examination of abdomen and pelvis (ÅKERLUND). November 6, 1940. The kidney shadows were of normal size on both sides but the spleen shadow appeared to be considerably enlarged. Urethrocystographic examination revealed a bladder stone the size of a hen's egg and considerable enlargement of the prostate.

Operation (HELLSTRÖM). November 7, 1940. Suprapubic cystotomy and extraction of the calculus. The concretion was as big as a hen's egg. The postoperative course was complicated by a hematoma in the prevesical space.

During the succeeding two months the leukocytes varied between 27,000 and 89,500 per mm³. Differential counts on three occasions showed the following variations: myelocytes, 1 per cent; metamyelocytes, 1—2.5 per cent; rod or band forms, 8.5—10 per cent; polymorphs, 59—64.5 per cent; eosinophils, 0—1 per cent; basophils, 0—1 per cent; lymphocytes, 4.5—9 per cent; monocytes, 18—22 per cent. (A differential count in 1937 had yielded the following values: myeloblasts?, 1.2 per cent; myelocytes, 0.2 per cent; rod or band forms; 31.2 per cent; polymorphs, 52.6 per cent; eosinophils, 0.8 per cent; basophils, 0 per cent; lymphocytes, 7.4 per cent; monocytes, 6.6 per cent.)

The patient was discharged with the wound healed on Jan. 21, 1941.

Epicrisis. Judging by the pattern of the white blood corpuscles and by the evidence of the roentgenograms, which indicated an enlarged spleen, it seemed likely that some form of chronic myeloid leukemia was in question in this case. Both the perirenal hematoma and the prevesical hematoma arising after the opera-

3 hands had been treated with fibrolysin injections. 2 had a partly, and 1 a fully developed recurrence.

In 3 cases the involved finger had been amputated.

For a period of 30 years LEXER has operated upon approximately 200 patients with "very few poor results or recurrences".

KANAVEL *and co-workers* have published a report of 29 cases operated upon in the course of 12 years. 20 were excellent (2 of which, however, exhibited new nodules, but at a distance from the operative incision), in 5 cases the results were fair, 2 had recurrences, and 2 had not been followed up long enough.

Up to 1936 MEYERDING had operated on 117 hands of 84 patients. 13 of these hands had been operated upon elsewhere previously. Excision of the palmar aponeurosis was made in 97 cases with excellent results in 55, fair in 11, and poor in 8. The possessors of the remaining 23 hands were dead or could not be traced.

Subcutaneous division of the palmar aponeurosis was made in 13 cases, with good results in 5, fair in 2, poor in 2. 4 hands could not be traced.

Besides, digital amputations were performed in 6 cases.

Tenotomy was done in one case with a poor result.

Up to the year 1940 the same author had seen 315 patients and operated upon "more than 100". He had obtained "satisfactory results in about 90 per cent.".

S. L. KOCH has previously reported 29 cases and later operated upon 18. His results are "constantly improving".

Writer's Material.[1]

During the period 1928—43 111 patients affected with Dupuytren's contracture have been treated at the Orthopedic Hospital in Copenhagen. 101 were males and 10 females.

The youngest patient was 17 and the oldest 76, mean age 51. The mean age among the operated patients was 50, the youngest being 25 and the oldest 66.

The occupation of the patients may be seen from Table II.

The duration of the disease had been from 1 month to 40 years, on an average a little more than $6^1/_2$ years.

Among the 111 patients 164 hands were affected with Dupuytren's contracture. Bilateral involvement was most common, next in order the right hand alone (Table III).

[1] My sincere thanks are due to Dr. KAREN ROJEL of Odense for leaving me the material, a great part of which had been followed up.

and the hematoma delivered. The tumor was a lipoangiosarcoma. The displacement of the kidney seems to have been due more to the large hematoma than to the much smaller tumor.

11. (KOLBENHEYER.) A 49-year-old man. He became acutely ill with intense pain over the left kidney but without blood in the urine. Pyelography on the left side revealed a renal pelvis abnormal in shape. Judging by the illustrations, the renal pelvis was also more laterally situated than is normal. The condition was diagnosed as renal calculus. (In view of the subsequent developments, however, this first attack also may have been connected with a perirenal hematoma which was later gradually absorbed.) The patient returned 3 years later suffering from a similar attack of pain on the left side. A large mass was now palpated under the left costal arch. Pyelography now revealed that the renal pelvis occupied a different position from that seen in the pyelograms taken 3 years earlier. It was now lying close to the left side of the upper lumbar vertebrae. The upper portion of the ureter arched downward and medially, passing in front of a couple of the lumbar vertebrae. Urography yielded the same picture. A large perirenal hematoma was discovered at the subsequent operation. Histologic examination of the excised kidney revealed arteriosclerotic lesions in the blood vessels.

Thus, in this case, the kidney had been displaced medially. In addition to this, the ureter, or at least its upper segment, was dislocated ventrally, since it was lying in front of the lumbar vertebrae.

12. (SIMON.) The patient had had pains in the right kidney region for 3 months. At the physical examination hypertension (185/150) and a mass in the right half of the abdomen were established. A plain roentgenogram showed shadows of increased density and obliteration of the psoas major and kidney outlines on the right side. The pyelograms from the left side were normal. The right renal pelvis looked clumsy. It showed considerable lateral, ventral, and cranial displacement from the normal position. The ureter was arched over the soft tissue shadow, which formed a large bulge in a ventral direction. These features are clearly visible on the lateral pyelogram reproduced. The patient was operated upon by LAEWEN on a diagnosis of suspected hypernephroma. The kidney and a large part of the hematoma were removed. In the kidney there were a number of necrotic foci penetrating out to its surface. It seemed likely that the bleeding had originated from these areas.

13. (MACKENZIE.) A man, 35 years of age, who was suffering from polycythemia. He became suddenly ill, with pains in the left kidney region. At the same time a mass developed in the same area. A pyelographic examination was made on the left side, and according to MACKENZIE the renal pelvis, which was large and irregular in outline, was found to be dislocated downwards and laterally. Judging by the roentgenogram he reproduces, however, this interpretation can hardly be the correct one. The picture shows that the renal pelvis is displaced

The writer has attempted to classify the disease into grades on the basis of the data obtainable from the case records. The classification in all essentials is according to MEYERDING:

Grade 0: Nodules in the palmar aponeurosis, sometimes involving the skin, but no flexion deformity.

Grade I: In addition to the conditions already mentioned, major or minor flexion deformity of one finger only.

Grade II: Flexion deformity of more than one finger, nowhere attaining 60°.

Grade III: Flexion deformity of more than one finger, exceeding 60° in at least one.

Grade IV: Major or minor flexion deformity of all fingers.

As mentioned above the deformity as a rule affects the ring or little finger. The distribution in our material is as follows:

Thumb	6	times
Index finger	10	»
Middle »	36	»
Ring »	87	»
Little »	88	»

84 of the 164 hands were submitted to operation, 80 not. Table IV sets out the degree of the deformity of all the affected hands.

Table IV.

Degree of Deformity of the 164 Hands.

Grade	Excision of palmar aponeurosis	Digital amputation (sometimes supplemented with excision of palmar aponeurosis)	Not operated	Total
0	10	—	16	26
I	34	8	24	66
II	13	1	20	34
III	11	7	19	37
IV	—	—	1	1
	68	16	80	164

Operative Technique.

Considering that the material has been in the hands of different surgeons and that it extends over a period of 16 years witnessing a changing technique, the operation of course has been performed in various ways. The skin incision generally has been

adapted to the nature of each individual case, being S-shaped, cross-shaped, or, with increasing frequency during the latter years, as shown in the drawing. During recent years there has been an increasing tendency to wide excision instead of a removal of the contracting cords only.

In 7 cases only was the skin of the palm sacrificed and substituted by a skin graft, once by the method of THIERSCH, another time by a pedunculated graft from the abdomen, and in the remaining cases with KRAUSE's flaps. All the transplants "took" without complications.

In the case of amputations the soft parts of the amputated finger often were applied to cover a defect resulting from the excision of the palmar aponeurosis.

Usually the operation was bloodless, performed in a number of cases under local, though as a rule under general anæsthesia. Mostly dry dressing. When dealing with skin grafts and in some other cases, e. g. of injury to the skin during operation, the bandage applied has been a "vaselin net" (i. e. vaselin on a single layer of extra coarse-meshed gauze) and sponge compression consisting of an ordinary sea sponge wrapped in a piece of dry gauze. In about half the cases the hand was immobilized in a splint with the fingers in extension. The splinting often was continued for the night up to several months.

The skin sutures are removed on the 14th post-operative day, and active movements are instituted. In case of slow restoration of function, physical therapy, exercise, warm hand baths, and often iontophoresis with potassium iodide. A few cases of hypertrophic scars have been treated with roentgen.

Excision of the palmar aponeurosis was employed in the case of 68 hands of 62 patients. 2 of these hands had previously been operated upon elsewhere, in the one case 5 times.

62 of the 68 hands have been followed up for a period ranging from 6 months to 12 years. The follow-up period was less than a year in the case of 4 hands only. 40 have been followed up for 2 years or longer, 27 for 3 years or longer.

In 43 cases or 69 per cent. the results were excellent.

This group includes 6 hands which later have developed nodules, but at a distance from the operative incision and without further symptoms. In one case the result is excellent as far as the contracture is concerned, the scar looks satisfactory, there is no tenderness or flexion deformity and the fingers spread normally,

but there is hyperæsthesia and when the hand is clenched the middle and ring fingers are 2 cm. and the little finger 4 cm. short of reaching the palm. It was, however, considered warrantable to include the case in this group, considering that a roentgen examination revealed arthritis of the finger joints.

In 7 cases or 11 per cent. the results were fair.

All the hands of this group are capable of working. In one case the operated finger is 2 cm. short of reaching the palm when the hand is clenched. The remaining hands could be clenched freely. In no case did the flexion contracture exceed 20°, but there was some paræsthesia, hypæsthesia or tenderness, cicatricial hypertrophy or a slight tension. If these conditions were pronounced, the case was classed with the poor results.

The group includes 3 patients exhibiting the initial stages of minor recurrences, but without tenderness, tension, or limited motion.

In 12 cases or 20 per cent. the results were poor on account of recurrences, tenderness, hypertrophic scars, severe sensibility disturbances, or flexion deformity of more than 20° (cf. the case histories).

16 hands of 12 patients were treated with amputation of the affected finger, and as a rule simultaneous removal of the adjoining aponeurosis. The little finger was removed in 11 cases, the ring finger in 4 cases, and the middle finger in 1 case.

Indication to amputate as a rule was constituted by severe articular contracture, especially when accompanied by subluxation, but sometimes amputation was preferred by the patient, who wanted to regain the use of the hand as quickly as possible, disregarding the cosmetic result.

13 of these hands were after-examined. 3 had recurrences with contracture of the adjoining fingers, but the remaining 10 are satisfactory.

The number of amputations, 16 out of 84 operations (19 per cent.) is high when compared with MEYERDING's figures, viz. 6 out of 117 (5 per cent.). This is not, however, the only striking difference between the two materials. Operation was performed in 74 out of the 111 patients constituting the writer's material (67 per cent.), whereas MEYERDING of the Mayo Clinic reports operation of "more than 100" of 315 patients up to 1940 (about 34 per cent.).

According to J. S. Davis the material reported by Meyerding of 117 operated hands was the largest material reported from any single clinic up to 1936. The writer has not been able to find a larger material in the literature accessible for the present. In view of the limited size of the materials, a comparison of the results is of minor interest (Table V).

Table V.

Results.

Author	Excision of palmar aponeurosis					Division of the palmar aponeurosis				Digital amputation	Fibrolysin injection	Teneotomy
	Total	After-examined	Excellent	Fair	Poor	Total	Excellent	Fair	Poor			
Kanavel, Koch, Mason 1929	29	27	20 (74 %)	5 (19%)	2 (7%)							
Desplas 1932	8	8	5 (62 %)	3 (38%)								
A. A. Davis 1932 .	31	31	12 (39 %)	10 (32%)	9 (29%)	8	6	1	1	3	3	
Meyerding 1936 ..	97	74	55 (74 %)	11 (15%)	8 (11%)	13	5	2	2	6		1
Writer's Material 1944	68	62	43 (69 %)	7 (11%)	12 (20%)					16		
	233	202	135 (67 %)	36 (18%)	31 (15%)							

Discussion — Conclusion.

Dupuytren's contracture has been known as an independent disease for the last one and one-quarter century, but even now its etiology is not clear. Several factors seem to play a part. The essential causes presumably are heredity and minor traumata. The significance of the trauma is indicated by a far higher frequency among labourers than among clerks and people of similar occupation, and moreover by the facts that the deformity is about 7 times as common among males as among females, that the onset as a rule occurs in the right hand, that it never is encountered in children, and that it is rare in early life, but increases in frequency with advancing age.

Numerous patho-anatomical investigations have been made, but the nature of the disease has not been fully elucidated. The onset is characterized by proliferating, amply vascularized con-

nective tissue with marked round-cell infiltration, in advanced stages passing into tendon-like connective tissue with few cells.

The discomfort is due to a flexion contracture of the fingers. The pain and tenderness sometimes experienced arise in consequence of the transformation of the aponeurosis into firm connective tissue, exerting a pressure upon blood vessels and nerves.

The treatment of choice is excision of the palmar aponeurosis in cases where it is practicable. Hardly any effect can be expected to result from physical therapy, though redressing exercises may contribute to delay the contracture. Fibrolysin injections were only attempted in the case of one patient before he entered the hospital. The injections were of no effect whatever, and the hospital has not felt tempted to try this method of treatment.

The incision should be made along the natural creases of the palm, an incision across the creases being apt to destroy an otherwise satisfactory result by the formation of a tense, hypertrophic cicatricial bridge giving rise to fissures and pain. An incision in the finger should be antero-*lateral*.

The excision of the aponeurosis is most easily accomplished when the mobilization is begun proximally, at the apex of the aponeurosis which may be raised with a forceps and pulled downwards. With the aid of a fine knife or scissors all the fascial strips are carefully dissected free of the surrounding tissue. While mobilizing the aponeurosis the surgeon should be extremely careful not to damage the blood vessels and nerves embedded in the fibrous tissue and which may be displaced as much as the width of a finger (MASON). For this reason a bloodless operative field is to be preferred.

Before the wound is closed, the hæmostasis must be complete. Post-operative hæmorrhage is an annoying complication which may compromise the healing and delay the restoration of function.

General anæsthesia is preferable to local anæsthesia, the risk of post-operative hæmorrhage being less.

A total removal of the aponeurosis would be most desirable, but it is technically impracticable. On the other hand, a systematic removal of the aponeurosis in line with the three ulnar fingers may be accomplished, and considering that the disease in most cases is localized to this area, such a procedure presumably would diminish the risk of recurrence.

Affected skin areas should be removed and replaced by skin grafts of full thickness. KANAVEL even recommends the removal

of skin injured during the operation, contending that such skin has a poor tendency to heal. His experience is not in accordance with ours. We have obtained excellent results in several cases in which the skin had become badly lacerated during the operation.

Dressing with sea sponge compression is to be recommended. The use of a hand splint may be discussed. KANAVEL, who formerly used a hand splint for a few weeks, has shortened the period to 8—10 days, maintaining that he obtains a more rapid restoration of function by this method. In case of a tendency to contracture of a finger we would, however, recommend a splint for the night for some length of time.

Hot hand baths are the best remedy against post-operative tenderness and articular stiffness. Iontophoresis with potassium iodide also has been applied with good results at the Orthopedic Hospital.

When is an operation indicated?

In mild cases occurring in early life it is advisable to excise the palmar aponeurosis as a prophylactic measure, since the deformity always is progressive, though slowly in most cases.

In mild cases occurring at a mature age (about 50) one must await developments, since these patients have a chance of escaping further symptoms on account of the slow progression.

Severe cases occurring at a mature age call for an operation, if the patient is embarrassed by the deformity. If the general condition is satisfactory and the tendency to heal is expected to be good, excision of the palmar aponeurosis should be performed, but a severe articular contracture requires digital amputation. The soft parts from the amputated finger may successfully be applied to cover a defect in the palm left by the excision of the aponeurosis. In several cases amputation is an excellent form of operation and the patient can as a rule quickly return to his work.

Case Histories.

For lack of space the writer is unable to report all the case histories and therefore has chosen those exhibiting a poor operative result, which presumably are of most interest.

No. 1. — Left hand.

Case Rec. 2245/35. Painter, aged 50. First seen on June 12, 1935. An advancing Dupuytren's contracture had for several years been present in the ulnar fingers of both hands and the left thumb.

Obj. exam.: Contracting cords to the left thumb, ring and little fingers. The flexion deformity is most marked in the case of the little finger (Grade II).

On June 13, 1935, under ether anæsthesia, a cross-shaped incision was made opposite the ring finger and an antero-lateral auxiliary incision in the little finger. After all the contracting tissue had been removed the finger could be fully extended. Immobilization with extended fingers in plaster of Paris for a fortnight. Uneventful recovery.

After-examination on March 2, 1943 ($7^3/_4$ years after the operation): The scar is tender, projecting above the palm like a panel. Extensive recurrence. The tip of the little finger is in contact with the palm.

No. 2. — Left hand.

Case Rec. 2255/36. Tram conductor, aged 50. First seen on April 16, 1936. Dupuytren's contracture of 3 years' standing.

Obj. exam.: A 45° flexion contracture of the proximal interphalangeal joint of the little finger (Grade I).

On May 26, 1936: Operation. All the contracting tissue was removed with great thoroughness and a volar splint applied. The contracture quickly recurred and the scar was hypertrophic and tender.

On Oct. 7, 1939: Re-operation under ether anæsthesia. Excision of all the contracting cicatricial tissue. KRAUSE's skin graft from the abdomen. Uneventful recovery. After-treatment with night-splint.

After-examination on Febr. 13, 1943 (3 years and 4 months after the latter operation): Left little finger flexed 90° at the proximal interphalangeal joint. The scar is hypertrophic and tender, but the hand may be clenched freely.

(The same patient was submitted to amputation of the right little finger. Result satisfactory after a follow-up of 8 years).

No. 3. — Right hand.

Case Rec. 5460/36. Female brewery worker, aged 52. First seen on Aug. 26, 1936. Bilateral Dupuytren's contracture of 2 years' standing.

Obj. exam.: A bilateral, symmetrical flexion contracture of 30° at the metacarpophalangeal joint of the little finger and a slight contracture of the ring finger (Grade II).

On Nov. 5, 1936, under ether anæsthesia, through an S-formed incision with a bloodless operative field, the affected palmar aponeurosis of the right hand was excised. The surgeon was positive that all the contracting tissue had been removed. Post-operative treatment with iontophoresis and night-splint. 2 months after the operation the finger could be fully extended.

After-examination on Febr. 3, 1943 ($6^1/_4$ years after the operation): The patient is working, but there is a recurrence with a thick contracting cord of fascia and a flexion deformity of 90° at the proximal interphalangeal joint of the ring finger. (The left hand was submitted to the same operation and the same post-operative treatment with an excellent result (6 years after the operation)).

No. 4. — Right hand.

Case Rec. 806/39. Boiler-smith, aged 46. First seen on Febr. 7, 1939. Dupuytren's contracture of 3 years' standing.

Obj. exam.: Flexion deformity of the middle and ring fingers of 30° at the metacarpophalangeal joint (Grade II).

On March 6, 1939, under ether anæsthesia, through a bayonet-shaped incision, *operation for Dupuytren's contracture of the right* hand. Dressed with sea sponge compression. The healing took a month, after which time there was full mobility.

After-examination on Jan. 18, 1944 (nearly 5 years after the operation): Recurrence with tenderness of the volar scar and a rather marked contracture of the little finger. (2½ years after the operation the left little finger was amputated on account of Dupuytren's contracture with a good result).

No. 5. — Left hand.

Case Rec. 2362/39. Painter, aged 52. First seen on May 11, 1939.

Obj. exam.: Dupuytren's contracture of the left ring and little fingers (Grade II?).

On June 16, 1939 operation was performed under ether anæsthesia. All the contracting tissue was considered to have been removed, down to the flexor tendons. Dry dressing and sea sponge compression. Uneventful recovery. Shortly after the operation there was a recurrence and the contracture progressed. On Febr. 17, 1943 the proximal interphalangeal joint of the left ring finger was 30° short of a full extension and the little finger was flexed 80°. Pronounced recurrence causing inconvenience during work. The right hand is now involved.

On Febr. 19, 1943 re-operation under local anæsthesia. After removal of all the contracting tissue the proximal interphalangeal joint of the little finger was 30° short of full extension which only could be obtained by articular resection. The patient did not, however, wish such a resection, so the wound was closed and the hand splinted and dressed with sea sponge compression.

After-examination on July 17, 1944 (1 year and 5 months after the latter operation): 60° flexion deformity at the proximal interphalangeal joint of the little finger. The patient states that the finger is hardly any better than before the operation. 30° flexion deformity at the proximal interphalangeal joint of the ring finger, but the middle finger is satisfactory. The hand may be clenched freely.

No. 6. — Right hand.

Case Rec. 888/40. Engineer (enthusiastic rower), aged 34. First seen on Febr. 20, 1940. Increasing flexion of the right little finger during the last 5—6 years. Is "unable to use the hand any more".

Obj. exam.: 90° flexion deformity at the metacarpophalangeal joint of the little finger and 45° at the proximal interphalangeal joint (Grade I).

On March 29, 1940, under ether anæsthesia, through a Z-shaped incision removal of all the contracting tissue between the skin and tendon. The finger could be almost fully extended. A slight infection

in the wound yielded to treatment with ointment, soap baths, and potassium iodide iontophoresis.

After-examination on March 13, 1943 (3 years after the operation): Recurrence and a hypertrophic, somewhat tender scar, 45° flexion deformity at the proximal interphalangeal joint. Reduced sense of touch.

No. 7. — Right hand.

Case Rec. 4228/42. Coal carrier, aged 57. First seen on June 2, 1942. Advancing contracture of the right middle, ring, and little fingers of several years' standing.

Obj. exam.: 60° flexion deformity at the metacarpophalangeal joints of the little and ring fingers, 45° at the proximal interphalangeal joint and a slight tension when extending the metacarpophalangeal joint of the middle finger (Grade III).

On July 27, 1942 an operation was performed under ether anæsthesia. The fingers now could be almost fully extended. There was some superficial necrosis of the wound. After-treatment with ointment of cod liver oil, soap baths, iontophoresis and at last Kanavel's glove.

After-examination on Oct. 26, 1944 (2 years and 3 months after the operation): The patient states that the hand is much worse after the operation. He is unable to clench it properly and the scar is tender. He had been obliged to give up his work as a coal carrier and now earns his living as a labourer. On account of the hand he prefers handling a spade and similar coarse tools.

The objective examination did not reveal an actual recurrence, but a tender and hypertrophic scar involving a considerable contracture in the right palm. The contracture keeps the ring and little fingers close together, only permitting a spreading of a few mm. There is a flexion deformity of 25° at the metacarpophalangeal joints of the ring and little fingers and of 10° at the proximal interphalangeal joints. When clenched the ring and little fingers are 4 cm. short of reaching the palm.

No. 8. — Left hand.

Case Rec. 928/43. Fruit merchant, aged 37. First seen on Febr. 2, 1943.

During the last 3—4 years there have been nodular growths and tension of both palms and a flexion deformity of the fingers.

Obj. exam.: Contracting bands in the palm in line with the little, ring, and middle fingers. Flexion deformity at the proximal interphalangeal joint of the little finger of 40°, at the metacarpophalangeal joint of the ring finger of a few degrees, at the metacarpophalangeal joint of the middle finger of 30°, and at the proximal interphalangeal joint of the last-mentioned finger of 60° (Grade III).

On Febr. 3, 1943, under local anæsthesia, all the tissue contracting the little and middle fingers was removed. Dry dressing. Uneventful recovery.

After-examination on Oct. 26, 1944 (1 year and 9 months after the operation): For the last 20 years the patient has run a whole-sale business in fruit. He spends much of his time handling boxes filled with fruit without major discomfort.

The objective examination revealed a hypertrophic, firm, and tense, though not tender scar. There is an extensive recurrence at the site of the incision and contractive changes spread over almost the entire palm and the fingers. The nodules are not tender. The mobility is still surprisingly good, there being a flexion deformity of merely 10° at the metacarpophalangeal and proximal interphalangeal joints of the middle finger, and the hand clenching freely. The fingers spread poorly.

No. 9. — Right hand.

The patient is identical with No. 8.

Obj. exam.: Contracting bands in the palm and to the index, middle, and ring fingers. Flexion deformity at the metacarpophalangeal joint of the index finger of 10°, at the metacarpophalangeal and proximal interphalangeal joints of the middle finger of 45°, at the metacarpophalangeal joint of the ring finger of 20°, and at the proximal interphalangeal joints of the ring and little fingers of 45° (Grade II).

On Apr. 7, 1943, under local anæsthesia, all the tissue contracting the middle and ring fingers was removed. Immobilization in a volar splint. The healing was delayed, and the patient received a post-operative treatment of iontophoresis with potassium iodide x16.

After-examination on Oct. 26, 1944 (1 year and 8 months after the operation): No inconvenience when working. Recurrence and massive changes in the palm and on the fingers. The scar is very tender and there is a flexion deformity at the metacarpophalangeal and proximal interphalangeal joints of the middle, ring, and little fingers of 20°.

No. 10. — Left hand.

Case Rec. 1298/37. Warehouse foreman, aged 52. First seen on March 3, 1937. Dupuytren's contracture of the left hand of 10 years' standing.

Obj. exam.: A flexion deformity of 90° at the metacarpophalangeal and proximal interphalangeal joints of the ring and little fingers (Grade III). In 1943 the middle finger had become involved.

On July 28, 1943 an operation was performed under ether anæsthesia, leaving, however, a flexion deformity of 10°—30° of the middle, ring, and little fingers. Uneventful recovery.

After-examination on Oct. 30, 1944[1] (1 year and 2 months after the operation): The scar looks satisfactory and is not tender. Flexion deformity of 110° of the little finger, 90° of the ring finger, 70° of the middle finger, and 45° of the index finger. When clenched all these fingers are 3 cm. short of reaching the palm.

No. 11. — Left hand.

Case Rec. 279/43. Housewife (epileptic), aged 39. First seen on Jan. 13, 1943. (More than a year prior to this time the *right hand* had been operated upon elsewhere and an exacerbation of the condition had necessitated an amputation of the ring and little fingers shortly after. The index and middle fingers are now becoming involved.)

Obj. exam. (left hand): Flexion deformity of 90° at the proximal

[1] Personal communication from the patient's own physician.

and 10° at the distal interphalangeal joint of the little finger, 45° at the proximal interphalangeal and 20° at the metacarpophalangeal joint of the ring finger, 45° at the proximal interphalangeal joint of the middle finger (Grade III).

On Sept. 9, 1943, under ether anæsthesia, through a Z-shaped incision, and with a bloddless operative field, all the tissue contracting the middle, ring, and little fingers was removed. The middle and ring fingers may now be fully extended, whereas there still is a contracture at the proximal interphalangeal joint of the little finger. Hand splint. Uneventful recovery.

After-examination on Oct. 27, 1944 (1 year and 1 month after the operation): The little finger is in acute flexion and there is a flexion deformity of the middle and ring fingers. The patient has not regained the full use of the hand.

No. 12. — Right hand.

Case Rec. 11534/43. Representative (formerly mechanic), aged 42. First seen on Aug. 16, 1943. Increasing contracture of the right little finger of 2 years' standing. The patient has received fibrolysin injections elsewhere, but without effect.

Obj. exam.: Contracting bands to the ring and little fingers. A flexion deformity of 60° at the metacarpophalangeal and of 20° at the proximal interphalangeal joint of the little finger. A minor contracture of the ring finger (Grade III).

On Dec. 22, 1943, under ether anæsthesia, and with a bloodless operative field, removal of two thick lumps of fascia at the site of the extensions to the ring and little fingers. Sea sponge compression. Uneventful recovery.

After-examination on Nov. 3, 1944 (11 months after the operation): Working as a representative. Is unable to carry bags or anything else in the right hand on account of tenderness and hypersensitiveness of the little finger.

On the flexor surface of the little finger there is a longitudinal, tender, and tense, rather nodular scar, adhering to the underlying tissue. There is a marked hyperæsthesia, "an electric current racing through" the patient when the finger is touched. There is full mobility of all fingers. The scar in the palm is hardly visible and neither tender nor hypersensitive.

Summary.

After a brief survey of the etiology, pathogenesis, pathological anatomy, and symptomatology of Dupuytren's contracture the writer reviews the methods of treatment, surgical treatment in particular, and describes the various forms of incision.

111 patients affected with Dupuytren's contracture, 101 men and 10 women, have been treated at the Orthopedic Hospital in Copenhagen during the period 1928—43. The mean age was 51

years. Among these 111 patients 164 hands were affected. 84 were operated upon and 80 not. Excision of the palmar aponeurosis was performed in the case of 68 hands, 62 of which have been followed up for a period ranging from 6 months to 12 years. Only 4 hands have been followed up for less than a year, 40 have been followed up for 2 years or longer, and 27 for 3 years or longer.

The results were excellent in 43 cases or 69 per cent., fair in 7 cases or 11 per cent., and poor in 12 cases or 20 per cent. (Table V).

The writer recommends surgical treatment. Total removal of the aponeurosis is desirable, but technically impracticable. The risk of recurrence perhaps could be reduced by a consistent removal of the apneurosis in line with the 3 ulnar fingers, this area usually being the site of the lesion.

Finally, the writer discusses the operative indications.

The case histories of the patients exhibiting poor results are appended.

Zusammenfassung.

Es wird eine kurze Übersicht über die Dupuytren'sche Kontraktur, ihre Ätiologie und Pathogenese, ihre pathologische Anatomie und Symptomatologie gegeben. Darauf werden die Behandlungsmethoden durchgenommen, besonders die operative Behandlung, und die verschiedenen Inzisionsformen beschrieben.

Im Orthopädischen Krankenhause in Kopenhagen wurden in den Jahren 1928—1943 111 Fälle von D. K. behandelt, 101 Männer und 10 Frauen. Das Durchschnittsalter betrug 51 Jahre. Diese 111 Patienten hatten 164 angegriffene Hände. 84 Hände wurden operiert, 80 nicht operiert. An 68 Händen wurde Faszienexstirpation vorgenommen, und zwar sind 62 von ihnen nach einer Beobachtungszeit von ½—12 Jahren nachuntersucht worden. Nur 4 Hände wurden weniger als 1 Jahr beobachtet, 40 sind 2 Jahre oder mehr beobachtet worden, 27 3 Jahre oder mehr.

Das Ergebnis war ausgezeichnet in 43 Fällen oder 69 %, mittelmässig in 7 Fällen oder 11 % und schlecht in 12 Fällen oder 20 % (Tabelle V).

Es wird betont, dass die Behandlung eine operative sein soll. Vollständige Entfernung der Aponeurose ist wünschenswert, technisch aber nicht durchführbar. Vielleicht würde systematische Abtragung der den 3 ulnaren Fingern entsprechenden Partie der

Aponeurose die Rezidivgefahr vermindern, da das Leiden zumeist in diesem Gebiete sitzt.

Schliesslich wird beschrieben, welche Fälle zu operieren sind.

Es folgen Auszüge der Krankengeschichten der mit schlechtem Ergebnis operierten Patienten.

Résumé.

L'auteur fait un court exposé de la maladie de Dupuytren, de son étiologie et de sa pathogénie, de son anatomie pathologique et de sa symptomatologie. Il passe ensuite en revue les méthodes thérapeutiques surtout les méthodes opératoires et décrit les divers tracés d'incision.

A l'Hópital orthopédique de Copenhague, on a traité 111 cas de la dite affection de 1928 à 1945, dont 101 hommes et 10 femmes. Age moyen: 51 ans. Chez ces 111 malades, 164 mains étaient atteintes. 84 ont été opérées et 80 ne l'ont pas été. Dans 68 cas, on a pratiqué l'extirpation de l'aponévrose; 62 ont été controlés postérieurement. Temps d'observation variant de 6 mois à 12 ans. 4 mains ont été observées moins d'un an et 40 l'ont été 2 ans ou plus, 27 mains, 3 ans ou plus.

Résultat excellent dans 43 cas ou 69 %; moyen dans 7 cas ou 11 %, mauvais dans 12 cas ou 20 % (Tableau V).

L'auteur souligne que le traitement doit etre opératoire. Il faudrait pratiquer si possible la résection de toute l'aponévrose, mais c'est techniquement irréalisable. La résection de l'aponévrose correspondante aux trois doigts cubitaux diminue le danger de récidive, car c'est le point d'élection de la maladie.

Enfin l'auteur indique quels sont les cas qu'il faut opérer.

L'exposé se termine par des extraits de journal concernant les malades opérés avec mauvais résultats.

References.

Barsky, A. J.: Plastic Surgery, Philadelphia and London 1938. — Bonnevie, P.: Beretning om Arbejds- og Fabrikstilsynets Virksomhed 1939—41, Socialt Tidsskrift, Afd. C. 151: 1942. — Davis, A. A.: Brit. J. Surg.: Vol. XIX: 539—547 (April) 1932. — Davis, J. S.: Arch. Surg. 32: 332: 1936. — Davis, J. S.: Plastic Surgery, London 1919. — Desplas & Meillère: Bull. et mém. Soc. nat. de chir.: 58: 424: 1932. — Dupuytren: The Lancet, Vol. II: 222 (May) 1834. — Fredet, P.: Bull. et mém. Soc. nat. de chir. 58: 440: 1932. — Gill, A. B.: Arch.

Surg. 32: 332: 1936. — ISELIN, Traité de Chirurgie ortopédique, publié sous la Direction de L. Ombrédanne et P. Mathieu, Paris 1937. — KANAVEL, A. B., S. L. KOCH & M. L. MASON: Surg. Gynec. and Obst., Vol. XLVIII, 145—190: 1929. — KLAPP, R.: Lehrbuch der Chirurgie, Wullstein und Küttner, Jena 1931. — KLOSSNER, A. R.: Acta Societatis Medicorum Fennicae, Series B., Vol. XXXIV, Fasc. 2. 1944. — KOCH, S. L.: J. Am. Med. Ass., Vol. 100: 878: 1933. — KOCH, S. L.: Arch. Surg., 32: 331: 1936. — KROGIUS, A.: Acta chir. Scand., 54: 33: 1922. — LEXER, E.: Die gesamte Wiederherstellungschirurgie, Leipzig 1931, Vol. II. — LUND, M.: Acta Psych. et Neur.: Vol. XVI: 465—492: 1941. — MEYERDING, H. W.: Arch. Surg.: 32: 320—333 (Feb.) 1936. — MEYERDING, H. W.: Am. J. Surg., Vol. XLIX: 94—103: 1940. — MOURE, M. P.: Bull. et mém. Soc. nat. de chir., 58: 444: 1932. — NIEDERLAND, W.: Archiv für Gewerbepathologie und Gewerbehygiene, Vol. 3, 1932. — BLAIR, BUNCH, COOPER, KEEN: quoted from KANAVEL. — BUSCH, JANSSEN, ROUTIER, NOBLE SMITH: quoted from ISELIN. — JONES & LOVETT, LOEWY: quoted from MEYERDING.

From Ålesund's Municipal Hospital.
Chief: The author.

Sacral Dermoid Cysts. Especially with a View to their Treatment.

By

H. FROSTAD.

The sacral dermoid cysts may be divided into two groups: Those which lie anterior to the os sacrum and those which lie posterior to it. Those which lie anterior are very rare. They lie strongly ramified between os sacrum and rectum, opening into a thin fistula in the rima at the inferior extremity of the coccyx. They give rise to protracted suppuration and are cured by total extirpation after a broad opening and chiselling of the coccyx and the lower end of the os sacrum as by amputatio recti.

Here only the dorsal dermoid cysts will be mentioned, especially their treatment. They are tumours which occur frequently, affording one of the best proofs that tumours may arise from wrongly stored elements of tissue during the embryonic growth; concerning dermoid cysts, from wrongly stored ectodermic components. Numerous experiments upon animals, the first time made by E. Kaufmann, prove this. Transplantation of epidermis with its corium and subcutis, forms typical dermoid cysts whose pulpy contents consist of degenerated epithelium, hair and secretion of sebaceous gland. Similar experiments with transplantation of dermal patches to different parts of the body, were made by Ribbert.

It should be emphasized that these cysts caused experimentally, did not become very great, although the cyst wall retained its function of forming horned epithelium. Evidently, the growth of the cells is limited by the formation of a closed cyst. The small energy of growth is characteristic to cysts arisen experimentally and traumatically, in contrast to the congenital tumours which

like hair, detritus and fatdegenerated or horned flat epithelial cells may be found. After an inflammation gone through, moist secretion from the cyst will usually always keep in the rima inter nates.

Microscopically the wall of the dermoid cyst presents a structure which more or less reminds of the cutis with its papillae, hair roots and sebaceous glands. Occasionally even a systematic research of several specimens will not suffice to show any dermal vestiges. In this case the cyst wall and the tubes of the fistulae are completely necrotized, and often the picture of a chronic infection may be found only. Other times formidable cells may be found in the walls of the dermoid cyst. König believes that these cells are formed by the young cells of the connective tissue and are to be considered as cells of alien bodies, arising on account of the constant irritant in the contents of the cyst, especially the hairs, but also fat and sebaceous drops, pieces of chalk and sanguinary pigment.

As to a differential diagnosis tuberculous fistulae and common banal anal fistulae should be considered. They are located close to the anus and most frequently perforates to rectum, which the sacrococcygeal dermoid cysts never do. In the case of osteomyelitis in the os sacrum, or os coccygis bared bone is always found, whereas the dermoid cysts do not attack the bone. Banal abscesses, furuncles and carbuncles are located more laterally to the midline, and the characteristic dermal changes of the dermoid cyst are not found.

Owen apostrophizes the occurrence of sacrococcygeal dermoid cysts merely in the white race. Not a single case has been traced either in the black, yellow, or red races. The same authors state that they occur familially, most frequently in men. Under 10 per cent in women. Most frequently in the obese pituitary type and are very common in Jews.

While earlier attempts were made at explaining the genesis and clinic relations of these tumours, their *treatment* has not aroused any interest till of late. Complete excision with partial closure and drainage is recommended by Thomason and Owen. Subcutaneous suture with drainage, without cutaneous suture, is practiced by Eisenklam. Complete extirpation of non-inflammatory and inflammatory cysts far to the side in sound tissue, without suture and secondary healing, is recommended by Marongos, Schulz and Winkler. Marongos says: "We do not care about the abscesses, we do not split the tubes, but excide

the focus completely, far out in the sound tissue, so that thereby a palm-great wound cavity is formed, which goes down to the very bone." He also apostrophizes the fact that this kind of treatment is favourable to the patients, as it turns out that they otherwise disappear after the little incision which takes away all symptoms, and return only at the next infection. Now, if the cyst and the fistulae are radically removed at once, the patient will be released from this pain in future. In a way he is right. It is difficult for the patient to understand that further treatment is necessary, as the infection is gone and the wound cavity closed. However, he is usually reminded of the state by the constant secretion from the fistulae now commencing, and the intertriginous and scratching eczima thereby being formed. It has therefore been aimed at explaining to the patient that the symptoms will recur, if the cyst is not radically removed, and with us there are very few who have not returned for treatment.

The most important principle of the author's treatment, is, first an extirpation of the cyst and the tubes of the fistulae in sound tissue with primary closure without drainage. Secondly, it consists in preventing infection, based on the assumption that the latter always comes from the anal region.

The aim is to attain healing in the shortest time possible, without suppuration. In this way the stay at the hospital may be cut down to a few days, whereas the usual is a stay of two — three months during granulation and secondary healing of the suppurating cavity which is formed without closure.

The advantages of primary healing is, besides short stay at the hospital and thereby won time of labour, that one saves the patient the pains involved in the treatment during the protracted suppuration. Further, a normal, thick and insensitive layer of skin and subcutis over the sacrococcygeal surface is formed. However, in the case of secondary healing, the thin flats of the cicatrice lie close to the bone, forming no normal buffer and being sensitive to touch and painful to sit upon.

During the operation as well as the after-treatment one proceeds consciously, aiming at preventing infection from the anal region.

The operation is always carried out in spinal anesthesy in order to avoid diffusion by the local anesthesy of possibly present inflammatory material in the pericystic indurated tissue. During the operation the patient is placed in a ventral position with a flection of 45 degrees of the hipjoints.

By desinfection of the region of the operation it is tried all the time to avoid suppuration from the anal region. A conveniently great tampon is limed down with mastix in the rima, superior and close to the anus which is wholly covered. It absorbs possible filtering from the anus and prevents contact with the latter. Then the usual covering of the region of the operation takes place.

After the closure of the wound cavity a new tampon is limed over and superior to the anus instead of the blood-imbibed one which has been lying there during the operation.

After the operation the patient is placed in a ventral position and is not allowed to lie on his back the first 5 days. This is done to prèvent secretion or ampullary contents to filter from the anal region up to the lower part of the traumatic angle. If the patient is allowed to enjoy the usual dorsal position, and if an ever so little drain is placed in the traumatic angle, then all conditions are present to give rise to infection and suppuration in the great traumatic cavity.

During the first 5 days after the operation the patient is given liquid food only. As he is thoroughly emptied he has no spontaneous evacuation in this time. On the 6th day the patient may get up. The neighbourhood of the trauma and the anal region are then quite dry, and primary healing has been achieved. The sutures are removed, the patient is given a clyster and passes to full food. Younger individuals may as a rule be dismissed the same day. Older individuals are rather stiff and will like to wait until next day. They feel flabby after the fast which actually does them well, as they often belong to the obese pituitary type.

In the case of extirpation of the nonabseeding cyst, only so much cutis is removed as is necessary in an oval excision containing the openings of the sinuses and the cyst. Then the cyst and the ramified tubes of the fistulae are removed totally, by working to the sides and down to the strengthened ligaments on the surface of the posterior part of the coccyx.

If now everything is removed, the surface of the cut is formed by the typical sound polygonal adipose tissue. If greyish, typical-looking maculae in the traumatic wall as signs of vestiges of the cyst wall, or continuations of the fistulary tubes, occur, several excisions may be made until all diseased tissue has been removed. Yet no infection will occur, when everything has been done to

avoid invasion from the anal region, and the infectious cutaneous tubes have been removed.

If an infection has taken place earlier, then the nearest portions of the cyst walls and the tubes of the fistulae are indurated by connective tissue, and also this should be excided, as it, on the one hand, forms fast bundles of fibrous tissue between the skin and the plate of connective tissue on the surface of the os sacrum, being little elastic and preventing an ideal closure of the traumatic cavity. On the other hand, it is possible that it is the site of a latent infection which may reblaze in the favourable conditions which a traumatized wound surface forms.

If, as in the case of MARONGOS, extirpation is to be made during an acute inflammation, it is difficult to decide what belongs to the pericystic infiltered tissue. It is therefore necessary to go far out to the sides to be sure, and, in this way, a much greater traumatic cavity is attained, which prolongs the course of the illness considerably.

To be better able to decide what belongs to the cyst walls and the tubes of the fistulae, many authors have recommended injection of blue dye, such as indigo carmine, before the operation. However, it is probable that this is very unfortunate. First, it should be presumed that the outermost parts of the fistulary tubes are most strongly infected, as they lie nearest to the inflammatory source, and by the injection infectious material is carried to the outermost ramifications of the fistulary walls. Secondly, it often happens that the dye solution pierces through the thin cyst walls, and does it once enter the lax adipose tissue, it may spread far and wide. After such an injection, a considerably greater danger of infection should, therefore, be reckoned with.

After the complete extirpation the traumatic cavity is closed primarily from the bottom with subcutaneous and cutaneous suture without drainage. The subcutaneous closure is more easily done after removing all tissue indurated by connective tissue and an undermining to the sides to get the traumatic walls together, is, in this case, usually not necessary.

The absceding cyst is broadly incided and tamponed with lapis gas. Thereby a sound granulating traumatic cavity is formed, and the extirpation may be made when all symptoms of infection have receded, without the traumatic cavity being by far closed. If the abscess has had time enough to spread any far to the sides,

Table 1.

Results of the operations.

No.	Age	Sex	Duration of symptoms	No. of abscesses	No. of incisions	No. of days in bed after operation	No recurrence after no. of years	Path. anat. or clinic diagnosis
1	33 years	M.	1/2 year	1	1	6	3 years	Derm. cyst.
2	28 years	F.	1 year	1	0	8	3 years	Derm. cyst.
3	30 years	M.	9 years	6	1	7	4 years	Chr. infection.
4	24 years	M.	5 years	2	2	7	4 years	Clinic. diagnosis.
5	25 years	F.	1 year	1	1	9	4 years	Chr. infection.
6	24 years	M.	2 weeks	0	0	7	4 years	Derm. cyst.
7	24 years	F.	4 years	3	3	7	5 years	Clinic. diagnosis.
8	19 years	M.	4 years	2	2	8	5 years	Derm. cyst.
9	19 years	F.	1 year	2	2	7	5 years	Chr. infection.
10	27 years	F.	3 months	1	1	6	5 years	Derm. cyst.
11	21 years	M.	1 week	1	1	12	5 years	Derm. cyst.
12	22 years	F.	12 years	11	6	8	5 years	Derm. cyst.
13	19 years	F.	1 week	1	1	7	5 years	Clinic. diagnosis.
14	28 years	F.	20 years	8	6	11	5 years	Chr. infection.
15	32 years	M.	2 years	6	0	7	1 year	Chr. infection.
16	15 years	F.	3 years	1	1	6	1 year	Chr. infection.
17	24 years	F.	6 years	2	1	6	1 year	Derm. cyst.
18	25 years	F.	6 years	3	1	4	1 year	Derm. cyst.
19	20 years	F.	5 years	1	1	9	7 years	Clinic. diagnosis.
20	41 years	M.	15 years	8	6	10	7 years	Clinic. diagnosis.
21	20 years	M.	3 years	2	1	8	6 years	Derm. cyst.
22	20 years	M.	3 years	3	2	11	7 years	Derm. cyst.
23	45 years	M.	2 months	1	1	5	7 years	Derm. cyst.
24	23 years	M.	2 months	1	1	7	7 years	Clinic. diagnosis.
25	21 years	M.	1 month	1	1	8	5 years	Clinic. diagnosis.
26	22 years	F.	2 months	1	1	7	6 years	Clinic. diagnosis.
27	19 years	F.	8 years	15	3	9	5 years	Clinic. diagnosis.
28	22 years	F.	5 years	1	1	6	7 years	Derm. cyst.
29	23 years	F.	7 years	12	5	8	6 years	Derm. cyst.
30	19 years	M.	5 months	0	0	5	6 years	Derm. cyst.
31	30 years	F.	2 years	5	2	14	6 years	Derm. cyst.
32	18 years	F.	7 months	1	0	6	2 years	Derm. cyst.
33	26 years	M.	5 years	4	0	7	2 years	Derm. cyst.
34	25 years	F.	3 years	12	4	6	2 years	Derm. cyst.
35	23 years	M.	2 years	1	0	6	2 years	Derm. cyst.
36	24 years	F.	13 years	6	1	7	2 years	Derm. cyst.
37	19 years	M.	3 years	8	2	6	3 years	Clinic. diagnosis.
38	27 years	F.	3 years	3	1	6	3 years	Derm. cyst.
39	25 years	M.	2 months	0	0	6	3 years	Derm. cyst.
40	28 years	F.	3 years	2	1	5	3 years	Derm. cyst.

only a few days' stay at the hospital may be needed. But, as a rule, the patient may be treated ambulant and do his usual work.

The material consists of 40 cases being indicated in the table above. With the exception of two, all of them have been in for a control examination. Those two have sent a written information about their state. Only in two cases a lesser infection took place

in the operative trauma. No. 11 and No. 31. Otherwise they have all of them healed without reaction.

In none of the cases has recurrence occurred.

In some of the cases the specimen has not been sent in for path. anat. examination. Clinically, however, the diagnosis has been certain, with multiple sinuses in typical place in the rima and the extirpated cyst, or the incided abscess has contained dermoid-cyst-like detritus and hair.

From table I it will be seen that the age, at the time when the patient comes for treatment, varies between 15 and 45 years. However, the greater part come between 20 and 30, 28 out of 40, or 70 per cent. The average age $24^1/_2$ years. In contrast to this aie, in other authors, the females prepondent, 22 out of 40. The obese type has absolutely been predominant.

The greater part go with the illness for several years before it is correctly diagnosticated and treated. More than half of them have had their symptoms from 3 to 20 years, whereas only 12 out of 40 have had them less than one year. The average duration has been 3.9 years. The typical disposition of the state to form abscesses will be seen from the tabula. Singular is the fact that so many of the abscesses perforate spontaneously. It must probably be ascribed to the fact that the feeling of pain is less decisive in the regions of the buttocks than in other parts of the body. The average number of days in bed, is 7.5. Usually the patient is in full work after one to two weeks.

Summary.

After a short survey of the clinic of the sacro-coccygeal dermoid cysts, their treatment is especially dealt with. Its principle is complete extirpation, primary closure without drainage, and avoidance of infection based on the presumption that it always comes from the anal region. After the operation the patient lies in a ventral position for 5—6 days, on liquid food, and without having evacuation. On the 5th or 6th day the sutures are removed. The anal region is then quite dry and the trauma is healed primarily. The patient may be dismissed next day and is again at full work in one or two weeks. 40 cases are referred to with merely lesser suppuration in two cases. No recurrence and average stay at hospital 7.5 days.

Zusammenfassung.

Nach einer kurzen Übersicht der Klinik der sakrokokzygealen Dermoidzysten wird deren Behandlung besonders besprochen. Ihr Prinzip ist vollständige Exstirpation, primärer Verschluss ohne Dränage und Vermeidung von Infektion, wobei man von der Annahme ausgeht, dass letztere immer aus der Analgegend kommt. Nach der Operation liegt der Kranke 5—6 Tage lang in Bauchlage bei flüssiger Kost und ohne Ausleerung. Am 5. oder 6. Tage werden die Nähte entfernt. Die Analgegend ist nun völlig trocken, und das Trauma ist primär geheilt. Der Kranke kann am folgender Tage entlassen werden und ist nach 1—2 Wochen wieder in voller Arbeit. Es wird über 40 Fälle berichtet, und zwar kam nur in zwei Fällen leichte Eiterung vor. Kein Rückfall. Durchschnittlicher Krankenhausaufenthalt 7.5 Tage.

Résumé.

Après avoir fait un bref résumé de la clinique des kystes dermoïdes sacro-coccygiens, l'auteur s'arrête longuement à leur traitement. En principe, c'est à l'extirpation totale qu'il faut recourir avec suture par première intention sans drainage, en évitant l'infection que l'on suppose toujours provenir de la région anale. Le malade se couche en position ventrale pour 5—6 jours après l'opération et il est mis à la diète liquide pour éviter les évacuations. Au cinquième ou au sixième jour on enlève les sutures. La région anale est alors tout à fait sèche et l'incision guérie *per primam*. Le malade peut être congédié le jour suivant et est complètement apte au travail une à deux semaines plus tard. Sur 40 cas mentionnés par l'auteur, il y a eu légère suppuration dans deux cas seulement. Aucune récidive; durée moyenne du séjour à l'hôpital: 7.5 jours.

Literature.

Kaufmann, E.: Virchows Arkiv. 1884: 97: P. 395. — Ribbert: Deutsche Zeitschrift f. Chir. 1898: 47: P. 243. — Cederbaum: Beiträge z. kl. Chir. 1914: 88: P. 92. — Hubley, R.: Annals of Surgery 1934: 99: P. 868. — Thomason, Th. H.: Annals of Surgery 1934: 99: P. 585. — Barden, R.: In Keibel und Malls Handbuch der Entwicklungsgeschichte des Menschen. 1910. — König: Archiv f. klin. Chir. 1894:

48: P. 297. — Owen, H. R.: Annals of Surgery 1934: 99: P. 868. — Eisenklam, D.: Wiener kl. W.schrift 1933: 29: P. 903. — Marongos, G.: Wiener kl. W.schrift 1939: 34: P. 1233. — Schulz, J.: Centralbl. f. Chir. 1939: 34: P. 1737. — Winkler, J.: Wiener kl. W.schrift 1912: 36: P. 1348. — Corning, H. K.: Lehrbuch der Entwicklungsgeschichte des Menschen 1921.

From Ålesund's Municipal Hospital.
(Chief: The author.)

Rupture of the Aponeurosis of the Shoulder Joint, Particularly Referring to its Treatment.

By

H. FROSTAD.

In the last twenty years not a few has written about the injuries to the shoulder. The pioneer in this field is E. A. CODMAN who, as it were, has devoted his life to the study of the pathology of the shoulder. Very interesting is the description of bursa subacromialis and its relation to rupture of the aponeurosis of the shoulder joint.

If the rupture is discovered early, it is easily suturated, and the result will usually be a complete function of the shoulder joint. Suturation of an old rupture is more difficult and the result will not be so good. Its value may be said to be rather doubtful. The most ideal would be to make the diagnosis the first days after the damage and by operating suturate the recent rupture.

Material: These investigations are based on the study of 243 arthrographically examined patients and 64 obductions of shoulders. 87 arthrographics and 48 obductions among these have previously been mentioned by the author in Acta Radiologica 1942. In the material consisting of 243 arthrographics complete rupture was to be found in 76 cases. Incomplete ruptures at the undersurface of the aponeurosis in 27 cases.

23 arthrographies have been used by fractura tuberc. majoris and avulsion fracture at the insertion of the aponeurosis, 13 of which with communication to bursa subacromialis. 19 by luxatio humeri, 6 having rupture. 7 by luxatio acromioclavicularis, none having rupture. 31 by tendinitis calcarea, 3 having rupture. 16 with secondary rigidity without any rupture. 4 with bursitis sub-

acromialis chr. without rupture, and 62 other injuries of the shoulder without any ruptures.

Among the 76 complete ruptures diagnosed, 32 have been subjected to operation, 23 of which by the author himself. 6 are operated after HJORT's method, 7 are primarily suturated and 10 are operated after the author's method. The last 17 have been postexamined and will be particularly mentioned. A special control of the complete material is in preparation.

In the 64 cases obducted complete rupture was found in 8, incomplete in 9, 2 of which at the uppersurface of the aponeurosis.

Bursa subacromialis and the aponeurosis.

To understand better the conditions of the rupture only a few features of the normal anatomy of the shoulder will be mentioned. In most anatomical works a bursa subdeltoidea and a bursa subacromialis have been described. According to CODMAN they are usually connected with each other into a large bursa subacromialis. Very unfrequently a thin membrane may exist between them or only a slight contraction on the spot where the membrane was to lie. The capsule of the shoulder joint is in its superior, posterior and frontal part inextricably intermixed with the plane, extended tendons of m. m. supraspinatus, infraspinatus, teres minor and subscapularis into a single large aponeurosis being fixed to collum anatomicum. The tendons of these muscles are also mixed and to separate them would be very difficult. The internal part of the aponeurosis is thus limited by the joint cavity, while the external is limited by bursa subacromialis. The floor of this bursa is closely connected with the aponeurosis, while its roof turns to musc. deltoideus and the undersurface of the acromion. When rupture of the aponeurosis occurs, it removes the base of the bursa and a direct communication between the shoulder joint and the latter takes place.

By an eventual operation or obduction of a rupture of the aponeurosis, one is always surprised at the size and extent of the bursa. When it constantly appears less at the roentgenogram when examining living persons, this must be due to the difficulty of filling it completely on account of the muscular pressure. A less central part is filled, but the more peripheral parts of it lie pressed together to the capillary fissure which is its normal lumen. Its real size is therefore difficult to point out roentgenologically, cadaver excepted. Fig. 1 shows a normal bursa filled with lipiodol.

The specimen is taken from a cadaver, a farmer 71 years old, dying from intercurrent illness. In prophile one sees that about $^2/_3$ of it is coming within acromion, while the rest of it lies like a hat over the lateral part of caput, collum anatomicum, tuberc. majus and collum chirurgicum. At a picture taken from above it is seen that it also sticks below the acromioclavicularly joint and the lateral end of clavicula. The lat. border of acromion is marked by a visible line in the contrast.

Rupture of the aponeurosis occurs both with elder women and men. It very seldom occurs before the age of 40, but later it is increasing with the years. According to LINDBLOM's investigations the frequency, however, decreases after the age of 65. Occasionally, however, ruptures may be seen with younger persons. Thus LINDBLOM has mentioned a case with a labourer about 32 years old, and I myself have seen a case with incomplete rupture in a man 27 years of age after trauma with fall on the shoulder. (Fig. 2.)

Rupture appears, however, most frequently with labourers. But by sufficient traumas any man or woman having passed the stage of youth, will get it.

Classification: According to CODMAN ruptures may be classified in total and partial ones. The former affect the whole aponeurosis subscapularis, supraspinatus and infraspinatus. Teres minor lies so far behind — downwards — that rupture of it may be considered to be improbable, at any rate it has not been observed by the author. The length of a total rupture measured along collum anat. will be about 9—10 cm. Some variation will occur due to strong and weak structure of the bones.

The partial ruptures include only a part of the aponeurosis and pierce one or more tendons or parts of it. They may be complete with avulsion of the complete transversal in the aponeurosis, or incomplete ones, only through a part of it.

The incomplete ones may again be subdivided into internal and external incomplete ruptures, according to their position externally to bursa subacromialis or internally to the joint cavity. Central incomplete ruptures most probably exist as well.

Etiology: The cause of a rupture is primarily trauma. A direct fall on the shoulder pushing it against the ground, fall on the partly abducted arm, fall hanging in an arm, often with an unfortunate distortion or a strain in the lengthwise direction of the arm when lifting heavy loads. Besides the trauma the aponeurosis in

elder individuals must be supposed to have degenerated more or less and thus be predisposed for rupture.

LINDBLOM has examined a great deal of aponeurosis in elder people without rupture, and in these too in a number of cases found little islands of fibrinoid degeneration. ULLMANN found by his examinations hyalin and mucoid degenerations. In approximately all the cases from 26—80 years LINDBLOM, in addition, found the bundles of the connective tissue changed into more homogeneous sclerotic tissue. With children, however, there was plenty of loose connective tissue between thin bundles of same.

Changes in the vascularization with degeneration of tissue and thus an inclination for rupture has been stressed. LINDBLOM, however, examined the vascularization in cadaver with and without rupture by injecting cinnabar in the vessels of the aponeurosis and afterwards made an X-ray examination of it. He found it almost similar in both cases and was of the opinion that the theory on reduced vascularization in tendons with rupture had not been proved.

In some cases calcified deposits together with rupture have been demonstrated, and it is obvious that it weakens the tendon and predisposes it for rupture. (Fig. 3.)

In many cases the trauma that brought about the rupture can be exceedingly slight and even arise when the patient is performing his customary work which has been done for years without his being troubled by it, and in some cases a rupture by abduction is found although trauma in the shoulder is not accounted for in the anamnesis.

By opening the bursa: One notices in recent ruptures firstly perhaps a peripheral end of 1—2 cm. length with a somewhat retracted central part, so that the hole in the manchette is triangular with its basis turning to collum anat. The edges are broad and firm and are well fitted for suture. After 2—3 months the short peripheral end especially degenerates so much that suture is out of the question.

Secondly the peripheral end may lack. On the ruptured spot in collum anatomicum and adjacent parts of tuberculum majus and minus an uneven and rough plane is discovered.

By roentgen examination may thirdly be seen that the aponeurosis has taken away a bony crust of tuberculum majus. The picture called fractura tubereulum majoris and avulsion fracture

at the insertion of the aponeurosis is frequently seen. The mechanism for the arise of the fracture is similar to that of the rupture, and by arthrographical examination communication between the joint cavity and the bursa is very often found. A slight avulsion fracture may, however, only with difficulty be healed. Therefore a permanent communication between the joint cavity and the bursa will take place, as is the case with rupture. Fig. 4 a shows such an avulsion fracture, 6 months old in a fisherman 35 years of age.

Is, however, a greater part of the whole tuberculum majus taken away, it will be healed and the communication will be interrupted. This is seen from Fig. 4 b + c. Fractura tuberculi majoris in a woman, 32 years old. Fig. 4 b was taken on the day of damage. Fig. 4 c, 8 weeks later.

Is the aponeurosis weak, rupture like that in old people with degenerative changes, will be brought about. If it is strong like that in younger people it will stand the pressure, but the bony crust will be taken away. This is how the young ones rupture. This has previously been mentioned by the author in a paper in Acta Radiologica 1942. In 1943 K. Lindblom has pointed out the same in Acta Radiologica.

In the case of inveterate ruptures the picture is somewhat different. The central stump atrophies gradually, its edges are getting thinner and by and by quite smooth and facetted. The peripheral stump atrophies gradually as well. Finally only warty formations at its insertion will be left, and they too may disappear.

If both supra- and infraspinatus are ruptured, tuberculum majus itself stands out as a prevention by abduction of the arm. At the rupture of subscapularis, tuberculum minus is still more prominent, looking like a bean-shaped, rough and uneven tap, crashing against acromion when abducted.

Osteophytes are seldom to be found on tuberculum majus, but more often uneven erosions in collum anatomicum some way up the caput.

All this, I suppose, one may characterize as rough areas on tuberculum majus, minus and collum anatomicum with the adjacent parts of caput. They have always form of destruction, deposits being infrequently found. By destruction the loss of substance differs. Islands are formed, with grooves and ditches between. The islands with harder bony substance being left, are particularly characteristic of the collum region, and they very often have a plate of cartilage at the top.

The rupture is, as a rule, larger in elder than in younger individuals. After all it may be said to be probable that a rupture takes place in stages. In several cases inveterate central ruptures have been found together with recent peripheral ones.

Symptoms: The symptoms of the rupture of the aponeurosis are subjected to some variation dependent on its being acute or inveterate. In the former case the patient feels great pains resulting from the trauma and as a rule it would be difficult to move the shoulder joint without increasing the pains. He keeps his arm fixed to the body supporting it by the other arm. The pains are especially great when abduction is tried. Otherwise the conditions of the pains are almost parallel to those accompanying other lesions of the shoulder. Besides sensitiveness for pressure corresponding to rupture is found. This sensitiveness disappears as tuberculum majus and the ruptured spot slips below acromion when the arm is abducted. The so-called Dawbarns sign. In addition comes disturbed humeroscapular-rhythm, and occasionally an incavation laterally to acromion corresponding to rupture is felt.

What troubles the patient suffering from inveterate ruptures, is pains in the shoulder, less mobility of the shoulder joint and a general weakening of the arm. Are the rough areas very much pronunced all movements will be painful, although greatest around the horizontal, often with audible and palpable crepitation. The pains are usually greatest at night, and it is impossible for the patient to lie on the side affected. Owing to these pains the patient has been unfit for work for several months and even several years. Sometimes the patient tells that it slips in the shoulder when it is abducted, and on closer examination a distinct click is noted when the arm by abduction passes the horizontal, and tuberculum majus slips past acromion.

With regard to the mobility in the shoulder joint the outward-upward lifting of the arm proves to be worst. The forward-upward lifting is somewhat better on account of musc. coraco-brachialis and caput longum bicipitis taking part in this movement. By abduction scapula follows before the arm has reached the horizontal, while it normally is kept fixed till the arm has reached that height. Scapula participates in a compensating way at a too early stage in the abduction: The so-called disturbed humeroscapular-rhythm. When scapula has been swung out maximally further elevation of the arm may take place to some extent by means of

supra- and infraspinatus. When the patient puts the hand on the other shoulder the elbow follows close to the breast and cannot be lifted. With the hand behind the neck the elbow points forward and in the direction of the chest. Because of the difficult inward-rotation it will not be easy to put the hand behind the back. The passive mobility in the shoulder joint is unlimited if no secondary rigidity of the shoulder is present. To put the hand behind the back is really the most difficult movement after an abduction, in the case of recent rupture owing to the heavy pull of the capsule when being rotated, and when inveterate ruptures are concerned, on account of the narrowing of the capsule after the patient having kept his arm at rest too long. Muscular atrophy varies according to the size of the rupture. When supra- and infraspinatus are ruptured a distinct atrophy occurs after 2—3 months.

Diagnosis: The diagnosis may be made with difficulty as several symptoms may be lacking. Besides the symptomatic picture of rupture is almost similar to that pertaining to other lesions of the shoulder. In all the cases where the presence of rupture is doubted, arthrography will decide it.

By roentgen examination and arthrography: Regarding the shoulder joint communication between the joint cavity and the bursa is found indicative of complete rupture and defects in the undersurface of the aponeurosis signifying an incomplete one. (Fig. 6.)

Besides elucidations and calcareous atrophy are very often found, particularly in the tubercles and the collum region, erosions and rough areas in collum anatomicum and in tuberculum majus and minus. (Fig. 5.) Seldom arthrotic changes.

The treatment: The purpose of the treatment is to relieve the pains, reestablish the mobility in the shoulder joint, and as far as possible regain the strength of the arm.

1. *Conservative treatment:* This treatment will as a rule turn out to be successful in the case of incomplete rupture. Any healing must not be expected as the central part of the rupture is inclined to become larger, but the edges are gradually smoothed, the pains disappear and the mobility improves. If the pains are great, the arm may be placed on an abduction-splint for a week, but usually it is not necessary. That the patient from the beginning carries on with active movements to avoid the secondary rigidity is of the greatest importance. All of the diagnosed incomplete ruptures at the undersurface of the aponeurosis were conservatively treated.

This was partly due to advanced age, partly to inconsiderably pronounced symptoms, but also because the patients often object to being operated on.

When the diagnosis rupture of the aponeurosis has been made by arthrography, indication for operative intervention is present with complete or partial invalidity owing to:

1. Considerable pains when moving.
2. Considerable active limitation of mobility and weakness in the arm.
3. Distinct roentgenological changes in the bony parts.
4. Distinct clinical changes as crepitation and click by abduction and palpable incavation.

Sometimes, however, patients will be met with having obvious clinical symptoms of rupture of the aponeurosis without communication with the bursa. In some cases an incomplete rupture will certainly be present on the upper surface of the aponeurosis. By obduction such a rupture has been seen twice partly with considerable rough areas. Roentgenologically the diagnosis is difficult to make. In that case a bursography ought to be made in order to point out the defect in the bottom of the bursa corresponding to the upper surface of the aponeurosis. The conservative treatment will certainly help the great majority of them by the immanent capacity of the organism for smoothing the frayed areas by means of the atrophication of the rumped tendinous lobes.

If the symptoms still are obstinate, with limited mobility and secondary rigidity of the shoulder as a result, it may, however, be indicated to undertake an explorative opening of the bursa. That is a slight intervention which may be profitable in order to remove a protracted misery.

Not all the frayed areas on the upper surface are due to rupture. Calcareous foci in the aponeurosis may be emptied to the bursa by an acute blaze. After some time a smoothed defect in the calcareous bed will then appear being like an incomplete rupture on the upper surface.

2. *Suture:* For suture only recent ruptures with a good peripheral stump are fitted. We have here suturated up 2 months old ruptures with a good result. A good hold must exist in the peripheral stump and the central stump must not be atrophied.

Regarding the direction of the incision by the exposure of the rupture, an incision of about 5 cm. is used, from the acromio-

Fig. 1. Shoulder joint. The specimen taken from a cadaver. Bursa subacromialis filled with lipiodol. a. In prophile. b. From above.

Fig. 2. Incomplete rupture in a man 27 years of age. Arthrogram taken after injection of urotrast and air.

Fig. 3. Calcified deposits together with rupture. a. Arthrogram in incomplete and b. in complete rupture.

Fig. 4. a. Arthrogram in complete rupture with avulsion fracture of the tuberc. majus. b. Arthrogram in fract. tuberc. majoris with communication to bursa subacromialis.

Fig. 4. c. The same patient 8 weeks later. The fracture is healed and the communication interrupted.



Fig. 5. Arthrograms in complete ruptures. a + d: After injection of air. b + c: After injection of Urotrast. a + c: Very prominent tuberc. majus. b + d: Erosions and rough areas in tuberc. majus and collum anatomicum.

Fig. 6 a. and b.: Arthrograms in incomplete ruptures on the undersurface of the aponeurosis.

clavicular joint in a direct lateral line splitting the deltoid fibres lengthwise and opening the roof of the bursa. By this a good view of the joint is obtained. Particularly by simultaneous traction in the lengthwise direction of the arm, and outward and inward rotation the complete domain, from the insertion of the subscapular tendon at tuberculum minus, to the tendinous insertion of infraspinatus at the distal part of tuberculum majus, may be seen.

Formerly the socalled sabre-cut incision, pointed out by CODMAN was used. The incision was laid from the arcomioclavicular joint to an extent of 5—6 cm. towards the most anterior axillary crease. Besides the basis of acromion was often chiselled through for the purpose of reaching the upper surface of the joint more effectively. After such an incision it has proved to be more difficult to restart the movements on account of the retracting faces of wound at the frontal side of the shoulder. After the suturation the arm is placed on an abduction-splint for 3 to 5 weeks, to some extent dependent on the size of the rupture. Already in the course of a week passive movements are started and 3 weeks afterwards followed by active ones. At the beginning slight passive movements by rotation and forwardmoving are made. Besides the patient is put horizontally in bed and his arm is passively placed upward along his head.

By postexaminations and arthrography it appears that the suture of the aponeurosis is not always tight, both air and contrast going into bursa subacromalis. It does not sound strange that in such long ruptures up to 5/6 cm. defect may be formed with a little hole by which the contrast is passing.

III. *Wilson's method:* In inveterate ruptures WILSON's method was previously used. He chisels out a deep V-formed ditch at the tubercular major side of collum anatomicum corresponding to the normal insertion of the tendon and in the extent of the capsular defect. Then several holes from the basis of tuberculum majus to the bottom of the ditch are drilled. By pulling downward at the arm and by simultaneously rotating it inward and outward a good view of the defect of the aponeurosis will be obtained, and the central stump may be fetched by a forceps. The edge of the aponeurosis is then drawn laterally to the bottom of the ditch by means of a number of sutures of flax or silk through the holes in tuberculum majus.

By this method one obtains a contact between the flat aponeu-

rosis and the spongeous bony plane in the ditch. In addition is obtained that the ditch medially to tuberculum majus is filled in the approximately normal way, preventing it from crashing against acromion when being abducted.

What proves difficult is, however, to arrange a healing between the bone and the aponeurosis. The suture will as a rule be torn, and now the situation is worse than before, tuberculum majus now being more prominent.

After such a suture adm. WILSON, the shoulder must be immobilized for a very long time, and, in addition, a secondary rigidity of the shoulder will certainly be the result. This will have to be broken when the movements are going to be started. LINDBLOM & PALMER, OTNES and ULLAND have referred cases operated on ad modum WILSON.

IV. *Hjort's method:* HJORT has launched a new method. He chisels a part of crista ilei including the nearest parts of fascia lata. The bony piece is firmly screwed to a chiselled line at tuberculum majus, and the fascial piece is firmly suturated to the central end of the aponeurosis. He has related about his material in the chirurgical association in Oslo 1942 and his results had been favourable.

6 cases after HJORT's method have been operated upon by the author. In one case the screw had to be removed, and in one case the bony piece and the necrotical remnants of the fascicular flap was driven out. In 4 cases an improvement was achieved, but still limited mobility accompanied by some pains.

V. *Roar Strøm's method:* ROAR STRØM has launched a modified Wilsonic method. He fixes a part of the tendon of musculus plantaris longus to tuberculum majus ad modum WILSON. ROAR STRØM, as well, has demonstrated his cases in the chirurgical association in Oslo 1942.

VI. *The author's method:* On account of the slightly satisfying results from the previous methods the author has launched a new method, which will be mentioned together with the results.

By exposure of inveterate ruptures one notices the abovementioned distinct frayed areas, especially of the prominent tubercles, and it is obvious that the crepitation is brought about by these areas. The slippery feeling in the joint on abducting, the accompanying pains, limitation of mobility and the weakening of the arm must be put down to the same cause.

The principle of treatment was intended to relieve the pains, reestablish the mobility of the shoulder joint and as far as possible regain the strength of the arm.

It was difficult to make the pains disappear and to restart the movements by the chiselling of the ditch and by transplantation of splinter of the bone with fascicular flap from crista iliaca.

Lately one has therefore always, as far as possible, without plastic only made a point of reestablishing the smooth sliding plane at the upper surface of the aponeurosis which is characteristic of the normal joint. This is obtained by

1. Suture of recent ruptures with a good hold in the peripheral tendinous stump besides chiselling and smoothing of all the rough areas on the tubercle and the suture itself.

2. All the other, recent and inveterate ruptures are planed getting rid of the rough areas. It may be recent ones with a bad hold or degeneration of the peripheral stump or with none at all. Inveterate ruptures with prominent tubercles, often increased with wart-like degenerated remnants or peripheral tendinous stumps, and by a deep erosion of the bone in collum anatomicum. In a rupture of the subscapular part of the aponeurosis is tuberculum minus, being like a peak, particularly prominent and provokes great pains when moving the shoulder joint.

One perceives that the organism itself works to repair injuries of the shoulder, in a rupture in this way by facetting and smoothing. This is evident because of the fact that by obduction large ruptures are found which have given no symptoms, and that these ruptures nearly always appear with a quite even plane. By planning one cooperates with the organism in its curative work. It has turned out that the more radically one proceeds, the better the result. The prominent tubercles and all projections or frayed areas of tendinous, cartilaginous or bony kind are chiselled till the complete upper surface of the joint in this region constitutes an even plane all over, which slips easily below acromion.

In recent ruptures with frayed and broad central end, this is smoothed as well if suture is impossible. In inveterate ones the central end has been facetted quite smoothly with ovular, convex edge turning laterally.

After the planing the bursa is closed so far it is possible. In deltoideus only a few sutures through its upper fascia are taken, being followed by the suturation of the skin.

Posttreatment: As soon as the patient awakens from the narcosis, or the day after the operation the moving exercises in the shoulder joint may start. The arm is not placed on an abduction-splint, but the patient may keep it resting on a pillow by his side. He may use the arm as it pleases him and usually gets up in 3—4 days.

From 1—3 days the movements in the shoulder joint will as a rule be painful, and the exercises are limited twice a day to moving the arm in all the directions within its normal region of mobility. At the outset these exercises ought, usually, to be done passively owing to the pains. But already the third day the patient may actively put his arm in full abduction lying horizontally in bed.

After a week when the wound has been healed, it is necessary in some cases that the pat. goes into training with rings, trapeze or by hoisting the arm in full abduction by means of a pulley resisting actively when the arm falls down. In most cases, however, this had proved to be quite unnecessary. After about 2 weeks application of massage takes place being essentially based on passive and active motionary exercises in the shoulder joint. Contemporaneously the pat. may eventually leave the hospital and be treated ambulantly. Many times even massage has turned out to be completely superfluous. 4 weeks afterwards he is often in full-time work again.

The advantages of this treatment are:

1. The intervention is much less than the previously mentioned methods.
2. The long immobilisation and the subsequent rigidity of the shoulder, which makes the restarting of the movements so difficult and painful, are avoided.
3. A short time in bed and hospital which particularly is of importance to elder persons.
4. The pat. may rather quickly start his usual work.
5. They are soon relieved of the pains and are able to make the movements to a normal extent. That they after the operation are capable of making the same movements as in the other normal shoulder when the pains are interrupted, should be indicative of the fact that this is primarily due to the pains preventing them either directly or by reflex.
6. The indication for intervention may be stretched further and rupture with secondary rigidity of the shoulder may be in-

cluded as well. During the intervention the rigidity will be mobilized and later on there will be a similar post-treatment for both conditions.

7. Strange to say the strength in the arm is gradually improved, the very abduction itself too. This is, of course, most usual when a partial rupture occurs, where only supraspinatus or even both supra- and infraspinatus are ruptured, but especially by rupture of subscapularis only, the strength is remarkably well preserved.

Total rupture is very seldom, but even in these cases it has appeared, that the movements in the shoulder joint, the ability of abduction and the strength are gradually improved.

When pains are present in the shoulder joint one notices when the patient is going to abduct, that he is unable to use the muscles of abduction. Instead of that he lifts his shoulder, bends over to the other side and preferably uses his adductionary muscles. When the pains have disappeared he makes use of his abductionary muscles to a full extent and after some exercise they abduct completely in an active way. The strength when abducting is, however, as a rule somewhat less than at the other side.

Complications: The only complication seen is that articular fistulae have been observed twice. The latter are characterized by the great amount of fluid secreted and the mixing of fibrinoidal flakes which to some extent may remind one of a partial necrosis. The fistulae have, however, closed rather quickly and have not resulted in any limitation of mobility or pains. Most probably this must be a catarrh of the synovial membrane. It may also be possible that it is due to an abnormal reaction against the contrast medium used for arthrographies. Bacteria have not been found.

Patients with broad communication between the joint cavity and bursa are best situated in such cases, as the rich number of fibrinoid pappus being formed in the cavity will easily be emptied. If the rupture is slight the opening is easily stopped by the fibrins, and greater pains are brought about by the accumulation.

Material operated on: After starting the planing according to the author's principle, 10 are planed and 7 are suturated. Among the 10 planed ones 4 were women and 6 men from 41 to 70 years of age. Approximate age 57 years.

1 was smith, 1 fireman, 1 carpenter, 3 farmers and 2 wives of farmers.

The nature of the trauma: Fall with direct push against the

shoulder in 5 cases. Fall on slightly abducted arm in 3 cases. Fall with unfortunate distortion of the arm in one. No anamnestical indicably obvious traumas in one.

The time elapsed from the presupposed trauma to the arrival at the hospital varied from 6 weeks to 1 month. For many of them, however, one must suppose that the rupture was older, on account of the great changes, and that the accidental trauma which the pat. remembers, only has aggravated the condition.

The pains in the shoulder, the reduced strength of the arm besides the limited mobility of the shoulder joint may be embodied in the idea: The working powers of the arm. It was quite unfitted for work in 6 cases. Partially employable in 4 cases.

Secondary rigidity of the shoulder had occurred in 3.

The size of the rupture: Supraspinatus in 3. Supra and infraspinatus in 4. Subscapularis in 1. Subscapularis, supraspinatus and partial infraspinatus in 2.

The time staying in bed at the hospital varied between 1—4 weeks, approximately 16 days.

Of complications one pat. got an articular fistula which closed after 3 weeks. On control he was working full time as a farmer, having free mobility in the shoulder joint and no pains.

When being examined for control from $^1/_2$—2 years after the operation, 9 had been working full time from 2—4 weeks after having left the hospital. One after 2 months.

The movements in the shoulder joint were quite normal in 7. 2 were able to abduct the arm 170 degrees. 1 abducted the arm 180 degrees, but still had some difficulties in putting it behind the back not being able to place the hand farther than just above the band of the trousers.

8 were completely without pains, 2 having slight pains.

The strength in the arm especially for abduction was normal and just like the other side in 5. Inconsiderably reduced in 3, and to some extent reduced but still rather good in 2.

The group of suturated ruptures of the aponeurosis consisting of 7, concerned only men.

The age varied from 48 to 70 years, approximately 60 years. 4 were farmers and 3 fishermen.

Regarding the nature of the trauma in 3 cases a fall directly on the shoulder was observed. In 3 cases a fall on slightly abducted arm. In 1 case hanging with the arm, he himself being caught up by the collar of a horse which had bolted.

The time elapsed from the damage to arrival at the hospital varied from 1 week to 2 months.

2 demonstrated ruptures of supraspinatus, 4 of supra- and infraspinatus and 1 of supra- and infraspinatus and partial subscapularis.

The mobility in the arm damaged considered according to the ability of abduction was on arrival at hospital from nought to 60 degrees.

On control from $^1/_2$ to 2 years after the operation, 5 had completely free mobility, 2 abducted to 170 degrees actively, otherwise the movements were quite free.

The time spent in bed at the hospital varied from 5 to 10 weeks, approximately 7 weeks. As to complications here as well an articular fistula occurred which closed after 4 weeks and on control he was in full-time work as a farmer, having free mobility without pains.

On control they had begun their usual work 2—5 months after the operation, approximately 3 months. 6 had no pains at all. 2 had inconsiderable pains. With regard to the strength of the arm 5 abducted as vigorously as on the healthy side, 2 had slightly reduced strength when abducting. 3 had no muscular atrophy, 4 had rather slight atrophy of supra- and infraspinatus. By roentgen examination by arthrography communication between the joint cavity and bursa acromialis was found in 4. 1 was not examined, and 2 were quite tight.

Summary.

The author mentions a work consisting of 243 arthrographically examined patients after trauma of the shoulder, 76 of which with complete and 27 with incomplete ruptures of the aponeurosis. After a short description of the clinical picture of the rupture of the aponeurosis, 10 cases operated on according to the author's own method are especially accounted for and 7 with primary suture. Incomplete ruptures are conservatively treated. The purpose of the operation must be to relieve the pains, restart the movement in the shoulder joint and as far as possible regain the strength in the arm. As the cause of the pains, the weakness and the limitation of mobility, the rough areas arising because of the rupture are emphasized, in recent ruptures because of the tendinous lobes, in inveterate ones owing to the frayed bony edges in the collum

region and the prominent tubercles. In all the cases it is made a point of reestablishing the smooth sliding-plane on the upper surface of the aponeurosis which is characteristic of the normal joint. This is obtained by primary suture of recent ruptures with a good hold in the peripheral stump, besides chiselling and smoothing of all the frayed areas on tubercula and the suture itself. All the other recent and inveterate ruptures are planed, getting rid of the frayed areas. The prominent tubercles and all the other projections of the bony, tendinous, or cartilaginous nature are chiselled until the complete upper surface of the joint in this region constitutes a smooth plane all over which slips easily below the under surface of acromion. When planing, the pat. starts the moving exercises when he awakes from the narcosis. For the 10 planed ones the approximate time of hospitalization was 16 days. 9 were at full-time work with free mobility and without pains from 2—4 weeks after having left the hospital, 1 after 2 months. When the pains had disappeared the strength in the arms with all of them was considerably increased, and in 5 just like the other side. When suturating, passive moving exercises already a week after the operation are started. The 7 suturated ones had started their usual work approximately 3 months after the operation.

Zusammenfassung.

Verf. erwähnt eine Arbeit, die 243 nach einem Schultertrauma arthrographisch untersuchte Patienten umfasst, von denen 76 eine vollständige und 27 eine unvollständige Ruptur der Aponeurose aufwiesen. Nach einer kurzen Beschreibung des klinischen Bildes der Zerreissung der Aponeurose wird über 10 nach Verf:s eigener Methode operierte Fälle sowie 7 primär genähte Fälle besonders berichtet. Unvollständige Zerreissungen werden konservativ behandelt. Die Operation bezweckt Behebung der Schmerzen, Wiederherstellung der Beweglichkeit des Schultergelenkes und möglichst vollständige Wiedererlangung der Kraft des Armes. Als Ursachen der Schmerzen, der Schwäche und der Bewegungsbeschränkung werden die durch die Ruptur verursachten rauhen Flächen genannt, bei frischen Rupturen durch die schnigen Enden bedingt, bei veralteten durch die zackigen Knochenränder der Kollumregion und die vorspringenden Tuberkeln. In sämtlichen Fällen hat man es darauf angelegt, die das normale Gelenk auszeichnende, glatte Gleitfläche der oberen

Oberfläche der Aponeurose wiederherzustellen. Dies wird erreicht durch primäre Naht frischer Rupturen mit guter Befestigungsmöglichkeit am peripheren Stumpf sowie Modellierung und Glättung aller unebenen Flächen der Tuberkeln und der Naht selbst. Alle übrigen, frischen oder veralteten Rupturen werden geglättet, so dass die unebenen Flächen beseitigt werden. Die vorspringenden Tuberkeln und alle anderen Vorsprünge knochiger, sehniger oder knorpeliger Art werden modelliert, bis die obere Oberfläche des Gelenks in diesem Gebiet eine überall glatte Fläche darstellt, die unschwer unter die untere Oberfläche des Akromion hineingleitet. Bei Glättung beginnt der Kranke schon beim Erwachen aus der Narkose mit Bewegungsübungen. Bei den 10 geglätteten Fällen betrug der Krankenhausaufenthalt etwa 16 Tage. 9 Patienten waren 2—4 Wochen nach der Entlassung in voller Arbeit mit freier Beweglichkeit und ohne Schmerzen, 1 nach 2 Monaten. Nach Verschwinden der Schmerzen, besserte sich die Kraft des Armes in sämtlichen Fällen bedeutend und war bei 5 der des anderen Armes völlig gleich. Bei Vernähung werden passive Bewegungsübungen bereits eine Woche nach der Operation eingeleitet. Die 7 vernähten Fälle hatten etwa 3 Monate nach der Operation ihre Arbeit wiederaufgenommen.

Résumé.

L'auteur expose le résultat de recherches ayant consisté dans l'examen articulaire de 243 malades, après traumatisme de l'épaule dont 76 avec rupture complète et 27 avec rupture incomplète de l'aponévrose; 10 cas opérés suivant la méthode de l'auteur dont 7 avec suture primaire font l'objet d'un exposé spécial. Les ruptures incomplètes sont traitées par la méthode conservatrice. Le but de l'opération est de soulager la douleur, de rétablir la mobilité de l'articulation et de restaurer autant que possible la force du bras. L'auteur souligne l'importance des surfaces inégales conséquences de la rupture, dues, dans les ruptures fraîches, aux saillies des tendons, dans les ruptures anciennes aux arêtes osseuses éraflées dans la région du col et aux tubercules proéminents, comme causes des douleurs, de l'asthénie musculaire et de la limitation des mouvements. Dans tous ces cas, il est important de restaurer le plan lisse de glissement de la face supérieure de l'aponévrose qui est l'un des éléments de l'articulation normale. Ce résultat s'obtient par une suture primaire de ruptures récentes ayant

un solide appui dans le moignon périphérique, complétée par aplanissement et modelage de toutes les surfaces irrégulières et de la suture elle-même. Dans toutes les autres ruptures récentes ou anciennes, on aplanit les surfaces de façon à les débarasser de leurs aspérités. On égalise au ciseau les surfaces inégales, on supprime les tubercules proéminents et toutes autres inégalités osseuses, tendineuses ou cartilagineuses, de telle sorte que toute la surface extérieure de l'articulation constitue en toutes ses parties une surface égale qui s'engage facilement sous la face inférieure de l'acromion. Le malade commence à pratiquer des mouvements au réveil de la narcose de l'opération plastique. La durée du séjour à l'hôpital des 10 malades chez lesquels elle fut pratiquée a été de 16 jours environ. 9 avaient recouvré leur capacité totale de travail avec liberté des mouvements sans douleur de 2 à 4 semaines après avoir quitté l'hôpital, le dixième au bout de deux mois. Chez tous, la force du bras avait considérablement augmenté lors de la disparition des douleurs; chez 5 d'entre eux, elle était égale à celle de l'autre bras. Après suture on commence les mouvements une semaine après l'opération. Les 7 malades suturés ont repris leur travail habituel environ 3 mois après l'opération.

Bibliography.

CODMAN, E. A.: On the shoulder. Boston 1934. — LINDBLOM, K.:Acta Radiologica: 1939: 20: p. 548. — FROSTAD, H.: Acta Radiologica: 1942: 23: p. 336. — LINDBLOM, K.: Acta Chirurgica Scandinavica: 1943: 88: p. 182. — ULLMANN, W.: Acta Chirurgica Scandinavica: 1943: 88: p. 132. — WILSON, P. D.: The J. Am. Med. Ass. 1931: 96: p. 433. — ULLAND, G.: Nord. Med.: 1942: 15: p. 2479. — LINDBLOM, K., and PALMER, I.: Nord. Med. 1939: 1: p. 532. — OTNES, W : Nord. Med. 1940: 5: p. 247.

Bispebjerg Hospital, Copenhagen. Surgical Department A.
(Chief: JENS FOGED, M. D.)

Investigations of Postoperative Shock: Haemoconcentration, Plasma Protein and Blood Electrolytes after Gastrectomy.

By

K. H. KØSTER and DYRE TROLLE.

Our knowledge of the origin, development and treatment of shock has been aquired mainly from experiments and from experiences of war-surgery. It is, however, profitable to study the lessons of shock in civilian surgery because, although shock following the normal elective operation is less marked than that which is seen in the Field, it can be studied in closer detail than is possible under conditions of war.

After major abdominal operations the circulation is severely stressed. Although the demands on the circulation remain unaltered certain factors in the circulation are weakened, *e. g.* the blood-volume is reduced. The strain on the circulation is sometimes overcome so easily that it cannot, at any time, be observed clinically, but, not unfrequently, it exceeds the body's compensatory powers, and then the insufficiency of the circulation becomes the dominant feature in the clinical picture.

In patients who, in other respects enjoy a sound circulation, the post-operative alterations of the circulation are a result of a reduction of the blood-volume which arises from loss of blood during an operation, a loss of plasma to the tissues, and a high degree of dehydration. Besides this, the action on the sympathetic nervous system resulting from manipulation of viscera, and anesthetization of the splanchnic area, reduces the blood-pressure. As a result of the reduction of the blood-volume, the venous pressure tends to fall, the diastolic filling diminishes, the cardiac output lessens — and arterio-venous O_2 difference rises.

The filling of the heart with blood occurs rapidly at the com-

mencement of diastole, after which the pressure in the heart rises. With a low venous pressure, the right heart closes more rapidly than normally; the heart contracts — and the rate rises, at the same time as the stroke-volume diminishes.

For the purpose of ensuring the coronary system and the carotid area a sufficient amount of blood, the arteries and arterioles in the periphery become contracted, *i. e.* the blood-supply to non-vital areas is rationed.

In this process, a relative anoxemia develops in the capillaries peripheral to the contracted arterioles followed by a loss of plasma through the hyperpermeable capillaries injured by the anoxemia. In this way the venous return and the cardiac output are further reduced. In the vicious circle thus established, the blood-volume is so reduced that even the strictest rationing to the periphery does not suffice to maintain an adequate supply of blood to the vital centres. In consequence of the resulting anoxemia, the function of the vasomotor centre is disturbed, the arterioles will become dilated, the blood-pressure falls abruptly and shock, hitherto latent, becomes manifest.

The fate of the patient depends essentially on the body's ability to reestablish and maintain a normal blood-volume, with an adequate cardiac output, adequate circulation and supply of oxygen to the vital centres. We endeavour to assist the body by infusion of saline, blood, etc. It is not possible to recognize clinically an incipient reduction of the blood-volume — latent shock. As it is important to institute treatment in this early fase, it is essential to study the variations in the blood-volume during the post-operative period.

As frequent blood-volume determinations are impracticable, efforts have been made to discover other ways of determining the variations in blood-volume. Erythrocyte counts and determinations of plasma protein have been chosen for reasons which will be given later as guides to the variations in blood-volume and water-content of the body.

The relation between the post-operative condition of patients (who have undergone gastrectomy) and the variations in haemoconcentration (as assessed by the red cell count) and plasma protein content will be shown in the following pages. In addition, the bicarbonate- and the chloride-content of the blood have been determined, and an account has been given of the patients' total fluid-balance.

It is also necessary to consider the question of haemoconcentration in haemorrhage and shock, the influence of blood-transfusion on haemoconcentration, and the connection between plasma protein concentration and the supply of fluid; attention is also drawn to the so-called limits of edema.

During the last few years at Bispebjerg Hospital, a more active surgical treatment of gastric ulcer and carcinoma has been adopted. As the latter disease is inevitably fatal radical operation is now performed if it is technically possible, even if the case is so advanced that there is only a minimal chance of success. (Note: 37 % have palpable tumours on admission (FOGED & LARSEN).)

Plasma (for the treatment of shock) was not available while this investigation was carried out.

Clinical Material:

This includes all patients — 63 — at Bispebjerg Hospital, Department A, during the period January 1940—July 1943, on whom gastrectomy for ulcer or cancer ventriculi has been carried out. According to disease, age and mortality, they are classified as follows:

Disease	Total patients	Average age	Youngest patient	Oldest patient
Gastric Ulcer	26			
of whom:				
survived	24	39	26	58
died	2	—	54	73
Carcinoma	37			
of whom:				
survived	17	53	23	65
died	20	57	45	72

Excepted from the following accounts are 2 patients: one with gastric ulcer (1999/42) who was insufficiently examined preoperatively (the patient lives), and one with carcinoma (2222/42) who died so quickly after the operation that it was impossible to investigate any of the circumstances dealt with here.

The operation was carried out according to BILLROTH II in all cases except 4. Of these 4 cases total gastrectomy was performed in two; resection ad modum POLYA in two.

Anesthesia: Preoperatively was given 1 ml Scophedal subcutaneously (Scopol. hydrobrom. 0.5 mg, Euchodal 1 cg, Ephetonin, 2.5 cg). The main-anesthesia was splanchnic-anesthesia, obtained with 60—80 ml $^1/_2$ % novocain, supplemented by local novocain-

anesthesia of the abdominal wall and, as a rule, nitrogen-dioxide + oxygen + ether-narcosis during the closure of the wound.

Pre-operative investigations. Before the operation, an erythrocyte count was made and the plasma protein-, chloride- and bicarbonate-concentration and fluid balance were estimated.

These components were, as far as possible, restored to normal values with blood-transfusion, saline, bicarbonate and glucose-solutions, etc.

The day before operation there were made renewed investigations of the blood, and the results were used for comparison with the post-operative values.

Methods of investigation.

Haemoconcentration was determined by counting the erythrocytes. The number of erythrocytes was preferred to the measurement of their volume on account of following:

With alterations in concentration of protein and crystalloids to which the erythrocyte membrane is entirely or partially permeable, changes of osmotic pressure influence the size of the erythrocytes. An increase in the carbondioxide-content of the blood, for instance, brings about an increase in osmotically active ions in the erythrocytes, the HCO_3^- taking the available base, K^+ from the haemoglobin which behaves as a polyvalent ion to which are bound many atoms of base. The combination is dissociated entirely into HCO_3^- and K^+. Bases are certainly released from the plasma protein, but to a slighter extent than in the cells. Consequently, the intracellular osmotic pressure rises with increasing CO_2-content in the blood, and this results in increased cell-volume.[4]

This explains the conflicting results of simultaneous erythrocyte-, haemoglobin- and haematocrit determinations; in a work by ACKMAN and others[2] on the treatment of burns, we find in one place an haematocrit increase of 31 % while the haemoglobin falls 12 %. Elsewhere, the haematocrit shows a lower figure, while the haemoglobin rises. Similar differences are to be found in works by LINDGREN & WILANDER[25], FINE, FUCHS & MARK[15], PRESMAN[29], and others.

The *plasma protein* was estimated by BING's[6] method. The specific weight of the plasma is only an approximate indication of what we want to know, namely, the plasma's colloid-osmotic pressure (of which more will be said in a later sec-

tion), but we have not, at present, any practicable methods for determining the albumin-globulin ratio.

Chloride- and *bicarbonate* determinations were executed according to VAN SLYKE.[31]

Pre-operative Investigations:

In the following tables, certain abbreviations are used: l. ulc. = ulcer patients discharged from the hospital; d. ulc. = ulcer patients who died in the hospital after gastrectomy; l. c. and d. c. = similar classes of cases of carcinoma.

Total patients in the report:

l. ulc.	23
d. ulc.	2
l. c.	17
d. c.	19

Erythrocyte counts:

	average	max.	min.	Standard error
l. ulc.	5.00 mill.	6.64 mill.	3.82 mill.	± 0.31 mill.
d. ulc.	4.00 »	4.32 »	3.68 »	—
l. c.	4.80 »	5.91 »	3.90 »	± 0.42 »
d. c.	4.53 »	6.67 »	3.00 »	± 0.51 »

Plasma-protein concentration:

	average	max.	min.	Standard error
l. ulc.	6.3 %	7.7 %	5.4 %	± 0.4 %
d. ulc.	5.8 %	5.8 %	5.7 %	—
l. c.	5.8 %	6.6 %	5.1 %	± 0.4 %
d. c.	5.6 %	6.6 %	4.3 %	± 0.7 %

Plasma-chloride concentration:

	average	max.	min.
l. ulc.	98 mMol/l	106 mMol/l	87 mMol/l
d. ulc.	91 »	92 »	89 »
l. c.	97 »	111 »	80 »
d. c.	93 »	103 »	77 »

Plasma-bicarbonate concentration:

	average	max.	min.
l. ulc.	29 mMol/l	33 mMol/l	23 mMol/l
d. ulc.	28 »	31 »	25 »
l. c.	27 »	39 »	22 »
d. c.	25 »	33 »	20 »

Of the many other preoperative investigations which were made, only the following are given.

Urea-concentration:

	average	max.
l. ulc.	24 mg %	36 mg %
d. ulc.	39 »	42 »
l. c.	25 »	36 »
d. c.	29 »	51 »

The tables show a tendency towards lower values in the patients who died after operation; on an average, they have the lowest erythrocyte- and plasma protein values, the lowest bicarbonate- and chloride figures, and the highest urea values, all of which points to these patients being in a poorer condition than those who survived.

A statistic valuation reveals, however, that the difference is not significant.

A few patients have had very low erythrocyte- and plasma protein values before the operation. It was impossible to bring these patients into the desired state of equilibrium, because of constant bleeding from their gastric lesion.

Post-operative treatment:

Before operation a duodenal tube was introduced — through the nose — into the stomach. During closure of the gastro-entero-anastomosis, the tube was placed in the efferent jejunal coil (c. 30 cm), as shown by STENGEL & RAVDIN[32]. In these cases, however, only single barelled tubes were employed.

Blood-transfusion:

Blood-transfusion was widely used. Frequently it was carried out during the operation or immediately after. Numerous patients had transfusion later on, during the postoperative period.

A more detailed account of the effect of the transfusions on haemoconcentration is given below.

With gross haemoconcentration, $^1/_2$—1 litre of gum-saline was often given together with, or instead of, transfusion; the results were good, except for a few cases which developed a temporary pyrexia.

Medical treatment:

For the first 4—8 days after the operation vasopressin (insipidin (AB) 20 IE (1 ml)) was administered subcutaneously every third hour, thereby escaping the simple post-operative paralytic ileus[22]. In spite of large doses, no disturbances of urinary volume or

chloride output was observed[28]. Most patients passed flatus after intestinal lavage from the first day onwards.

During the first few days, care was taken to provide a specially rich supply of B- and C-vitamins.

In the gastrectomies carried out during 1943, sulphathiazol powder was introduced into the peritoneum on closing the wound. In addition, 5 grammes of sulphathiazol were administered daily to most of the patients, either through the tube or parenterally.

No use was made of the routine "stimulation" with drugs of the sympathomimetic amine group; neither have digitalis nor strophanthin been given when they were not indicated by a well-defined heart affection. With threatening or manifest pulmonary edema a 50 % solution of glucose was given intravenously or intrasternally.

Fluid intake.

Fluid intake was adjusted according to the position of the fluid balance. 100 ml of glucose saline an hour, *i. e.* 2,400 ml daily, was introduced by the tube. An attempt was made to retain the tube for 8 days, but it was frequently necessary to remove it earlier, because of discomfort to the patients, or because it had slipped back during vomiting. When this was the case, the fluid was given orally, in the ordinary way.

Where it was impossible to give sufficient fluid by the alimentary tract, supplementary infusions were administered subcutaneously or intravenously or, when necessary, permanently into a vein of the foot, at a rate of, as a rule, 30 drops per minute, *i. e.* 100 ml per hour.

A summary of the fluid balance in the different groups of patients is given below.

Insensible perspiration was estimated at 1,000 ml daily[12, 19]. No account was taken of the water produced on *combustion*, amounting to about 300 ml daily.

Operation day:		2	3	4	5	6
l. ulc.	+ 1,500 ml	+ 700	+ 500	+ 400	+ 300	0
l. c.	+ 1,400 ml	+ 1,000	+ 600	— 200	+ 150	— 750
d. c.	+ 1,700 ml	+ 950	+ 850	+ 400	+ 150	(— 1,000)

The three groups of patients have approximately the same (average) fluid balance; not much value can be attached to the figure for the 6th day for the cancer patients who died, this group consisting of only 3 patients one of whom had a loss of fluid up to 8 litres daily.

The diminishing fluid balance, during the course of the postoperative period, is attributed chiefly to the increasing diuresis; moreover, with a number of patients (just those who lost fluid on vomiting), it was necessary to remove the tube before the end of the 8 days. In these cases, it was necessary to administer the greater part of the fluid parenterally, which sometimes caused difficulties, especially those patients with low plasma protein.

Postoperative blood investigation.

Erythrocyte count was made once, at 17.00 hours, on the operation-day (as a rule, the operation was concluded by 11.00 hours), and afterwards at 08.00 hours and 17.00 hours on the following days. This is the fixed plan for these investigations, but otherwise the erythrocyte counts were made at any time it was thought that a count would assist in the assessment of the patient's condition.[23, 26]

The results of these counts are shown in Figs. 1—4.

The curves show the percentage values of haemoconcentration as compared with the figures immediately before operation.

The curves for the surviving ulcer and cancer patients start sometimes with a rise, sometimes with a fall, but in one or two days all the curves fall, especially in the ulcer cases, where all are below the 100 % level. The observed rise is moderate, only in one case does it rise above 125 %.

The haemoconcentration curves in the fatal ulcer and cancer cases all show a rise, most of them exceeding the 125 % level.

(Two patients who died of intraperitoneal hemorrhage and two of pulmonary embolism are not included. The first two (who died on the second and fifth day after the operation), first showed a great fall in haemoconcentration, values resp. 70 % and 49 % of the last preoperative value, but shortly before death a rise, to resp. 80 % and 70 %. The last two patients who died of pulmonary embolism the second day after operation, showed on the operation day a fall to 90 % and 95 % of the last preoperative value resp., and on the day the embolism made its appearance a rise to 110 % and 128 % resp.)

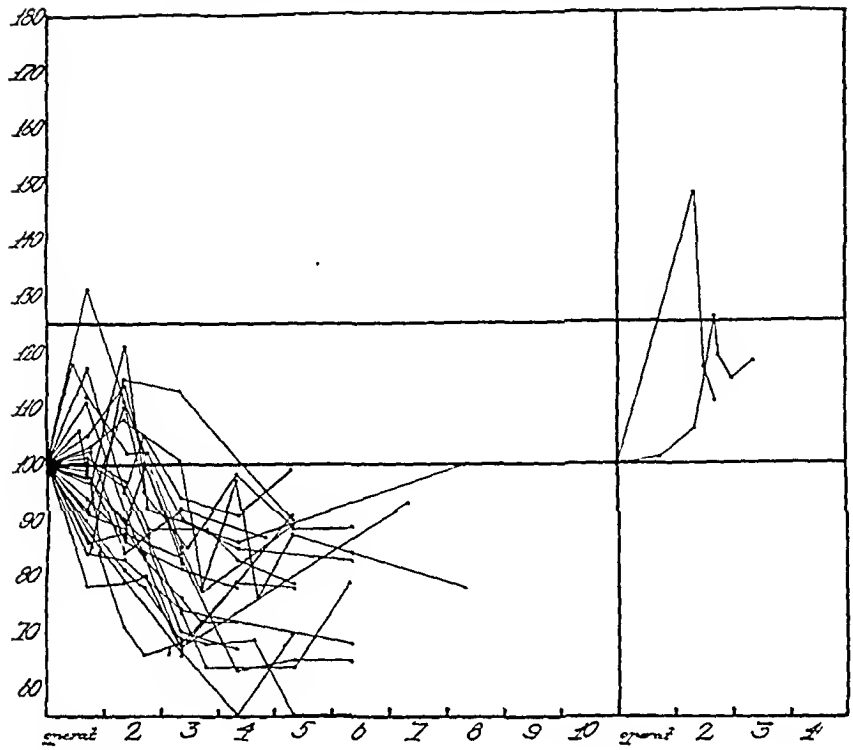

Fig. 1.

Fig. 2.

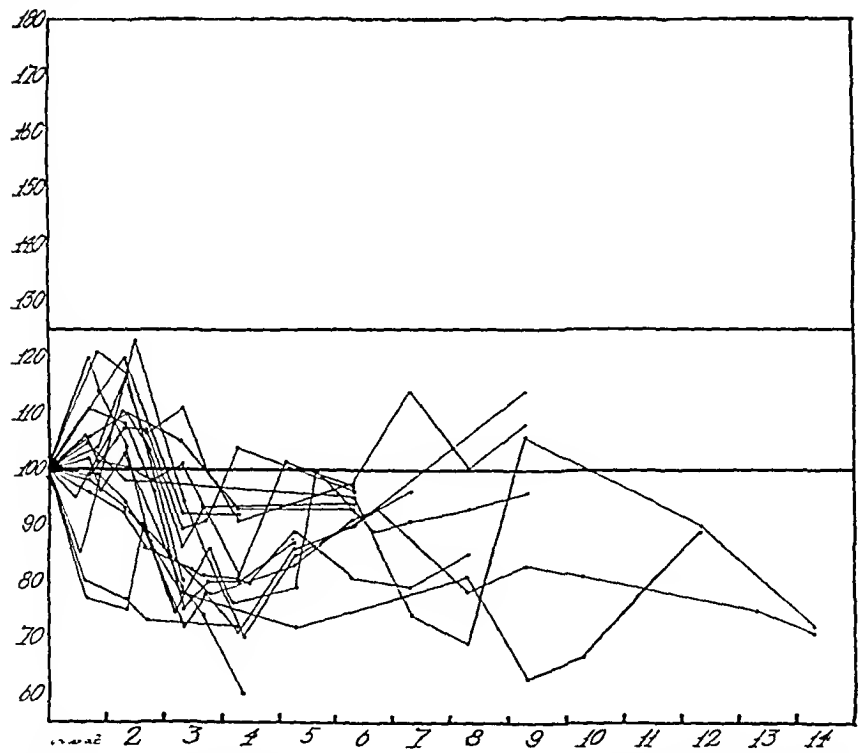

Fig. 3.

Ordinate: haemoconcentration in percentage of the last pre-operative figure.
Abscissa: post-operative day.

Fig. 1: haemoconcentration-curves in surviving ulcer cases.
Fig. 2: haemoconcentration-curves in fatal ulcer cases.
Fig. 3: haemoconcentration-curves in surviving cancer cases.

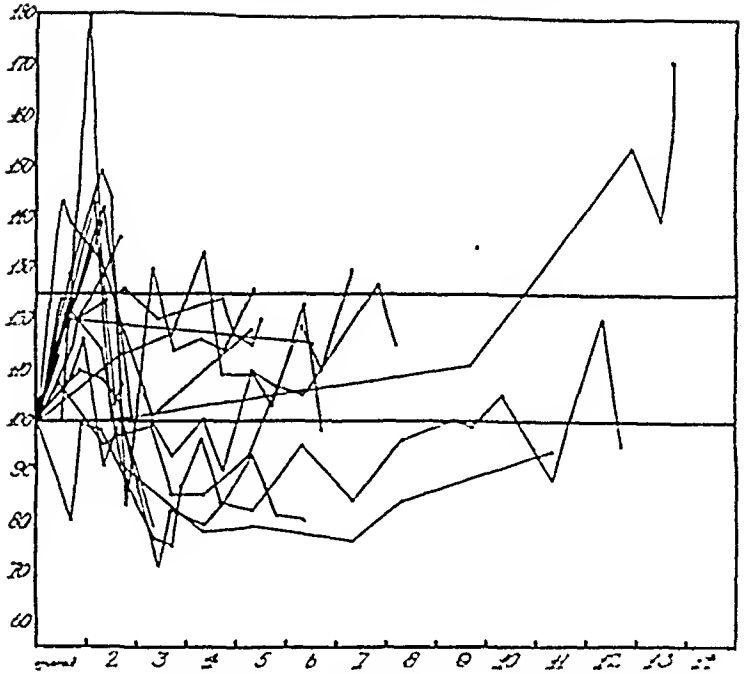

Fig. 4.

Ordinate: haemoconcentration in percentage of the last pre-operative figure. Abscissa: post-operative day.

Fig. 4: haemoconcentration-curves in fatal cancer cases.

Plasma protein estimation:

This, as a rule, is carried out on the second day after the operation, and on succeeding days, at varying intervals. The curves show the percentage value of the plasma protein-concentration as compared with the pre-operative value last measured (Figs. 5—7). The curves of the surviving ulcer and cancer patients show a uniform tendency to fall. After the fifth day there is a tendency to rise, but it is only in rare instances that the concentration reaches the 100 % level. On the other hand, the trend of the curves for the fatal cases is not uniform; most of them rise, but others display a considerable fall.

(The four patients, previously mentioned, with intraperitoneal hemorrhage and pulmonary embolism, are not included here. Both the patients with hemorrhage showed a fall, one to 87, the other to 89 % of the pre-operative value. In the last-mentioned case, there was a rise, shortly before death, up to 99 %.)

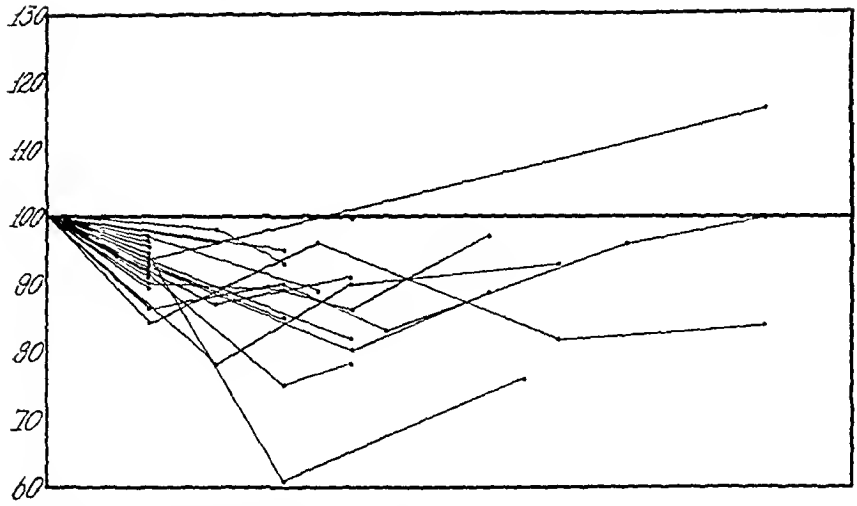

Fig. 5.

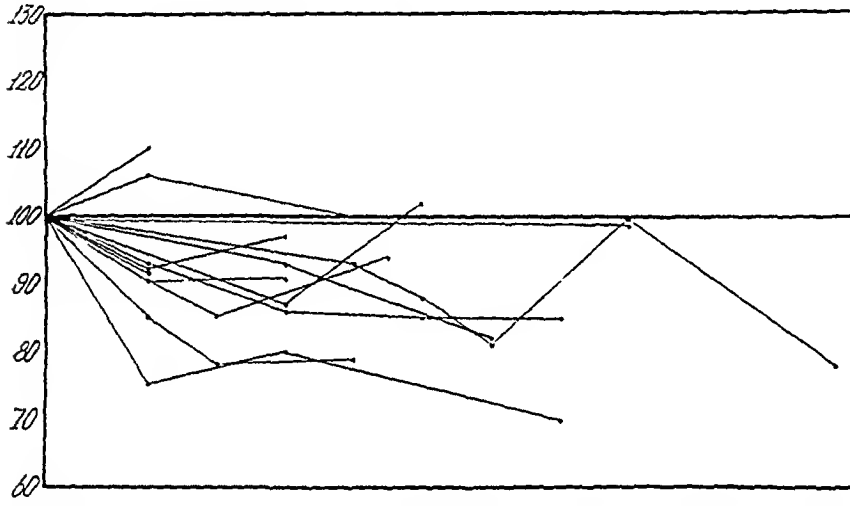

Fig. 6.

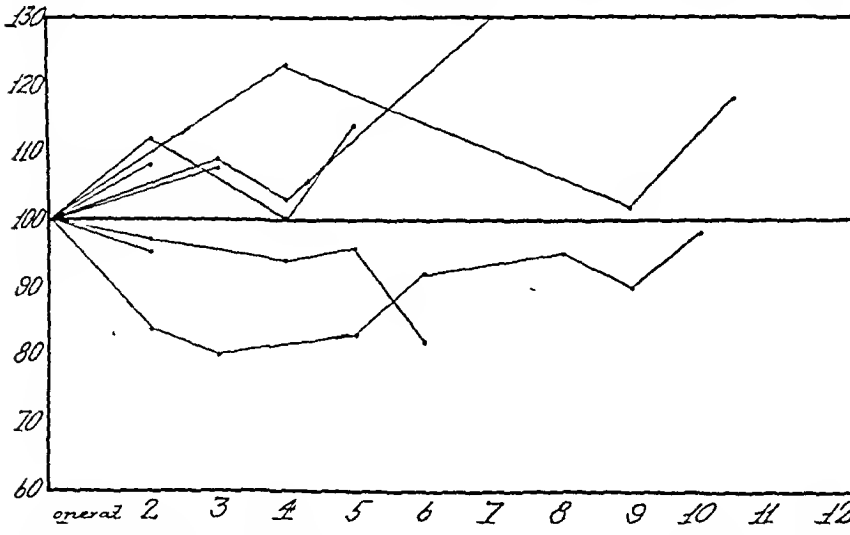

Fig. 7.

Ordinate: Plasma protein concentration in percentage of the last pre-operative figure. Abscissa: post-operative day.

Fig. 5: protein concentration-curves in surviving ulcer cases.
Fig. 6: protein concentration-curves in surviving cancer cases.
Fig. 7: protein concentration-curves in fatal cancer cases.

Fig. 8.

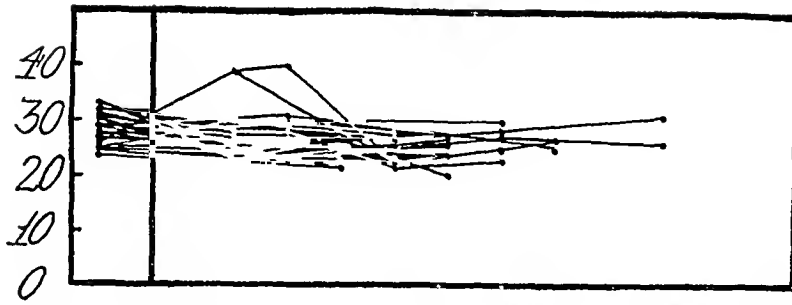

Fig. 9.

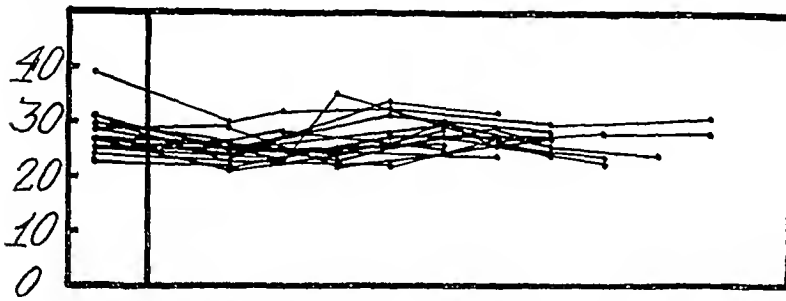

Fig. 10.

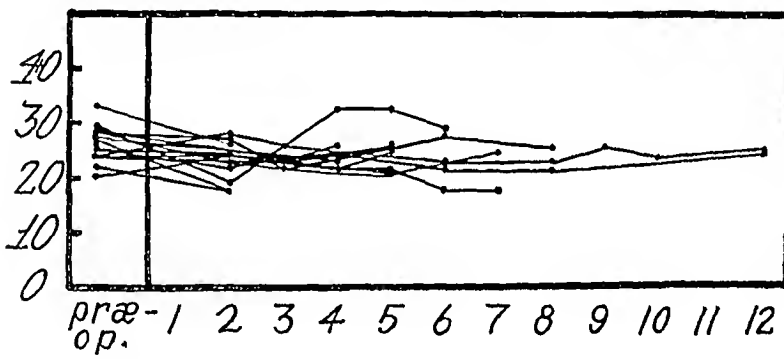

Ordinate: mMol/l bicarbonate in plasma.
Abscissa: post-operative day.

Fig. 8: bicarbonate concentration-curves in surviving ulcer cases.

Fig. 9: bicarbonate concentration-curves in surviving cancer cases.

Fig. 10: bicarbonate concentration-curves in fatal cancer cases.

Determinations of plasma bicarbonate (Figs. 8—10) are made on the second postoperative day, and afterwards at varying intervals. The results display only a very slight dispersion — among the fatal cases there are three who come down to 18 mMol/l.

One result of 40 mMol/l in one patient, healthy in all other respects, cannot be explained.

Determinations of plasma chloride (Figs. 11—13), were carried out simultaneously with the bicarbonate-determinations. The dis-



Fig. 11.

Fig. 12.

Fig. 13.

Ordinate: mMol/l chloride in plasma.
Abscissa: post-operative day.

Fig. 11: chloride concentration-curves in surviving ulcer cases.

Fig. 12: chloride concentration-curves in surviving cancer cases.

Fig. 13: chloride concentration-curves in fatal cancer cases.

persion for the surviving patients is just within physiological limits; among the fatal cases, chloropenia is seldom found, but striking rises, on the other hand, sometimes occur.

Discussion.

Haemoconcentration as a guide to changes in blood volume.

Acute alterations in haemoconcentration are found in *haemorrhage* — where the dilution of the blood is an indication of the body's attempt to maintain a normal blood-volume; in *shock* — where the concentration signifies that plasma is lost from the blood, and

also in *dehydration* — where the blood volume is reduced by the drainage of the extra-cellular reservoirs of "available water".

Haemorrhage.

Here the compensatory mechanism consists of two factors, one, a reduction of the vascular bed's capacity by vasoconstriction, and the other a replacement of the lost blood by means of the inflow of fluid from tissues to the vascular system.

The vascular capacity must necessarily correspond to the blood-volume; when the latter is reduced (through a reflex probably over the pressor-sensitive zones) — a contraction of arteries, arterioles and, probably, mesenterial veins starts, the supply of blood to the vital centres is maintained, but a relative anoxemia may develop in the capillaries peripheral of the vascular contraction. If the blood-volume is restored quickly, the effects of the capillary anoxaemia will be reversible[21], but if the hemorrhage is severe and the restoration slow, the anoxemia increases the permeability of the capillaries so that the protein molecules + water leave the circulation, and the result is a further reduction of the blood-volume, and thus the vicious circle of shock is instituted.

The restoration of blood-volume commences soon after haemorrhage and takes place very rapidly; in as little as three hours after a loss amounting to 15—20 % of the blood the blood-volume is restored[14] — that is to say, the plasma-volume is greater than before the haemorrhage, and corresponds to the reduced cell-volume. Only a few hours after haemorrhage a fall in the erythrocyte count, and in the plasma protein values may be observed — provided that sufficient fluid is available.

The inflow of fluid is promoted when the capillary pressure is low, and ceases when a new equilibrium of hydrostatic and osmotic forces has been established.

Shock.

In shock without haemorrhage — in trauma, burns, handling of viscera, etc., — we find a reduction of blood-volume brought about by a loss of plasma through capillaries made permeable to protein; and which becomes apparent by increasing haemoconcentration.[26]

It is important to realise how great the plasma loss is. BLACK[7], for instance, found a reduction of plasma-volume of 2,100 ml

in a case of burns affecting 12 % of the body surface. In burns extensive edema of the liver, kidneys and lungs is found.[2] In abdominal operations, the loss probably occurs in the operation-field and in the whole of the affected peritoneal area. In a later stage the involvment of capillaries becomes generalized. It is found that dyes bound to the proteins of the plasma disappear from the vascular system in organs which are not affected by trauma.[17]

Dehydration.

Plasma constantly supplies fluid to secretions and insensible perspiration, and receives fluid from the intestinal canal and from the extra-cellular "available water" which, in an adult man, amounts to 15—20 litres.

No investigation has been made of the amount by which this reservoir of fluid is reduced before a noticeable diminution of the plasma-volume and increased haemoconcentration occur. The evidence suggests that the amount is large, as indicated in the following case.

A patient following gastrectomy had negative fluid balance each day, but haemoconcentration remained constant until the deficit of fluid amounted to about 10 litres. Violent haemoconcentration and shock was followed by death.

In another patient, one of us (K. H. K.) has found that the extracellular available water was reduced to 60 %, without any reduction of the plasma-volume.

Consequently, it is understandable that, in an acute, "extreme" dehydration a diminution of the plasma-volume[18] amounting to only 8—9 % may be found; whereas in long-continued dehydration there may be found a reduction of the plasma-volume which, percentually, is greater than the diminution of the extracellular volume of fluid (naturally the latter is greater when measured in litres)[20].

Further, it is obviously impossible to calculate the degree of fluid deficiency from the haemoconcentration.

In a lengthy operation such as gastrectomy, where there is much bleeding and much handling of viscera, two rival processes are initiated. First, following blood loss fluid moves from the tissues into the vessels diminishing the haemoconcentration. Secondly, loss of plasma in the operation-field occurs and, eventually, in peripheral areas.

During the first hours after operation, either process may

predominate; the natural course cannot be followed as every effort is made to re-establish and maintain the blood-volume by means of infusions of blood and saline.

Investigations of haemoconcentration after gastrectomy.

The haemoconcentration-curves for the surviving and for the fatal cases present greatly differing pictures.

The curves of the surviving patients are characterized by a tendency to fall (Figs. 1 and 3). All these patients can — with a certain external assistance — draw fluid from the tissue into the circulation. On every occasion, this process exceeds the loss of plasma from the capillaries. (Only on one occasion did a value exceed 125 %. This patient was a man 32 years old with gastric ulcer, in good general condition. At 17.00 hours, on the operation day, a haemoconcentration was found of 6.85 million erythrocytes, or 132 % of the last preoperative figure, together with an evidently approaching shock. After blood transfusion he regained full health.)

One might expect that the fall in haemoconcentration would take place quickly[10,14], as the acute loss of blood is fully compensated within a few hours of the hemorrhage. This does happen in some cases, and most plainly in those who are considered as belonging to the best group — those who do not receive blood-transfusion after the operation (Fig. 14). But, in other patients, the loss of plasma occasionally exceeds the flow of fluid into the vessels, so that haemoconcentration oscillates during the first and second day until the diminution of plasma ceases and the blood volume is finally re-established. Frequently a large amount of fluid is brought into the vessels, so that the haemoconcentration in some cases falls to 55 % of the preoperative value (Fig. 1).

The curves of the fatal cancer and ulcer cases lie preponderately above the 100 % level, most of them displaying rises exceeding 125 % of the preoperative value. This implies that the plasma volume of these patients has fallen by at least 20 % (Figs. 2 and 4). Gradually, when the importance of haemoconcentration became clear, defensive measures were introduced against the reduction of blood-volume. First and foremost blood-transfusion, and — as will be seen by the curves — the attempt to reduce the haemoconcentration was successful, the figures falling in many instances below the 100 % level — but still, these patients died. It is probable that, when the haemoconcentration reaches 125 %

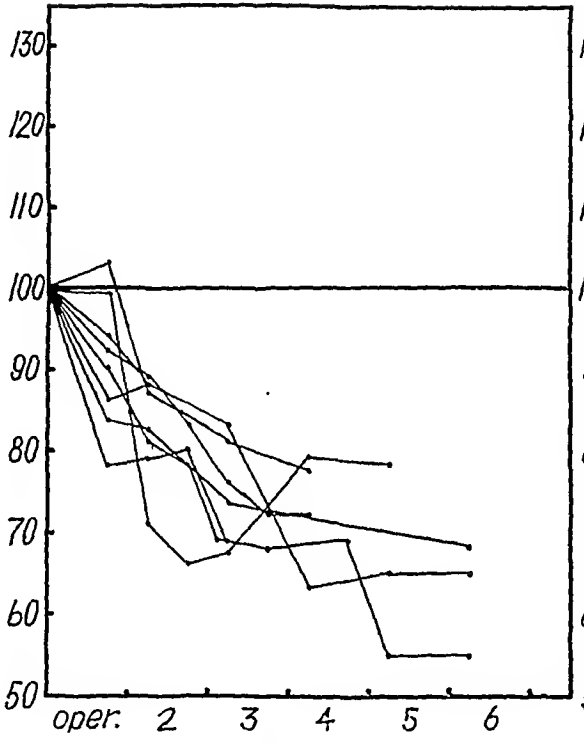

Fig. 14.

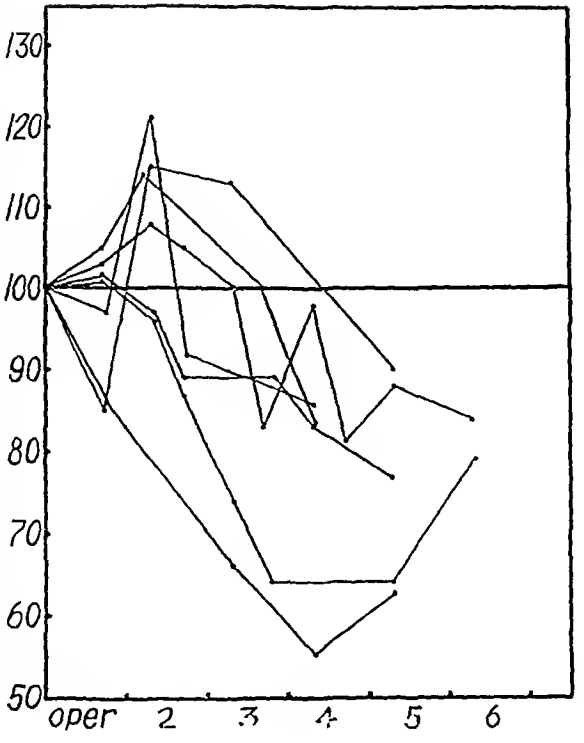

Fig. 15.

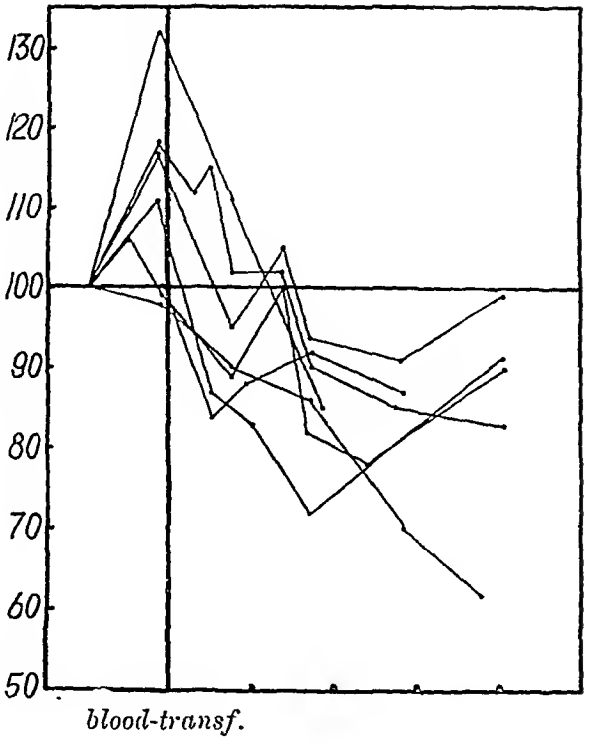

Fig. 16.

Effect of blood transfusion in surviving ulcer patients.
Ordinate: haemoconcentration in percentage of the pre-operative value.
Abscissa: post-operative day for Figs. 14 and 15; day after blood-transf. for Fig. 16.

Fig. 14: haemoconcentration curves for patients who were not transfused.

Fig. 15: haemoconcentration curves for patients who were given "prophylactic" transfusion.

Fig. 16: haemoconcentration curves for patients given therapeutic transfusion.

of the preoperative value, the reduction of the blood-volume is so great that the circulation is inefficient, and irreparable damage is caused *inter alia* of the central nervous system that proves to be irreparable.

Not infrequently patients, whose haemoconcentration has been brought down again to normal values and whose protein- and electrolyte levels are normal, present somatic and psychic alterations which persist until death; the patients present nystagmus, tremor, clonus, dysphagia and derangement and confusion of mind and, sometimes, hallucinations, all of which indicate severe damage to the brain.

The influence of blood-transfusion on haemoconcentration.

In this material the ulcer patients who did not receive transfusion display a constant and gross fall of haemoconcentration — in contrast with the ulcer patients who have been transfused during, or immediately after, operation, almost all of whom display increasing haemoconcentration for the first day or two.

In considering the influence of blood-transfusion on haemoconcentration the surviving ulcer ventriculi patients were divided in three groups. The first group embraces those patients who have not been transfused. These patients display a constant and great fall of haemoconcentration (Fig. 14) (which shows that the decision to withhold transfusion was correct).

The second group embraces all patients who received blood-transfusion during or immediately after operation (prophylactic transfusion). Almost all display rising haemoconcentration for one or two days (Fig. 15). To decide whether this rise was caused by the transfusion or by developing shock, curves were drawn for the third group of patients in whom blood-transfusion was given later in the postoperative period, indication for transfusion being rising haemoconcentration (therapeutic transfusion) (Fig. 16). For the sake of clarity the curves have been synchronized at the time of transfusion. It is seen that a fall in haemoconcentration follows transfusion, in each case; thus it seems improbable that the rise in haemoconcentration in group two is caused by transfusion. It must therefore be assumed that the rise was caused by developing shock. The transfusion during operation did not in these cases prevent the increasing haemoconcentration (though in all cases the rise is below 25 %), but it was sufficient to prevent the further development of shock.

Plasma protein estimation.

As already mentioned a transmission of fluid from the tissues to the blood occurs immediately after a haemorrhage; as the tissue-fluid contains no more than about 0.3 % protein, the plasma protein-concentration sinks during this process.

In experimental shock — manipulation of the intestines after laparotomy — it has been found that the plasma protein-concentration remains almost constant[23], and after shock following trauma, the fluid accumulated in the tissues has almost the same composition as plasma.[5]

However, it is likely that varying degrees of injury to the capillaries occur, in different areas and at different times. With less serious injury to capillaries, the smaller albumin-molecules are lost first; with increasing permeability, the larger globulin-molecules are lost.[4]

In burns, PRESMAN and others[29] have found that, in the blisters, there is a relative increase of albumin so that the albumin-globulin-quotient is 12—79 % higher than in the patient's blood, where the quotient is lower than the normal.

Clinically the determination of total protein in plasma is carried out by determining the specific weight (BING[6], LINDERSTRÖM-LANG[21], BARBOUR & HAMILTON[3]) but this is not an exact reflection of the effective colloid-osmotic pressure of the plasma.

It is not known[26] how great the displacements of albumin-globulin are that can occur during hemorrhage and shock; in kidney disease, VAN SLYKE[31] has found a diminution of the quotient down to 0.86, which signifies a reduction of the osmotic pressure by about 20 %.

When protein passes through the capillary wall, the osmotic pressure of the intercellular fluid rises, so that the pressure-difference between blood and tissue diminishes. This signifies that, with a constant total protein-content a diminished effective colloid-osmotic pressure in the plasma may be found.

Plasma protein and fluid intake.

If we compare the plasmaprotein curves of the fatal cases with the erythrocyte curves (Figs. 17 and 18), we find throughout that the patients with rising plasma protein also have rising red cell concentration, and vice versa. It might seem the rise were due to dehydration.

In a few cases, where fluid loss exceeded intake, dehydration arose, but a deficit balance of 8—10 litres is necessary before increased haemoconcentration becomes noticeable; that is to say, the greater part of the extra vascular reserves must have been consumed. In the great majority this point is not reached, and, on the whole, the fluid-balance for the group of fatal cancer cases is almost the same as that for surviving patients (see p. 8).

This fact is not affected by the uncertainty about the magnitude of insensible perspiration; according to DILL[12] and GREGERSEN[19] it amounts to 1,000 ml.

Insensible perspiration varies very little; on the other hand, sweat-secretion is a uncalculable factor which compromises the fluid-balance calculations. This latter secretion seems to be about 1,500 ml during the first post-operative day.

In this connection the problem of *Pulmonary edema* should be mentioned. This was found at autopsi of 11 of the patients who had undergone gastrectomy. In only two of these was the plasma protein concentration found to be less than 5.5 %, both of these were patients with severe intraperitoneal haemorrhage, whose blood-volume was certainly diminished.

Only one patient displayed a positive fluid balance, but he had 5.7 % plasma protein and a haemoconcentration above 125 %. Five others showed erythrocyte concentration exceeding 125 %.

It is an established fact that a patient can be waterlogged by infusion of crystalloids, and this has probably occurred in some cases; the above figures show, however, that one cannot rely on the so-called edema-limit, and that pulmonary edema, in patients suffering from shock arises essentially as a result of increased capillary permeability and not simply from discrepancy between the hydrostatic-colloid-osmotic pressures. A striking example of this was a man who had a gross negative fluid balance amounting in the course of 6 days to about 12 litres. The man died with symptoms of pulmonary edema.

The axiomatic edema-limit — a plasma protein concentration of 5.5 % — should be applied with discrimination. First, determination of plasma protein by its specific weight — and without a knowledge of the albumin-globulin ratio — is not an exact reflection of the plasma's colloid-osmotic pressure. In the second place, the effective pressure of the plasma depends on the amount of protein in the tissue fluid. — Furthermore the re-

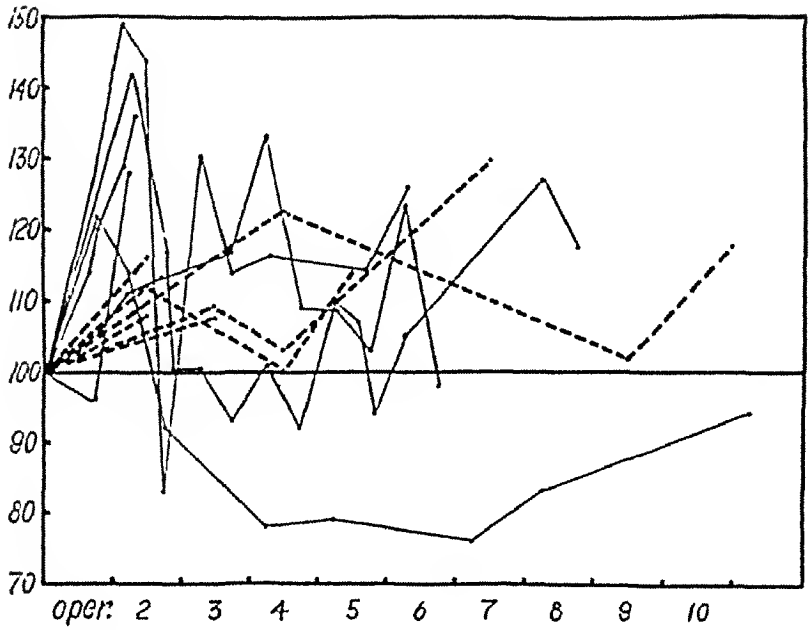

Fig. 17.

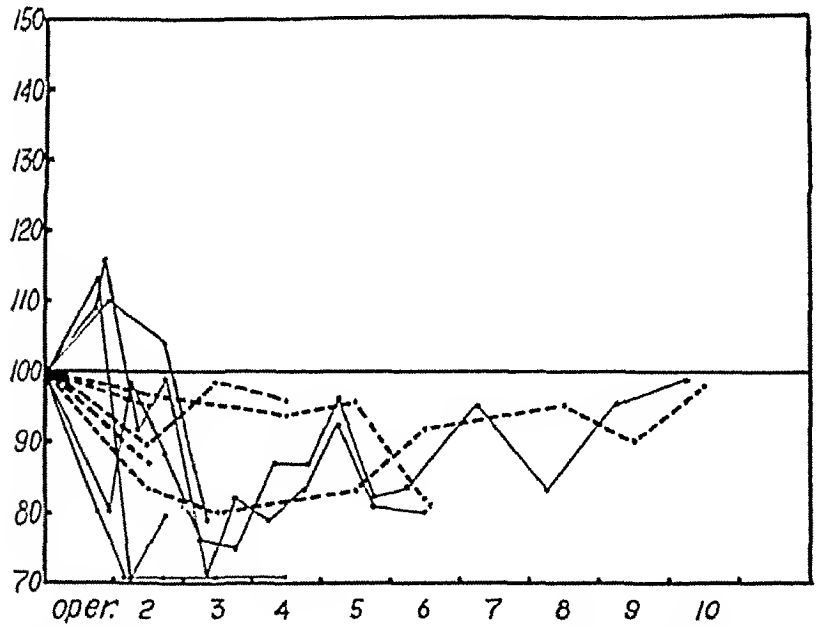

Fig. 18.

Ordinate: concentration in percentage of the last pre-operative value.
Abscissa: post-operative day.
Dotted lines: plasma protein concentration.
Whole-drawn lines: haemoconcentration (erythrocyte count).

Fig. 17: fatal cancer cases with rising plasma protein.

Fig. 18: fatal cancer cases with falling plasma protein.

tention of plasma in the vascular system changes with the permeability of capillaries.

Investigations of plasma protein after gastrectomy.

The changes in protein concentration correspond in many ways to the alterations in the erythrocyte numbers.

From the curves showing the relative values in the surviving patients (Figs. 5 and 6), it is seen that these are able to dilute their blood, that is to say, to absorb fluid poor in protein from the tissues into the blood; very great losses have been observed, down to as much as 60 % of the original value. After the lapse of 4—6 days there is a certain tendency to a rise of the figures, which may possibly depend on an increased production of protein following a richer supply of food.

In fatal cases, the curves sometimes fall, sometimes rise (Fig. 7); the greatest downward tendency occurs in patients with intraperitoneal hemorrhage; the rising curves have already been discussed.

The curves showing the absolute values of plasma protein concentration are centred round the value, 5.5 % — the so-called edema-limit (Figs. 19, 20, 21). Most of the surviving patients had, for varying periods, a protein-concentration below 5.5 % — even down to 4.5 % — without any of them displaying manifest edema, though some may very well have had cryptic edema.[12] The curves for the fatal cases start at a somewhat lower level, but show a tendency to rise.

Determination of plasma bicarbonate.

It is generally held[8–26], that shock and peritonitis are accompanied by acidosis; BORGSTRÖM[9] has lately declared that, in 4 out of 5 patients who had undergone gastrectomy, the acidosis was so pronounced that treatment with infusions of bicarbonate was necessary; however, he does not state the degree of acidosis. Nothing corresponding is met with in the present series. Three patients, *in extremis*, were down to 18 mMol/l bicarbonate; at autopsy, all of them were found to have had pulmonary edema, and one of them was one of the two patients with intraperitoneal haemorrhage. One patient had 19 mMol/l which rose, without any bicarbonate being given to 33 in one day. There was also a single case with 20, while 22 mMol/l generally represents the lowest limit (Figs. 8, 9 & 10). Consequently, it is seen that acidosis was a negligeable factor in this series.

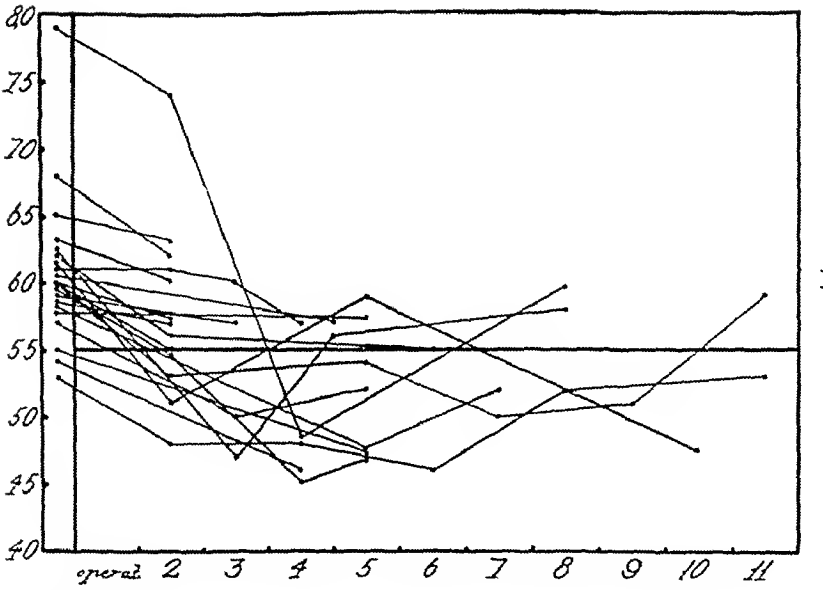

Fig. 19.

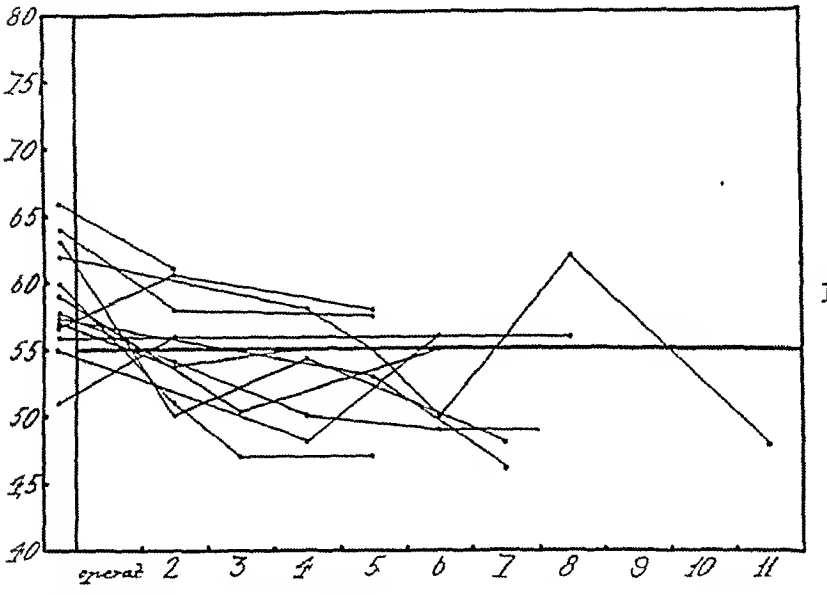

Fig. 20.

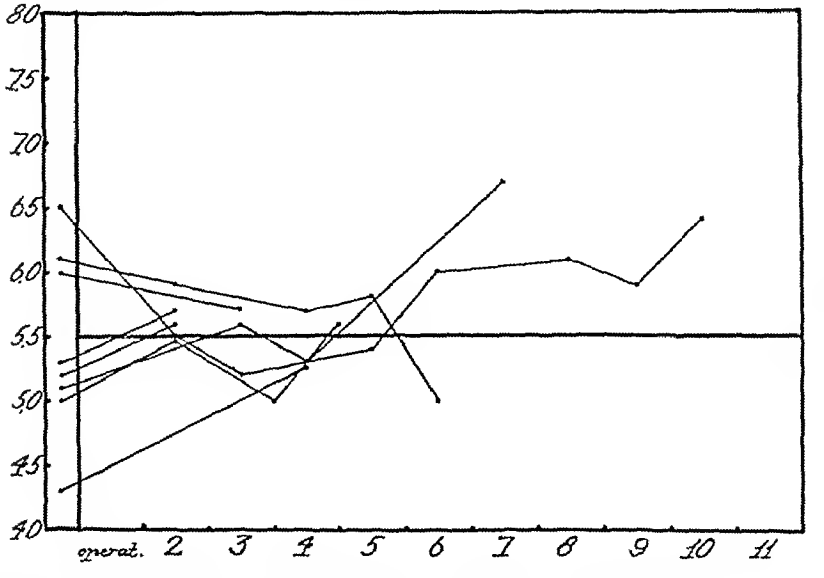

Fig. 21.

Ordinate: plasmaprotein concentration in percentage. Abscissa: post-operative day.

Fig. 19: protein concentration curves in surviving ulcer cases.
Fig. 20: protein concentration curves in surviving cancer cases.
Fig. 21: protein concentration curves in fatal cancer cases.

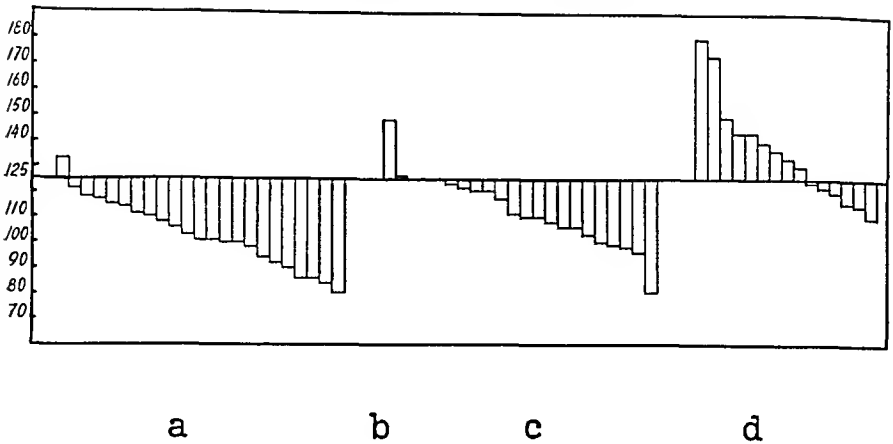

Fig. 22.

Ordinate: haemoconcentration in percentage of the last preoperative value.
Schematic survey of the maximum haemoconcentration in the four groups of the series, with 125 % of the preoperative haemoconcentration as axis.
Each column represents one patient.
(2 patients, dead in intraperitoneal hemorrhage, and 2 who died of embolia arteriae pulmonalis are omitted.)
a: Surviving ulcer cases — b: fatal ulcer cases — c: surviving cancer cases — d: fatal cancer cases.
The haemoconcentration of all the fatal cases has exceeded 110 % of the preoperative values. All the patients, with the exception of one, whose haemoconcentration curves exceeded 125 %, died.

Determinations of plasma chloride.

No marked examples of chloropenia were observed — the lowest figure being about 80 mMol/l. On the other hand, we find among the dead cancer patients, several rises which are quite striking.

The highest values — 136 and 140 mMol/l — were observed in two patients who died of pulmonary oedema (bicarbonate figures: 24 and 18 mMol/l) (Figs. 11, 12 and 13).

Undue significance is attached in COLLER & MADDOCK's[11] formula to plasma chloride concentration as a guide to fluid intake.

The plasma chloride figure merely gives information respecting the concentration of chloride ions in plasma; changes do not solely depend on the loss or supply of chlorides, especially when little fluid has been lost from the alimentary tract. The loss of chloride by perspiration is slight[12], and the secretion of chloride in the urine is minimal[28] during the first few days after operation. The eventual diminished plasma concentration is due, rather, to increased permeability of the red blood cell membrane from anoxia. Thus an equilibrium is established between the ions

whose concentration depend on selective permeability of the cells, that is to say, the plasma-content of Cl^- and Na^+ falls, while, for instance, the concentration of K^+ rises.[30]

COLLER & MADDOCK[11] suggest to administer saline — according to the plasma chloride concentration and the patient's weight, but this presupposes normal capillary permeability, plasma protein concentration[1] and kidney function, which are not always found after operation.

Furthermore, as the chloride concentration seldom falls low enough to give symptoms, it should be a natural thing to abandon the linking of the chloride concentration in the plasma to the supply of fluid[27], and, instead, to adjust the latter in accordance with the patient's clinical condition, the fluid-balance and the plasma protein-concentration.

Summary.

An account is given of pre- and post-operative investigations of haemoconcentration, plasma protein-, plasma bicarbonate- and plasma chloride-concentrations, and of the fluid-balance of 61 patients who have undergone gastrectomy.

The methods employed for the determination of haemoconcentration are discussed.

Haemoconcentration in the patients who survived operation falls, the fall is greatest in those whose condition is best.

After operation, the haemoconcentration of 12 patients was 25 % higher than before it. All these patients died, with the exception of one, although, in many of these cases, haemoconcentration was successfully reduced to a normal level.

Two patients died of intraperitoneal hemorrhage — their haemoconcentration curves displayed falls to 49 and 70 % of the preoperative values.

Two patients who died of pulmonary embolism, displayed rises of 10 % and 28 %.

Haemoconcentration as a reflection of the blood-volume during haemorrhage, shock and dehydration is discussed.

Haemoconcentration, during the first post-operative days, can oscillate as an expression of the varying predominance of two processes — loss of plasma through the capillaries, and inflow of fluid from tissues to the vascular system.

Patients whose condition was best diluted their blood quickly

and markedly — as an expression of an effective restoration of blood-volume after the loss of blood during operation.

An increased haemoconcentration, of 25 %, corresponds to a reduction of blood-volume of 20 %. It may be assumed that when the blood-volume falls below this, insufficient circulation causes irreparable injury to the central nervous system.

A rise of haemoconcentration as a result of blood-transfusion cannot be demonstrated.

The determination of plasma protein by measuring the specific weight of the plasma does not give reliable information respecting its colloid-osmotic pressure, without knowledge of the albumin-globulin ratio.

For this and other reasons there is a risk in relying on the edema-limit — 5.5 % protein in the plasma — administering infusions of crystalloids, etc.

Pulmonary edema was found at autopsy of 11 patients. The plasma protein-concentration in these cases was higher than 5.5 %, with the exception of two who showed gross intraperitoneal hemorrhage.

No pronounced case of acidosis occurs in the present series.

The determinations of plasma chloride showed in a few instances great rises in patients with pulmonary edema, but the lowest concentrations lay about 80 mMol/l.

The importance of plasma chloride-concentration is discussed; it is emphasized that this factor cannot be an expression of the fluid-demand of the organism and that one cannot administer fluid on the basis of this figures.

Zusammenfassung.

Es werden prä- und postoperative Untersuchungen der Hämokonzentration, der Plasmaprotein-, Bikarbonat- und Chloridkonzentration sowie der Flüssigkeitsbilanz bei 61 magenresezierten Kranken vorgelegt.

Die Methodik der Blutkonzentrationsbestimmungen wird besprochen.

Die Blutkonzentration bei Kranken, die die Operation überleben, ist eine sinkende, und zwar um so niedriger, je besser der Zustand ist.

Bei 12 Patienten war die Blutkonzentration auf einem gewissen Zeitpunkt nach der Operation 25 % höher, als vor der Operation.

Alle diese Kranken starben mit einer Ausnahme — obwohl es bei vielen von ihnen gelang, die Blutkonzentration wieder auf ihre normale Höhe herabzubringen.

Zwei Kranke starben an intraperitonealer Blutung — ihre Blutkonzentration zeigte ein Sinken auf 49 bzw. 70 % des präoperativen Wertes. Zwei Patienten, die an Embolia a. pulm. starben, wiesen Steigerungen auf 10 % bzw. 28 % auf.

Es wird die Blutkonzentration als Ausdruck für das Blutvolumen bei Blutung, Choek und Dehydrierung besprochen.

Die Blutkonzentration kann in den ersten 24 Stunden naeh der Operation Sehwankungen aufweisen, als Ausdruek des weehselnden Überwiegens bald des einen, bald des anderen von zwei Vorgängen: Plasmaverlust dureh die Kapillaren und Einströmen von Flüssigkeit aus dem Gewebe in die Blutbahn. Die Kranken, die am besten zurechtkamen, hatten ihr Blut raseh und kräftig verdünnt — als Ausdruck für eine effektive Wiederherstellung des Blutvolumens naeh dem Blutverlust bei der Operation.

Eine Konzentration des Blutes von 25 % entsprieht einer Blutvolumenreduktion von 20 %. — Es ist anzunehmen, dass hierbei der Kreislauf so insuffizient ist, dass irreparable Sehädigungen des Zentralnervensystems stattfinden. Ein Steigen der Blutkonzentration als Folge von Bluttransfusion lässt sieh nieht naehweisen.

Plasmaproteinbestimmung durch Messung des spezifischen Gewiehts des Plasmas gibt keine sicheren Auskünfte über den kolloidosmotischen Druek des Plasmas, so lange der Albumin/Globulinquotient nieht bekannt ist.

Aus diesem und anderen Gründen ist es gefährlieh, sieh bei der Administration von Infusionen mit Kristalloiden usw. auf die Ödemgrenze — 5.5 % Protein im Plasma — zu verlassen.

Lungenödem wurde bei der Sektion von 11 Patienten gefunden. Bei diesen betrug die Plasmaproteinkonzentration über 5.5 %, ausser bei zweien, die eine grosse intraperitoneale Blutung hatten.

Im Material kommen ausgesprochene Fälle von Azidose nicht vor.

Plasmaehloridbestimmungen ergaben vereinzelte, grosse Steigerungen bei Kranken mit Lungenödem, während die geringsten Konzentrationen etwa 80 mMol/l betrugen. Die Bedeutung der Plasmachloridkonzentration wird erörtert, und es wird betont, dass sie nieht einen Ausdruek des Flüssigkeitsbedürfnisses des Körpers darstellen kann, und dass Flüssigkeitsadministration an Hand derselben nieht stattfinden kann.

Résumé.

Les auteurs présentent les résultats de leurs recherches pré- et postopératoires faites chez 61 malades ayant subi une résection d'estomac, recherches qui portent sur la concentration sanguine et celle des protéïnes du plasma, du bicarbonate et des chlorures, ainsi que sur le bilan hydrique.

Discussion des méthodes servant à déterminer la concentration sanguine.

Chez les malades qui survivent à l'opération, la concentration sanguine va en s'abaissant, et cela d'autant plus que leur état est meilleur.

La concentration sanguine de 12 malades était, à un moment donné après l'opération, de 25 % plus élevée qu'avant l'intervention. Ils moururent tous, à l'exception d'un seul — bien qu'on eût réussi pour beaucoup d'entre eux à faire redescendre la concentration sanguine jusqu'à un niveau normal.

Deux patients décédèrent d'hémorragie intrapéritonéale — la courbe de leur concentration sanguine présenta des chutes de 49 et 70 % par rapport aux chiffres préopératoires. Chez deux sujets qui succombèrent à une embolie dans l'artère pulmonaire on constata des ascensions jusqu'à 10 % et 28 %.

Discussion du rôle de l'hémoconcentration en tant qu'expression du volume sanguin dans l'hémorragie, le shock et la déshydratation.

La concentration sanguine peut osciller au cours des premiers jours après l'opération, traduisant ainsi l'alternance des deux processus — la perte de plasma par les capillaires et en pénétration de liquide des tissus dans la voie sanguine.

Les malades qui se sont le mieux tiré d'affaire ont dilué leur sang rapidement et fortement — comme expression d'une reconstitution efficace du volume sanguin après l'hémorragie opératoire.

Une concentration de 25 % correspond à une réduction de 20 % du volume sanguin. Il faut admettre que dans ces conditions la circulation devient si insuffisante que des dommages irréparables sont causés au système nerveux central.

On ne peut pas démontrer d'ascension de la concentration sanguine à la suite d'une transfusion de sang.

Le dosage des protéïnes plasmatiques par détermination du poids spécifique du plasma ne donne pas de renseignements certains sur la pression colloïde osmotique du plasma tant qu'on ne connaît pas le quotient albumines globulines.

Pour cette raison et d'autres encore, il est risqué de se fier au chiffre indiquant que le seuil de l'œdème est atteint — 5.5 % de protéïne dans le plasma — lors de l'administration d'infusions de cristalloïdes, etc.

Un œdème pulmonaire a été trouvé à l'autopsie de 11 sujets. Chez eux la concentration des protéïnes du plasma dépassait 5.5 %, à deux exceptions près où il y avait une grande hémorragie intrapéritonéale.

Dans le matériel étudié on n'a pas rencontré de cas d'acidose marquée.

Le dosage des chlorures plasmatiques a montré quelques grandes ascensions chez des malades atteints d'œdème pulmonaire, tandis que les concentrations les plus basses étaient autour de 80 mMo 1/1. Les auteurs discutent de la concentration des chlorures du plasma, et ils soulignent qu'elle ne saurait exprimer le besoin de liquide éprouvé par l'organisme, de sorte qu'on ne peut pas se baser sur elle pour l'administration des liquides.

Literature.

1. Aalkjaer, V.: Væskeforholdene ved kirurgiske Sygdomme, København 1943. — 2. Ackman, D., J. W. Gerrie, J. E. Pritchard & E. S. Mills: A Report on the Management of Burns. Ann. Surg. 119: 161, 1944. — 3. Barbour, H. G. & W. F. Hamilton: The Falling Drop Method for Determining Specific Gravity. J. Biol. Chem. 69: 625, 1926. — 4. Bazett, H. C.: The Circulation, in Macleods Physiology in Modern Medicine, p. 300, London 1942. — 5. Beard, J. W. & A. Blalock: Experimental Shock: Composition of Fluid that Escapes from Blood Stream after Mild Trauma to Extremity, after Trauma to Intestines and after Burns. Arch. Surg. 22: 617, 1931. — 6. Bing, J.: Serumproteinbestemmelse med Glasperlemethoden. Ugeskr. f. Læger 100: 1162, 1938. — 7. Black, D. A. K.: Treatment of Burn Shock with Plasma and Serum. Brit. M. J. 2: 693, 1940. — 8. Blalock, A.: Principles of Surgical Care. Shock and Other Problems. St. Louis 1940. — 9. Borgström, S.: Erfarenheter vid kirurgiska kliniken i Lund av kontrollerad vätskebehandling. Nord. Med. 21: 359, 1944. — 10. Carrier, E. B., F. W. Lee & G. M. Whipple: Determination of Plasma and Hemoglobin Volume after Unit Hemorrhage under Controlled Experimental Conditions. Am. J. Physiol. 61: 138, 1922. — 11. Coller, F. A. & W. G. Maddock: Water and Electrolyte Balance. Surg., Gynec. & Obst. 70: 340, 1940. — 12. Dill, D. B.: Life, Heat and Altitude. Cambridge, Harvard University Press 1938. — 13. Drury, A. N. & N. W. Jones: Observations upon the Rate at which Edema Forms when the Veins of the Human Limb Are Congested. Heart, 14: 55, 1927. — 14. Ebert, R. V., E. A. Stead & J. G. Gibson: Response

of Normal Subjects to Acute Blood Loss with Special Reference to the Restoration of Blood Volume. Arch. Int. -Med. 68: 578, 1941. — 15. FINE, J., F. FUCHS & J. MARK: Effect of Desoxycorticosterone on Plasma Volume in Intestinal Obstruction. Proc. Soc. Exper. Biol. & Med. 43: 514, 1940. — 16. FOGED, J. & H. LARSEN: Cancer ventriculi — en klinisk Analyse af 407 Tilfælde. Ugeskr. f. Læger 106: 71, 1944. — 17. FREEMAN, N. E., H. FREEDMAN & C. C. MILLER: Production of Shock by Prolonged Continuous Injection of Adrenalin in Unanesthetized Dogs. Am. J. Physiol. 131: 545, 1941. — 18. GIBSON, J. G. & I. KOPP: Studies in the Physiology of Arteficial Fever. I: Changes in the Blood and Water Balance. J. Clin. Invest. 17: 219, 1938. — 19. GREGERSEN, M. I.: The Distribution and Regulation of Water in the Body, in MACLEODS Physiology in Modern Medicine, p. 1073. London 1942. — 20. GREGERSEN, M. I. & E. E. PAINTER: Plasma Volume and, "Available Fluid" Changes in Dehydration. Am. J. Physiol. 126: 511, 1939. — 21. JACOBSEN, C. F. & K. LINDERSTRÖM LANG: Method for Rapid Determination of Specific Gravity. Acta physiol. scand. 1: 149, 1940. — 22. KØSTER, K. H.: Vasopressin. Ugeskr. f. Læger 104: 27, 1942. — 23. KØSTER, K. H.: Traumatisk Shock, København 1943. — 24. LANDIS, E. M.: The Effect of Lack of Oxygen on the Permeability of the Capillary Wall to Fluid and to the Plasma. Am. J. Physiol. 83: 528, 1928. — 25. LINDGREN, S. & O. WILANDER: Kontrollerad vätsketillförsel vid shock. Nord. Med. 12: 3099, 1941. — 26. MOON, V. H.: Shock, Its Dynamics, Occurrence and Management. Philadelphia 1942. — 27. MORRIS, N.: Dehydration. Lancet 245: 91, 1943. — 28. OTTSEN, M. & K. H. KØSTER: data, not yet published. — 29. PRESMAN, D. L., M. JANOTA, R. E. WESTON, S. O. LEVISON & H. NECHELES: Intensive Human Serum Treatment of Burn Shock. J. A. M. A. 122: 924, 1943. — 30. SCUDDER, J.: Shock. Philadelphia 1940. — 31. VAN SLYKE, cit. BAZETT. — 32. STENGEL, A. & I. S. RAVDIN: The Maintenance of Nutrition in Surgical Patients with a Description of the Orojejunal Method of Feeding. Surgery 6: 511, 1939.

From the Surgical Department III of Ullevål Hospital, Oslo.
(Chief: CARL SEMB, M. D.)

Liver Changes in Surgical Conditions.

By

LEIF EFSKIND, M. D.

1. Introduction.

The importance of the liver for the post-operative symptom complex has long been generally recognized. Meanwhile it has gained new actuality through the investigations made in recent years respecting the behaviour of the serum proteins in patients with various surgical diseases and through the many experimental inquiries that have been undertaken with regard to the significance of the liver as producer of and depot for easily mobilizable protein.

In succession to large operations there comes, as is known, a fall in the quantity of serum protein. The extent and duration of the fall is to an essential degree dependent on the power of the organism to produce serum protein, provided that the supply thereof has not been materially reduced during a long period. The clinical-psysiological tests available for control of the hepatic function are in so far so uncertain and inexact that minor changes in the functioning of the liver cells cannot be recorded by this means. It should therefore be of interest to scrutinize the anatomical conditions in the liver of patients with varying reaction to the operation on the part of the serum proteins. No such systematic examination, of both hematological and histological nature, seems hitherto to have been published.

2. Material and Methods.

Altogether 120 patients, with primary lesions as shown in the table given below (Tab. I) have been investigated. The hematological status of these patients was carefully examined both before

and after the operation. The hematological status and the fluid-NaCl status have as far as possible been balanced before the operation. Biopsies from the liver were taken at the beginning and at the conclusion of the operation at intervals varying from 1 to $3^1/_2$ hours. As a rule they were taken from the left lobe by means of a sharp instrument. In some cases it would have been of interest to examine the liver findings during the further course of the illness. Meanwhile it was found that liver biopsies taken by puncture proved to be not quite reliable for the purpose of such examinations, probably owing to the mechanical damage to the tissue, and moreover the harmlessness of the method is disputable. The samples were examined for content of glycogen and fat. The behaviour of the mitochondria was also scrutinized, while an attempt was made to study the circulatory conditions from the appearance of the sinusoids. Likewise were examined the general cytological conditions in the liver-cells themselves and the interlobular formations.

Tab. I.

Ulcus ventriculi	17 cases.
Ulcus duodeni	20 » .
Ulcus perforans	4 » .
Ulcus pepticum	4 » .
Carcinoma ventriculi	20 » .
Polypus ventriculi	3 » .
Carcinoma oesophagi	3 » .
Cholelithiasis and cholecystitis	16 » .
Icterus chronicus	8 » .
Dyskinesia of the bile ducts	3 » .
Choledocholithiasis	6 » .
Carcinoma coli	8 » .
Acute jeunitis and ileitis	4 » .
Icterus haemolyticus	2 » .
Hernia diaphragmatica	2 » .
	120 cases.

3. Survey of the Material.

In order to give a clearer view of the matter, the glycogen, fat and mitochrondria preparations will be described separately. The circulatory conditions will be discussed together with the general cytological reactions in the liver-cells and the changes in the connective tissue.

According to the histological findings the patients have been divided into three groups, namely:

I. Those who before the operation received adequate nourishment, and who without special preliminary treatment show normal hematological conditions.

II. Patients who presented signs of pre-operative chronic hypoproteinemia.

III. Patients with diseases of the liver or of the bile-ducts.

A. The Glycogen Material.

In Group 1, with normal state of nutrition before the operation, there was found without exception in the first biopsy abundant deposition of glycogen in the liver cells, with diffuse distribution within the liver as a whole and within the separate lobes, being possibly somewhat less marked in the intermediary part of the lobulus. Within the individual cell the glycogen is either generally diffused or pressed somewhat towards one half of the cell, which thus acquires a semilunar appearance. The glycogen occurs as fairly even-sized granules, lying close together. It is therefore permissible to assume that when the liver is saturated with glycogen, the deposition will be fairly homogeneous throughout the whole organ.

After laparotomy, even of relatively short duration, there may be found in the second biopsy changes of both morphological and quantitative nature in the glycogen deposit. The most conspicuous features in this group are the quantitative changes in form of a reduction which to a certain extent seems to run parallel with the duration of the operation. As regards the topograph, the loss of glycogen is most marked in the intermediary part of the lobulus, where the process of washing out is most effective, but in operations of short duration the loss is very moderate. Where the operation, however, has been severe and of longer duration there may be seen in patches a more complete mobilisation of the glycogen. Some circumscribed parts of the liver tissue may thus be practically entirely deprived of glycogen, often passing over with sharp boundaries to areas with almost normal glycogen content. As a rule these parts extend out over the middle fields of the lobes, not infrequently touching upon the central vein or being in some cases circular in relation thereto (Fig. 1). It is generally found in this group that the glycogen remains longest

in the periphery of the lobuli, but when the loss has been excessive it disappears also there and we find only a border of cells containing glycogen just beneath the capsule of an otherwise glycogenfree liver. Where general degenerative changes are seen in the liver cells, especially in the form of fatty degeneration, as well as in some few other cases, glycogen-containing cells may, as will later be seen, be found with in centrolobular location. These topographical variations in the loss of glycogen may often be ascribed to local circulatory disturbances in the sinusoids of the liver. In some few cases, however, where there is great local centrolobular venous dilation attended by edema, it may be found that the glycogen maintains itself best in the central part of the lobes.

In Group II are found chiefly the same changes as were seen in Group I, but with certain quantitative divergencies, of which the most conspicuous is the considerably greater operative fall in glycogen deposit in this group. Likewise hereto liver cells which lose their glycogen show no distinct change in size as compared with the glycogenfilled cells. Where these patients have received adequate pre-operative treatment the content of glycogen in the first biopsy may be normal, or only slightly reduced. Nevertheless, the operative fall in glycogen will be remarkably great. It is therefore evident that in these patients, even though the liver glycogen may easily be restored, there exists an abnormal balancing of the carbohydrate metabolism, of hepatogenous or extrahepatogenous nature.

In Group III there are not infrequently found, as shall later be referred to, very distinct degenerative changes of general cytological nature, which was also occasionally the case in Group II. Likewise we often find at the same time in the liver cells deposits of other substances, such as bile-pigment and fat, a circumstance which makes it difficult to judge about the effect of deposition of glycogen. Also in this group there is seen a considerable operative fall in the glycogen deposit, sometimes more marked than in the previously mentioned groups. In patients with chronic icterus one may find before the operation that the cells are remarkably well supplied with glycogen. In these cases, however, it is seen that the operative trauma causes an abnormally active mobilisation. In those cells which are interspersed by brownish pigment, a finding especially to be noted in centrolobular parts (Fig. 2), the content of glycogen is usually found to be small. As

regards cells infiltrated with fat, it seems that this substance in itself does not produce changes affecting the glycogen deposit in the cells, except of course, in purely volumetric respects. On the contrary, these cells are found, both before and after operation, to be strikingly well saturated with glycogen, and they may lie as small glycogen-filled islands in a liver otherwise free from glycogen, and then usually in the central part of the lobe. Often there may specially be seen an accumulation of glycogen granules around the fat vacuoles (Fig. 3). This persistance of glycogen in areas which otherwise earliest lose their glycogen decidedly indicates that the mobilisation of glycogen in these fat-infiltrated cells is rendered difficult and that there exists a form of glycogen blockade in considerable degree.

In this group of patients there are now and then seen islands of cells which contain much glycogen, surrounded by glycogen-free areas. As a rule these cells show no general cytological signs of regressive changes (Fig. 4). They may, however, also occur as single cells, but then often with distinct signs of degeneration. They are usually situated perilobularly and as regards localisation and appearance they resemble those parts of the liver where in animals with experimental hyperthyrosis abnormal permeability conditions have been observed in the sinusoids (Eker and Efskind). The glycogen in these cells is often found to be assembled in patches separated by areas quite free from glycogen, so that the cells acquire a vacuolized appearance. These vacuoles may, without special staining, be difficult to distinguish from others of different nature, such as fat vacuoles. They usually have not, however, the circular form and regular contours of these latter. In some patients in this group the largest deposits of glycogen are found, as above mentioned, to be centrolobularly situated in a circle around the central vein. At the same time we usually find signs of considerable disturbances of the central circulation, together with edema, and now and then invasion of granulocytes and lymphocytes into the tissue. In other words, signs of serious central permeability derangements of the blood-vessels. The reduced glycogen mobilisation in these exceptional cases might then be explained as being due to a blockade on circulatory basis. In the same direction points the fact that a similar picture can be seen when the central vein is practically occluded through endophlebitic changes (Fig. 5.)

B. Fat Deposition.

In Group I we practically never find in the first biopsy signs of deposition of fat in the liver cells. The same applies to the second biopsy in cases where the operation has not been greatly protracted. In case of severe operations, lasting several hours, very small droplets of fat may be found in some of the liver cells. These cells usually lie in the vicinity of the central vein, more rarely out in the intermediary part of the lobes. This fat deposit has, however, in no case been of dominating character and it has as a rule been accompanied by other signs of general regressive changes in the cells.

In Group II, on the other hand, with addition of cases of malignant gastric tumours without special signs of nutritional insufficiency, small fat vacuoles are not infrequently found in the first biopsy. In cases where the anamnesis contains information as to hemorrhage of any material extent and duration the infiltration of fat may be considerable (Fig. 3). Also these fat deposits are centrally or paracentrally situated in the lobes, except in some few patients with malignant tumours, where the deposition may be perilobular around the vessels. Patients belonging to this group show, after the more serious operations, a considerable increase in the deposition of fat. It is therefore beyond doubt that patients of this category have an abnormal propensity to deposition of fat in the liver cells. This may be taken as an indication that the liver cells have difficulty in meeting the increased strain which an operation imposes upon the liver. The above-mentioned abnormalities in the carbohydrate metabolism which may be observed at the same time possibly play a part in the matter.

Group III shows mainly the same changes as those mentioned above. They are, however, still more accentuated, especially for patients with occlusions in the bile ducts combined with infection, while in patients suffering from chronic icterus without infectious basis the findings may be remarkably few. That infection here plays an important rôle is evident also from the fact that patients with relatively mild cholecystitis often show strikingly great changes in the liver cells in the form of abundant fat-infiltration, which also here is localized in middle part of the lobes, often around a dilated, periphlebitic central vein.

In the second biopsy the fat-infiltration is seen to have increased considerably, even in patients with moderate infectious

disorders of the bile ducts. Where stenotic processes and chronic icterus are present at the same time the infiltration of fat may be considerable and extend over large areas. Thus we may not infrequently find whole liver cells transformed into a single fat-vacuole and not one cell from fat. Also in these pronounced cases the deposition is greatest in the middle of the lobes, although there are some few exceptions, where a considerable interlobular inflammatory reaction is found at the same time.

C. The Mitochondria Material.

In patients belonging to Group I the liver cells in the first biopsy show entirely normal mitochondria, in plentiful numbers and with some preponderance in the peripheral parts of the lobes. With the method of staining employed (Altmann) they are bright red in colour. Some of them are of spherical form, some more rod-shaped, and they are of uniform size. The rod-shaped mitochondria are by far the least numerous. After protracted operations some reduction of the total number is noted in the second biopsy, the decrease being most evident in the middle parts of the lobes. At the same time the rod-shaped increase somewhat in number, while the shape and size become less uniform (Fig. 6).

Groups II and III show already in the first biopsy a distinct decrease in the number of mitochondria in the centre of the lobes. The morphological changes also become more pronounced. The colour becomes violet-blue and the contours are indistinct. The second biopsy may sometimes show very great changes. The number of mitochondria may be so greatly reduced that they occur only singly in the cells. The staining capacity is greatly lessened, so that with the staining methods used they may appear as almost achromatic yellowish, light-refracting formations. They become irregular in form and huge club-shaped aggregations, while the spherical forms may have entirely disappeared (Fig. 7). Now and then small vacuoles may be seen within the mitochondria. This is especially the case where the liver cells show pronounced signs of general degenerative character, with deposition of pigment and fat, nuclear changes and dissociation of the liver structure.

In some preparations it may be seen that the mitochondria persist longest in the centre of the lobes. There are then as a rule seen at the same time considerable central circulatory disturbances.

The first signs of reduction of the mitochondria within the individual cells appear in the perinuclear part, where there may be

seen a clear zone entirely without mitochondria. The remaining mitochondria are often radially arranged, so as to lie like spokes of a wheel. Where the rod-shaped types are predominant they also usually have a radial arrangement of their longest axis. In case of incipient degenerative changes the spherical mitochondria are often found to retain their shape and fresh colour, while the rod-shaped become achromatic and afterwards change their form (Fig. 8).

As regards the relation to other intracytoplasmatic substances, it is found that the changes in mitochondria and in glycogen do not proceed absolutely parallel. Thus we may find few mitochondria in a cell containing much glycogen, and vice versa. This speaks against the assumption that the mitochondria have a direct relation to the glycogen. In the fat infiltrated cells the content of mitochondria in the part of the cytoplasm that remains intact may be without any great changes, whereas the cells that contain pigment are as a rule poorly supplied with mitochondria.

D. General Histological Findings.

With respect to the circulatory conditions, the ordinary clinical and cardiographic investigations have not revealed organic changes that might be supposed to occasion serious circulatory disturbances in the liver. In Group I there are consequently found no histological signs of abnormal blood circulation. In the second sample the findings are also as a rule very few and uncharacteristic. After protracted operations one may now and then find signs of circulatory abnormality in the form of dilation of sinusoids in the centre of the lobes and a suggestion of dilation of the vena centralis. These vascular changes may be localized to individual lobes, in rare cases also to isolated sinusoids, a circumstance which might be taken as indicating a certain degree of autonomy in the regulation of blood flow to the separate lobes.

In Groups II and III, on the contrary, one often finds in the first sample signs of moderate centrolobular circulatory disturbances, such as previously described. Further, there may be found in the central vein hyperplasia of the intima and signs of perivenous fibrosis and some extrusion of lymphocytes into the tissue. In the second sample these findings are usually accentuated in case of severe operations and in patients who have for a long time been exposed to nutritional insufficiency. We may here find a diffuse sinusoidal dilation, pervading the entire lobulus and at the

same time distinct degenerative changes in the liver cells. These, however, cannot be regarded as commonplace stasis phenomena, as no signs of venous hyperemia can be found. Thus erythrocytes are so seldom observed in the dilated veins, that there seem to exist a relative erythrocytopenia. Neither are there to be found in the rest of the liver tissue the ordinary signs of permanent venous stasis. In some few cases of protracted icterus signs of serous hepatitis may be seen, but never to the extent regularly found in case of catarrhal icterus.

As regards the connective tissue, the first group shows no pathological changes. In the two other groups there is frequently seen some increase of the interlobular connective tissue, often associated with lymphocyte infiltration and thickening of the wall of the v. centralis. This increase of connective tissue may be seen in patients with long-continued nutritional insufficiency, but it is not accompanied by any certain atrophy of the liver cells, nor can it be designated as being a regular cirrhosis. As already mentioned, there is often found in these patients abundant infiltration of lymphocytes in the perilobular connective tissue. This is a constant phenomenon in patients with hepatic lesions, where even ordinary cholecystitis may show marked inflammatory cellular infiltration, of lymphocytes and plasma cells, without there being found in the clinical course any certain evidence of hepatitis or cholangitis. In some few instances the cells lie in and around the blood vessels, including the central vein. In most cases the infiltration is more diffuse, without definite relation to blood vessels and bile ducts, and may probably be explained as being a hepatic lymphangitis, the more so because enlarged lymphatic nodes have been observed in the hilus of the liver at the same time. This inflammation may be a very prominent feature without any clearly demonstrable changes of regressive nature being necessarily found in the liver cells.

The reticulo-endothelial apparatus in the liver rather frequently shows changes, usually of proliferative nature. We may find increase in the number of cells, hyperplasia of the individual cell and augmented phagocytary activity. This latter manifests itself in the cases where there is a considerable deposition of fat in the liver, as we then find numerous fat-droplets in the Kupffer cells. In cases with protracted icterus deposition of bile-pigment is not infrequently seen.

4. Conclusions.

The present investigations have shown that in operation patients suffering from serious illnesses there may before the operation be noted a number of changes in the liver, which are probably to be regarded as pathological. These changes are considerably accentuated after more severe operations.

On closer analysis of the material several questions naturally arise, namely: the causative relations in these changes, whether one can draw conclusions therefrom respecting the functional condition of the liver cells and thereby obtain information as to the otherwise indeterminable factor: hepatic reserve, whether they can supply a basis for prognostic conclusions and, finally, whether they can be clinically detected and treated.

As regards causative factors it is reasonable firstly to investigate whether the patient's general condition and the primary disorder, in fact the whole pre-operative status, are reflected in the histological findings in the liver. Next, the effect of the operative trauma and whether this effect is independent of the pre-operative condition. This latter question may be of both prophylactic and therapeutic importance.

The effects on the liver of chronic nutritional insufficiency have been ascertained through numerous experimental investigations on animals reported in the literature. There, however, the most prominent features are loss of glycogen and atrophy of the liver cells, while degenerative changes, of other nature, including deposition of fat, do not seem to be very pronounced in this dissimilatory phase of hepatic function. In our cases with protracted undernourishment and hematological signs of considerable hypoproteinemia pre-operative changes of both quantitative and topographical nature in the glycogen deposit in the liver have been observed. The question whether at the same time there has existed chronic occlusional icterus, without simultaneous infection of the bile ducts, need not be supposed to play any decisive rôle as regards the glycogen content. A liver well supplied with glycogen has also been found by Krarup in cases of icterus due to acute hepatitis.

A less constant finding in this group of patients is deposition of fat in the liver cells. This is, however, by no means a rare phenomenon, and may appear where there have not been seen any signs of cardial stasis or other conditions which might pre-



Fig. 1. × 150. Glycogen-free area (1) around the central vein (2) passing with sharp delimitation over to a region well supplied with glycogen.



Fig. 2. × 1,000. Cells containing pigment and little glycogen in the centre of a lobulus.

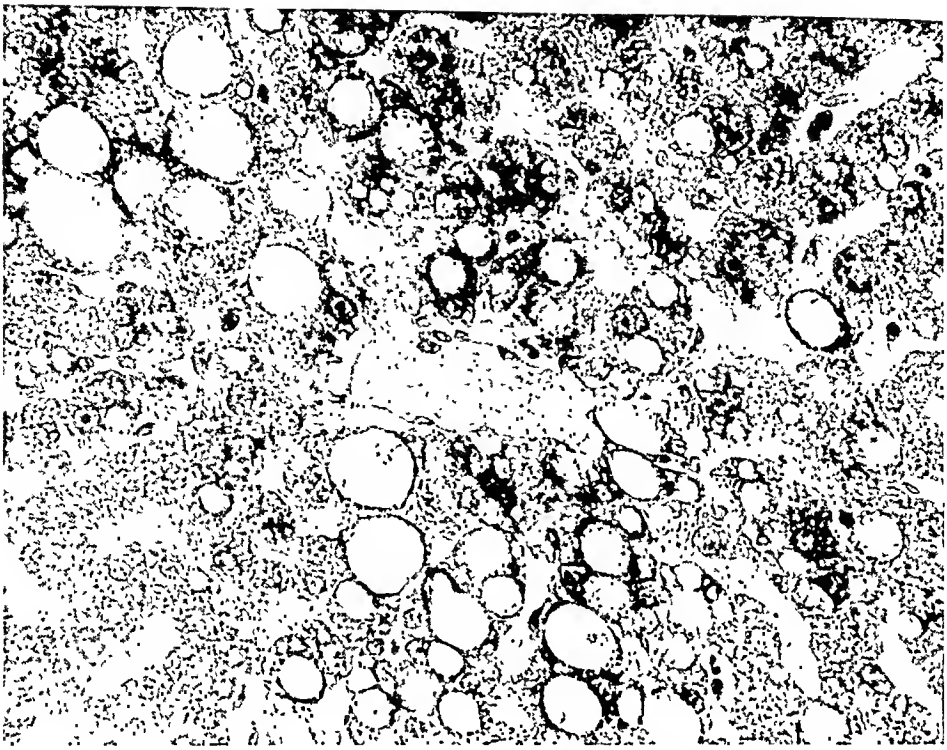

Fig. 3. × 400. Liver cells containing fat around the central vein, with a belt of glycogen granules.



Fig. 4. × 200. Vacuolized cells containing glycogen (1) around the central vein (2).



Fig. 5. × 400. Vacuolized cells containing glycogen around an endophlebitic obturated central vein.

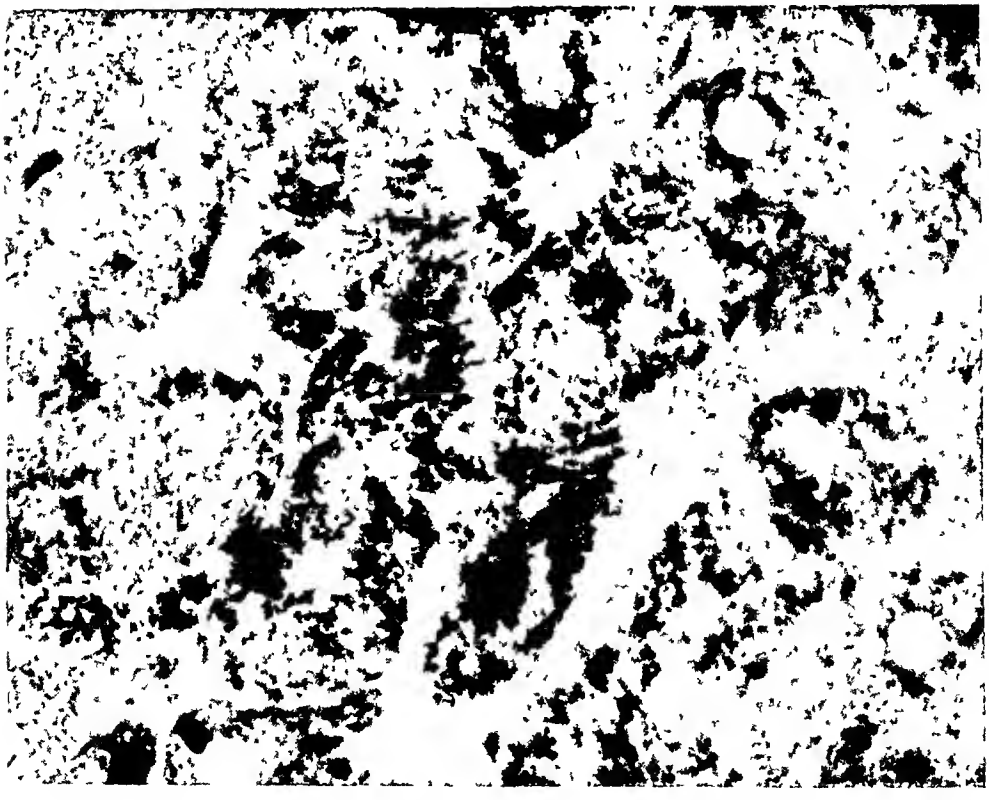

Fig 6. × 1 000 Cells with some reduction of the number of mitochondria and with relative increase in the rod-shaped elements.



Fig. 7. × 1,000. Cells with mainly rod-shaped mitochondria.

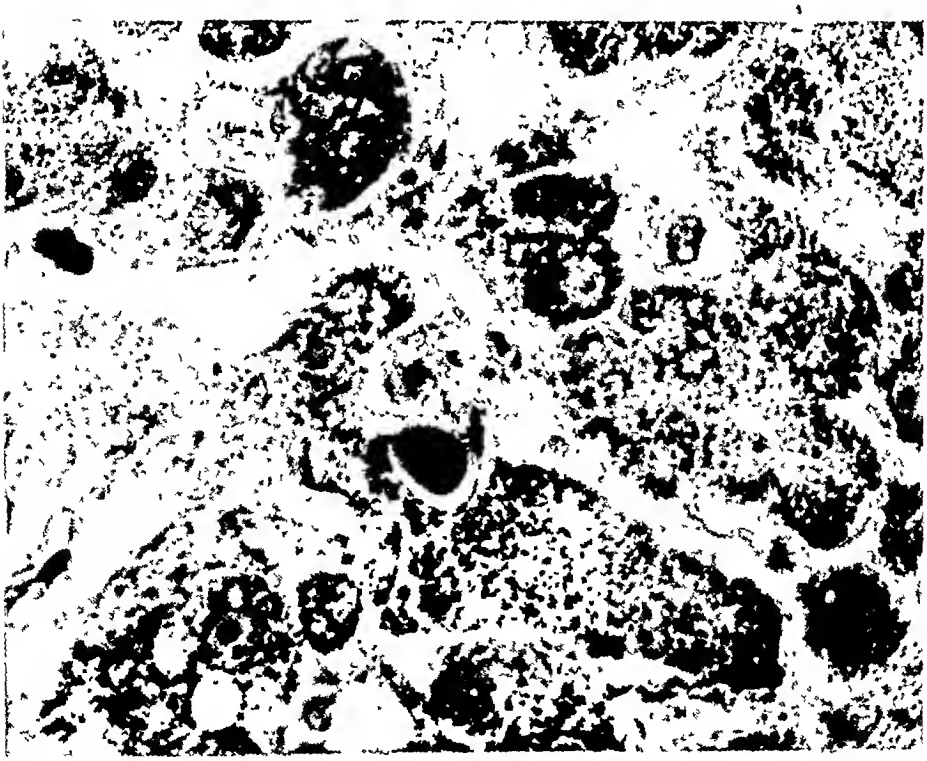

Fig. 8. × 1,000. Cells with distinctly stained round mitochondria. The rod-shaped are achromatic and therefore not visible.

dispose for hepatogenic deposition of fat. Its importance for the liver's store of glycogen seems to be of purely volumetric nature. Apart from the local cellular glycogen blockade caused by this deposition of fat, however, the liver shows in these cases, as reaction to the operative trauma, an increased mobilisation of glycogen as compared with normal controls. The fat-infiltrated liver cells are often remarkably well supplied with glycogen. This store of glycogen may remain unaltered after serious operative traumata, where the intact liver cells are entirely depleted of glycogen. This circumstance, taken in connection with glycogen blockade in distinctly degenerated liver cells, would seem to indicate an impairment of cellular function, with prevention of the transformation or consumption of glycogen. In these cases there is often nothing to show that the blockade has been of purely circulatory nature, whereas such a possibility may exist in the described cases of centrolobular circulatory disturbances with retention of glycogen in the centre of the lobes.

In these patients with nutritional insufficiency during a rather long time there is regularly found infiltration of fat after a grave operative injury, while this is only exceptionally the case with those who had a normal pre-operative status without any preliminary treatment. If these undernourished patients are brought into equilibrium before the operation as regards protein, fluids and electrolytes, their reaction to the operative trauma will still be far stronger than in the normal material taken for comparison. The reaction will, however, naturally be distinctly less marked than in patients not treated beforehand.

The mitochondrial investigations in these patients also show pathological features. On double-staining of mitochondria and glycogen in Regaud-fixed material the cells containing little glycogen are often found to show the most marked mitochondrial changes. The fat-containing cells, in spite of an abundant content of glycogen, may show both quantitative and morphological changes in the mitochondria, a fact which speaks for their pathological nature. On the whole, however, it may be said that fat-infiltration and mitochondrial changes represent a less sensitive indicator of the state of the liver cells than the glycogen reaction, even though we must make reservation as to the relatively large range of variation of this reaction.

The circulatory changes are everywhere less prominent as primary findings in comparison with the above-mentioned changes

in the liver cells. Meanwhile, this does not, of course, preclude the possibility of purely vasculofunctional changes being present at a far earlier point of time. For in human subjects, in contrast to animal material, we have no opportunity of investigating this matter with the means at present available (EKER and ERSKIND). The circulatory disturbances noted are, however, localized to more or less the same parts of the liver as the cellular changes. Meanwhile it is probable that they stand to a certain degree in relationship to each other, as the changes in the connective tissue point in that direction. The remarkably often found interstitial hepatitis in varying degrees and in widely different primary disorders seems to be more of lymphogenic than hematogenic nature. In my cases of perforating ulcer such reaction often failed to appear. No evidence of cholangitic infection has at all been discovered.

The question as to the organs to which the disorders have been localized in the material investigated seems to have no significance as regards the histological findings. As already mentioned, however, the liver and the bile ducts occupy an exceptional position in this respect. Where the localisation of the organ affected has been such as to hinder ingestion of food this circumstance has exerted an indirect influence via the preoperative status.

The supplementary post-operative changes have been mainly quantitatively or topographically divergent from the pre-operative. In degree they seem to be to a certain extent proportional to the pre-operative changes. The extent and duration of the operative trauma, however, also plays a demonstrable rôle. Thus after large operations we often observe changes also in patients whose livers were quite normal before the operation. On comparing these changes with the hematological findings it is seen that patients with little glycogen and considerable fat-infiltration in the liver show after operation an inordinately great fall in the serum proteins. This applies in most marked degree where the serum proteins have beforehand shown pathological features in the form of fractional displacement or reduction of total quantity, and in somewhat less degree in those patients in whom the serum-protein and fluid-electrolyte balance has been restored before the operation. Least affected are those who prior to the operation had normal conditions without undergoing preparatory treatment. Moreover it is found that patients with the afore-mentioned histological liver changes who show this post-operative fall re-

quire a longer time for restoration of their hematological status than normal persons, in this can be attained at all without active treatment. With this question we come to the problem of the judgment of this special part of the hepatic function on the basis of the histological findings and their reliability. We know that the earliest appearing change, the loss of glycogen, may within certain limits be a physiological phenomenon and that it is a dynamic factor based upon the functional rhythm of the liver. The same applies, according to my experience, in some degree to the behaviour of the mitochondria. These patients have, however, all been operated at the same time of the day and at the same interval after eating, with the exception of those who had for a considerable time been completely prevented from taking food. This source of error in the material should thereby be reduced to a minimum. Moreover, the bioptical samples have been taken at the same place, so that variation errors due to different topography ought to be very slight.

It has formerly been a general assumption that the glycogen content in the liver decreases greatly in case of hepatic diseases with icterus. This assumption is based upon experiments on animals with administration of toxic substances or ligation of the Ductus choledochus. It seemed to be supported by the clinically observed favourable effects of combined glucose and insulin therapy. Later investigations, however, have shown that such treatment can hardly be said to produce an increase of the glycogen content in the liver, but rather a mobilisation. In our material a normal glycogen content has repeatedly been found in patients with chronic icterus.

It has been claimed that experiments on animals (Whipple, Ravdin) have shown that livers containing little mobilisable protein are abnormally sensitive to toxic substances, and that fat-infiltration of the liver cells and diet rich in fat will increase this effect. These investigators have not carried out determinations of the glycogen content, but nevertheless they ascribe to glycogen a certain degree of protective influence. From our investigations there seems to be no fundamental antagonism between glycogen and fat deposits in the liver, apart from purely volumetric factors, while a liver poor in glycogen appears to be associated with reduction of hepatic function in so far as concerns the production of serum proteins. This is also under the assumption that the patient concerned has received adequate pre-operative treatment.

We shall not here enter into the question whether the glycogen has a direct protective action or is merely an expression for normal functioning of the liver. The same applies to the fat-infiltration, which doubtless in itself causes no increased sensitivity of the liver cells towards augmented demands upon their functions, but may well be regarded as the reaction in a beforehand pathological liver, with reduction of the functioning parenchyma and thereby of the hepatic reserve.

It is therefore reasonable to classify the observed histological changes as regressive and to regard them as signs of reduced hepatic function. The changes found, however, are often so moderate that from a histological standpoint they may seem to be of reversible nature. Thereby we come to the question whether they can be clinically diagnosed and eventually treated. No certain diagnosis can be made by the known clinical tests of hepatic function. On the other hand, there are particular categories of patients who, to judge from our material, may give grounds for the suspicion of such disorders of the liver, namely, patients with chronic hypoproteinemia, patients with impaired general state of health owing to nutritional difficulties and patients with disorders that lead to anemia.

Patients with chronic icterus do not seem to differ particularly from these categories in their post-operative reaction. Formerly it was reported that such patients had a considerably increased operational mortality, even after means had been obtained for overcoming their tendency to hemorrhage (WALTERS and others). Only in cases where cirrhosis was distinctly present at the same time did these patients seem to show an especially severe post-operative reaction.

Eventual causal treatment, which may often be of radical nature, ought therefore to be preceded by a purely symptomatic pre-operative therapy, with a view to remedying the hematological abnormities. Such treatment will, as already mentioned, not normalize their general reaction, but may distinctly reduce the degree thereof.

Summary.

1. In patients with various serious disorders in the intestinal tract there have been found, sometimes considerable, histological changes of regressive nature in the liver cells. These changes have been most pronounced in patients with protracted nutritional dis-

turbances, hypoproteinemia and anemia, and in case of disorders of the liver and bile ducts.

2. Topographically, these changes occur at certain places of predilection in the lobuli of the liver and are considerably accentuated during severe operations. Also normal livers may after large operations show the same changes, but in minor degree.

3. These changes occur in the following order:

a. Abnormal mobilisation of the liver glycogen.

b. Mitochondrial changes of regressive nature.

c. Interstitial lymphocyte-infiltration, sometimes with fibrosis.

d. Fat-infiltration of the liver cells.

4. The changes in the liver cells appear earliest and are most pronounced in the central parts of the lobuli.

5. The fat-infiltrated cells may often be well supplied with glycogen and frequently maintain their glycogen deposit for a long time, probably owing to a kind of cellular blockade. The same may be seen in case of chronic icterus and of considerable degenerative changes in the liver cells.

6. Patients in whom the liver, in spite of adequate preliminary treatment, contains little glycogen and much fat show an abnormally great post-operative fall in serum proteins, with inordinately long restitution time.

7. The Kupffer cells show proliferative changes and in many cases deposition of pigment or fat.

8. The interstitial hepatitis seems to have arisen on a vascular, probably lymphogenic basis. Cholangitic infection has not been observed, even in case of choledochal occlusion with infection.

Zusammenfassung.

1. Bei Patienten mit verschiedenen ernsthaften Krankheiten in Intestinaltraktus findet man in den Leberzellen histologische Veränderungen regressiver Art. Diese Befunde sind sehr deutlich bei Patienten mit langdauernden Ernährungsstörungen, Hypoproteinämie und Anämie samt Krankheiten in Leber und Gallenwegen.

2. Diese Veränderungen treten mit bestimmten topographischen Prädilektionsstellen in Leberlobuli auf. Sie werden durch grössere operative Eingriffe verstärkt. Auch in präoperativ normaler Leber können postoperative regressive Veränderungen geringeren Grades erzeigt werden.

3. Diese Veränderungen treten in folgender Reihe auf:

a. Abnorme Mobilisierung des Leberglykogens.

b. Mitokondrieveränderungen regressiver Art.

c. Interstitielle Lymphocyteninfiltration, nicht selten mit Fibrose.

d. Fettinfiltration der Leberzellen.

4. Die Veränderungen treten am ersten zentral in Lobulus auf.

5. Die fettinfiltrierten Leberzellen können reichliche Mengen von Glykogen enthalten. Dieses Glykogendepot ist schwer mobilisierbar, wahrscheinlich liegt eine zellulare Glykogenblockade vor. Dasselbe Verhalten kan man in degenerierten Leberzellen bei chronischer Ikterus sehen.

6. Bei Patienten, die trotz adäkvater Vorbehandlung glykogenarme und fettreiche Leber erzeigen, findet man abnorm grosse postoperative Erniedrigung der Serumproteinen und relativ verlängerte Regenerationszeit derselben.

7. Die Kupfferzellen zeigen anatomische und funktionelle Veränderungen proliferativer Art.

8. Die oben erwähnte interstitielle Hepatitis scheint oft auf lymphogenem Wege entstanden zu sein. Cholangitische Veränderungen sind selten auch bei mechanischer Choledochusokklusion.

Résumé.

1. Chez les malades atteints de désordres sérieux du tube intestinal, on a trouvé des modifications histologiques parfois très graves, de nature régressive, dans les cellules du foie. Ces modifications ont été plus accusées chez des malades souffrant de troubles de nutrition prolongés, d'hypoprotéinémie et d'anémie, ainsi que dans les cas de troubles du foie et des conduits biliaires.

2. Au point de vue topographique, ces modifications se produisent à certains endroits déterminés des lobules du foie et sont très marqués pendant les opérations graves. Dans ces derniers cas, les lésions peuvent se produire, bien qu'à un moindre degré, dans le foie normal lui-même.

3. Ces modifications se produisent dans l'ordre suivant:

a. mobilisation anormale du glycogène du foie.

b. modifications mitochondriques de caractère régressif.

c. infiltration lymphocytaire interstitielle, quelquefois accompagnée de prolifération fibreuse.

d. infiltration graisseuse des cellules hépatiques.

4. Les modifications dans les cellules du foie apparaissent très tôt et sont le plus accusées dans la partie centrale des lobules.

5. Les cellules ayant subi la dégénérescence graisseuse sont souvent bien pourvues de glycogène et gardent souvent longtemps leurs dépôts glycogéniques, probablement à la suite d'un blocus cellulaire. On peut observer le même phénomène dans les cas d'ictère chronique et de modification dégénérative grave dans les cellules hépatiques.

6. Les malades dont le foie, malgré le traitement préliminaire, contient peu de glycogène et beaucoup de graisse, subissent une diminution post-opératoire anormalement forte des protéines du sérum; le retour à la normale est exceptionnellement lent.

7. Les cellules de Kupffer prolifèrent et sont dans beaucoup de cas le siège de dépôts de pigment et de graisse.

8. L'hépatite interstitielle semble être d'origine vasculaire, probablement lymphogène. On n'a pas observé de cholangite infectieuse, même dans les cas d'occlusion du cholédoque avec infection.

Für wissenschaftliche Druckarbeiten jeder Art
— Abhandlungen, Fachzeitschriften usw. —
empfiehlt sich unsere Druckerei, die u. a.
den Druck der vorliegenden
Zeitschrift ausführt.

KUNGL. BOKTRYCKERIET
P. A. NORSTEDT & SÖNER
STOCKHOLM

ACTA CHIRURGICA
SCANDINAVICA
VOL. XCIII FASC. II—V

*

DONUM NATALICUM

FABIAN WILHELM GUSTAV LANGENSKIÖLD

STOCKHOLM 1946
KUNGL. BOKTRYCKERIET. P. A. NORSTEDT & SÖNER
454787

Fabian Langenskiöld

FABIANO VILELMO GUSTAVO

LANGENSKIÖLD

PROFESSORI CHIRURGO EMINENTI

SEXAGENARIO

A. D. XII Kal. April. Anno MCMXLVI

HUNC LIBRUM DONANT DEDICANT

DISCIPULI AMICI

INDEX AUCTORUM.

Pag.

G. af Björkesten (Helsinki): Position of Fingers and Function Deficiency in Ulnar Paralysis 99
O.-E. Cederberg (Helsinki): Beiträge zur Kenntnis über das Vorkommen von Echinokokkus-Fällen in Finnland 111
Aarre Ellonen (Helsinki): L'effet de la sympathectomie sur le fantôme douloureux d'un amputé 131
Harry Elving (Åbo): Einige Worte über die Spondylolisthesis und deren Behandlung 146
Sten Friberg and *Carl Hirsch* (Stockholm): On Late Results of Operative Treatment for Intervertebral Disc Prolapses in the Lumbar Region . 161
Lars Hagelstam (Helsinki): On the Deformities of the Spine in Multiple Neurofibromatosis (von Recklinghausen) 169
O. Hultén (Uppsala): Über Prolapsus recti bei Erwachsenen 194
Martti Hämäläinen and *Bror-Åke Söderlund* (Kuopio, Finland): On the Surgical Treatment of Scleroderma 201
K. R. Inberg (Tampere, Finland): Indefinite Pain in the Right Flank and its Origin — a New Symptom of Ileitis 213
K. E. Kallio (Helsinki): Sur les opérations plastiques du pouce 231
A. R. Klossner (Åbo): Sur l'endométriose se présentant dans l'anse sigmoïde 254
Aulis Korhonen (Helsinki): Sur les Epididymites aigues non spécifiques . 270
A. Langenskiöld (Helsinki): Gustatory Local Hyperhidrosis Following Injuries in the Parotid Region 294
L. J. Lindström (Vasa, Finland): On Repositioned Luxation Fracture of the VI Cervical Vertebra with Transverse Paralysis of the Spinal Marrow 307
Pehr Malm (Helsinki): Über einen Fall von Paraganglion mit seltener Lokalisation 315
P. E. A. Nylander and *K. Kivikancrvo* (Helsinki): On Extrapleural Pneumolysis in Pulmonary Tuberculosis 325
T. Gunnar Nyström (Kuopio, Finland): On the Treatment of Periappendicular Abscesses, Particularly with Regard to their X-Ray Therapy 344
Aarne Pelkonen (Helsinki): Über die Prostatamyome 352
Erkki Saarenmaa (Helsinki): On Clostridia Infections in War Wounds on the Carelian Isthmus 363
Torsten Sandelin (Helsinki): Processus Pyramidalis in Struma Operations . 386
Erik Severin (Stockholm): Arthrography in Sequelae to Acute Infectious Arthritis of the Hips of Young Children 389
E. Tiitinen and *K. Wahlfors* (Helsinki): Vertebra Plana Osteonecrotica (Calvé) 396
P. I. Tuovinen (Helsinki): Splanchnectomy by Megacolon Congenitum . . 404
Johannes Wahlberg (Helsinki): On the Practical Importance of the Clinical Determination of the Basal Metabolic Rate in Thyrotoxicosis 410
G. Wallgren (Helsinki): Treatment of the Congenital Flat-Foot 417
Carl Wegelius (Helsinki): Tables for Calculation of Exact Measurements of Radiographed Objects 424
Johan Holst (Oslo): Closure of the Bronchus in Pneumonectomy and Lobectomy 431
John Hellström and *Ragnar Romanus* (Stockholm): Uretero-intestinal Implantation According to Coffey 439

From the Finnish Red Cross Hospital.
(Surgeon-in-chief: A. SNELLMAN, M. D.)

Position of Fingers and Function Deficiency in Ulnar Paralysis.

By

G. AF BJÖRKESTEN.

While radial paralysis always yields a constant and typical picture (the so-called drop-hand), the situation is different with paralysis of some of the nerves supplying the flexors of the hand and the fingers. The reason for this is that while the innervation area of the radial nerve is practically always constant (all extensors and abductor pollicis longus), there is an important variation in the median and ulnar nerves, the innervation areas of which more or less work into each other.

The median nerve is normally considered to supply the following muscles: Pronator teres, flexor carpi radialis, palmaris longus, flexor digitorum sublimis II—V, flexor digitorum profundus II—III, flexor pollicis longus, pronator quadratus, flexor pollicis brevis, abductor pollicis brevis, opponens pollicis and lumbricales I—II. The following muscles are supplied by the ulnar nerve: Flexor carpi ulnaris, flexor digitorum profundus IV—V, adductor pollicis, abductor dig. V, flexor dig. V brevis, opponens dig. V, all interossei and lumbricales III—IV (CLARA).

The principal variations in innervation can be considered in relation to three different groups of muscles:

1. *The long finger flexors:* Here the median may, in extreme cases, take part in the innervation of all deep flexors. On the other hand the ulnar may supply the deep flexors of the middle finger, and, in rare cases, even of the index, as well as more or less the superficial flexors also.

2. *The thenar muscles:* MAUSS & KRÜGER (1920) pointed out that opposition of the thumb may be almost normal in cases of

median paralysis. Careful investigations of this have been made by HIGHET (1943) who analyzed 20 cases of complete lesion of the median, and who established that the ulnar took part in the innervation of flexor pollicis brevis in no less than 16 cases, of opponens pollicis in 4 cases and of abductor pollicis brevis in 2 cases.

3. *Interossei and lumbricales:* In paralysis of the former there is a loss of abduction and adduction of the fingers while a paralysis of the latter produces the characteristic clawing ("Krallenhand", "main en griffe", "teacup pinky").

The function of the lumbricales is to flex the basal phalanges of the fingers and, at the same time, to extend the distal phalanges. When this function is paralyzed, the corresponding fingers assume a position caused by the antagonistic muscles with hyperextension of the proximal phalanges (extensor digitorum communis) and flexion of other phalanges (flexor digitorum sublimis and, as far as it functions, profundus). The clawing embraces a varying number of fingers, depending on the size of the innervation area of the ulnar. When the ulnar nerve takes part in the supply of the whole of the lumbricales the characteristic claw-shape is found from the 2nd to the 5th fingers. Should all the lumbricales be supplied by the median, a total rupture of the ulnar nerve may cause no anomalies in the position of the fingers.

In consequence of the above we may state that a "typical ulnar paralysis" does not exist in the same sense as a "typical radial paralysis". On the contrary, complete ulnar paralysis may show very varying features. GIRAUD (1920) described a number of different types of anomalies in the position of the fingers caused by ulnar paralysis. To show the position he uses a formula which will be used below, modified to a certain extent. The fingers are numbered 1 to 5, a normal phalanx position is indicated by 0, extension (= hyperextension) by E, flexion by F. A high and very high degree of flexion or extension is indicated by means of + and ++ respectively. The phalanges are arranged in the following order: basal phalanx, middle phalanx and terminal phalanx, and the position is estimated at the moment when the patient tries actively to extend his fingers.

GIRAUD in his investigations has established two principal types of anomalies in the position of the so-called paralytic claw-hand. One occurred as a consequence of high ulnar lesion where all muscles supplied by the ulnar were paralyzed and was ex-

pressed by the formula 4—5: E F F, viz. the 4th and the 5th finger hyperextended in the basal phalanx and flexed in the middle and the terminal phalanx. With a slight ulnar lesion, in which function of the long finger flexors was intact, he described the position as 4—5: E F+ F+, thus the 4th and the 5th finger hyperextended in the basal phalanx with marked flexion in the middle and the terminal phalanges. The difference in the position of the fingers with a high, as distinct from a low lesion, is shown principally by the more marked flexion of the fingers in the low type of paralysis. This can easily be understood and explained

Fig. 1. Ulnar paralysis, type O.

by the fact that the power of flexion in low paralysis is considerably greater than in high paralysis, when only flexors supplied by the median nerve function. When a greater number of ulnar paralysis are examined, it will soon be found out that the types established by GIRAUD represent only two of the many variations which may occur. I have, therefore, more closely analyzed the position anomalies with material of in all 152 cases of ulnar paralysis treated in 1944 and 1945 in the Finnish Red Cross Hospital. Only cases with a good passive motility in all phalanges have been considered in order to avoid anomalies of the position caused by anchylosis or contracture. The material comprises 87 high lesions with the nerve injured above the elbow and all muscles supplied by the ulnar paralyzed. In 65 cases the lesion either lies below the elbow, thus allowing the long finger flexors to function, or they are late stages of complete high ulnar paralysis, where the long flexors have recovered their function either spontaneously or as a result of an operation, the condition thus corresponding to a low lesion with paralysis of the small muscles of the hand, supplied by the ulnar, only.

An examination of the material gives the following types of position anomalies, divided below into four groups, indicated by 0, I, II and III:

Table 1.

		High lesions:	Low lesions:	Total:
Type 0:	No anomalies in the position of the fingers except the loss of abduction and adduction in the ulnar fingers (mostly only in the little finger which assumes a light abduction position) caused by paralysis of the interossei.	8	2	10
Type I:	Anomalies in the position of the fingers IV—V:			
	5: O F F	3	—	3
	5: E F F	10	1	11
	5: E F+ F	—	1	1
	4—5: O F F	1	—	1
	4—5: E F F	22	21	43
	4—5: E F+ F	7	3	10
	4—5: E F++F	4	5	9
Type II:	Anomalies in the position of the fingers III—V:			
	3—5: O F F	1	—	1
	3—5: E F F	6	3	9
	3—5: E F+ F	8	6	14
	3—5: E F++F	1	2	3
Type III:	Anomalies in the position of the fingers II—V:			
	2—4: E O O; 5: E F F	—	1	1
	2—5: E F F	9	5	14
	2—5: E F+ F	5	10	15
	2—5: E F++F	2	5	7
	Total	87	65	152

In accordance with the above assumption that the claw-hand is principally caused by the loss of function of the lumbrical muscles, the following degree of innervation of these muscles is established:

Table 2.

Type 0:	All lumbricales supplied by the median nerve	10 cases	(7 %)	
Type I:	Lumbr. IV supplied by the ulnar nerve	15 »	(10 %)	51 %
	» III—IV » » » » »	63 »	(41 %)	
Type II:	» II—IV » » » » »	27 »	(18 %)	
Type III:	» I—IV » » » » »	37 »	(24 %)	
	Total	152 cases	(100 %)	

The decisive influence of the small muscles (especially of the lumbricales) on the production of the claw-hand is strikingly apparent in cases of combined median and ulnar lesions where the

flexion of the fingers, as long as the paralysis is total, is completely destroyed. The following table comprises a group of 20 median-ulnar lesions showing the position of the fingers at a moment when a recovery of the function of all long flexors has already occurred (either spontaneously or as a result of an operation) all small muscles of the hand still being paralyzed. The system of classification same as above.

Table 3.

Type I:	4—5: E F F	1 case
Type II:	3—5: E F F	3 cases
Type III:	2—5: E F F	5 »
	2—5: E F+ F	7 »
	2—5: E F++F	4 »
	Total	20 cases

The distribution of types in this material, small that it is, shows clearly that the great majority of the ulnar-median lesions during the stage of recovery gradually yield a position corresponding to type III, a natural result of the fact that all long flexors function, the small muscles being paralyzed. GIRAUD gives the position 2—5 E F F as the type corresponding to low median-ulnar lesions. This position diminishes gradually during recovery and is finally replaced by the normal position.

The flexion of the fingers is completely independent of the extent to which the lumbricales function and depends only on the long flexors. There is a surprisingly great number of cases where all fingers are flexed till the tip touches the palm even in cases when the ulnar innervation area is large. Among the 87 high ulnar lesions 11 cases were found, in which the tip of the little finger when flexed remained at a distance of $^1/_2$—2 cm from the palm, while both the 4th and the 5th finger showed imperfect flexion in 9 cases. In all remaining 67 cases the flexion was total though, in several cases, the terminal phalanges remained more or less unflexed. Among the low lesions 15 cases with an imperfect flexion of the 4th and 5th or the 5th only were observed which must be attributed to a direct injury of the muscle, as a low lesion of the nerve naturally cannot influence the function of the long flexors.

The function deficiency in ulnar paralysis may be much more distinctly established by measuring *the power of flexion*, which almost always seems to be greatly reduced, than by the flexion movement itself. I have made dynamometric examinations in 56

cases. The results are recorded in the following table. The strength of the uninjured hand is indicated by 1 and the strength of the injured hand by fractions of this unit:

Table 4.

Strength	High lesion	Low lesion	Total
1/1	—	1	1
3/4	1	5	6
2/3	4	2	6
1/2	10	11	21
1/3	3	5	8
1/4	6	1	7
1/5	2	1	3
< 1/5	2	2	4
	28	28	56

As could be expected the table shows a somewhat smaller reduction in strength where there are low lesions with functioning long flexors than where there are high lesions.

There are two circumstances which reduce the reliability of these numbers to some extent. With material which is insured against accidents, like the above, one cannot exclude the possibility that a deficient may to some extent yield results showing in general a significant decrease in strength. Apart from this it happens that if the dynamometer does not let the patients get an effective grip the results were worse than if the patient squeezed some other object, *c. g.* the hand of the examiner. The dynamometric examination is certainly not an ideal method for the measurement of the strength of the hand but there is no better one available. To register the flexion strength in each finger separately, like POLLOCK does, gives no idea of the total strength of the whole hand.

An investigation into the influence of the different types of finger positions on the strength of the hand shows the following result:

Table 5.

Strength	0	I	II	III	Total
1/1	1	—	—	—	1
3/4	—	3	1	2	6
2/3	—	1	2	3	6
1/2	1	9	4	7	21
1/3	—	2	2	4	8
1/4	—	2	1	4	7
1/5	—	1	—	2	3
< 1/5	—	2	1	1	4
Total	2	20	11	23	56

A more obvious reduction in strength with the more serious position anomalies can thus not be demonstrated.

An inquiry among the the 56 cases which were more closely investigated, as to the degree of disablement shows that the most common and most frequently made complaint is the reduced strength of the hand. In cases of more serious clawing (especially type III) where the interphalangeal joints are strongly flexed, the complaint is that the grasp is hampered through the failure of active extension of the flexed fingers and thus of grasping a desired object. In serious cases the patients state that they have to place the objects between the flexed fingers and the palm with the assistance of the sound hand. This applied especially to late stages of combined median-ulnar lesions and cases of type III.

A general complaint is also *a feeling of "clumsiness"* in the hand, particularly by work demanding greater precision. An effort to find out to which extent patients with ulnar lesions were able to do certain exact movements, showed that buttoning small buttons with the aid of the injured hand was successfully achieved in 55 cases out of 56, one failing (type III: 2—5: E F++ F, one of the most marked claw-hands of the whole material). All others succeeded in buttoning three buttons in succession, though at varying speed, in all cases considerably slower than with the uninjured hand.

It was characteristic that the more marked the clawing was, the worse the task was performed. Patients with the finger position 0 or I mostly succeeded, using usually at least the fingers I—III, while patients belonging to type III in particular had serious difficulties and tried to manage with the fingers I—II only.

Regarding *the ability to write* two of the 27 patients with the right hand injured stated that they had started writing with the left hand after the injury. Of the above, in 10 cases the patient had observed no important reduction in the writing ability (2 of them belonging to type III!), while the remaining 15 patients complained of serious difficulties, though not enough to force them to change over to the other hand. The impaired grip of the thumb-index was regularly given as a cause of reduced writing ability. Several patients had tried and even succeeded to eliminate this impediment by holding the pencil between the 2nd and 3rd fingers. The writing was in most cases distinctly better when produced in this manner.

Amongst all the cases which were examined more closely as

regards impediment, it appeared that one patient only (type 0) did not complain of the effect of his injury. Objectively, the power was normal and all movements were carried out fully, except for the abduction and adduction of the 4th and 5th finger. Further the flexion of the terminal phalanges of the 4th and the 5th finger, on clenching the fist, was incompete. A patient with a complete lesion (type I, right hand) said that he still played the piano. This is remarkable, in that ulnar paralysis in pianists, and also in surgeons, is considered to cause a very high degree of disablement (ENGELEN).

According to the now generally accepted principles for the treatment of injuries causing paralysis in the peripheral nerves, one must ensure that the paralyzed muscles are protected against hyperextension, which soon leads to irreparable changes in the muscle substance, thus making the result of a continued treatment utopian. In an ulnar paralysis the small muscles of the hand are the most severely damaged. Through clawing, the lumbricales and the interossei also, to some extent, will be subject to a continual stretching which is most dangerous for their eventual restitution. For years innumerable projects for an ulnar splint have been put forward but evidently it has not been easy to develop an effective and suitable form. Consequently the result of an operative treatment of ulnar lesions has in many cases been so poor that the usefulness of an operation is questionable. The experiences of ulnar nerve suture at the Finnish Red Cross Hospital shows that the function of the long muscles supplied by the ulnar (flexor carpi ulnaris and, generally, flexor digitorum prof. of the 4th and the 5th finger) returns almost as frequently as after a suture of other nerves, as for instance, of the radial and median. A failure of the small muscles to function is, however, almost invariably observed still one year after the injury; and even in cases examined later this function has been missing or imperfect, because, in all probability, the degeneration of the muscles had advanced too far to allow any restitutio ad integrum. As the position of the hand and the fingers is not influenced by the regained function of the flexors (at least not in a positive direction) the patient gains very little advantage from the actual improvement which has taken place.

A type of splint which seems suitable for ulnar paralysis, is one used since 1944 at the Finnish Red Cross Hospital. The principle was originally reported by OVERGAARD. The splint, which

Fig. 2. Ulnar paralysis, type I (4—5:EFF), without and with splint.

Fig. 3. Ulnar paralysis, type III (2—5:EFF), without and with splint.

Fig. 4. Ulnar paralysis, type III (2—5:EF+ F), without and with splint.

can be seen in the pictures, 2—4, and which resembles the "knuckle-duster" splint of HIGHET, is made like a clasp which is applied straight across the hand over the metacarpophalangeal joints, the basal phalanges of the fingers being pressed downwards from their hyperextension to a straight or a slightly flexed position. This enables the patient to extend his fingers more or less completely, the clawing disappears and the stretching of the small muscles likewise.

An examination of the 30 cases of this material which were supplied with the splint described above, shows that the clawing disappeared completely in 19 cases and was considerably reduced in 10 cases. Should the splint be made separately to suit each

case, which, owing to the present lack of material, has not always been possible, it is probable that the position of the fingers can be completely corrected as long as anchylosis and contractures have not set in. In only one case was no noteworthy improvement of the position observed. In this case the hyperextension in the basal phalanges was very slight (4—5: 0 F F) and thus the splint could hardly be of any effect.

Although there is, up to now, no information as to the established influence of the correction of the position, which must, naturally, commence at an early stage, the use of the splint must be considered justified as it prevents hyperextension of the paralyzed muscles. The result of an inquiry among the 30 patients who used the splint, also speaks in its favour. Half of these patients stated that they worked better with than without the splint. In most cases it was the finer work which was affected, because the rough grip of the hand was to some extent hampered by the inner part of the splint. It should further be mentioned that no less than 13 of the 19 totally corrected cases belonged to type III.

Summary.

An examination of 152 cases of ulnar paralysis shows that there is no position anomaly characteristic for this paralysis. There are numerous types which have been divided into four main groups indicated by 0, I, II and III. 10 cases (7 %) of this material belonged to type 0, these cases showing no clawing at all. Type I, position anomalies of the 4th and 5th fingers, comprised 78 cases (51 %), type II was represented by 27 cases (18 %) with changes in the 3rd to the 5th fingers, type III containing 37 cases (24 %) with more or less marked clawing in the 2nd to the 5th fingers. The decisive factor for the creation of a claw-hand is the paralysis of the lumbricales which show considerable variations in their innervation. The strength of the grasp is reduced in 4/5 of the cases to at least one half, though the loss of strength is not directly proportional to the degree of clawing. The more marked the clawing, the more limited is the usefulness of the hand for finer manual work. A splint of the clasp type seems to give the best guarantee for the neutralization of the pathological position of the fingers and thus also of the hyperextension of the paralyzed

muscles. Moreover it influences in about one half of the cases positively the capacity for work of the patients, especially fine manual work.

Zusammenfassung.

Die Untersuchung eines Materials von 152 Fällen von Ulnarislähmung zeigt, dass es keine für diese Lähmung typische Stellungsanomalie gibt, sondern dass eine Unzahl von Typen vorkommen, welche in vier mit 0, I, II und III bezeichnete Hauptgruppen eingeteilt wurden. Der Gruppe 0 gehörten von dem vorliegenden Materiale 10 Fälle (7 %) an, die überhaupt keine Krallenhand aufzeigten. Typ I, Stellungsanomalien der vierten und fünften Finger, umfasst 78 Fälle (51 %). Typ II der sich auf die Finger III bis V bezieht, wurde von 27 Fällen (18 %) vertreten, während schliesslich Typ III, wo sich die sämtlichen Finger II—V in einer mehr oder weniger ausgeprägten Krallenhandstellung befanden 37 Fälle (24 %) umfasste. Von entscheidender Bedeutung für die Entstehung der Krallenstellung ist die Lähmung der Lumbrikalmuskel, welche also bedeutende Variationen in Bezug auf die Innervation aufweisen. Die Kraft des Handgriffes ist in 4/5 der Fälle wenigstens auf die Hälfte herabgesetzt, der Einbuss an Kraft steht in keiner direkten Proportion zu dem Grade von Krallenhand. Je ausgeprägter die Krallenstellung ist, umso beschränkter ist im übrigen bei feineren Arbeiten die Brauchbarkeit der Hand. Eine Schiene vom Schnallentypus scheint die besten Garantien für die Aufhebung der pathologischen Stellung der Finger und dadurch auch der Überdehnung der gelähmten Muskel zu bieten. Sie wirkt ausserdem in ungefähr 50 % der Fälle erhöhend auf die Arbeitsfähigkeit des Patienten ein, besonders wenn es sich um feinere Fingerarbeit handelt.

Résumé.

Un examen des materiaux comprenant 152 cas de paralysie ulnaire nous prouve qu'il n'existe pas d'anomalie de position typique de cette paralysie, mais qu'il y en a des quantités de types différents qui ont été divisés en quatre groupes principaux appelés 0, I, II et III. 10 des cas (7 %) traités par nous et appartenant au groupe de types 0, ne présentait aucun signe de

position de griffe. Le I:er type comprenant des anomalies de position du quatrième et cinquieme doigt, comptait 78 cas (51 %), le type II traitant des troisième—cinquième doigts était représenté par 27 cas (18 %), tandis que le type III où tous les doigts II—V avaient une position de griffe plus ou moins marquée, comprenait 37 des cas (24 %). C'est la paralysie des muscles lombrieaux qui est décisive pour le développement de la position de griffe, et ces muscles montrent donc des variations considérables quant à la nervation intérieure. La force des mains est dans 4/5 des cas diminuée au moins de la moitié, la perte de force n'est pas en proportion directe avec le degré de la position de griffe. L'usage qu'on peut faire de la main pour les travaux délicats diminue d'ailleurs de plus en plus dès que la position de griffe est plus nette. Une éclisse du type boucle paraît le mieux garantir la cessation de la position pathologique des doigts et, en même temps, la ductilité outrée des muscles paralysés, et augmente en outre dans environ la moitié des cas la capacité de travail du malade, surtout pour les travaux plus délicats faits à l'aide des doigts.

References.

CLARA, M.: Das Nervensystem des Menschen. Leipzig 1942. — ENGELEN: Ärztl. Sachverst. ztg 1920: *26:* 102. Quoted from Z. org. Chir. 1920: *8:* 126. — GIRAUD, G.: Progrès méd. 1920: *48:* 113. — HIGHET, W. B.: Lancet 1942: I: 555. — HIGHET, W. B.: Journ. of Neurol. and Psych. 1942: *5:* 101. Quoted from Brit. Med. Bull. 1943: *1:* 76. — MAUSS and KRÜGER: Bruns' Beitr. 1920: *108:* 143. — OVERGAARD, J.: Private information. — POLLOCK, L.: Motor Disturbances in Peripheral Nerve Lesions. The Medical Departement of the United States Army in the World War. Vol. XI: 866. Washington 1927.

Aus dem Provinzkrankenhaus Lappland.
(Chefarzt: Dr. O.-E. CEDERBERG.)

Beiträge zur Kenntnis über das Vorkommen von Echinokokkus-Fällen in Finnland.

Von

O.-E. CEDERBERG.

Unsere heutige Kenntnis über die Echinokokkus-Affektionen gründet sich auf schon recht umfangreich und vielseitig gewordene, überall in der Welt gesammelte Statistiken, und gleichzeitig hat die biologische Entwicklung und das klinische Bild dieser Affektion schon bis in zahlreiche Einzelheiten ihre endgültige Klärung gefunden (BECKER, DEVÉ, FINSEN, FALTIN, HOSEMAN, LEHMAN, MACGILLIWRAY, MADELUNG, MAGNUSSON, PERICIC, POSSELT, SCHWARZ, SIEVERS, SIMON, J. D. THOMAS u. a. m.). Aus diesem Grunde scheint es, dass die in diesen Kreis gehörenden kasuistischen Mitteilungen kaum mehr anderes zu bieten haben als einen verhältnismässig bedeutungslosen quantitativen Beitrag. Wenn der Unterzeichnete es dessen ungeachtet für angebracht gehalten hat, im Folgenden zwei von ihm in Nordfinnland beobachtete und behandelte Echinokokkus-Fälle zu besprechen, so basiert dieser Entschluss vor allem auf der Auffassung, dass unsere Kenntnis von dieser parasitären Affektion vielleicht doch nicht ganz so lückenlos ist, dass es nicht möglich wäre, noch weiterhin einige Ergänzungen beizubringen. Solche können ausserdem noch Bedeutung haben als ein Hinweis auf das immer mögliche Vorkommen dieser seltenen Affektionen bei uns. Um die unnötige Wiederholung schon bekannter Tatsachen zu vermeiden, beschränke ich mich im Folgenden darauf, nur solche klinische Züge zu berühren, die besonderes Interesse haben in diesem Zusammenhang.

Die Echinokokkus-Infektion ist, wie bekannt, schon seit Jahrtausenden (HIPPOKRATES, GALEN u. a.) als ein »mystischer Krank-

heitszustand dunkler Herkunft« in der medizinischen Welt bekannt gewesen, aber ihre Ursache und Entwicklung ist bis zur zweiten Hälfte des vorigen Jahrhunderts ein ungelöstes Problem geblieben (HOSEMAN). Mit Hilfe vieler aufeinander folgenden Fütterungsversuche gelang es damals, bindend zu beweisen, dass es sich um eine eigentümliche parasitäre Infektion, morbus sui generis, handelte, deren biologischer Entwicklungsverlauf sich vor allem auf den im Dünndarm des *Hundes* lebenden, *geschlechtlichen*, sog. *Hundebandwurm* gründete, dessen zweite Entwicklungsphase als eine besonders in der Leber des *Schafs* eingenistete *ungeschlechtliche* aber doch wachstums- und ausbreitungsfähige *blasenbildende* Binnenstufe weiterging, von welcher Form diese Affektion ihren eigentlichen Namen erhalten hat (v. BENEDEN, FINSEN, KÜCHENMEISTER, NAUNY, v. SIEBOLD, POSSELT, SIEVERS, VIRCHOW u. a. m.). Die mit den Exkrementen der Hunde abgegangenen Echinokokkus-Embryonen verunreinigen gewöhnlich Rasenplätze, Wiesen, Gärten, Trinkwasser usw., wodurch sich ihnen die Möglichkeit eröffnet, in den Verdauungskanal, vor allem pflanzenfressender Tiere, zu gelangen. Einem Teil der Embryonen gelingt es schliesslich, in erster Linie durch Vermittlung der Pfortadersystem, in die Leber des infizierten Wirts zu gelangen (DEVÉ, HOSEMAN, LEHMAN, LERCKART u. a.), wo sie dann typische Blasenbildungen zu entwickeln beginnen. Später können die Hunde oft wieder Schlachtabfälle von infizierten Tieren bekommen, und damit sind die notwendigen biologischen Voraussetzungen für einen neuen Kreislauf in der Entwicklung des Echinokokkus-Parasiten geschaffen.

Obwohl der *Hundebandwurm*, wie schon der Name sagt, vor allem den Verdauungskanal des Hundes bevorzugt, wird dieser Parasit auch bei anderen, vor allem bei vielen dem Hunde verwandten Tieren angetroffen, wie der Wolf, der Schakal, der australische Wildhund, Dingo. Wichtig ist aber, dass auch unsere *Hauskatze* Echinokokkus-Infektionen vermitteln kann (HOSEMAN, LEHMAN, POSSELT). Wie allgemein die E-Infektion bei den Hunden sein kann, beweist THOMAS' Statistik aus Australien, nach welcher dort bis 50 % der Hunde als von diesem Parasit infiziert ermittelt wurden (LEHMAN). Von den Pflanzenfressern haben sich besonders die *Schafe* als für die Echinokokkus-Infektion am meisten empfänglich erwiesen, und neben diesen Wirten ist die Bedeutung z. B. des Rindes und des Schweins viel bescheidener (HOSEMAN). Zu dieser Serie haben meine Fälle ihren eigenen in-

teressanten Beitrag zu bieten. Es wirkt nämlich sehr wahrscheinlich, *dass auch das lappische Renntier — möglicherweise auch Elche — als ein solcher am biologischen Kreislauf des Echinokokkus beteiligter »Blasen-Wirt« funktionieren könnte.*

Meine beiden Echinokokkus-Infektionen wurden nämlich im Kreis solcher *Renntierlappen* festgestellt, welche selbst keinerlei Schafzucht betrieben, sondern ihren Viehbestand bildeten lediglich die Renntiere, die sie zusammen mit ihren wachsamen Hunden das ganze Jahr hindurch hüteten. Aller Wahrscheinlichkeit nach ist die Echinokokkus-Infektion in meinen Fällen durch eben diese Renntierhunde vermittelt worden, denn meine beiden Patienten berichteten, dass ihre Hunde ihnen oft die Hände und sogar das Gesicht lecken durften, und es war auch nicht selten, dass sie das Essgeschirr reinlecken durften. Die gleichen infizierten Hunde haben natürlich ihre Parasiten weiter an die Renntiere weitergegeben, wahrscheinlich durch die Vermittlung des *Renntiermooses*, und bei den jährlichen grossen Renntierschlachtungen konnten die parasitenhaltigen Schlachtabfälle wiederum von den Hunden gefressen werden, so dass auch hier charakteristische biologische Kreislauf in der Entwicklung der Echinokokkus-Infektion erreicht wurde. *Da ich bis jetzt keine Erwähnung über den möglichen Anteil des Renntiers als Verbreiter der Echinokokkus-Infektion gesehen habe* (SCHWARZ), *ist es angebracht, die praktische Bedeutung und Konsequenz dieser Beobachtung zu unterstreichen.*

Wenn wir den zentralen Anteil bedenken, welchen gerade die von Hunden unterstütze Schafzucht als Verbreiter der Echinokokkus-Infektion hat, lässt sich schon theoretisch voraussetzen, dass überall dort in der Welt, wo sich die Viehwirtschaft in erster Linie auf die Schafzucht beschränkt, auch die Echinokokkus-Infektion am häufigsten ist. Diese Annahme ist durch statistische Untersuchungen als berechtigt bestätigt worden. Den Spuren intensiver Schafzucht folgt immer grosse Echinokokkus-Gefahr. Es ist klar, dass ausserdem allzu enge Verhältnisse in den Wohnungen, Unreinlichkeit, mangelhafte Hygiene und vor allem Unwissenheit oder Gleichgültigkeit hinsichtlich der drohenden Ansteckungs-Gefahr, einige andere wichtige Faktoren darstellen, welche die Verbreitung dieser Infektion begünstigen.

Die grössten Echinokokkus-Statistiken auf europäischem Gebiet sind demnach in *Island* angetroffen worden, wo Schafherden festgestellt worden sind, von welchen nahezu die Hälfte infiziert

sein konnte (FINSEN, MAGNUSSON, SCHWARZ, THOMSEN), und desgleichen in *Dalmatien*, wo die Schafzucht ebenfalls einen wichtigen Erwerbszweig darstellt (LALIC, HOCHE, PERICIC, SCHWARZ u. a. m.). Seit altersher sind auch die Schafzuchtgebiete in *Mecklenburg* als deutliche E-Herde in Mitteleuropa bekannt gewesen (BECKER, MADELUNG, HOSEMAN, SCHWARZ u. a. m.). Auch in *Spanien*, besonders in den Küstengegenden, sind zahlreiche E-Gebiete endemischer Natur angetroffen worden. Von den aussereuropäischen Ländern dürfte als E-Zentrale *Australien* am wichtigsten sein (J. D. THOMAS, v. LENDENFELD, MACGILLIWRAY, POSSELT, SCHWARZ u. a. m.). Desgleichen hat die blühende Schafzucht in *Argentinien* auch reichliche E-Infektionen mit sich gebracht (CRANWELL u. VEGAS, SCHWARZ u. a.). Die *westlichen Küstengegenden Nordafrikas*, wo ebenfalls seit Jahrhunderten ausgedehnte Schafzucht betrieben worden ist, bilden weiterhin deutliche Herde auf den Frequenzkarten über die Verbreitung dieses Parasiten (SCHWARZ).

Bis jetzt sind die *skandinavischen* Länder, soweit man weiss, von eigentlichen *Echinokokkus-Epidemien* verschont geblieben (HENSCHEN, SIMON, SCHWARZ). In Norrland, in Schweden, konnten jedoch irgendwelche kleinere E-Infektionen endemischer Natur beobachtet werden (SIMON), aber sonst hat das Auftreten dieser parasitären Krankheit in den nordischen Ländern — zum Glück — ein ziemlich zufälliges, sporadisches Gepräge. Diese Feststellung trifft zwar im grossen und ganzen gewissermassen wohl auch für unsere entsprechenden Verhältnisse zu, aber dessen ungeachtet dürfte die von dem Echinokokkus-Kenner, Prof. E. SCHWARZ, im 40. Band der Neuen Deutschen Chirurgie (1928) dargelegte Auffassung über unsere diesbezüglichen Verhältnisse zu mangelhaft und irreführend sein. Seiner Ansicht nach sollte die Echinokokkus-Infektion in Finnland »ganz besonders selten« sein, weil er in unserer Literatur *nur einen einzigen*, von KROGIUS beobachteten und im Jahre 1907 publizierten E-Fall finden konnte. In Wirklichkeit ist unsere E-Kasuistik bedeutend reichlicher, denn schon vor dem Jahre 1914 sind in unserem Lande laut FALTIN's Untersuchung mindestens 16 Echinokokkus-Fälle beobachtet und gemeldet worden (v. BONSDORFF, DICKSTRÖM, FAGERLUND, FALTIN, GADD, EHRNROOTH, HENRICKSSON, HJELT, O. E. A., HOMÉN, KOLSTER, KROGIUS, LAITINEN, v. NUMERS, PIPPINGSKIÖLD, SIEVERS, STAUDINGER, WESTERLUND, WINTER). Die letzte Erwähnung über unsere Echinokokkus-Fälle ist, meines Wissens, die von MIKKONEN im Jahre 1935 im Duodecim veröf-

fentlichte Mitteilung, wo er berichtet über eine im Maria-Krankenhaus in Helsinki beobachtete, von BARDY operierte *Lungen-Echinokokkus*, wobei er gleichzeitig erwähnt, dass der gleiche Operateur schon früher (1916) einen anderen E-Fall behandelt habe. Danach würde die Anzahl der bis 1935 in unserem Lande beobachteten und veröffentlichten Echinokokkus-Infektionen also auf insgesamt 21 steigen. Da ich später erfahren habe, dass mindestens im Allgemeinen Krankenhaus in Kemi vor ungefähr zwei Jahren ein Leber-Echinokokkus behandelt worden ist (AALTO-SETÄLÄ), und wenn ich zu den früheren noch meine im Folgenden darzustellenden Fälle hinzufüge, so sind bis jetzt in Finnland insgesamt *24 klinische Echinokokkus-Infektionen* mit Sicherheit festgestellt und behandelt worden. Dieses Resultat gibt zu hoffen, dass die obengenannte Auffassung von SCHWARZ über die Echinokokkus-Frequenz in Finnland seinerzeit revidiert wird.

Wie aus dem Obigen hervorgegangen ist, hat die Echinokokkus-Infektion, womit hier lediglich der *Echinokokkus-Cysticus-Typ* gemeint ist, zum Unterschied von der selteneren *Echinokokkus-Alveolaris-Form* (POSSELT), eine nicht zu unterschätzende Bedeutung auch in der Menschenpathologie, weil dieser Parasit verhältnismässig leicht sowohl in den menschlichen Körper gelangen als sich auch dort einnisten kann. Als eigentliche Überträger der Infektion wirken auch hier vor allem unsere treuen Freunde, die Hunde (FALTIN, HOSEMAN, LEHMAN, POSSELT, SCHWARZ u. a.). Infolge der Unwissenheit und Unvorsichtigkeit können virulente E-Embryonen auf *oralem Wege* in den Darmkanal des Menschen gelangen, und so hat diese heimtückische Infektion die wichtigste Etappe gewonnen. Neben der durch *die vom infizierten Fell* des Hundes *verunreinigten Hände* oder durch dessen *embryohaltigen Speichel* vermittelten *direkten Übertragung* ist wahrscheinlich die Ansteckungs-Gefahr, die z. B. im Genuss infizierter Milch, Trinkwassers, Gemüse oder zu wenig gekochtem, blasenhaltigem Fleisch, enthalten ist, wesentlich geringer (FINSEN, HOSEMAN, MAGNUSSON, LEHMAN, SCHWARZ). Als eine eigenartige Ausbreitung dieser Infektion verdient Erwähnung die noch im vorigen Jahrhundert besonders in Mecklenburg beliebte Unsitte, bei gastrischen Beschwerden unter dem Namen »Piluli Graeci« (PAULLINI) bekannte aus Hundefäkalien hergestellte Magenmittel zu geniessen (HOSEMAN).

FRANGENHEIM gibt uns ein ausserordentlich anschauliches Beispiel davon, wie stark eine solche, gerade durch den Hund ver-

mittelte E-Infektion sein kann, indem er über einen Fall berichtet, wo eine Frau, die an eitriger Brustentzündung litt, auch eine typische E-Mastitis bekam, nachdem sie ihren Hund die schmerzende Brust lecken liess.

Die meisten Echinokokkus-Kenner sind der Ansicht, dass die Infektion meistens schon im *frühen Kindesalter* stattfindet, zu einer Zeit also, wo es dem Hund leichter möglich ist, seinen unverständigen und unvorsichtigen Spielkameraden anzufassen (FINSEN, MAGNUSSON, HOSEMAN, POSSELT, THOMSEN u. a. m.). Da die Entwicklung der E-Blasen gewöhnlich sehr langsam ist, oft jahrelang dauert, und weil die Symptome lange Zeit hindurch entweder ganz gering sein können, oder auch klinisch latent bleiben, wird dieser Parasit oft erst im späteren Alter festgestellt (FINSEN, HOSEMAN, LEHMAN, POSSELT u. a.).

Die wichtigste Entwicklungsstelle der E-Zysten ist auch im menschlichen Körper das *Lebergewebe*. Die Sektionsstatistiken zeigen, dass ca. 70—80 % der E-Infektionen sich gerade in der Leber einnisten (BECKER, FALTIN, GARRÉ, LEHMAN, MIKKONEN, TEICHMANN u. a. m.). Die nach der Leber am meisten bevorzugte Niststelle bilden die *Lungen* mit 7—10 % (LEHMAN, MIKKONEN) und dann folgen in absteigender Reihenfolge die *Milz*, die *Bauchspeicheldrüse*, die *Nieren*, die *Gedärm-* und *Bauchhöhle*, das *Muskel-* und *Knochengewebe* usw. (FALTIN, GARRÉ, LEHMAN, SCHWARZ, TEICHMANN, THOMAS). Dass die Leber von den E-Embryonen als Nistplatz besonders begünstigt wird, erhält seine natürlichste Erklärung dadurch, dass die in den Zwölffingerdarm gelangten und in dessen Schleimhaut festgebissenen Embryonen sich durch die Darmwand hindurchfressen können und dann in dem Lymph- und vor allem in den Blutkreislauf des Pfortadersystems dringen, durch deren Vermittlung sie gerade in die Leber gelangen, deren rechter Lappen in erster Linie zu dem von diesen Parasiten infizierten Zentrum wird (GARRÉ, FINSEN, HOSEMAN, LEHMAN, LEUKART, POSSELT). Ausserdem sei noch eine andere Ausbreitungsmöglichkeit erwähnt, die darauf beruht, dass die Embryonen in die Zweige der Venae haemorrhoidales eindringen, und durch diese in die untere Hohlvene getrieben werden, so dass sich ihnen damit die Möglichkeit zu unbegrenzter Metastasierung eröffnet. Dennoch scheinen sich die auf diesem Wege in unseren Organismus eingedrungenen Echinokokkus-Embryonen meistens *gerade im Lungengewebe* einzunisten (LEHMAN, MIKKONEN, POSSELT).

Die meisten unserer Fälle in Finnland sind überzeugende Be-

weise für die Häufigkeit der in der Leber eingenisteten E-Infektionen. Die von KROGIUS beobachtete, durch Echinokokkus erzeugte *Knochenmetastase*, die von v. BONSDORFF observierte *Nierenmetastase* und die von MIKKONEN erwähnte Blasenbildung in den *Lungen* sind meines Wissens die sichersten bis jetzt bei uns veröffentlichten *extrahepatischen* Parasiten-Lokalisationen. Bei allen anderen Fällen handelte es sich um einen primären Lebereehinokokkus oder in den Gallenwegen eingenistete E-Bildung (FALTIN, MIKKONEN), und von solcher Entwicklung sind auch meine eigenen Fälle erhellende Beispiele.

Fall I. 36-jähriger Renntierzüchter aus Sodankylä. L. L. S. Journ.-Nr. 1461, 1940.

Der Patient berichtet, dass er von Beruf Renntierzüchter ist, der sein ganzes Leben lang zusammen mit seinen Hunden Renntiere gehütet hatte. Schafzucht ist beim zu hause dagegen nicht betrieben worden. In den letzten Jahren hat er sich schwach und müde gefühlt. Der Appetit ist schlechter geworden und er ist abgemagert. Der Grund dafür, dass der Patient ins Krankenhaus kam, sind jedoch *die während der zwei letzten Jahre aufgetretenen 4 heftigen, akuten Anfälle von Bauchschmerzen*, die den Patienten zwangen, jedesmal mehrere Tage das Bett zu hüten. Ausserdem litt der Patient dann an Übelsein und Erbrechen. Er kann sich erinnern, dass wenigstens zweimal während der Anfälle *seine Haut gelblich* wurde. Während des letzten Anfalls kam er ins Krankenhaus von Sodankylä zur Behandlung, wo der Arzt ihn bei der Entlassung aufforderte, sich an einen Chirurgen zu wenden, um von seiner als *Gallensteinanfall* gedeuteten Krankheit befreit zu werden.

Im Krankenhaus der Provinz Lappland, in welches der Patient später zur Behandlung aufgenommen wurde, weisen die Untersuchungen ebenfalls gerade auf diese Affektion hin. Nach der Kontrast-Mahlzeit wird die Gallenblase im Röntgenbild überhaupt nicht sichtbar. Senkungswert = 31/47 mm. Sahli 71 %. Fieberfrei. Helm. und Harn —. In den Lungen wird trockenes Rasselgeräusch festgestellt. Bei der Palpation ist der Bauch im Hypogastrium empfindlich, aber irgendwelche deutliche, an die Gallenblase erinnernde Resistenz lässt sich nicht feststellen. *Die Klopfempfindlichkeit des Patienten im rechten Lendenrücken und die dort fühlbare Schwellung fallen dabei auf.* Der Patient unterzieht sich gern der vorgeschlagenen Operation.

CEDERBERG. *Laparotomia. Evacuatio et canalisatio cystae echinococcicae retroperitonealis reg. lumbalis dx.* Äther.

Mit einem langen rechtseitigen transrektalen Schnitt wird die Bauchhöhle geöffnet. Es wird festgestellt, dass die Gallenblase gespannt und am Oment, der oberen Schlinge des Duodenums und am Mesocolon fixiert ist, aber Konkremente können darin nicht festgestellt werden. Das Lebergewebe ist sowohl bezüglich des Aussehens als auch palpatorisch symptomlos. Die Aufmerksamkeit wird auf eine *in der Loge unter der Leber gelegene, von hinten prominierende, grosse, fluktuierende,*

retroperitoneale Resistenz gelenkt, welche sowohl die Leber als auch das Duodenum und die Fl. coli dextra gewissermassen in ventraler Richtung aufhebt. Der erste Gedanke wäre, dass es sich um einen eigenartigen *Congestions-Abszess* handeln könnte, aber wegen der palpatorisch ungewöhnlichen Beschaffenheit der Resistenz und *weil durch die sie bedeckende Peritoneal-Membran deutlich hellere und dunklere Schatten durchscheinen*, wird beschlossen, den Tumor jedoch zu punktieren. Hierbei wird in die Spritze eine klare, geruchlose Flüssigkeit eingesaugt, in welcher man bei der Betrachtung gegen das Licht für die E-Krankheit charakteristische kleine Hakenbildungen (*Scolices*) sieht.

Nach dieser Feststellung wird die in Frage stehende Zyste gespalten, wobei sich daraus reichliche Mengen klarer, geruchloser Flüssigkeit und eine grosse Anzahl *geplatzter, kleiner Zysten-Bildungen*, deren Grösse von der einer Erbse bis zu der einer Kirsche schwankt, entleert. Die *Schale* der geplatzten Zysten ist *verdicktes, geschwollenes* und oft *fast durchscheinendes Gewebe, das sehr an geplatzte, grosse Sagokörner erinnert*. Der Inhalt dieses Tumors wird *möglichst gründlich* entleert, und der ganze Innenraum wird mit einem scharfen Löffel reingeschabt. Ehe seine Ränder mit einer Catgut-Naht zusammengefügt werden, wird seine Innenfläche mit Jod-Lösung bestrichen, und der Hohlraum selbst wird durch eine gesonderte Öffnung *rückwärts* in den Lumbalrücken kanalisiert. Mit einigen Nähten wird noch das Mesocolon zur Verstärkung der Tumorsutur fixiert, und die Wunde in der Wand der Bauchhöhle wird schichtenweise exakt zugenäht.

Der Patient übersteht die Operation gut, und die Wunde heilt p. p. i., aber er bekommt in der entleerten Tumor-Höhle eine äusserst heftige *sekundäre anaerobe Infektion*, die später zu einer erneuten Eröffnung von hinten aus zwingt. In diesem Stadium bekam er ausserdem eine wahrscheinlich *reaktive*, purulente, wenn auch aseptische Pleura-Entzündung im unteren Teil der rechten Pleura. Auch diese Infektion geht jedoch mit Punktionsbehandlung zurück und beruhigt sich schnell, nachdem der oben erwähnte, retroperitoneale, putride Eiterprozess von neuem eröffnet und kanalisiert worden ist. Nach ungefähr zweimonatlicher Behandlung im Krankenhaus wird der Patient bei gutem Befinden zur Hauspflege entlassen, und zwei Jahre später war seine Gesundheit immer noch ausgezeichnet. Im Herbst 1944 erlag er jedoch einer galoppierenden Lungenschwindsucht, die sowohl durch Röntgen- als auch Bazillen-Untersuchung verifiziert wurde.

Fall II. 59-jährige Lappin aus Sodankylä. L. L. S. Journ.-Nr. 644, 1942.

Die Patientin berichtet, schon seit mindestens 20 Jahren sich irgendwie krank und schwach gefühlt zu haben, aber irgendwelche schwere, akute Schmerzanfälle hat sie niemals gehabt. Auch sie erzählt, sehr die Hunde zu lieben, die sie fast als Glieder der Familie betrachtete. Auch in diesem Hause wurde keine Schafzucht betrieben, sondern die Viehwirtschaft beschränkte sich auf die Renntiere. Die Patientin kam zur ärztlichen Behandlung und ins Krankenhaus vor allem deshalb, weil sie im Leib zunehmende Spannung gefühlt hatte, und beobachtete, dass

besonders die obere Partie des Bauches allmählich zunahm. Die Nahrungsaufnahme war ihr immer schwerer geworden, weil sie das Gefühl hatte, dass die Speise im Magen stehen bleibt. Auch nach den geringsten Mahlzeiten war das Epigastrium geschwollen, und ausserdem stellte sich Sodbrennen und oft auch Erbrechen ein. Am meisten war die Patientin jedoch angegriffen worden durch die *Atmungsbeschwerden* und das *heftige Herzklopfen*, welche auch von der geringsten körperlichen Anstrengung, Essen usw. hervorgerufen wurden.

Im Krankenhaus wird festgestellt, dass es sich um eine kurz gebaute Lappenfrau mit fast kugeligem Leib handelt. Deutlich zyanotisch. Thorax flach, breit, in der Vorderwand Ödem. Desgleichen ist in den Beinen, den Knöcheln und Füssen der Patientin reichlich Schwellung. Plattfüsse. Herz nach links disloziert. Besonders der obere Teil des Bauches ist gewaltig vorgewölbt und gespannt, und bei seiner Palpation wird festgestellt, *dass die ganze obere Partie durch eine gewaltige, unbestimmt begrenzte, bis unterhalb des Nabels reichende, ballotierende Resistenz ausgefüllt ist*, die nicht mit der Genital-Sphäre in Zusammenhang steht. Senkungswert = 19/41 mm. Sahli 62 %. W. R. —. Helm. —. Nieren o. B. Es wird gleich vermutet, dass der Tumor durch Echinokokkus hervorgerufen sein könnte, und diese Diagnose erweist sich als richtig bei der vor der Operation vorgenommenen Probepunktion, wo im Punktat *Scolices*-Bildungen gesehen werden. Wegen der durch den Tumor hervorgerufenen, die Herztätigkeit störenden und die Atmung erschwerenden Kompressions-Beschwerden wird beschlossen, schleunigst zur Operation zu schreiten.

Cederberg. *Laparotomia. Resectio partialis cystae echinococcicae permagnae. Evacuatio et canalisatio cystae regionis epigastricae.* Evipan-Narkose.

Die Operation verläuft ausgezeichnet in *Evipan*-Narkose, und es wurde nur 13 ccm verbraucht. Mit einem langen schrägen, linksseitigen Leberschnitt wird die Bauchhöhle geöffnet, wobei festgestellt wird, dass ihr oberer Teil vollständig von einer riesigen Zyste ausgefüllt ist, die fest an der Unterfläche der Leberlappen adhaeriert ist. Hinter dem Tumor liegen eingepresst und zusammengedrückt der Magen und die Darmpakete. Ebenso sieht man deutlich, dass die Zyste das Zwerchfell nach oben geschoben hat, indem sie besonders den linken Leberlappen zu einer *scheibenartigen »Kalotte«* komprimiert. Die Zyste wird gespalten, wobei daraus — trotz beträchtlichen Flüssigkeitsverlustes — ca. 13 L klare, geruchlose, wässrige Flüssigkeit gemessen worden kann, die reichlich für die E-Infektionen typische Scolices-Bildungen enthält. Eiweiss lässt sich darin nicht feststellen, aber beim Abkühlen kristallisieren sich daraus reichlich wahrscheinlich für *Bernsteinsäure* charakteristische Kristallbildungen. Ausser der Flüssigkeit werden daraus noch *mehrere Liter* erbsen- bis kirschengrosse, *geplatzte, geleeartige Bläschen* entfernt.

Der Versuch, diesen Tumor zu exstirpieren, erweist sich als undurchführbar, wegen seiner festen Adhaerierung an der Unterfläche der Leber und der durch diesen Versuch hervorgerufenen Blutungen und Rupturen. Vom Mesocolon und dem Ventrikel dagegen lässt er sich ver-

hältnismässig leicht abtrennen. Aus diesem Grunde begnügte man sich damit, den grössten Teil der Wände der Zyste zu resezieren, so dass nur ein trichterförmiger, der Basis des Tumors entsprechender Sack zurückbleibt, dessen Mündung an der Lateralecke der Operationswunde fixiert wird, und die Zystenhöhle wird mit einem dicken Drain kanalisiert. Vorher wird der Boden des Hohlraums mit einem Löffel möglichst reingeschabt und die Innenfläche mit Jodlösung bestrichen.

Unter der Wirkung der permanenten Kompression sind beide Leberlappen, an welchen der Boden der Zyste unablösbar befestigt ist, stark atrophiert, und besonders der linke Lappen ist — wie gesagt — zu einer dünnen, streifenartigen Platte zusammengepresst. Desgleichen ist der Magen zu einem kaum faustgrossen, gegen die Hinterwand der Bauchhöhle gepressten, beutelartigen Sack zusammengeschrumpft. Ebenso erinnern grosse Teile des Dünndarms und auch das Colon transversum mehr an den Darmkanal eines Kindes als eines Erwachsenen. Nur das Coecum und die im kleinen Becken gelegenen Darmschlingen sind von dieser durch den Tumor hervorgerufenen atrophierenden Kompression verschont geblieben.

Die Patientin übersteht die Operation ausgezeichnet und fühlt sich danach sehr erleichtert und die Atmungsbeschwerden und die Funktionsstörungen von Seiten des Herzens verschwinden auch schnell. Desgleichen wird die Nahrungsaufnahme leichter, und der Appetit bessert sich. Die Genesung wird auch hier durch eine in dem kanalisierten Zystenrest entwickelte, *heftige putride Infektion gestört*, die sich erst nach längeren täglichen desinfizierenden Spülungen beruhigt. Ungefähr 6 Wochen später wird die Patientin aus dem Krankenhaus zur Hauspflege entlassen, aber sie hat immer noch in der Wunde geruchlosen, eitrigen — wenn auch geringen — Fistelausfluss. Diese Sekretion erweist sich als sehr hartnäckig, denn noch ungefähr ein Jahr nach der Operation hat sie gemäss den von mir erhaltenen Mitteilungen zeitweilig Eiterausfluss aus der Wunde. Ihr Allgemeinbefinden ist jedoch gut gewesen, und es wurde mitgeteilt, dass sie mit dem Resultat der Operation sehr zufrieden war.

Epikrisis.

Hichsichtlich ihrer klinischen Entwicklung vertreten meine beiden Fälle von früherer bekannte, wenn auch stark voneinander abweichenden Krankheitstypen. Bei dem ersteren Fall standen im Vordergrund des Krankheitsbildes *akute, wahrscheinlich durch die Echinokokkus-Zysten erzeugte Verschluss-Anfälle im D. choledochus.* Die in Frage stehenden Koliken, die gemäss allgemeiner Erfahrung *verhältnismässig selten sind* gerade als durch diese Infektion hervorgerufene Komplikationen (Garré, Hoseman, Lehman u. a. m.), wirkten so deutlich wie Gallenstein-Stenosen, dass die E-Aetiologie vor der Operation überhaupt nicht in Betracht

gezogen wurde. MAGNUSSON bemerkt auch — ganz richtig — dass die unerlässliche Voraussetzung für die Echinokokkus-Diagnose gerade der Umstand ist, dass wir die Möglichkeit dieser parasitären Infektion bei der Analysierung der Ursache des Krankheitszustandes in Betracht ziehen.

Ob diese Verschlussanfälle durch in den Choledochus eingedrungene und dort eingekeilte E-Zysten hervorgerufen, oder ob sie Folgen der ausserhalb der Gallenwege entwickelten Kompression waren, lässt sich schwer sagen. Die feste Adhaerierung des in Frage stehenden lumbalen Tumors sowohl an der Gallenblase als auch am Unterrand der Leber und teilweise auch am Choledochus selbst kann vielleicht als ein Beweis dafür angesehen werden, dass sich möglicherweise E-Zysten in den Gallenwegen eingenistet und dort entleert und auf diese Weise Verschluss-Störungen hervorgerufen hatten, aber irgendwelche Fistel-Verbindungen konnten bei der Operation nicht festgestellt werden. Wenig glaubhaft wirkt es auch, dass der ausserhalb des Choledochus gelegene elastische Tumor derartige lokale, akute Komprimierung hätte erzeugen können, dass dadurch eine wirkliche Choledochus-Stenose entstünde. Auch die sog. spastischen Koliken wirken in diesen Verhältnissen nicht glaubhaft. Wahrscheinlicher wirkt die Entwicklungsmöglichkeit, *dass es sich dennoch um eine von dem intrahepatischen Echinokokkus-Herd abgelöste, solitäre, Zyste handeln könnte*, welche, nachdem sie sich langsam im D. choledochus eingenistet hat, dort eine typische Stenose erzeugte. Obwohl das Lebergewebe sowohl bezüglich seines Aussehens als auch palpatorisch symptomlos wirkte, ist es natürlich ganz gut möglich, dass es immer noch intrahepatische Blasenherde enthielt. Diese Theorie ist um so wahrscheinlicher, als die in Frage stehende retroperitoneale Tumorbildung vermutlich auch gerade infolge einer sekundären Progression aus der intrahepatischen E-Infektion entstanden ist.

Die langsame und lange Zeit relativ latent gebliebene Entwicklung des Krankheitszustandes in dem zweiten Falle ist gerade sehr typisch für den Entwicklungsverlauf dieser Infektion. Die meisten Forscher, welche diesen Verlauf verfolgt haben, sind sich einig darüber, dass gerade die langsame, in erster Linie nur unbestimmte, allgemeine Störungen erzeugende Entwicklung des Infektions-Prozesses für die im menschlichen Organismus eingenistete E-Infektion charakteristisch ist (GARRÉ, FINSEN, HOSEMAN, MAGNUSSON, LEHMAN, POSSELT u. a. m.). Es wirkt fast un-

glaublich, dass auch diese Patientin erst dann, als ihr Riesentumor Herzstörungen und Atmungsbeschwerden verursacht hat, sich an den Arzt wendet, und trotzdem ist sie sicherlich schon seit Jahren mit ihren 10—15 Liter Flüssigkeit von Bauch herumgelaufen. Dass es sich um eine *längere Kompressionswirkung* handeln muss, beweist die atrophierte und deformierte Form und Grösse der eingepressten Organe. Trotz ihres ungeheuren Ausmasses ist die von mir beobachtete Zyste kein Rekordfall, denn in der Literatur habe ich eine Mitteilung u. a. über eine nicht weniger als 48 Liter fassende Echinokokkus-Zyste angetroffen (Garré, Lehman, S. Sudakoff).

Die Deutung des Krankheitszustandes war in diesem Fall bedeutend leichter als im vorigen. Erstens einmal hatte schon unser früherer Fall den Gedanken der Möglichkeit einer E-Infektion erweckt, und da ausserdem bei objektiver Untersuchung sowohl die genitalen als auch die Nierentumoren von der Diagnose ausgeschlossen werden konnten, war der Kreis der ätiologischen Möglichkeiten schon recht begrenzt. Unser Verdacht wurde bestätigt durch die vor der Operation durchgeführte Probepunktion, vor welcher Eingriff zwar viele Kliniker in der Furcht einer Ausbreitung der Infektion warnen (Bardeleben, Garré, Magnusson, Lehman, Leisving u. a. m.). Andererseits wird allerdings zugegeben, dass, wenn die Punktion unmittelbar vor der Operation vorgenommen wird, die Gefahr einer Ausbreitung der Infektion wahrscheinlich recht gering ist (Garré).

Die heftige *anaerobe Infektion*, die sich in beiden Fällen in der geöffneten und kanalisierten Zystenhöhlung entwickelte, ist hinsichtlich ihrer ätiologischen Erklärung interessant. Es hat nämlich den Anschein, dass die Infektion kaum *exogenen Ursprungs* war, sondern wahrscheinlich war sie *schon latent in den E-Zysten verborgen gewesen*. Eine solche sekundäre Infektion dieser Zysten ist in der Entwicklung dieses parasitären Prozesses eine verhältnismässig gewöhnliche, *prognostisch ungünstige* Komplikation (Garré, Magnusson, Lehman), denn die Prognose wird im allgemeinen fast *um die Hälfte* schlechter, wenn sich diese Zysten sekundär infiziert haben (Garré, Magnusson, Lehman). Der von manchen Seiten gemachte Vorschlag, die evakuierte E-Zyste unkanalisiert zu lassen — *also exakte Primärsutur* — wirkte schon aus Vorsichtsgründen in diesen Fällen weniger verlockend und deshalb wurden die Zystenhöhlen nun kanalisiert. Die glückliche Genesung dieser Fälle — wo die operative Mortalität zwischen

ca. 30—50 % variieren soll (GARRÉ, LEHMAN) — dürfte zugunsten der Drainage sprechen.

Wie bekannt, sind die in Finnland bis jetzt festgestellten Echinokokkus-Fälle *sporadischer Natur* gewesen, indem sie sich geographisch verhältnismässig zufällig über das ganze Land verteilen. Diese Infektionen sind bis jetzt festgestellt worden in *Helsinki* (5), *Tampere*, *Viipuri*, *Kokkola*, *Kemi*, *Kittilä* (2), *Ruovesi*, *Tammela*, *Nivala*, *Pudasjärvi*, *Säkkijärvi* und *Lavansaari* (*Suursaari?*) (FALTIN, MIKKONEN). Die zwei letztgenannten Gegenden sind besonders interessant, weil dort auch viele Robbenhunde gehalten werden. Schon in dieser Serie fällt es auf, dass Lappland mit 2 Fällen vertreten ist, zu welchen noch Kemi und Pudasjärvi hinzukommen als Gegenden, in welchen Renntierzucht schon betrieben wird. Jedoch scheint es nicht unmöglich, dass einige E-Fälle ganz ausserhalb der Grenzen unseres Landes stammen (FALTIN, SIEVERS).

Der Umstand, dass im Verlauf verhältnismässig kurzer Zeit in dem gleichen nordfinnischen Krankenhaus 2 Echinokokkus-Fälle beobachtet werden, ist natürlich kein genügender Beweis dafür, dass es sich nun um eine von der sporadischen Natur abweichende Ansteckung E-Typus handelte, aber ganz unmöglich ist es selbstverständlich nicht, dass es sich vielleicht doch um eine auf eine kleine Endemie-Möglichkeit hinweisende Erscheinung handeln könnte. Für die in Nordfinnland tätigen Ärzte sind meine Fälle jedenfalls eine heilsame Erinnerung daran, dass es angebracht ist, dort besondere Beachtung auch *der Echinokokkusmöglichkeit* zu schenken. Diese Fälle sind ausserdem auch eine Aufforderung an die dortigen Gesundheitsbehörden, die für die Nahrungswirtschaft bestimmten Renntier-Produkte besonders scharf auf diese gefährliche parasitäre Krankheit hin zu kontrollieren. *Wie überall ist auch hier die Prophylaxe als Abwehr und Behebung des Unglücks wichtiger als die Therapie.*

Zusammenfassung.

Der Verfasser beschreibt in seiner Abhandlung zwei im Provinzkrankenhaus Lappland in Nordfinnland im Verlauf verhältnismässig kurzer Zeit von ihm beobachtete und behandelte, unter den sog. *Renntierlappen* vorgekommene *Echinokokkus-Fälle*. Er nennt die wichtigsten heutzutage bekannten E-Herde in Europa und den übrigen Erdteilen und stellt fest, dass in Skandinavien,

bis jetzt, soweit man weiss, noch keine eigentliche Echinokokkus-Epidemie vorgekommen ist, sondern die hier festgestellten Fälle sind mehr oder weniger sporadischer Natur gewesen.

Diese Feststellung betrifft auch die Verhältnisse in Finnland, wo bis jetzt, wenn man die vom Autor referierten Fälle mitrechnet, *24 klinische Echinokokkus-Fälle* mitgeteilt worden sind. Dieses Resultat weicht bedeutend ab von der von SCHWARZ im 40. Band der D. Chir. im Jahre 1928 vorgeführten Auffassung, wonach in Finnland nur ein einziger Echinokokkus-Fall (KROGIUS) festgestellt worden wäre. In Wirklichkeit waren schon damals mindestens insgesamt 20 Echinokokkus-Infektionen beobachtet worden.

Bei dem ersten vom Verfasser dargestellten Fall stehen im Vordergrund des Krankheitsbildes *wiederholte, akute und heftige, an Gallenstein-Koliken erinnernde abdominale Schmerzanfälle*, im zweiten Fall wurde bei dem Patienten eine an der Unterfläche *der Leber befestigte Riesenzyste* festgestellt, und die dadurch hervorgerufenen *Atmungsbeschwerden* und *Funktionsstörungen des Herzens* waren die eigentliche Ursache dafür, dass der Patient sich in klinische Behandlung begab. Beide Fälle wurden operiert, und bei dem letzteren wurde die Diagnose schon vor der Operation gestellt. Bei dem ersteren Fall wurde im rechten Lendenrücken *eine grosse retroperitoneale Tumorbildung* gefunden, wo ausser grossen Flüssigkeitsmengen eine grosse Anzahl geschwollener, geplatzter, weichschaliger *Blasen* angetroffen wurde, deren Grösse von der einer Erbse bis zu der einer Kirsche schwankte. Der retroperitoneale Tumor wurde inzidiert, evacuiert, reingeschabt, mit Jodlösung bestrichen, sorgfältig zur Peritonealhöhle hin suturiert und nach hinten in den Lendenrücken kanalisiert. Der Autor vermutet, dass der in Frage stehende Tumor kaum die Ursache für die Kolik-Anfälle des Patienten gewesen sei, sondern dass sie durch *kleine Solitär-Zysten hervorgerufen wurden, die sich aus einem latenten intrahepatischen Echinokokkus-Herd abgelöst hatten, in den D. choledochus eingewandert und dort festgekeilt waren.*

Beim letzteren Fall wiederum handelte es sich um eine riesenhafte *intra-abdominale Zystenbildung*, welche den grössten Teil der Bauchhöhle ausfüllte. Der Boden der Zyste war weitläufig und unlöslich an der Unterfläche der Leberlappen fixiert, von welchen besonders der linke unter der Wirkung der zunehmenden Kompression *zu einer flachen, plattenartigen Bildung atrophiert war.*

Da auch diese Zyste nicht radikal exstirpiert werden konnte, begnügte man sich mit ihrer Entleerung, wobei aus ihrem Inhalt u. a. *13 Liter* klare, geruchlose Flüssigkeit gemessen wurde, in welcher sich nach dem Erkalten reichlich *Kristalle der Bernsteinsäure* zeigten. Ausserdem sah man darin reichlich typische Hakenbildungen (Scolices). Weiterhin entleerten sich auch aus dieser Zyste mehrere Liter geplatzte Solitär-Zysten von der gleichen Art wie in dem ersteren Fall. Die Ränder der Riesenzyste wurden so reseziert, dass nur eine schmale, beutelartige, an der Leber befestigte Bildung übrig blieb, deren Öffnung in die eine Lateral-Ecke der Operationswunde geführt, dort fixiert und nach aussen kanalisiert. Ebenso wie im ersteren Fall wurde die Zystenhöhlung mit dem Löffel möglichst reingeschabt und mit Jod-Lösung bestrichen.

Beide Fälle genasen glücklich von ihrer Krankheit, aber ihre Heilung wurde verzögert durch eine *eigentümliche putride Infektion*, die sich jedoch nur auf die geöffnete und entleerte Zystenbildung beschränkte. Der Verfasser nimmt an, dass diese Entzündung *endogenen Ursprungs* war, indem eine in den Echinokokkus-Zysten schon früher latent verborgen gewesene Infektion zum Ausbruch kam.

Der Verfasser ist seinerseits zu der Auffassung gekommen, dass, wenn auch in beiden Fällen ohne Zweifel die *Hunde* Überträger der Echinokokkus-Infektion gewesen sind, diese ihrerseits die Ansteckung von infizierten *Renntieren* bekommen hätten. Es wirkt nämlich sehr wahrscheinlich, *dass auch das Renntier, bzw. Elche, zu denjenigen Pflanzenfressern zu zählen ist, welche als »Wirte« im biologischen Kreislauf des Echinokokkus-Parasiten in Frage kommen können.* Diese Beobachtung, über welche der Verfasser keine Angaben in der Echinokokkus-Literatur gefunden hat, ergänzt in interessanter Weise die Reihe der Pflanzenfresser, welche als Wirte des Blasenstadiums der E-Infektion fungieren können, von welchen bekanntlich das *Schaf* immer noch die wichtigste Rolle spielt.

Die bis jetzt in Finnland festgestellten Fälle sind sämtlich mehr oder weniger sporadischer Natur gewesen, und der Autor hält sich nicht für berechtigt, auf Grund der von ihm beobachteten Fälle zu behaupten, dass sie als Ausdruck einer drohenden Echinokokkus-Endemie, noch weniger einer E-Epidemie anzusehen seien. *Dennoch sind sie besonders für die in Nordfinnland tätigen Ärzte eine zeitgemässe Erinnerung an das Vorhandensein auch dieser In-*

fektion und eine Warnung für die Behörden, die Möglichkeit in Betracht zu ziehen, dass auch die Renntierprodukte vom Echinokokkus infiziert sein können.

Summary.

In his treatise the author describes two cases of Echinococcus which he has observed and treated in the Lappland County Hospital in North Finland and which occurred amongst the so-called *Reindeer Lapps.* He mentions the most important Echinococcus nests which are known to us in our days in Europe and other parts of the world and confirms that hitherto in Scandinavia, as far as one knows, no real Echinococcus epidemic has occurred and that the cases established here have been more or less of a sporadic nature.

This also confirms the conditions in Finland where hitherto, if the cases referred to by the author are included, 24 clinical cases of echinococcus have been reported. This result differs considerably from the opinion expressed by SCHWARZ in Vol. 40 of the D. Chir. of 1928, according to which only one case of echinococcus (KROGIUS) was established. Actually a total of 20 echinococcus infections had been observed at that time.

In the first of the two cases referred to by the author the predominant features of the disease are *repeated, acute and intense attacks of abdominal pains suggestive of biliary colic,* in the other case the picture showed an enormous cyst adhering to the lower surface of the patient's liver although the *difficulties in breathing* and the *functional disturbances* of the heart caused by this were the real reasons for making the patient seek clinical assistance. Both cases were operated; diagnosis in the second case was established before the operation. In the first case a large retroperitoneal tumorous mass was encountered in the right lumbar region in which was found, besides a large quantity of fluid, a great number of swollen, cracked, soft-coated *blisters* varying in size from a pea to a cherry. The retroperitoneal tumour was encised, emptied, scraped clean, painted with a solution of iodine, sutured carefully to the peritoneal cavity and canalized posteriorly into the loin. The author supposes that the tumour in question could hardly be the cause of the patient's attacks of colic but that these were *brought about by small solitary cysts which were freed*

from a latent intra-hepatic echinococcus nest, wandered into the choledoch and wedged themselves there.

In the other case it was a matter of a gigantic *intra-abdominal cyst formation* which filled the greatest part of the abdominal cavity. The bottom of the cyst was broad and immovably fixed to the under surface of the lobes of the liver of which the left especially, under the influence of the increasing pressure, *atrophied to a smooth flattish formation.* As it was not possible to extirpate this cyst radically, one had to be satisfied with emptying it, in doing which there was measured, amongst other things from the contents, 13 litres of a clear odourless liquid, in which, when it cooled down, there was a profuseness of *succinic acid crystals.* In addition a vast quantity of typical hook-formations (scolices) were found. Further, many litres of cracked solitary cysts, similar to those in the first case, were evacuated from the cyst. The edges of the giant cyst were resected in such a way that only a small pouch-like formation remained adhering to the liver the opening of which was led to the one lateral corner of the operation-wound, where it was fixed and drained outwardly. As was done in the first case, the cavity of the cyst was scraped as clean as possible with a scoop and painted with a solution of iodine.

Both cases happily recovered from their illness, but the process of healing was delayed by a *curious putrid infection* which, however, confined itself to the opened and emptied cyst formation. The author supposes that the inflammation was of an *endogenous origin* in that one of the earlier latently hidden infections in the echinococcus cysts made itself manifest.

The author has personally come to the conclusion that even if *dogs* were the doubtless carriers of the echinococcus infection they, in their turn, had been infected by infected *reindeer.* It seems rather probable that *reindeer are also to be included in the herbivora which can come into the question as being hosts in the biological cycle of the echinococcus parasite.* This observation, about which the author has not found any information in echinococcus literature, adds, in an interesting manner, to the range of herbivora which can function as hosts for the blister stage of echinococcus infection and amongst which, as is known, the *sheep* continues to play the most important rôle.

Those cases which hitherto have been established in Finland have all been of a more or less sporadic nature and the author

does not consider that he is justified in maintaining, on the basis of the cases observed by him, that they should be considered as an expression of a threatening echinococcus endemic even less so as an echinococcus epidemic. *At the same time they are, for the active medical practitioner in North Finland especially, an actual reminder of the occurrence of the infection and a warning for the authorities to regard the possibility that products originating from reindeer can be infected with echinococcus.*

Résumé.

Dans son mémoire, l'auteur décrit deux cas d'échinococcose qu'il a observés et traités au cours d'une période relativement courte à l'hôpital départemental de la Finlande du nord et dont étaient affectés *deux lapons propriétaires de rennes.* Il mentionne les foyers d'échinococcose connus en Europe et dans le reste du monde; il constate que jusqu'ici et pour autant qu'on le sache, la maladie n'a pas eu un caractère épidémique en Scandinavie; les cas dont il s'agit ici ont eu un caractère plutôt sporadique.

La même remarque s'applique à la Finlande où, compte tenu des cas rapportés ici par l'auteur, on n'a fait état que de *24 cas cliniques d'échinococcose.* Ce chiffre diffère notablement de celui adopté par Schwarz dans le 40e volume de D. Chir. 1928 suivant lequel on n'aurait observé en Finlande qu'un seul cas (Krogius) de la maladie. En fait, on avait observé alors déjà une vingtaine de cas d'infection par échinocoque.

Dans le premier cas exposé par l'auteur, *des crises douloureuses abdominales répétées, aiguës et violentes, rappelant des coliques hépatiques,* dominaient l'image clinique; dans le second cas, il a constaté chez son malade la présence d'un kyste géant adhérente à la face inférieure du foie; les troubles qui en résultaient: *dyspnée et troubles fonctionnels du cœur* amenèrent le malade à la consultation. Opération dans les deux cas; dans le second, le diagnostic fut fait avant l'opération. Dans le premier cas, on trouva dans la région lombaire droite une *volumineuse tumeur rétropéritonéale;* dans l'abondant liquide qu'elle contenait nageaient un grand nombre de *vésicules* gonflées, éclatées, à coque molle dont la grosseur variait de celle d'un pois à celle d'une cerise. On incisa, vida, cureta, badigeonna à la teinture d'iode, sutura avec soin vers la cavité péritonéale et draina dans la région lombaire. L'au-

teur admet que ce n'est pas la tumeur elle-même qui fut la cause des coliques ressenties par le malade, mais que celles-ci furent causées par des *vésicules secondaires qui se sont détachées d'un foyer latent intra-hépatique d'échinocoque, ont émigré dans le canal cholédoque où elles sont restées prises.*

Dans le second cas, il s'agissait d'un kyste géant intra-abdominal qui occupait la plus grande partie de la cavité péritonéale. La base de la tumeur était large et scellée à la face inférieure des lobes du foie dont le gauche surtout avait, par suite de la compression grandissante, *subi une atrophie qui l'avait réduit à l'état de plaque à surface lisse.* Comme dans ce cas-ci l'extirpation radicale était aussi impossible, force fut de se contenter de vider le kyste; il contenait *13 litres* d'un liquide transparent, inodorant dans lequel se formèrent, lorsqu'il se fut refroidi, de nombreux *cristaux d'acide succinique.* On y trouva également de nombreux scolex. On évacua en outre plusieurs litres de vésicules-filles ayant le même caractère que celles observées dans le premier cas. On excisa le kyste de telle sorte à ne laisser qu'une bourse étroite, adhérente au foie; on en fixa l'ouverture à l'extrémité latérale de l'incision abdominale et on la draina vers l'extérieur, après avoir cureté la cavité aussi soigneusement que possible et l'avoir badigeonnée à la teinture d'iode.

Les deux malades se rétablirent complètement, mais leur convalescence fut retardée par une singulière infection putride qui se limita cependant au kyste ouvert et vidé. L'auteur admet que cette infection était de *nature endogène* et existait auparavant à l'état latent dans les kystes.

L'auteur a acquis la conviction que, si dans les deux cas, ce sont des chiens qui ont été les intermédiaires de l'infection, celle-ci leur a été transmise par des rennes. Il est vraisemblable que le renne appartienne lui aussi aux *herbivores qui peuvent servir d'hôtes dans le circuit biologique* de l'échinocoque parasite. Cette observation qui semble encore unique en son genre, complète de façon intéressante la liste des herbivores qui peuvent servir d'hôtes au stade vésiculaire de l'infection par échinocoques et parmi lesquels la mouton continue à jouer le rôle le plus important.

Les cas observés jusqu'ici en Finlande ont tous été de nature plus ou moins sporadique et l'auteur ne se sent pas fondé sur la base des cas qu'il a observés, à prétendre qu'il faille les considérer comme le symptome avant-coureur d'une endémie et moins encore d'une épidémie d'échinococcose. *Toutefois — ceci vaut sur-*

tout pour les médecins pratiquant en Finlande septentrionale — ils sont un avertissement de l'existence de cette sorte d'infection; cet avertissement s'adresse aussi aux autorités qui doivent prendre en considération le fait que les produits provenant du renne peuvent être une source d'infection à échinocoques.

Litteraturverzeichnis.

AALTO-SETALA, E.: Nach müntl. Mttng. — BATREAM & ROUSSEN: R. Zorg. Chir. 1932. — BECKER, H.: Bruns Beiträge. Bd. 56. — CAPELLE, W.: Hdb. prakt. Chir. (GARRÉ—KÜTTNER—LEXER). Bd. III. 1923. — DEMEL, R.: Chirurg. Diagnostik. W. Maudrich. Wien 1943. — DEVÉ: Revue d. Chir. 1924. Cit. LEHMAN. — DREW, H.: Surgery. N:o 2. s. 363—380. 1937. — FALTIN, R.: F. L. H. *1914. s. 279. Bd. 56. — FINSEN, A.: Schmidts Jahrbücher. 1867. Cit.* SCHWARZ. — FRANGENHEIM, P. Samml. Vortr. (VOLKMAN). Chirurgie 1906. Bd. 116—117. N. F. 419, 420. — FRIEDRICH, H.: Med. Klin. Bd. 34. s. 1220—1222. — GARRÉ, C.: Hdb. prakt. Chir. (GARRÉ—KÜTTNER —LEXER). Bd. III. s. 707. 1923. — GERULANOS, M.: R. Zorg. Chir. 1930. — HARTMAN, H.: R. Zorg. Chir. 1930. — HELLER, E.: Die Chirurgie (KIRSCHNER & NORDMAN). Bd. V. s. 157. Urban & Schwarzenberg. Wien 1931. — HENL, F.: Arch. klin. Chir. Bd. 184 s. 458—65. 1939. — HJELT, O. E. A.: F. V. Soc. F. H. 1864. p. 58. — HOCHE, O. Zbl. Chir. Bd. 63. s. 502—507. 1936. — HOCHE, O.: Zbl. Chir. Bd. 63. s. 1589—1592. 1936. — HOCHE, O.: Chirurg. Bd. 9. s. 469—480. — HOSEMAN, G., SCHWARTZ, E., LEHMAN, und POSSELT, A.: Die Echinokokken-Krankheit. N. D. Chir. Bd. 40. F. Enke 1928. Stuttgart. — HOSEMAN, G.: Die Chirurgie (KIRSCHNER & NORDMAN) Bd. II. s. 352 —69. Urban & Schwarzenberg. Berlin—Wien. — HOSEMAN, G.: Med. Klin. 1916. N:o XII. s. 308. — HÖRL, A.: R. Zorg. Chir. 1928. — JARMOPOULOS, D.: Chirurg. Bd. 11. s. 405—407. — KROGIUS, A: F. L. H. Bd. 49. 1907. — KLEINSCHMIDT, O.: Operat. Chirurgie. J. SPRINGER, Berlin 1942. — LEHNE, W.: D. Arch. Klin. Med. Bd 52. Cit. LEHMAN. — MAGNUSSON, G.: Zbl. Chir. s. 479. 1913. — MAGNUSSON, G.: Zbl. Chir. s. 1363. 1914. — MAGNUSSON, G.: Arch. klin. Chir. Bd. 100. — MIKKONEN, H.: Duodecim N:r 2. 1935. — MADELUNG, H.: Münch. Med. Wschr. N:o 39. 1903. — MOST, A.: D. Ztschr. Chir. Bd. 48. — MILLER & COLLINS: Ann. Surgery. Bd. 105. s. 881—895. 1937. — NORDMAN, O.: Prakt. d. Chirurgie, Springer. Berlin 1940. — OEHLECKER, W.: Zbl. Chir. 1910. N:o 36. — PERICIC, B.: Wiener. Klinik. N:o 5. 1907. Cit. SCHWARZ. — POSSELT, A.: Münch. med. Wschr. N:o XII, 1906. — RUDOIJ, E.: R. Zorg. Chir. 1929. — SIEWERS, R.: F. L. H. 1903. Bd. 48. s. 39. — TEICHMANN, H.: Dissertatio. Halle 1898. Cit. LEHMAN. — TOOLE, H.: Arch. Klin. Chir. Bd. 188 s. 459—465. 1937.

De l'hôpital orthopédique d'assistance aux invalides de Finlande.
(Chirurgien en chef: prof. F. LANGENSKIÖLD.)

L'effet de la sympathectomie sur le fantôme douloureux d'un amputé.

Par

AARRE ELLONEN.

C'est un fait connu depuis des siècles qu'après l'amputation totale ou partielle d'un membre, la personne amputée se fait une idée plus ou moins nette du membre enlevé. On a attribué ce phénomène exclusivement au fonctionnement du système nerveux central et on y a vu la preuve d'une projection excentrique même lorsque les parties périphériques des nerfs sensitifs ont été détruites. Certains ont voulu nommer ce phénomène une illusion et même une hallucination et particulièrement les psychologues y ont porté le plus grand intérêt. La science médicale lui a donné le nom de fantôme, c.-à-d. l'illusion de présence du membre amputé.

On entend donc par le phénomène du fantôme le fait que les amputés continuent presque tous à percevoir le membre absent comme s'il était toujours là, collé contre le moignon, en entier ou en partie ou quelquefois comme rapetissé. Ce fantôme apparaît le plus clairement immédiatement après l'amputation et s'estompe d'habitude peu à peu pour finalement disparaître tout à fait.

Le fantôme est en règle générale ressenti plus clairement que le membre normal. Immédiatement après l'amputation la perception est tellement vive que les amputés ne croient pas à l'amputation avant d'avoir constaté visuellement l'absence du membre enlevé. Souvent la perte d'un membre est oubliée longtemps, ce qui amène les amputés à vouloir s'appuyer sur une jambe inexistante ou à se servir d'une main disparue. De ces manifesta-

tions du fantôme on ne peut cependant guère dire autre chose qu'elles constituent une sensation légèrement troublante ou tout au plus désagréable.

Le phénomène du fantôme n'aurait pas, par lui-même, tant d'importance pratique pour la science médicale, s'il n'était pas accompagné par un état douloureux se manifestant dans une ou plusieurs parties du fantôme. Cet état douloureux peut être continu ou intermittent. Il dépend dans une grande mesure des variations climatiques et se fait sentir surtout avant ou durant le mauvais temps.

Il est souvent le plus intense au moment des selles ou au lever du lit. Un pareil état est propre à augmenter les souffrances d'un invalide, car il provoque souvent des insommies et un emploi exagéré de médicaments ou bien encore l'alcoolisme et le morfinisme. Dans certains cas la douleur provoquée par le fantôme a, en dépit de tous les soins donnés, conduit au suicide.

Etant donné que l'état douloureux dû au fantôme n'est ressenti souvent que subjectivement sans présenter des indices quelquonques, les invalides peuvent souvent être l'objet de conceptions erronnées même de la part des médecins. Pour ne pas accuser les malades de simulation chaque médecin devrait porter son attention sur ce phénomène.

Les premiers qui aient fait du phénomène du fantôme l'objet d'études scientifiques sont Guéniot (1861) et Weir-Mitchel (1872). Ce n'est qu'après la première guerre mondiale que ce phénomène a été généralement connu. Au début il a été étudié surtout par les psychologues. Entre autres Katz (1920) s'est livré à de vastes recherches dans ce domaine. Il est arrivé à la conception qu'au point de vue psychologique il faudrait voir dans le fantôme une manifestation hallucinatoire, puisque l'état douloureux provoqué par lui est quelquefois continu et augmente selon l'attention que porte sur lui le malade. Katz considère cependant qu'il manque à ce phénomène une base de pathologie cérébrale. Par la suite (1940), Katz a affirmé que la forme définitive du fantôme provient des résidus physiologiques se trouvant dans le système nerveux central.

Gallinek (1931) a attribué le phénomène du fantôme en partie à une excitation périphérique, en partie à une manifestation partiellement indépendante de cette excitation et déterminée dans une certaine mesure par des facteurs centraux.

Head (1920) a, de son côté, affirmé que la sensation du propre

corps est en majeure partie indépendante des sensations périphériques instantanées et que l'indépendance de cette sensation mérite d'être considérée comme «postural and tactual schema».

Les différents aspects du phénomène du fantôme comprennent indubitablement des éléments psychologiques intéressants qui toutefois ne rentrent pas dans le cadre de la présente étude. Rappelons cependant encore l'œuvre de KATZ «Gestaltpsychologi» dans laquelle l'auteur attribue le phénomène du fantôme à des réminiscences d'origine centrale.

NIILO MÄKI voit également dans ces réminiscences un facteur important du phénomène du fantôme, mais dans des conversations ultérieures avec l'auteur de cette étude il a admis aussi la possibilité d'une influence périphérique.

Au point de vue physiologique le phénomène du fantôme a été étudié, e. a., par EEVA JALAVISTO (1943). Elle l'explique par le schéma corporel invariable ou, autrement dit, par l'invariabilité de l'image qu'on se fait de son corps.

Parmi les pathologues qui ont porté intérêt sur les répercussions d'une amputation sur le système nerveux central citons HOMÉN (1890). En amputant des chiens il a constaté des conséquences pathologiques dans le système nerveux central et notamment dans la substance grise de la moëlle épinière, où les altérations et les disparitions des cellules doivent être considérées comme les suites de fonctions interrompues.

LERICHE (1932) est le premier chirurgien ayant donné une description scientifique étendue et détaillée de divers états douloureux soignés par lui. Dans son ouvrage fondamental qui fait époque «La chirurgie de la douleur» (1937) il écrit sur la douleur en général: «Il y a, à l'origine de beaucoup de douleurs une action sympathique, puisque, en suspendant, par un toxique, l'action du système autonome, on fait disparaître la douleur.» LERICHE paraît être le premier qui se soit rendu compte que la douleur habituelle causée par le fantôme ainsi que toute l'illusion de présence du membre absent peuvent disparaître en insensibilisant ou en bloquant le nerf sympathique. Les sensations et les états douloureux sont classés par lui de la manière suivante:

I. Le phénomène normal: l'illusion de présence du membre amputé.
II. L'illusion douloureuse du membre absent.
III. La douleur sympathique du moignon.

IV. La grande hyperesthésie douloureuse des moignons.
V. Un phénomène incompréhensible: la douleur instantanée et persistante dans le membre absent.

Recherches personnelles de l'auteur.

Encouragé par le professeur F. LANGENSKIÖLD, chef de l'hôpital orthopédique d'assistance aux invalides de Finlande,[1] j'ai entrepris ce travail ayant pour but d'éclaircir le rôle que joue le nerf sympathique non seulement dans les états douloureux causés par l'illusion d'un membre amputé, mais dans ce phénomène en général. Je n'aurais peut-être pas porté mon attention sur la deuxième question, s'il n'y avait pas eu un cas où le blocage du sympathique a fait disparaître, avec les douleurs causées par le fantôme, toute sorte d'illusion gênante de présence du membre amputé.

Mes observations ont été faites au hasard du 1:er mars jusqu'au 30 juin 1944 en soignant dans l'hôpital des malades atteints d'une manière continue ou passagère de douleurs de fantôme. Selon la gravité des cas je les ai classés en absolus, c.-à-d. états continus qui troublent sérieusement le sommeil, et en relatifs, c.-à-d. états intermittents n'ayant guère d'influence sur le sommeil. Ce classement est certainement arbitraire, puisqu'il existe des cas limites, mais il paraît justifié par des considérations d'ordre pratique. Dans les cas appartenant au premier groupe la guérison n'est intervenue qu'à la suite de sympathectomie. Dans les cas du deuxième groupe les soins ont été limités à des blocages répétés du grand sympathique.

Dans mes observations il y a eu 7 cas de sympathectomie dont 5 cas d'amputés de membres inférieurs et 2 de membres supérieurs. En plus, j'ai soigneusement examiné 7 cas de blocage du grand sympathique. Au total, 15 malades souffrant du fantôme ont subi l'interruption définitive ou passagère du fonctionnement du système nerveux sympathique.

En plus, j'ai fait subir à 13 malades souffrant du fantôme intermittant ou définitif l'anesthésie de la moëlle épinière afin d'établir si les nerfs spinaux ou les fibres péri-spinales du grand sympathique sont pour quelque chose dans le phénomène du fantôme. L'ensemble de mes observations porte donc sur 28 cas (tableau 1) qui ont fait l'objet d'une analyse détaillée du fantôme

[1] Je saisis ici l'occasion de remercier le prof. LANGENSKIÖLD de son encouragement et de l'intérêt qu'il a porté à mes recherches.

Tableau 1.

(Le terme fantôme est indiqué par la lettre «f»).

N:o d'ordre	Bulletin du malade	Partie amputée	Indications	Traitement	Résultat immédiat
1	46/VIII	Femur	Douleur totale provoquée par le f	Sympatectomia lumb.	La douleur disparut définitivement
2	43/VIII	»	»	»	»
3	253/VIII	»	»	»	»
4	60/IX	Pes (Chopart)	M. Raynaud et douleur partielle provoquée par f	»	»
5	172/VII	Brachium	Douleur totale provoquée par f	Cervic.	»
6	381/VIII	»	»	»	La douleur s'atténua
7	365/VIII	Pes (Lisfranc)	Ulcus styli et douleur partielle provoquée par f	Sympatectomia lumb.	La douleur disparut
8	383/VIII	Crus	Douleur totale provoquée par f	Exploratio reg. lumb.	La douleur ne disparut pas
9	183/IV	»	Douleur partielle provoquée par f	Blocage du sympathique	La douleur disparut passagèrement
10	281/I. S.	»	»	»	»
11	70/VII	»	»	»	»
12	211/VII	»	»	»	»
13	264/VI	Femur	»	»	»
14	220/IX	»	»	»	La douleur s'atténua
15	191/IX	Crus	»	»	La douleur disparut
16	91/IX	»	Amputation renouvelée	Anesthésie de la moëlle épinière	»
17	313/VII	»	»	»	»
18	109/VII	Femur	»	»	»
19	65/IX	Crus	»	»	»
20	398/VI	Femur	»	»	»
21	253/VIII	»	»	»	»
22	335/VII	Femur	»	»	»
23	220/VII	Crus	»	»	»
24	38/VII	»	»	»	»
25	327/VII	»	»	»	»
26	165/VII	Femur	»	»	»
27	90/VI	Crus	»	»	»
28	383/VII	»	Douleur totale provoquée le f	Curative	La douleur disparut presque entièrement

avant et après le traitement (voir la figure). Je n'ai pu me livrer à des observations ultérieures, dans chaque cas particulier que durant 2 à 4 mois.

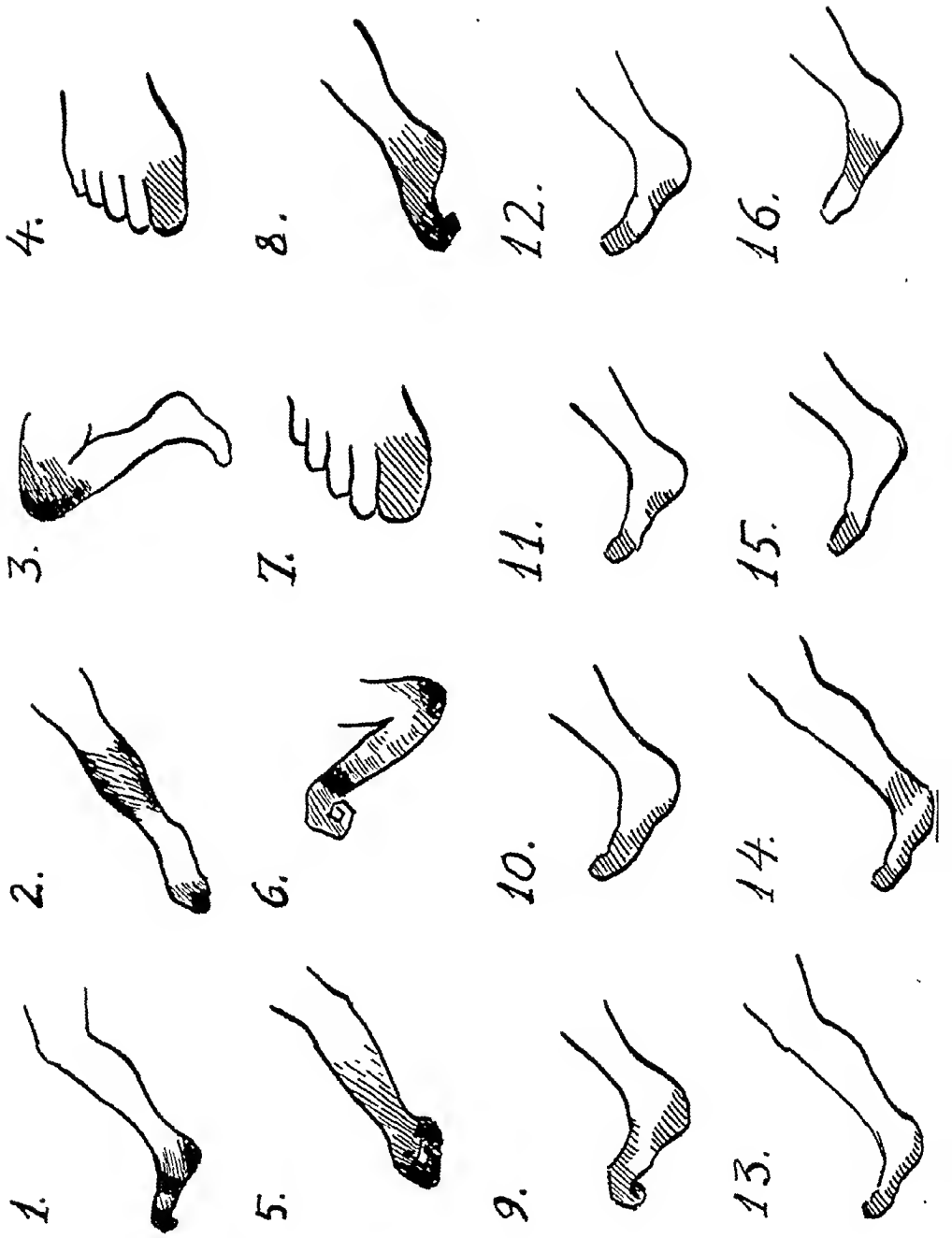
1.
2.
3.
4.
5.
6.
7.
8.
9.
10.
11.
12.
13.
14.
15.
16.

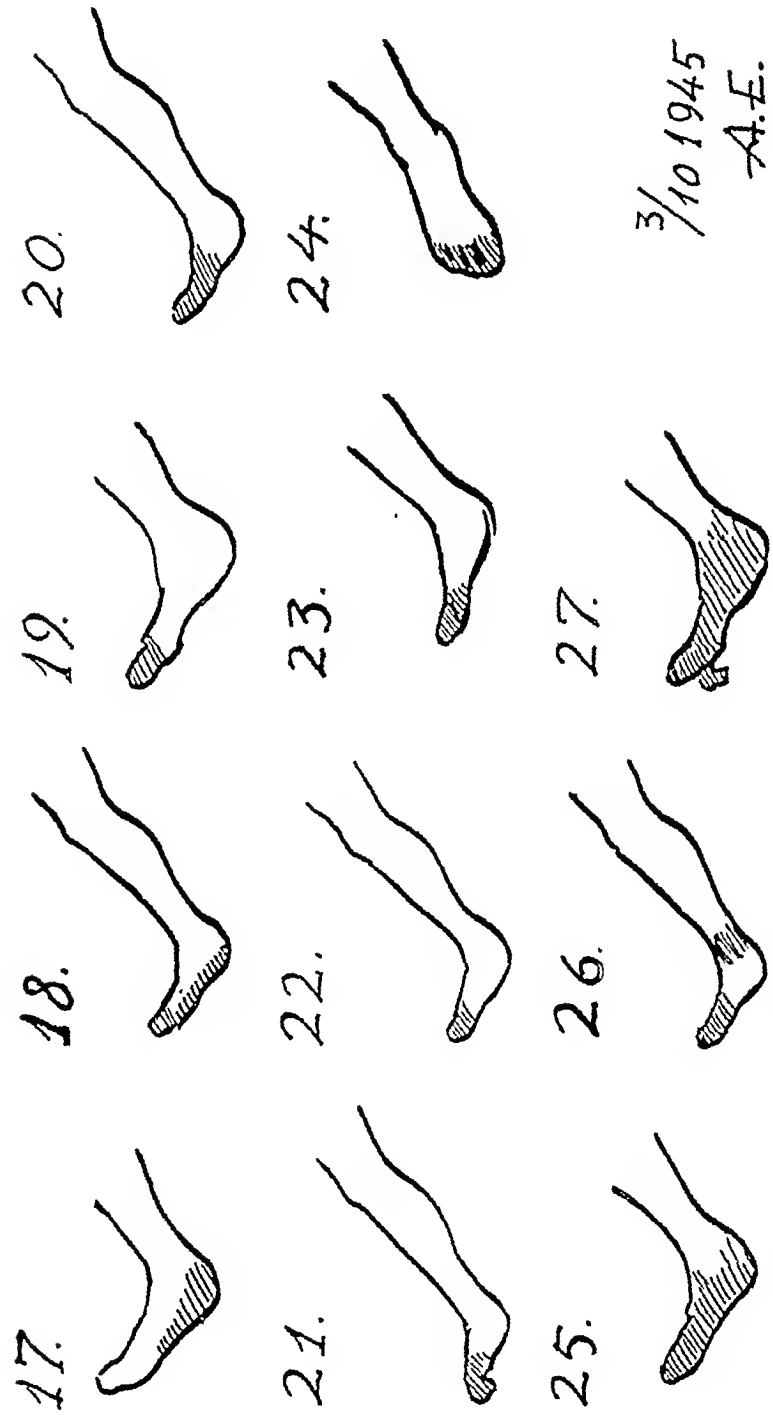

Schéma de l'analyse d'un fantôme avant la sympathectomie, le blocage du sympathique ou l'anesthésie de la moëlle épinière. Les parties les plus douloureuses sont marquées en noir, les parties sans douleur en blanc et celles avec une douleur relativement peu violente sont striées.

Selon le tableau annexé on peut constater que dans 5 cas de sympathectomie lombaire le fantôme douloureux a disparu complètement de même que dans un cas de sympathectomie du cou. Dans un autre cas de sympathectomie du cou, l'état douloureux s'est adouci en devenant «ondulatoire», étant tantôt plus forte, tantôt presque imperceptible. L'examen histologique a été fait sur le tissu reséqué et chaque fois on a constaté la présence de ganglions et de nerfs sympathiques. Dans un seul cas (N:o 8), où il a été usé d'*exploratio reg. lumb.*, l'état douloureux causé par le fantôme est demeuré sans changement. Etant donné que parmi mes observations ce cas est nettement exceptionnel, il y a lieu de l'examiner de plus près.

Il s'agit d'un soldat de 25 ans qui, en juillet 1942, a été victime d'un accident de chemin de fer et dont le degré d'invalidité en vue d'une indemnisation n'était pas encore fixé au point de vue médical. Sa jambe gauche fut amputée dix jours après l'accident à la suite de la gangrène qui s'y était déclarée. Une semaine après l'amputation le moignon devint fortement douloureux, à la suite de quoi on a procédé dix mois après, dans un autre hôpital, à *ganglionectomia lumbalis*. Cette mesure n'eut aucune influence sur la douleur qui devint tellement pénible et continue que le malade ne pouvait pas user de sa prothèse. Dans ces conditions on recourut six mois plus tard à la reséction du nerf sciatique sans que la douleur en soit atténuée. Par la suite on essaya d'user d'hypnose, de traitement électrique et d'injections d'insuline sans obtenir de résultats. Aucun signe ne permettait de conclure à une simulation intentionelle. L'état du malade inscrit plus tard dans la section du soussigné a donné lieu à l'analyse médicale suivante (Voir la figure N:o 8): La douleur causée par le fantôme qui, au début, ne pouvait être localisée s'était légèrement atténuée par la suite et était ressentie le plus distinctement dans la plante du pied et dans les orteils qui semblaient se trouver en état de crampe. La douleur provoquée par le mouvement à l'aide de prothèse était tellement violente qu'il était pour ainsi dire impossible d'user de cette dernière. En se déplaçant le malade était obligé de tenir immobile son bras gauche, faute de quoi la douleur causée par le fantôme s'accentuait. En touchant la partie gauche du corps du malade au-dessous des vertèbres on rendait immédiatement la douleur causée par le fantôme plus violente. Il découle de ce qui précède que le malade était inapte au travail et à tout apprentissage. En plus des médicaments il eut recours à l'alcool. Ayant à le soigner j'ai commencé par un *blocage* du nerf sympathique, à la suite de quoi la douleur causée par le fantôme empira considérablement durant une demi-heure. Ceci était tellement surprenant que j'ai été amené à supposer qu'il s'agissait d'un hystérique. On fit néanmoins *exploratio reg. lumb.* (Kallio), car on pouvait supposer (en absence de documents nécessaires) que dans les opérations précédentes on n'avait peut-être même pas atteint le nerf sympathique. Ainsi qu'il a été in-

diqué, l'opération est demeurée sans résultat, puisqu'on n'a trouvé aucune trace de nerf sympathique et que dans ces conditions il fallait se contenter de penser que celui-ci avait quand-même été sectionné dans la première opération. J'ai cependant fait l'expérience de l'anesthésie de la moëlle épinière en usant de «planocaïne». Toutes les douleurs disparurent durant deux heures, mais le fantôme, débarrassé toutefois de toute crampe, demeura inchangé. Quand par la suite on renouvela à plusieurs reprises l'anesthésie de la moëlle épinière, on arriva à atténuer l'état douloureux définitivement, ce qui permit au malade de devenir un invalide apte au travail.

Ce cas doit, selon moi, être classé dans le groupe V de LERICHE. Le malade constituait ainsi un cas exceptionnel parmi les sujets observés, étant donné que la sympathectomie n'avait eu aucune influence sur l'état douloureux causé par le fantôme pas plus que les blocages et la section du nerf sciatique, mais que par contre l'anesthésie de la moëlle épinière avait coupé les voies par lesquelles les sensations douloureuses atteignaient le système nerveux central. Ce qui cependant étonne dans ce cas, c'est que le blocage paravertébral du sympathique répété deux fois accentua passagèrement l'état douloureux. Rappelons ce que dit en cette matière LERICHE en expliquant les causes des états douloureux: «C'est que la causalgie n'est pas une maladie anatomique, mais une maladie fonctionnelle.»

Des tableaux il ressort que le blocage du sympathique appliqué aux états douloureux relatifs du fantôme amena la guérison définitive de six malades (No:s 9 à 14) et que chez le malade N:o 15 le fantôme devint si peu sensible et la douleur si atténuée qu'il refusa l'opération en se contentant du résultat obtenu. A titre d'essai on usa du blocage du sympathique aussi dans tous les cas de sympathectomie et le résultat fut positif. Les blocages furent faits, selon le procédé de BAUER en usant de 30 cm³ de novocaïne à 1 %. Ils furent répétés environ 4—5 fois et le résultat direct en fut chaque fois d'une part le rechauffement du membre, de l'autre l'interruption nette du fonctionnement du nerf sympathique. Seulement dans deux cas où avant l'opération on procéda au blocage du stellatum dont les résultats furent considérés comme satisfaisants étant donné que l'épreuve Horner devint positive, l'état douloureux causé par le fantôme ne disparut pas complètement, mais la crampe dans les doigts cessa et le fantôme devint trouble. Dans ces deux cas on obtint également un résultat entièrement satisfaisant par le sympathectomie du cou, bien que chez l'un des deux malades le fantôme réapparût par intermitten-

ce. Ce cas n'a pu être élucidé définitivement par moi en dépit d'examens ultérieurs.

Les cas de l'anesthésie spinale (N:os 16 à 27) donnent lieu à quelques observations intéressantes. Elles ont été faites à cause des amputations réitérées du même membre. J'ai toujours interrogé mes malades et fait mes observations avant l'injection et durant l'opération. Dans tous les cas traités l'anesthésie réussit complètement, mais dans aucun *le phénomène du fantôme ne disparut.* Le rechauffement du membre, qui apparaît toujours après un blocage réussi, ne pouvait non plus être constaté. Ces faits semblent démontrer que le nombre des fibres sympathiques qui suivent les nerfs spinaux doit être bien inférieur à d'autres voies du système sympathique comme par ex. à celles qui suivent les veines et artères. HÄMÄLÄINEN a écrit que l'interruption du fonctionnement du sympathique peut être obtenue par l'anesthésie de la moëlle épiniere ou par l'injection de la novocaïne dans le sympathique. Il est vrai qu'il dit ne s'être servi lui-même que de ce dernier procédé. Je crois néanmoins avoir montré que l'anesthésie de la moëlle épiniere ne peut amener qu'une interruption partielle du fonctionnement du sympathique laquelle ne peut pas être considérée comme une indication pour la sympathectomie, puisqu'elle ne suffit pas pour faire disparaître ou changer le phénomène du fantôme. Je tiens à mentionner à ce propos que dans notre hôpital il y a eu au moins un cas où un fantôme douloureux et un neurome de moignon ont été éliminés par la suppression du neurome. Il est évident que dans ce cas la voie par laquelle les sensations dues au fantôme arrivaient au centre suivait les nerfs spinaux.

Ces observations sont propres à élucider l'origine du fantôme. Elles montrent que les fibres sympathiques peu nombreuses qui suivent les nerfs spinaux de même que les nerfs sensitifs transmettant les sensations périphériques au systéme central ne jouent pas un rôle important en tant que voies suivies par le fantôme ou la douleur qu'il provoque. En plus du tableau annexé, qui donne un aperçu général de tous ces cas, je tiens à rendre compte de plus près d'un cas particulier qui sert d'exemple typique et que j'ai pu examiner ultérieurement 4 mois après le traitement.

Il s'agit d'un homme de 27 ans qui a heurté une mine le 4. VIII. 1944. Le même jour il fut amputé de la cuisse gauche. Depuis l'amputation le malade souffre d'un fantôme avec douleur continue. Pour cette raison on fit le blocage du sympathique un mois après. Le résultat en fut que le fantôme douloureux disparut pour 1 à 2 heures. Les blocages ne furent pas continués, parce que le malade fut transféré dans un autre

hôpital. Arrivé dans ma section le malade, ayant oublié qu'il avait été amputé et croyant s'appuyer sur sa jambe absente, est tombé en essayant de marcher. Conséquence: *fract. pertrochanterica styli femoris sin. Applic. oblig. gypsan.* Durant le temps d'immobilité le fantôme douloureux a continué comme auparavant. Le bandage plâtré une fois éloigné on exécuta le blocage du sympathique avec le résultat que le fantôme et la douleur disparurent complètement pour une heure. Après, on fit *sympatectomia lumbalis l. sin.* (Kallio). L'examen histologique du nerf reséqué montre «des cellules ganglionnaires et des fibres nerveuses en groupes épais». (Saxén.) L'analyse du fantôme avant l'opération était la suivante: dans le moignon de la cuisse gauche rien de pathologique à signaler. En remuant le moignon la douleur se fait sentir plus fort. Elle se manifeste le plus nettement dans les doigts du pied spasmodiquement contractés. Le pied semble être serré dans un anneau. Dans le talon il y a des douleurs resemblant à des coups de marteau. Si le malade remue le moignon de cuisse, le fantôme le suit, ce qui indique que le malade a gardé l'image de la position du membre enlevé. En mettant le moignon contre le mur le fantôme semble le traverser. La douleur empêche souvent le sommeil et se fait violemment sentir également le jour, surtout au moment des selles, durant lesquelles la crampe des doigts du pied et le sentiment de l'anneau serrant le pied sont les plus intenses, ce qui a provoqué une tendance de s'abstenir des selles. S'étant réveillé, après la sympatectomie, de la narcose d'éther le malade n'a plus eu aucune sensation du fantôme douloureux. C'était comme s'il «était resté sur la table d'opération».

En visitant le service policlinique de prothèses 4 mois après l'opération le malade déclara que le fantôme douloureux ne s'était plus fait sentir.

Les autres cas de sympathectomie de membres inférieurs sont similaires. Hämäläinen a également mentionné quelques cas de moignons douloureux guéris par la sympathectomie. Parmi les cas traités par moi l'opération semblait indiquée dans un cas encore par le fait que le fantôme était accompagné de *morbus Raynaud* et dans l'autre de *ulcus styli pedis*. Il y a lieu d'ajouter que la sympathectomie a provoqué la guérison également dans ces deux derniers cas.

Les analyses des fantômes ont été faites, comme il est indiqué plus haut, immédiatement avant l'opération ou l'injection de la novocaïne. Sans vouloir les présenter dans chaque cas particulier je les décris sous forme schematique (voir la figure, p. 136—137) en résumant les déclarations faites par les malades. La partie dessinée du membre représente le fantôme en entier, c.-à-d. la partie absente du membre ressentie par le malade. Les endroits où la douleur est la plus intense sont marqués en noir et ceux avec une douleur moins violente sont striés. Les parties laissées en blanc

représentent les endroits sans douleur. Les parties douloureuses du fantôme constituent bien entendu les sensations les plus distinctes de celui-ci dans chaque cas particulier, mais étant donné que chaque figure se base sur la description personnelle donnée par le malade, il va de soi que les figures ne peuvent pas être comparées entre elles.

Dans quelques cas (N:os 1, 8, 9, 21, 27) on remarque que les orteils ou quelques-uns d'entre eux sont spasmodiquement contractés. Souvent la douleur la plus vive se fait sentir dans le premier doigt du pied ou dans le talon. Dans un cas (N:o 24) la douleur est la plus violente «entre les orteils». Dans les deux cas où ce sont les membres supérieurs qui constituent le fantôme, les doigts souffrent de la même crampe. Dans l'un de ces deux cas (N:o 8) la douleur la plus vive se fait sentir dans le coude et dans le poignet spasmodiquement contracté.

Dans tous ces cas le malade garde l'image de la position du membre enlevé. Le fantôme suit tous les mouvements du moignon. Si le malade colle le moignon contre le mur, il sent souvent la partie enlevée qui «traversant le mur se trouve dans la pièce voisine». Il y a lieu de noter ici encore le fait qu'un fantôme est en règle générale un indicateur fidèle du temps qu'il fait, car l'intensité de la douleur en dépend.

Résumé.

En dépit du nombre relativement limité des cas observés et traités je tiens néanmoins à résumer le résultat de mes recherches sous forme de thèses suivantes:

1. Les résultats de mes recherhes semblent démontrer que le fantôme douloureux peut être éliminé par une sympathectomie ou un blocage de la voie sympathique. Cela est difficilement conciliable avec la théorie approuvée généralement aujourd'hui selon laquelle le fantôme constituerait un résidu purement cérébral. Le problème est compliqué encore par le fait que selon les derniers résultats de la science (White, Smithwick) le nerf sympathique ne contiendrait pas de fibres douloureuses provenant des extrémités.

2. Les voies sympathiques qui suivent les nerfs spinaux n'ont guère d'importance pour le phénomène du fantôme.

3. La disparation passagère de l'état douloureux du fantôme

pouvant être obtenue par le blocage du sympathique constitue une indication de l'opportunité de la sympathectomie.

4. Le blocage du sympathique n'apportant aucun changement au fantôme douloureux ne doit pas être considéré comme un indice rendant inutile la sympathectomie, étant donné la difficulté technique du blocage.

5. On peut couper la voie sympathique et éliminer ainsi l'état douloureux provoqué par le fantôme non seulement à l'aide de la sympathectomie mais aussi par des blocages répétés.

Summary.

The author has studied the effect of sympathectomy, blocking of sympathetic nerves and spinal anesthesia on both the illusory presence of amputated members and phantom pains. The latter are divided into relative and absolute categories. Pains have been eliminated in cases of the first category through sympathectomies and in the second through repeated sympathetic blockings. Spinal anesthesia has not, however, proved successful in eliminating the illusory member phenomenon except in a single exceptional instance. The author has thus reached the conclusion that:

1. My conclusion that phantom pain can be eliminated either by sympathectomy or blocking of the sympathetic nerve is difficult to reconcile with the theory prevailing at present that the phantom phenomenon is purely cerebral in origin. The problem is further complicated by the fact that according to the latest results of scientific research (White, Smithwick), no centripetal pain fibers proceed from th extremities along the sympathetic nerve.

2. The sympathetic fibers along the spinal nerve play little if any part in the illusory member phenomenon.

3. The phantom pains of an amputated member to be eliminated by a sympathetic blocking is an indication for the application of sympathectomy.

4. If the blocking does not take effect, it should not be interpreted as a contra-indication for a sympathectomy.

5. Through repeated sympathetic blockings, it is possible to eliminate phantom pains of an amputated member.

Zusammenfassung.

Verf. hat die Wirkung der Sympathektomie, der Sympathikusblockierung und der Spinalanästhesie sowohl auf das gewöhnliche Auftreten des Scheingliedes eines Amputierten als auch auf die Schmerzen in einem solchen untersucht. Die letzteren Fälle werden in absolut und relativ schmerzende Scheinglieder eingeteilt. Bei absolut schmerzenden Scheingliedern ist es gelungen, die Schmerzen durch Sympathektomie und bei relativ schmerzenden durch wiederholte Sympathikusblockierung zu beseitigen. Durch Spinalanästhesie hat man dagegen (ausser in einem einzigen Ausnahmefall) die Scheingliedempfindung nicht beseitigen können. Verf. kommt daher zu folgenden Ergebnissen:

1. Meine Feststellung, dass die Schmerzen eines Scheingliedes der Amputierten durch Sympathectomie oder Sympatikusblockierung beseitigt werden können, geht schwierig zusammen mit der heutzutage allgemeingültigen Theorie nach welcher die Scheingliederscheinung einen rein cerebralen Ursprung hätte. Das Problem wird noch weiter dadurch kompliziert dass nach den letzten Resultaten der modernen Wissenschaft (White, Smithwick) der Nervus sympathicus durch keine zentripetalen schmerzleitenden Fasern mit den Extremitäten verbunden ist.

2. Die den Spinalnerven folgenden Sympathikusfasern spielen beim Auftreten eines Scheingliedes jedenfalls keine bedeutende, vielleicht überhaupt keine Rolle.

3. Schmerzen in einem Scheingliede, die durch Sympathikusblockierung beseitigt werden können, sind eine Indikation für Sympathektomie.

4. Bleibt die Blockierung ergebnislos, so darf es nicht als Gegenindikation für Sympathektomie betrachtet werden.

5. Durch wiederholte Sympathikusblockierung kann ein schmerzendes Scheinglied auch bisweilen beseitigt werden.

Littérature.

Gallinek, A.: Dtsch. Z. Nervenheilk. 1931: *122:* 38. — Guéniot: J. de Physiol. 1861: *4:* 416. Ref. par Jalavisto. — Head: Studies in Neurology (London). 1920. Ref. par Jalavisto. — Homén, E. A.: Veränderungen des Nervensystems nach Amputationen. Beitr. z. path. Anat. u. z. allg. Pathologie 1890: *8:* 304—351. — Hämäläinen, Martti:

Lumbaalisympatektomiasta. Duodecim 1939: 1—21. HÄMÄLÄINEN, MARTTI: Avis donné verbalement. — JALAVISTO, EEVA: Oma ruumiimme havaintomme kohteena. Duocecim 1942: *58:* 187—209. — JALAVISTO, EEVA: Oman ruumiin havainnosta esineinvarianssina. Ajatus (XII) 1943: 1—40. — KATZ, DAVID: Zur Psychologie des Amputierten und seiner Prothese. Beih. z. Zschr. f. angew. Psychologie. (Leipzig) 1921. — KATZ, DAVID: Gestaltpsykologi (Stockholm) 1942: 81—85. — MÄKI, NIILO: Avis donné verbalement. — LERICHE, RENÉ: Les douleurs des moignons d'amputation. Presse méd. 1932: *40:* 869—873. — LERICHE, RENÉ: La chirurgie de la douleur. Paris 1937: 162—186, 42. — WEIR-MITCHELL: Des lésions de nerfs et de leurs conséquences. (Paris) 1872. Ref. par Katz. — WHITE, JAMES C. and SMITHWICK, REGINALD: The Autonomic Nervous System (reprinted January, 1944), 229—236, 239—244.

Aus dem Provinzialkrankenhaus zu Åbo.
(Chefsarzt: Professor H. ELVING.)

Einige Worte über die Spondylolisthesis und deren Behandlung.

Von

HARRY ELVING.

Die *Spondylolisthesis* ist seit Jahrzehnten bekannt. Früher erregte sie nur in geburtshilflicher Hinsicht Interesse. Seit der Erfindung und dem Ausbau der Röntgendiagnostik hat sich dieses Krankheitsbild, das bisher für selten angesehen wurde, als sehr gewöhnlich erwiesen. Es stellte sich heraus, dass die ältere Auffassung, nach der die Krankheit vornehmlich bei den Frauen vorkomme, falsch war und dass männliche Patienten der Krankheit sogar häufiger ausgesetzt sind. Eine reiche Literatur diese Frage betreffend ist in den letzten Jahren entstanden. Auch im Norden hat man dieser Frage Interesse entgegengebracht. Unter bemerkenswerteren nordischen Publikationen seien die von BENZON, BROFELDT, FRIBERG, J. HELLSTRÖM, PORTMAN, SILFVERSKIÖLD und G. WALLGREN erwähnt. Man könnte somit die Frage für hinlänglich beleuchtet und deren weitere Berührung für unnötig halten. Wenn wir aber beachten, wie selten die Kranken chirurgischer Behandlung unterzogen werden, ergibt sich, dass eine fortgesetzte Propaganda für die spondylolisthesischen Operationen nötig ist. Es sind hauptsächlich nur die akademischen Unterrichtskliniken und die Jahresberichte der orthopädischen Spezialanstalten, die Berichterstattungen über eine aktive chirurgische Behandlung enthalten; die vielzähligen Lazaretten und deren Chirurgen bringen der Frage vorläufig nur sehr wenig Interesse entgegen. Unter diesen Umständen mag das Erscheinen einer kürzeren Mitteilung als begründet erachtet werden.

Aus den veröffentlichten Zahlenangaben und Statistiken geht hervor, dass in den nordischen Ländern die Spondylolisthesis kein

seltenes Leiden ist. So konnte FRIBERG aus der Stockholmer Krüppelanstalt in einer zehnjährigen Periode 50 Fälle sammeln. BROFELDT beobachtete in sechs Jahren ebenso viel Fälle in Helsingfors. In der Röntgenabteilung des Åboer Provinzialkrankenhauses hat man die Diagnose der Spondylolisthesis in den Jahren 1939—1944 insgesamt 75 Mal gestellt und in der chirurgischen Abteilung sind in derselben Zeit 15 Patienten nur unter dieser Diagnose gepflegt worden. In zwei von diesen Fällen waren meiner Meinung nach Indikationen vorhanden, die eine aktive operative Behandlung erheischten.

Ob das Krankheitsbild eine grössere Verbreitung bei anderen Völkern und Rassen hat, lässt sich nicht entscheiden. MEYERLING beschreibt allerdings 207 Fälle, die in den Jahren 1918—1931 in der *Mayo*-Klinik beobachtet wurden, aber ganz gewiss sind die Materialien nicht vergleichbar.

Die von mir operierten Fälle sind folgende:

Fall I. J. A. Arbeiter. 18 Jahre. Aufgenommen 23. 11. 38. Diagnose: *Spondylolisthesis gravis.* Früher kein Trauma. Seit $^1/_2$ Jahr Steifheit und Rückenschmerzen. Hat sich mit Schwierigkeit vorwärtsbiegen können. In letzter Zeit zu jeder Arbeit ganz unfähig. Status: starke Lordose in der Lendengegend. Christa ilei beiderseits stark vorspringend, ebenso die beiden Schulterblätter. Die Rippenbogen unmittelbar auf die Hüftbeinskämme gestützt (Siehe Fig. 1). Krümmt den Rücken in der Lendengegend 180°—160°. Die Röntgenuntersuchung zeigt, dass die Lendenwirbelsäule mit ihrer Längsachse etwa 4 cm vor dem Kreuzbein liegt. Der V. Lendenwirbel ist mit seinem Körper beinahe vollständig vom Kreuzbein abgeglitten (Fig. 2). Er zieht mit seiner Vorderfläche fast senkrecht nach unten und die Gegend des Dornfortsatzes regt kopfwärts.

Den 2. 12: *Operatio* ALBEE. Der Span 16 cm lang. Die Hinterfläche des Sacrums nach hinten offen (spina bifida). Die Kanten werden losgemeisselt und an das Transplantat fixiert. Am 16. 2. 39 entlassen, geheilt. Laut Mitteilung vom 1. 2. 45 völlig gesund. Führt auch die schwerste Erdarbeit aus und trägt mit Leichtigkeit schwere Bürden.

Fall II. H. J. Haushälterin. 48 Jahre. Aufgenommen 4. 11. 44. Diagnose: *Spondylolisthesis gravis.* Früher keiner Art von Trauma ausgesetzt. Seit 1 Monat Schmerzen im Rücken und im Unterteil der Beine. Hat sich nicht vorwärtsbiegen und von der sitzenden Stellung erheben können und sich nur mit Schwierigkeit im Bette drehen können. Völlige Unfähigkeit zu jeder Arbeit in der letzten Zeit. Status: starke Lordose zu unterst in der Lendengegend. Blutsenkung 6 mm, WR. — Röntgenuntersuchung: im Seitenbild ist ersichtlich, dass L IV sich um die Hälfte seiner Unterfläche am Vorderrand des L V. vorbei nach vorne verschoben hat. Der Defekt im Wirbelbogen erscheint deutlich in einer

Breite von 1 cm. Am 13. 11. 44: *Operatio* ALBEE. Der Tibiaspan 14 cm lang, wird in proc. spinosi des L II—V und in den oberen Teil des Sacrum eingepflanzt. Den 9. 1. 45 geheilt entlassen. Den 4. 7. 45: völlig gesund. Keine Beschwerden. Kann schwere Erdarbeit leisten.

Fig. 1.

Definitionsmässig verstehen wir unter der Spondylolisthesis nicht das Vergleiten des ganzen Wirbels mit allen seinen Teilen, denn es gleitet stets nur der Wirbelkörper und ein Teil des Bogens über den nächst unteren Wirbel, bezw. da es sich meist um den V:ten Lendenwirbel handelt, über das Kreuzbein nach vorn. Ermöglicht wird dieses Gleiten durch die Trennung an typischer Stelle im Bereich des Bogens und zwar in dem als Zwischenlenkstück oder Interarticularportion zwischen oberen und unterem Gelenkfortsatz gelegenen Bogenabschnitt. Den vor dem Gleitprozess vorhandenen Beinspalt des Wirbelbogens nannte NEUGE-

Fig. 2

BAUER zunächst *Spondyloschisis*, später ist die Benennung *Spondylolysis* eingeführt worden. Man hat — und zwar mit Recht — diese Spaltbildung auch *spina bifida lateralis* genannt. Im Jahre 1925 führte SCHERB für diese Krankheit die Bezeichnung *Spondylolisthesis imminens* ein, um dadurch den Zusammenhang, bzw. den einheitlichen kränklichen Zustand zu charakterisieren, der vor dem Gleitprozess besteht.

Der Defekt des Wirbelbogens ist meist symmetrisch, doppelseitig; mitunter kann er einseitig oder auf der einen Seite verschieden stark entwickelt d. h. asymmetrisch sein.

In der Regel wird das Gleiten am öftesten zwischen dem V. Lendenwirbel und dem Kreuzbein wahrgenommen, es kann aber auch bei anderen Wirbeln vorkommen. Nicht selten ist ein Vergleiten des IV. Lendenwirbels zu finden, in seltenen Fällen war eine spondylolisthesis des III. Lumbarwirbels wahrnehmbar. Nach BURKHARDTS Statistik betreffend 63 Fälle handelte es sich 46 Mal um ein Gleiten des V. Lendenwirbels, in 11 Fällen um den IV. Lendenwirbel und nur in zwei Fällen um ein Vergleiten des dritten Wirbels. JUNGHANS fand sogar in einem Drittel der Fälle eine Verschiebung des vierten Wirbels. Mein zweiter Fall betraf einen Prozess im IV. Lumbalwirbel, und in einem der von J. HELLSTRÖM operierten Fälle hatte das Gleiten auch im vierten Wirbel stattgefunden, vielleicht weil im fünften Lumbalwirbel eine Sacralisation vorlag, die wohl das Gleiten dieses Wirbels verhindern soll.

Häufig ist eine Vermischung verschiedener nahverwandter Krankheitsbilder vorgekommen und fälschlich unter dem Namen der Spondylolisthesis gegangen. So wird bisweilen von einer pseudospondylolisthesis geredet, wo wir auch ein Vorgleiten des Wirbels sahen, wo aber die für die Spondylolisthesis charakteristische und nur bei ihr vorhandene Teilung im intraartikulären Stücke des Bogens fehlen. Unter dem Namen präspondylolisthesis beschreibt WHITEMAN ein Krankheitsbild mit einem kleineren Lendenkreuzbeinwinkel als normal und betrachtet sie fälschlicherweise als Vorstufe der Spondylolisthesis. SCHERB nennt den gleichen Zustand *sacrum acutum*. GLASEWALD hat nachgewiesen, dass bei der Präspondylolisthesis das Becken sehr abschüssig ist, so dass das Kreuzbein horizontal steht (sacrum horizontale). BURCKHARDT fasst diese Krankheitsbilder als eine Haltungsanomalie auf. Eigentümlich ist, dass auch die Wirbelluxationen bisweilen mit der Spondylolisthesis verwechselt wurden. Die Luxa-

tionen setzen selbstredend ein vorangehendes, starkes Trauma voraus. Bei diesem vollzieht sich das Abtrennen in den kleinen Gelenken, während es beim Wirbelgleiten weiter vorne im Zwischengelenk stattfindet.

Man hat auch Verschiebungen nach hinten wahrgenommen (JUNGHANS), vor allem bei alten Leuten, und dieses Krankheitsbild scheint seinen Ursprung in einer weit vorgeschrittenen Degenerierung der Intervertebralscheibe verbunden mit lumbaler arthrosis deformans und Spangenbildung zwischen den Wirbeln zu haben. Die Lordose ist hier gewöhnlich ausgetilgt und das Sacrum hat eine auffallend senkrechte Stellung.

Was den Grund des Wirbelgleitens betrifft, hat man keine Einigung erzielen können. Veränderungen und Missbildungen der Wirbelvorsprünge haben es verschuldet (CHIARI, PALMER), auch Einlagerung funktionell minderwertiger Substanz im Bogen (BURKHARDT), ferner LOOSER'sche »Umbauzonen« und Nekrosen hat man als Ursprung des Krankheitsprozesses angenommen. Mehrere Forscher haben den Grund in primären Degenerierungsveränderungen der Intervertebralscheibe sehen wollen. Es ist allerdings wahrscheinlich, dass eine Zermürbung der unter dem vorgeglittenen Wirbel befindlichen Intervertebralscheibe öfters vorhanden ist. Eine völlig unversehrte Intervertebralscheibe verhindert ganz gewiss trotz einem Defekt des Interartikularteils sehr lange jedes Gleiten, aber andererseits reicht die Verankerung der Wirbel durch intakte Wirbelbogen auch bei völlig zermürbten Intervertebralscheiben hin, um das Vorwärtsgleiten eines Wirbels zu verhindern. MEYER-BURGDORF hat nachgewiesen, dass die Wirbelscheibe trotz der Durchschneidung der Intervertebralscheibe, der Muskeln und Ligamente einem recht starken Trauma standhält, aber wird der Wirbelbogen in Zwischengelenkstücke geteilt, so wird bald die Intervertebralscheibe zerrissen und die Voraussetzungen für ein Gleiten sind vorhanden. Bei einfacher Spaltbildung ohne Gleiten (Spondylolysis) hat MEYER-BURGDORF Veränderungen der Osteochondritis dissecans nachgewiesen, hält sie aber nicht für Erscheinungen primärer Natur. Die meisten Forscher halten auf die sekundäre Natur der Intervertebraldegenerierung. Auch die Forschungen auf dem Institut SCHMORLS gehen dahin. Dort hatte man nachgewiesen, dass bei fast allen älteren Menschen mehr oder weniger hochgradige Osteochondrosis vorhanden war, und trotzdem ist die Spondylolisthesis ein recht seltenes Krankheitsbild.

Der Erste, der die Bedeutung der Spaltbildung in den Interpartikularteilen hervorhob, war NEUGEBAUER. Dieser Spalt befindet sich gewöhnlich unter dem Ursprung des oberen Gelenkfortsatzes. Ihre Grösse wechselt. Ihre Oberfläche hat bei jüngeren Patienten ein geriffeltes Aussehen, während es sich bei älteren Menschen an den Rändern stets Randwülste finden wie bei der Spondylosis deformans des Wirbels. Die Spaltbildung ist meistens doppelseitig; nur in 3 Fällen sah JUNGHANS eine einseitige Anlage. Aus diesen Randwülsten kann man den Schluss ziehen, dass die Kluft bereits eine längere Zeit bestanden hat und dass in ihr Bewegungen und Verschiebungen vorgekommen sind. Der Defekt selbst füllt sich mit zähem Bindgewebe aus.

Über die Entstehung des Spaltes am Wirbelbogen sind die Ansichten noch geteilt. Vor allem zwei Theorien stehen da einander gegenüber. MEYER-BURGDORF nimmt an, dass sich die Spondylolyse als Folge eines ungewöhnlichen Druckes allmählich entwickelt. Er fand im Röntgenbild vorwiegend bei Deformitäten der Wirbelsäule des Erwachsenen Altersveränderungen im Zwischengelenkstück, die über laufende Übergänge schliesslich zur Spaltenbildung führten. Wie früher TURNER glaubt MEYER-BURGDORF dass bei stärkerer Lordose die Gelenkfortsätze der benachbarten Wirbel das Zwischengelenkstück zwischen sich fassen und dass in Folge des Druckes nunmehr durch »Knochenmaterialsermündung« und allmählichen Umbau eine Spaltbildung entsteht. Er hat niemals trotz eifriger Forschungen derartige Bogendefekte bei den Neugeborenen oder bei den Kindern nachweisen können.

SCHMORL dagegen hält mit vielen anderen Forschern die Spaltbildung für angeboren und führt dafür Gründe an, die recht einleuchtend sind. Er konnte nach systematischen Untersuchungen 2—2½ jähriger Kinder in vielen Fällen einen Spalt der Interartikularteile feststellen oder mitunter auch Reste eines Knorpellagers mit nach beiden Seiten gerichteten Wachstumszonen, das an eine Epiphyse erinnerte. Den gleichen Fund machte er auch bei einigen älteren Kranken. Dieses epiphysenartige Aussehen des Spaltes deutet SCHMORL als einen Beweis für deren angeborene Natur. KLEINBERGER hat eine Spondylolisthesis bei einem Kind von 17 Monaten wahrgenommen und auch MOSEBERGER hat über Wirbelgleiten in sehr frühem Alter berichtet. Das gleichzeitige Vorkommen anderer Missbildungen zusammen mit der Spondylolyse haben mehrere Forscher nachgewiesen (ROCHER, WOLFF).

Auch in meinem erstmaligen operativen Fall kam auf der Hinterfläche des Sacrums eine lange Spina-bifida-Öffnung vor, zusammen mit der Olisthese des Lumbalwirbels. Durch alles, was ich oben angeführt habe, scheint mir die kongenitale Natur der Spondylolyse ganz gesichert zu sein.

Wie man sich den Grund für die Entstehung einer kongenitalen Spondylolyse des Wirbelbogens erklären soll, ist nicht klar. NEUGEBAUER meinte, die Hälfte jedes Wirbelbogens sei aus zwei Wachstumkernen aufgebaut und der Spalt sei durch Ossifikationsstörungen zwischen diesen entstanden. Die Ansichten darüber, ob es wirklich zwei Beinkerne gibt, sind strittig, Nach der Meinung vieler Forscher sind diese doch vorhanden, mindestens im Bogen des V. Lumbalwirbels.

Die Frage, inwiefern es sich denken lässt, dass das Trauma eine Spondylolisthesis herbeiführen kann, ist sehr eifrig erörtert worden, ohne dass dabei irgend welche Einigung erreicht wurde. Als Grundlage der ganzen Diskussion, von der auszugehen ist, müssen wir wohl doch die nunmehr beinahe einheitlich vertretene Meinung gelten lassen, dass eine kongenitale Spondylolyse vorgekommen und die Voraussetzung für die Entwicklung der Spondylolisthesis gewesen ist. Ich will auch auf das hinweisen, was oben über den Widerstand gesagt wurde, den eine Intervertebralscheibe gegen das Gleiten zwischen den Wirbeln leistet. Bei dem heutigen Stand der Frage ist dem Trauma kaum ein Vorrang betreffend die Spondylolisthesis anzuerkennen. Die vielerorts veröffentlichten Angaben eines vorausgegangenen Traumas stützen kaum eine traumatologische Stellungsnahme. Es handelt sich im allgemeinen um sehr unbestimmte Angaben von Unglücksfällen und noch häufiger um so geringfügige Gewalt, dass diese unter keinen Umständen ein Wirbelgleiten hätten verursachen können. Eine Unfallsversicherungsunterstützung hat man allerdings hie und da wenigstens für eine gewisse Anzahl Jahre nach dem angemeldeten Unfall ausgezahlt, aber man kann wohl hier BROFELDT recht geben, wenn er sagt, es habe den Anschein, als ob man bei der Anweisung dieser Unterstützungen allzu freigebig verfahren hätte.

Inwiefern sodann ein Trauma beim schon begonnenen Gleiten beschleunigend und verschlechternd auf den Gleitprozess einwirkt, lässt sich wohl mit Sicherheit nicht entscheiden. Dass der Gleitprozess als Regel langsam vor sich geht, muss angenommen werden. Die Möglichkeit einer ruckweisen Verschlechterung ist doch

nicht mit Sicherheit abzuweisen. Doch scheinen die unmittelbar nach einem Trauma ausgeführten Untersuchungen meist Veränderungen älteren Datums aufgewiesen zu haben. Obgleich man in versicherungstechnischer Hinsicht wahrscheinlich freilich Anlass zu haben scheint die Linie zu wahren: in dubio mitis, so soll das nicht auf die Beurteilung der Frage vom theoretischen Gesichtspunkte aus einwirken.

Die Krankheitssymptome, die das Spondylolisthesisbild charakterisieren, wechseln sehr. Die Diagnose auf Grund der Symptome zu stellen, ist in scharf ausgeprägten Fällen möglich, mitunter auch leicht, aber im Anfangsstadium schwer oder am öftesten wohl unmöglich. Bisweilen kann eine Röntgenuntersuchung schwere Veränderungen entschleiern, ohne dass sich der Patient seiner Krankheit klar bewusst war, mitunter finden wir ausgeprägte Beschwerden bei objektiv geringen Veränderungen. Eine gelinde Überbürdung oder dgl. kann zunächst die Aufmerksamkeit auf die Affektion der Wirbelsäule lenken, und die Untersuchung bringt das Gleiten an den Tag, das der Aufmerksamkeit des Kranken entgangen war.

Schmerzen am Kreuz sind die gewöhnlichsten einleitenden Symptome, Schmerzen, die sich wenig von denen unterscheiden, die wir bei anderen Krankheitsbildern bemerken, die zum Lumbosacralsyndrom gehören. Der Verdacht der Ischias ist häufig. Schwerere Störungen in den motorischen und sensiblen Nerven der unteren Extremitäten sind selten, doch klagen viele Kranke über leichte Parästhesien und ausstrahlende Schmerzen in den Beinen. Die Schmerzen am Kreuz können permanent sein, doch treten sie gewöhnlich abwechselnd in besseren oder schlechteren Perioden auf.

Häufig hat der Kranke selbst eine Verkürzung der Körperlänge feststellen können, die in ausgeprägten Fällen bedeutend sein kann; der Oberkörper kann gleichsam ins Becken eingesunken sein (Turners Teleskopsymptom). Die Rippen können am Hüftbeinkamm lehnen. Bisweilen ist eine scharf ausgeprägte Lordose in der Lendengegend und mitunter eine kompensatorische Kyphose oben höher an der Wirbelsäule ersichtlich. Der Dornfortsatz des fünften Lendenwirbels lässt sich nicht fühlen. Beim Druck wird oft Empfindlichkeit über den untersten Lumbalwirbeln angegeben. Die Rückenmuskulatur ist am öftesten gespannt und der Gang bisweilen leicht schwankend. Die Biegsamkeit der Wirbelsäule ist nicht selten beschränkt und eine Steifheit liegt vor.

Die Knie können beim Stehen in leichter Semiflexion gehalten werden.

Den entscheidenden Aufsschlag beim Diagnostizieren gibt doch die Röntgenuntersuchung, bei der jedoch recht grosse Anforderungen gestellt werden müssen. Gewiss ist das seitliche Bild für alle ausgeprägten Spondylolisthesen entscheidend. Hier erkennt man die Verschiebung am besten an der Kontur der beteiligten Wirbelkörper. Das Abgleiten ist ja das Kardinalsymptom des Krankenbildes. MEYERLING hat für diesen Prozess ein Masstab aufgestellt. Er teilt die Sacrumbasis in vier gleich grosse Teile und nennt das Abgleiten im hintersten Vierteilsgebiet den ersten Grad usw. Beim vierten 100-prozentigen Grade ist der ganze Wirbel über die Kante des Promontoriums hinausgeglitten. Es hat sich herausgestellt, dass ein Abgleiten, das sich bei einem älteren Kranken vollzieht, selten extrem hohe Werte erlangt. Mein erster Fall würde der vierten Klasse MEYERLINGS entsprechen und der zweite Fall steht auf der Grenze zwischen dem 2. und 3. Grade. Für die wahre Spondylolisthesis ist aber noch definitionsgemäss die Unterbrechung in den Interartikularpartien des Wirbelbogens nachzuweisen. Diese Linie lässt sich oft leicht erkennen. Sie ist von dorsal-kranial nach ventral-kaudal geneigt und trennt den hinteren Wirbelbogen inklusive Proc. art. inf. von der Bogenwurzel inkl. Proc. art. sup. und Proc. transv. Es gibt doch Fälle, wo die Spaltbildung nicht im Seitenbild hervortritt, und dann ist es notwendig, dass man Röntgenaufnahmen in anderen Projektionen zu Hilfe zieht. In meinen beiden operierten Fällen kam der Spalt in der Seitenprojektion sehr schön zum Vorschein. Grosse Aufmerksamkeit hat man der Dicke und dem Zustand der Intervertebralscheibe geschenkt. In mehr entwickelten Fällen der Spondylolisthesis des untersten Wirbels hat sie sich oft um ihre halbe Höhe verengert, in hochgradigen Fällen ist sie dermassen eng geworden, dass sich die Wirbel unmittelbar berühren. In frischen Fällen sieht man in der Regel keine Verengerung, nicht einmal immer in den hochgradigen. Daraus geht hervor, dass die Veränderungen der Bandscheibe nicht immer primäre Erscheinungen sind, sondern im Verlauf des Krankheitsprozesses aufkommen. Die Spondylosis deformans ist recht gewöhnlich. Die Degenerierung der Intervertebralscheibe führt zeitweilig ligamentäre Verkalkungen herbei, und die sich nach vorn buchtende Intervertebralscheibe schiebt das vordere Ligament vor sich, das dann durch Verbeinung ein Konsol unter dem gleitenden Wirbel bildet.

Was dann die *Therapie* bei der Spondylolisthesis betrifft, hat man zwischen konservativer oder aktiv chirurgischer Behandlungsmethode zu wählen. Während früher die operativen Eingriffe nur in vereinzelten ausgewählten Fällen zur Anwendung gelangten, haben sie später immer mehr an Boden gewonnen. Bei einer Krankheit mit so wechselnden Symptomen und verschiedenen Entwicklungstufen muss sich die Behandlung selbstverständlich nach der Art des Falls richten. In frischen Fällen muss man womöglich eine zeitlang eine abwartende Stellung einnehmen, um die Einwirkung der Stabilisierungsprozesse zu ermitteln, die etwa vorgehen. Die Erfahrung hat nämlich gezeigt, dass die reparativen Prozesse in den Fällen, wo die Degenerierung der Intervertebralscheibe weit genug gekommen ist, zur vollständigen oder fast vollständigen Freiheit von Beschwerden führen können. Bisweilen rühren die Beschwerden gar nicht von den Wirbelgleiten als solchen her, sondern von gleichzeitig erscheinenden intervertebralen Arthriten und Arthrosen in den kleinen Gelenken und können spontan aufhören oder sind mit verhältnismässig einfachen Mitteln zum Weichen zu bringen. Unter den konservativen Behandlungsmethoden nehmen wohl Ruhe — am häufigsten in Form von Bettlage —, Massage und physikalische Therapieformen die erste Stelle ein. Das Gipskorsett ist auch von vielen Seiten empfohlen worden, aber ein solches ist dem Kranken gesagt äusserst unbequem und beschwerlich und ist ein Foltergerät, das man schon längst hätte abschaffen sollen.

Bevor operative Mittel gewählt werden hat man hie und da eine aktive Repositionsbehandlung erstrebt (Burns, Jenkins, Burckhardt). Obgleich man die Methode auf jugendliche Fälle beschränkt hat, bei denen der Gleitprozess relativ frisch und das Gewebe noch nachgiebig ist, sind die Ergebnisse unbedeutend gewesen (Friberg u. a.) Bis zu 24 kg schwere Extensionsgewichte wurden ein paar Monate lang mit wenig Erfolg angewendet. Und auch in den wenigen Fällen, wo man behauptet, positive Resultate erreicht zu haben, ist eine späterhin angeschlossene stabilisierende Operation notwendig gewesen.

Die operative Fixation der Lumbosakralgegend hat man auf zwei Wegen zu erreichen versucht, sie sind: die hintere Rachifixation nach Albee, Hibbs oder andere noch kompliziertere Methoden und der vordere, transabdominale Weg. Die letztere Vorgangsweise, die zuerst Capener vorschlug, ist auf verschiedene Art von Burns, Jenkins, Mercer, und Henschen ausgestaltet

worden. BURNS und JENKINS bohrten, nachdem sie zunächst per laparatomiam die Vorderfläche des V. Lumbarwirbels und die obere Kante des Sacrums freigelegt hatten, einen Kanal durch den Wirbel, die Intervertebralscheibe und den obersten Wirbelkörper des Sacrums und trieben in diesen eine der Tibia oder der Fibula entnommenen Knochenspange ein. Sie haben von guten Ergebnissen berichtet. Um die Gefahr einer möglichen Resorption vom wichtigsten Teil der Spange, seinem Intervertebralteil zu beseitigen, schlug BURNS vor, dass vielleicht ein Metallstift dem Knochenspange vorzuziehen wäre. MERCER hat zuerst eine Verfahrungsweise ausgestaltet und ausgeführt, die er *Mosaikplastik* nannte. Er meisselte ein rechteckiges Loch aus, das den unteren Rand des V. Lumbalwirbels, die Intervertebralscheibe und die vordere Oberkante des Sacrum umfasste. In diese Höhle passte er ein der Christa ilei entnommenes rechteckiges Beinstück und befestigte es durch eine Schraube, die in den oberen Teil des Sacrums eingetrieben wurde. Dass diese Methoden nicht ganz gefahrlos sind, geht daraus hervor, dass in dem einen von MERCERS nach seiner eigenen Methode behandelten Fälle der Tod durch Thrombose in den während der Operation lädierten Mesenterialgefässen erfolgte. FRIBERG hat die Methode noch mehr erweitert und es versucht, die Intervertebralscheibe in deren ganzen Breite und nach hinten, so viel er es wegen der Dura wagte, zu beseitigen. Zur Verbindung benutzte auch er Metallstift. Die Vorteile der Methode liegen ja auf der Hand: eine breite beinige Verbindung des untersten Lendenwirbels mit der Oberfläche des Kreuzbeins. Aber dass die Gefahr der Komplikationen in hohem Grade wächst, scheint offenbar. FRIBERG selbst sagt, dass die Methode sich nicht für ältere, beleibte Menschen eignet. Die Methode schliess auch die im Lendenteil weiter oben sitzenden Spondylolisthesen aus. Keinesfalls können die transabdominalen Methoden zu Methoden der Wahl werden. Sie erfordern unbedingt ein grösseres Mass chirurgischen Könnens als die Operation nach ALBEE und gleichartigen Methoden.

Wenn man die in der Literatur erscheinenden Zeugnisse von operativer Behandlung der Spondylolisthesis betrachtet, ist ersichtlich, dass die Rachifixation nach ALBEE die am meisten angewandte ist und ebenso dass sie gute, hier und da ausgezeichnete Ergebnisse zu zeitigen scheint. Rein theoretisch hat man gegen sie Einwände gemacht und sie als unlogisch bezeichnet. Da nur der Wirbelkörper und der obere Teil des Bogens gleiten und da

der ALBEE-Span nur den aus seiner früheren Lage nicht abgeglittenen Dornfortsatz mit den unteren und oberen Teilen der Wirbelsäule verbindet, wie kann man, hat man gefragt, das Gleiten des Wirbelkörpers zum Stehen bringen? Die meistens gelungenen Operationsergebnisse lehnen doch diese Beanstandungen ab. Entscheidend ist hier, wie HELLSTRÖM sagt, die Fixation der Quervorsätze der oberhalb liegenden Wirbel an das Sacrum. Wissen wir doch aus unseren Operationen wegen tuberkulöser Spondylitis, dass ein durch Tuberkulose völlig zermürbter Wirbel durch die hintere Rachifixation aus seiner Rolle als tragendem Teil völlig ausgeschaltet wird. Bei der Spondylolisthesis bewirkt die Operation aus denselben Gründen, dass die Kräfte aufhören, die das Vorwärtsgleiten des Wirbelkörpers veranlassen. Es ist möglich, dass die verhältnismässig seltenen Fälle, in denen das Gleiten vollständig ist und der V. Lumbalwirbel gar keine Stütze mehr von der Oberfläche des Sacrum findet, den beabsichtigten Nutzen von einer ALBEE-Operation nicht immer haben können.

Eine gute Fixation des Tibiaspans im Sacrum zu leisten, ist einem Ungewandten nicht ganz leicht, dazu ist eine lange Erfahrung derartiger Operationen bei der Spondylitis erforderlich. Wenn man sich genau an die Mittellinie hält, lässt sich eine hinlänglich tiefe Rinne im hinteren Sacrum ohne Komplikationen gewinnen. Nur in den Fällen offener Spina bifida, wie in meinem ersten Fall, sind besondere Massnahmen nötig. Ich machte da die Beinränder der Spina bifida mobil und knüpfte sie in der Mittellinie an den Tibiaspan an. Eine gute Beinheilung erfolgte. In den Fällen, wo der Lumbosacralwinkel Schwierigkeiten bereitet, soll man versuchen, den Tibiaspan ein wenig zu krümmen, was nicht allzu schwer ist. Die Fixation beim Abgleiten im V. Lumbalwirbel soll nicht nur den vierten Wirbel betreffen, sondern stets auch den dritten. Es ist oft recht vorteilhaft in die Winkel und Ecken kleine, lose Beinsplitter um das Transplantat herum einzuschieben, die bei der Ausmeisselung und der Ausgestaltung des Tibiaspans entstanden sind. Man kann oft bei der Röntgenkontrolle später sehen, wie viel kräftiger der Span geworden ist, er ist der Breite nach gewissermassen gewachsen und zur soliden Beinmasse geworden.

Hier und dort hat man sich auch anderer, den ALBEE'schen nahverwandten Operationsmethoden, bedient. LANGENSKIÖLD hat mindestens in einem Falle die GIBSON'sche Modifikation angewendet. Andere haben zwei Späne benutzt und nach HENLE operiert. Grössere Anwendung hat doch die HIBB'sche Operationsmethode

gefunden, wenigstens in Amerika. BROFELDT behauptet gleich gute Ergebnisse mit dieser wie mit der ALBEE-schen gezeitigt zu haben. FRIBERG sagt, wenn die ALBEE'sche Operation als theoretisch unlogisch gelten könne, dies in noch höherem Grade mit der HIBB'schen der Fall sei und er meint, dass die Spondylolysis durch den Eingriff gar nicht beeinflusst wird, es sei denn möglicherweise durch die Narben nach den Beschädigungen der Weichteile.

Die vorläufig veröffentlichten Statistiken sind meist sehr gering und berücksichtigen nur einige Einzelfälle. HIBBS meldet doch schon im Jahre 1937 23 nach seiner Methode behandelte Fälle, und zwar mit guten Ergebnissen. Im Jahre 1940 macht BURCKHARDT die Mitteilung, dass er von 63 in der orthopädischen Anstalt zu Zürich beobachteten Fällen 29 Mal nach ALBEE mit gutem Erfolgt operiert hat und ist der Meinung, dass diese Operation die Methode der Wahl sein soll.

Indem CAPENER von dem Gedanken ausging, eine fixierende Operation solle auf das vordere, gleitende Fragment, also den Wirbelkörper mit Vorsprüngen einzuwirken versuchen, hatte er, abgesehen von seinem Vorschlag zur transabdominalen Operation, der hier schon oben beschrieben wurde, zu dem gleichen Zweck auch die Linien für eine Operation von hinten abgesteckt. Seine Idee haben andere Chirurgen auf verschiedene Art ausgestaltet. CAMPBELL hat versucht, mittels einer Spange von der Christa iliaca diese auf einer oder auf beiden Seiten mit den Querfortsätzen des 4. und 5. Lumbalwirbels fest zu verbinden, um damit eine Stabilisierung der vorderen Partien des Wirbels hervorzubringen. Nach HELLSTRÖM's Angabe fassen SALOMON und CONTIADÈS ihr Urteil über die Methode in den Worten, dass die Technik schwer sei, die Operation langwierig, die Fixation schlecht und das Resultat zweifelhaft. LANCE und AUROUSSEAU haben eine analoge Methode ausgearbeitet und angewendet. SALOMON und CONTIADÈS legen auf jeder Seite »paraepinös« einen weichen biegsamen Knochenspan vom Kreuzbein aufwärts in die Rinne zwischen Dorn- und Querfortsätzen des Lendenwirbels. MATHIEU und DEMIRLEAU bohren ein Loch im ala ossis ilei, durch das ein Tibiaspan eingesetzt wird, der mit seinem nach innen zugespitzten Ende in den transversal gespalteten Querfortsatz eingeführt wird.

Betreffend diese theoretisch erdachten, komplizierten und schwer auszuführenden Methoden kann man die oben angeführte Kritik über CAMPBELLS Methode wiederholen.

Auf die Nachbehandlung hat man allgemein grosses Gewicht

gelegt. In absolut unbeweglicher Bettlage ist der Kranke oft 6—12 Wochen gehalten worden. Einige benutzen das Gipsbett, andere legen den Operierten auf den Magen hin oder in die Rückenlage auf harter Matratze. Ich habe meine Patienten nicht mehr als 6 Wochen unbeweglich gehalten, davon 3 Wochen auf dem Magen und 3 Wochen auf dem Rücken, danach aber die Bettlage mindestens einen Monat lang verlangt. Nach dem Aufstehen haben sie ein exakt liegendes Ledermieder tragen müssen. In den folgenden Monaten muss noch jegliche grössere körperliche Belastung vermieden werden, da dem operierten Wirbel noch keine Belastung zugemutet werden darf. Nach 6—8 Monaten haben sie zu ihren früheren Beschäftigungen zurückkehren dürfen und sich dann allmählich des Mieders abgewöhnt.

Als Schlusswort möchte ich sagen, dass wir, ohne einem schablonenhaften Verfahren bei der Spondylolisthesis anheimzufallen, in geigneten Fällen immer häufiger zur aktiven chirurgischen Behandlung greifen sollen und als Regel nach Albee operieren.

Zusammenfassung.

Verfasser berichtet über zwei Fälle hochgradiger, mit grossen Beschwerden verbundener Spondylolisthesis, die nach Albee mit ausgezeichnetem Resultat operiert wurden. In dem einen Falle war der V. Lumbalwirbel fast ganz abgeglitten, in dem anderen war der IV. Wirbel um die Hälfte am fünften vorüber verschoben worden. Verf. berichtet über die landläufigen Ansichten über die Entstehung und die Symptome der Krankheit und gibt eine kurze Übersicht der verschiedenen Operationsmethoden, die in Frage kommen können, und empfiehlt die Anwendung einer immer häufiger aktiven chirurgischen Behandlung nach Albee.

Summary.

The author describes two cases of severe spondylolisthesis accompanied with great pain which were operated with extremely good results according to Albee's method. In one of the cases the fifth lumbar vertebra had almost slipped right off and in the other the fourth vertebra had slipped over half of the fifth. The author mentions the general current opinion about the origin of the disease and its symptoms and gives a short resumé

of the different operative methods which possibly could be employed and recommends ALBEE's method for the active surgical treatment which is more frequently being resorted to.

Résumé.

L'auteur rapporte deux cas très prononcés de spondylolisthesis accompagnés de troubles graves, opérés avec des résultats excellents par la méthode d'ALBEE. Dans l'un de ces cas, le glissement de la V:e lombaire était à peu près complet et dans l'autre la IV:e lombaire était déplacée sur la moitié antérieure de la V:e. L'auteur expose les conceptions courantes de l'étiologie de la maladie et sa symptomatologie; il donne ensuite un court aperçu des diverses méthodes d'opération qui entrent en ligne de compte et recommande l'emploi plus fréquent d'un traitement chirurgical actif suivant ALBEE.

Literatur.

BROFELDT, S.: Nord. kir. möte 1937. s. 484. — BURCKHARDT, E.: Schweiz. med. Wochenschr. 1940. s. 1093. — BURNS, B.: Zbl. f. Chir. 1934. s. 298. — FRIBERG, S.: Nord. kir. möte 1937. s. 600. — GUILLEMINET, M.: Zbl. f. Chir. 1937. s. 2273. — HELLSTRÖM, J.: Acta orthop. scand. 7. 143. (1936). — HENSCHEN, C.: Zbl. f. Chir. 1939. s. 882. — HIRSCH: Zbl. f. Chir. 1930. s. 1733. — JENKINS, J.: Zbl. f. Chir. 1937. s. 2260. — JUNGHANS: Brun's Beitr. 148. s. 557. (1929). — MEYER-BURGDORF, H.: Deutsche Zeitschr. f. Chir. Bd 245. s. 173 (1935). — MEYERDING, H.: Zbl. f. Chir. 1940. s. 287. — RATHCKE, L.: Deutsche med. Wochenschr. 1937. s. 1228. — REGENSBURGER: Zbl. f. Chir. 1936. s. 2788. — SCHMORL, E.: Deut. Z. f. Chir. Bd 237. s. 422. (1932). — SILFVERSKIÖLD, N.: Acta orthop. scand. 4. s. 40. (1933). — TURNER: Z. orthop. Chir. 51. s. 23. (1928). — WALLGREN, G.: Acta orthop. scand. 4. s. 23 (1933). — ZSCHAU, H.: Münch. med. Woch. 1938. s. 599.

From the University Orthopaedic Clinic of Stockholm.
(Head: STEN FRIBERG, Professor.)

On Late Results of Operative Treatment for Intervertebral Disc Prolapses in the Lumbar Region.

Preliminary report

by

STEN FRIBERG, M. D. and CARL HIRSCH, M. D.

Between 1934 and 1937 it was shown by MIXTER and BARR, MIXTER and AYER, LOVE and WALSH that the majority of prolapses of the intervertebral discs occur in the lumbar region. They demonstrated that immediate relief from the sciatic pain could be obtained by surgery, and initiated a period of intense interest in research and therapy. The operation on an intervertebral disc in the lumbar region is a great advance and on the whole the results reported are good (LOVE, MIXTER and BARR, FRIBERG and others).

Prolapses of the intervertebral disc should not be considered as an isolated phenomenon; generally it is undoubtedly associated with preexisting degenerative changes in the disc, as is shown by experimental investigations by one of us (FRIBERG 1941). More recently P. MAGNUSSON has made the same statement. In our experience these degenerative changes rather seldom develop into a prolapse, and disc degeneration without prolapse is much more common. On the other hand the prolapse may occur in a sound disc as an immediate result of trauma. When this happens, the trauma must be violent, such as fall from great heights, railway accidents etc.

It can be stated that, irrespective of whether the prolapse is traumatic or pathological and whether the trauma is the sole factor or has acted as an "exciting cause", the removal of the prolapse is no more than a relief of the pressure on the nerve root; the pathological changes in the disc remain uninfluenced. The disc degeneration progresses, and as a consequence of this, a

certain risk cannot be excluded on the one hand of postoperative low back pains, on the other, and later on, of a pressure on the emerging nerve roots in the lowest spaces. With regard to this the authors have begun a continuous following-up examination of the late results following on operations for intervertebral disc prolapses in the lumbar region.

The entire material is up to now 550 cases. We have included only cases followed during more than 5 years.

1939—1/11 1940 55 patients were operated, 44 of whom are examined up to 1/11 1945; 28 were male, 16 female patients. One patient died a year after the operation from an intercurrent disease. 32 of the patients followed up have earned their livings as labourers. In 37 cases a prolapse was found. In 5 of the remaining cases the operation could give an explanation of the symptoms. The age at the time of operation has been: men lowest 19, highest 49; women lowest 17, highest 60 years.

The duration of the disease has been stated in 41 cases and was on the average 4 1/2 years. There are two reasons for this long time of praeoperative troubles: firstly, that during the first few years operations were made upon several patients from the time when operation for disc prolapse were not carried out in our clinic, and secondly, that operative indications were restricted during the first period.

Earlier, sciatic pains were treated conservatively and many patients became free from symptoms and capable of work even then; Swedish reports on conservative treatment for sciatica show satisfactory results up to 80 % (Brahme, Malmros). It must be supposed that among these 70 % there are some disc prolapses as well. Therefore, in the investigated material, with some few exceptions which had violent symptoms, no patient was operated upon unless he had been treated in advance conservatively and without success. This restrictive attitude has two disadvantages: the patients with pains resistent to the conservative treatment suffer from their pains and are disabled for a longer time, and besides, there is a greater risk that the long standing pressure on the nerve root will cause irremediable damage.

Without reducing in principle the importance of applying the conservative treatment before surgical intervention is taken into consideration, however, with increased experience the duration of the non-surgical treatment has diminished. At the time when the patients discussed in this paper were treated, the myelo-

graphy was also of importance. This material dates from a period when we mainly used lipiodol at our clinic (iodized poppy seed oil). Considering the risks of adhesive meningitis, we used lipiodol almost as an ultimum refugium, in severe cases, when all conservative treatment had failed and in cases where we were almost certain to obtain a positive result by the myelography. In 37 of the 44 cases now followed up, the myelography has been made using lipiodol. In 32 cases the examination gave a positive result and in 28 of them a prolapse was found at the operation. In two of the other cases the operation could give a clear explanation of the myelographic finding (protruding disc). In the remaining two cases the exploration gave a negative result. Praeoperative roentgenological examination showed signs of degeneration of the disc in the form of affected and narrow space, marginal osteophytes and sclerose of the surfaces of the adjacent vertebral bodies.

This restrictive attitude towards the use of myelography, necessary at that time (1939—40) because of the irritating effect of the lipiodol, is not satisfactory. There is in our material a very good correspondence between myelographic and operative finding, but this is caused by the selection of the material, which consisted almost only of patients showing the classical picture. It is to be presumed that during this period a fair amount of prolapses were not revealed because no myelography was carried out. Basing themselves on the experience of the last few years, the authors consider a more extensive use of myelography as advisable. They do not consider a case of longstanding severe lumbago or sciatica as fully investigated without myelography. It is true that in many cases we get an accurate diagnosis by the clinical findings without myelography. But on the other hand, in many cases we cannot exclude a prolapse only by clinical examination. Therefore, since we started using myelography by abrodil 5 cc. in 20 % solution combined with spinal anæsthesia as a routine method, every patient showing symptoms of sciatica and long-standing signs of unstable low back is subjected to myelography. In all the cases the operation was performed under general anæsthesia in prone position.

In the first 16 cases the operation was performed by laminectomy of the two vertebras bordering on the disc affected. In 19 cases subtotal laminectomy of one vertebra was performed. When a prolapse was not found a resection of the intervertebral joints in order to explore the intervertebral foramen was never performed.

The operative technique has undergone modifications. From 1941 the operation has been performed under local anæsthesia with ½ % novocain and adrenalin, during the work with dura and roots completed with spinal anæsthesia, 2 cc. 5 % novocain injected directly after removal of the ligamentum flavum or part of it. During the last four years, general anæsthesia has been administered only in some very rare cases and at the explicit request of the patient. With increased experience the amount of bone removed has decreased. From the subtotal laminectomy we passed to hemilaminectomy combined with resection of the spinal process. Nowadays the routine method is a partial hemilaminectomy: the spinal process is not resected, the muscles on the other side of the medium line are nor reflected, and the prolapse is taken out by a hole of the size of a fingertip in the arch above the intervertebral space. This procedure supposes a safe diagnosis, the technique is more difficult and the duration of the operation longer. On the other hand, it affords a sort of insurance for the future: if the low back pain should be severe after the operation, the possibilities of a fusion are greater if the spinal processes and arches are left.

In two cases the intervertebral joint on one side was opened and some parts of one facet removed. In 12 cases transdural exstirpation was performed. The use of the transdural method in so many cases is evidently due to a lack of routine, and during the last few years, this method has been used very seldom. The lipiodol was removed in all the cases.

1 prolapse was situated in the third space, 15 in the fourth and 21 in the fifth.

The time of convalescence was, in the prolapse cases from 3 weeks up to 1 year, in the other cases from 3 months up to 2 years. For 22 of the patients the convalescence lasted 2—3 months. For the whole material, it took on average 4.25 months before they could return to work.

The time of postoperative observation is at least 60 months, at most 78 months.

42 patients consider themselves as capable of work. 32 have returned to their former profession, in 22 cases as labourers. 10 patients, 7 prolapses and 3 explorations, have changed their profession. The two patients who have not returned to any work complain of low back pains; one was a prolapse, the other a disc degeneration whithout prolapse.

Out of the 37 patients where prolapse had been stated, 31 = 83.8 % are free from sciatic pains. Out of the 7 explorations where no prolapse had been stated, 2 were free from sciatic pains. 26 prolapse patients = 70 % and two of the explorations affirm that they are altogether free from low back pains.

Lasègue was at the postoperative examination negative in 35 = 79.5 %, and 28 = 65 % showed a clinically normal mobility of the lumbar regions of the back. A regression of the non-reflexiveness of the achilles observed before the operation could not be demonstrated in any of the cases related, and a regression of diminished sensibility could be demonstrated in 14 cases out of 33. To a certain extent this is to be attributed to the long postoperative duration of the pains. In this matter there seems to be no agreement with the more recent material of our clinic. At the postoperative examination, the roentgenological symptoms of disc degeneration mentioned above were stated in 37 cases, whereas they had been shown before the operation in 14 cases. Very interesting are in this matter the 7 cases where the roentgenological examination showed no anatomical signs whatever of disc degeneration. In three of these cases there was undoubtedly a disc prolapse. In the two others there were macroscopical symptoms of disc degeneration, and in these two an incision in the annulus was performed in order to exclude a concealed prolapse. The microscopical examination of these two cases showed pronounced degenerative alterations ("cartilaginous tissue only containing a very small number of living cells. The intercellular substance is in a state of complete alteration. — Cartilage showing pronounced regressive alterations", FREDRIK WAHLGREN). Thus, there are 5 cases which showed indubitable alterations of the disc at the time of the operation and which 5—6 years later do not still show the symptoms of degeneration mentioned above.

This shows furthermore how slowly the degenerative alterations of the disc can take place, and also that a roentgenological examination is not always decisive. The investigations of F. KNUTSSON now make it possible in a greater extent to state by the radiological method instability and abnormal mobility, and thus also to give an earlier diagnosis of a lumbar disc degeneration.

These observations on the remarkable slowness of the development of disc degeneration affords a certain security concerning one detail of the operation. For, during the operation the firm, elastic and well marked resistance under nerve root and dura that is so characteristic for the prolapse, cannot be stated in all the cases, but only an increased prominence of annulus. The operator therefore often doubts whether there is a concealed prolapse at hand or not. If no incision is made in the annulus, there is the

Summary.

Postoperative examination of the results has been performed, after a lapse of at least 5 years, in 44 cases operated on for lumbar disc prolapse. In 37 cases prolapses were found, in 5 disc degeneration; in 2 cases the findings were negative. 42 = 95.4 % are capable of work, 32 in their old profession, which in 22 cases has been physical labour. 10 patients have changed their profession. Out of 37 patients with positive prolapse findings, 31 = 83.8 % were free from sciatic pains.

In 5 cases where pathological alterations of the disc could be stated with certainty at the time of the operation, no signs of disc degeneration could be demonstrated at the postoperative roentgenological examination. This shows the remarkable resistance of the intervertebral disc, and also that a roentgenological examination is not always decisive when judging the state of the lumbar discs.

In no case fusion was undertaken in connection with the prolapse exstirpation. The patients declare that the state of their backs underwent a successive amelioration during the first 1—3 years after the operation. The authors do not advise combined operation as being not necessary and recommend the performing of fusion in a second seance in the cases where low back pain symptoms do not cease.

Zusammenfassung.

Nachuntersuchung der Ergebnisse nach mindestens 5 Jahren bei 44 Fällen, die wegen lumbaler Zwischenwirbelscheibenprolapse operiert waren. In 37 Fällen Prolapse, in 5 Zwischenwirbelscheibendegeneration, in 2 negativer Befund. 42 = 95.4 % sind arbeitsfähig, 32 in ihrer früheren Arbeit, die in 22 Fällen Körperarbeit war. 10 Patienten haben den Beruf gewechselt. Von 37 Patienten mit positivem Prolapsbefund waren 31 = 83.8 % von ihren Ischiasschmerzen befreit.

Bei 5 Fällen, die zur Zeit der Operation sichere pathologische Veränderungen der Zwischenwirbelscheibe aufwiesen, konnten bei der Nachuntersuchung keine röntgenologischen Anzeichen einer Zwischenwirbelscheibendegeneration nachgewiesen werden. Dies veranschaulicht die bedeutende Resistenz der Intervertebralscheibe, und zeigt, dass eine röntgenologische Untersuchung für die Beurteilung des Zustandes der lumbalen Zwischenwirbelscheiben nicht immer massgebend sein kann.

Bei keinem einzigen Falle wurde gelegentlich der Exstirpation des Prolapses eine Fusion vorgenommen. Die Patienten geben an, dass der Zustand ihres Rückens sich in den ersten 1—3 Jahren nach der Operation nach und nach besserte. Verff. halten die kombinierte Operation nicht für notwendig und empfehlen eine in einer zweiten Sitzung vorgenommene Fusion in denjenigen Fällen, wo die Rückensymptome nicht zurückgehen.

Résumé.

Examens de contrôle, après au moins 5 ans, des résultats obtenus dans 44 cas opérés de prolapsus discal lombaire. Chez 37 il s'agissait de prolapsus, chez 5 de dégénérescence du disque, et deux fois on ne trouva rien. 42 d'entre eux (= 95.4 %) sont capables de travailler, dont 32 ont repris leurs anciennes occupations qui 22 fois étaient un métier manuel. 10 malades ont changé de profession. Sur 37 sujets où la constatation du prolapsus fut positive, 31, soit 83.8 %, sont débarrassés de leurs douleurs de sciatique.

Dans 5 cas qui, lors de l'opération, avaient des altérations pathologiques certaines au niveau du disque, l'examen ultérieur ne permit de constater aucun signe radiologique de dégénérescence discale. Cela montre la remarquable résistance du disque intervertébral, et fait voir qu'un examen radiologique n'est pas toujours probant pour juger de l'état des disques lombaires.

Dans aucun des cas on ne pratique une opération de fusion osseuse à l'occasion de l'extirpation du prolapsus. Les malades indiquent que l'état de leur dos s'est amélioré progressivement pendant les premières 1—3 années après l'opération. Les auteurs ne considèrent pas l'opération combinée comme nécessaire et recommandent de fusionner les vertèbres dans un second temps opératoire, cela dans les cas où les symptômes du côté du dos ne voudraient pas céder.

Bibliography.

Brahme, L.: Acta med. scand. 1942: 110: 1. — Deery, E.: Surg. Gyn. Obst. 1943: 77: 79. — Friberg, S.: Acta chir. scand. 1941. Suppl. 64. — Ghormley, R. K., Love, J. G. and Young, H. H.: J. A. M. A. 1942: 120: 1171. — Knutsson, F.: Acta radiol. 1944: 25: 593. — Love, J. G. & Walsh, M. N.: Surg. Gyn. Obst. 1943: 77: 497. — Magnusson, P. B.: Amer. J. Surg. 1945: 107: 228. — O'Connel, J. E. A.: Brit. J. Surg. 1942—43: 30: 315.

From the Orthopaedic Hospital of the Invalid Foundation, Helsingfors.
(Chief: Professor F. LANGENSKIÖLD.)

On the Deformities of the Spine in Multiple Neurofibromatosis (von Recklinghausen).

By

LARS HAGELSTAM.

Since v. RECKLINGHAUSEN (1882) had demonstrated that both the multiple soft cutaneous fibromata and the multiple neuromata have a common origin, the connective tissue of the nerves, his name is connected with the disease we call multiple neurofibromatosis.

The disease is not so often met with. From the King County Hospital, Seattle, D. TRUEBLOOD (1940) reports that of 132,000 patients there were 11 under the diagnosis neurofibromatosis. As the disease is so rare, an account of a case of bad deformity of the spine in neurofibromatosis may be of interest. A collocation of the reports found in the literature of these unusual deformities has also seemed indicated.

The multiple neurofibromatosis is in short characterized by the formation of tumours in skin and nerves; as the third of the so called *cardinal symptoms* abnormal pigmentations arise. The *cutaneous tumours* are soft fibromata of varying number and size, irregularly distributed over the surface of the body. The *nerve tumours* develop anywhere on spinal, cranial or sympathetic nerves, and may consequently give indefinitely varying clinical pictures. Especially deforming are the so called plexiform neuromata, the racemose neuromata and the neuromatous elephantiasis forms, the last are often congenital. The *pigmentations* are often described as naevi, by others "café au lait" coloured, oval, sharply outlined patches are mentioned as particularly characteristic of the disease. Usually the symptoms from the skin appear first, while the nerve tumours may develop in a later stage.

A great number of so called *secondary symptoms* have been described in connection with the disease. I shall later return to the *skeletal changes* seen in neurofibromatosis. The *mental disturbances* often mentioned in the literature were by G. HEUYER and L. VIDART (1940) demonstrated usually to be various degrees of oligophrenia or psychopathia. A rather intimate connection between the disease and the *endocrine glands* is generally stressed and appears most clearly from the fact that the disease in women usually is rapidly exacerbated during pregnancy. J. C. SHARPE and R. H. YOUNG (1936 and 1937) as well as FRUHINSHOLZ, J. LOUYOT and J. RICHON (1935) have paid special attention to the influence of pregnancy on the neurofibromata. Persons suffering from the disease are often dwarfed. Congenital abnormalities are usual in these patients and are also numbered among the secondary symptoms of the disease.

Incomplete forms, so called "formes frustes", are much more frequent than what one would believe, which, for instance, is pointed out by F. HARBITZ (1916). The pigmentations of the skin are often the only manifestations of the disease, of which the classical form may develop later in the same patient. Lastingly incomplete forms are also usual in families where fully developed cases of neurofibromatosis are found.

In neurofibromatosis the symptoms develop slowly, often through decennia. Periods during which the disease is rapidly exacerbated alternate with long periods of standstill. Usually the patients die in advanced age with, and not from, their disease, F. HARBITZ (1909). — Malignant, sarcomatous degeneration of neurofibromatosis is stated to appear in 12—16 % of the cases.

That the multiple neurofibromatosis is a *congenital, hereditary disease*, often appearing in the same family, has long been known.

A dominant heredity was proved by S. A. PREISER and C. B. DAVENPORT (1918). A. PEYRON, N. KOBOZIEFF and L. ZIMMER (1937) considered that they could distinguish three genetically different forms of the disease, a monomeric dominant form, a monomeric recessive form and a dimeric form, in which one factor is dominant and the other has a modifying or restricting influence. The dominant heredity of the disease is also stressed by F. HARBITZ (1942). He thinks it possible that the hereditary principle contains two hereditary factors in the form of alleles or allelomorphs, of which one causes pigment anomalies, the other the complete picture with tumours and pigmentations.

The *histological changes* in multiple neurofibromatosis are very variable as to location, distribution and structure.

According to the prevailing opinion the tumours originate from the Schwann's cells, and would consequently be of ectodermal origin, J. VEROCAY (1910), G. HERXHEIMER and W. ROTH (1914), N. ANTONI (1920). The researches of M. BIELSCHOWSKY also confirm this view. W. PENFIELD (1931) points out that the presence of nerve fibres in v. RECKLINGHAUSEN's neurofibromata clearly shows that they are neurofibromata and not perineural fibroblastomata. The presence of typical connective tissue elements in the tumours has nevertheless been observed and raised the question of their eventual endo- or perineurial origin, F. HARBITZ (1909). Because of the often disseminated appearance of fibromatous-gliomatous processes in both the peripheral and the central nervous system in neurofibromatosis, W. PENFIELD and A. W. YOUNG (1930) suppose the presence of a stimulus of unknown nature that causes hyperplastic changes in the cells and secondarily leads to the formation of tumours. W. KRÜCKE has in a treatise from 1942 gone much farther on the same lines. To him the essential of the disease is a degeneration of the nerve fibres arising from an unknown hereditary cause. A beginning degeneration starts at once a proliferation of the Schwann's cells, but also an edema or a serous inflammation, which in its turn causes a regenerative proliferation of the connective tissue element of the nerves. KRÜCKE does not consider the conception of the neurofibromatosis as a blastomatous process to be tenable any more.

The character of the multiple neurofibromatosis being an often congenital or in earliest childhood appearing disease of clearly hereditary nature, the primary multiplicity of the tumours and the not uncommon combination with congenital anomalies gave already in the beginning of the 20th century rise to the denomination "an anomaly in the broadest sense of the word".

The ontogenetically dystrophic character of the disease is pointed out by H. STARCK (1928), who also draws parallels between "Dystrophia ontogenetica Recklinghausen", Dystrophia pigmentosa Leschke (endocrine disturbances with pigment anomalies) and Laurence-Moon-Biedle's disease (endocrine dystrophies, in the first place dystrophia adiposo-genitalis, and retinitis pigmentosa).

The simultaneous development, often occurring in several members of the same family, of different forms of tumours in neurofibromatosis has been treated of by several authors. Already C. ADRIAN (1901) found the combination of neurofibromatosis with hemangiomata and lymphangiomata often mentioned in the literature. F. HARBITZ (1942) has devoted special attention to these questions proceeding from an observation of neurofibroma-

tosis passing into gliomatosis, spindle-cell sarcoma and hemangiosarcoma in the same family.

The connection between neurofibromatosis and gliomatous processes in the central nervous system has with full evidence been proved by different authors. F. HARBITZ (1938) points out the correlation between neurofibromatosis and other dysplastic conditions bordering on tissue anomaly: gliomatosis, *e. g.* in the spinal cord with syringomyelia, real gliomata, ependymal tumours and meningeomata or endotheliomata in the dura mater, which tumours not so seldom appear simultaneously. In 1942 F. HARBITZ pursues this thought, also referring to other authors. According to him, the multiple neurofibromatosis ought to be assumed to stand in connection with a series of tumorous formations or anomalies in the nervous system on a hereditary basis, as for instand the tuberous brain sclerosis and hemangiomatosis, *e. g.* in Hippel's and Lindan's syndromes. W. KRÜCKE (1942) submits the appertaining questions to a close examination. He reports that M. BIELSCHOWSKY has showed the anatomical connection between neurofibromatosis and the familiar hypertrophic neuropathy. BIELSCHOWSKY had put the question whether all the "dystrophic" forms of the heredodegenerative nerve diseases that develop with changes in the peripheral nervous system were not in close connection with each other. To them he refers Charcot-Marie's neuropathic muscular atrophy and Werdnig-Hoffmann's myatonia congenita. These two diseases had by JENDRASSIK been placed into one group together with the hypertrophic neuropathy. The connection between neuropathic muscular atrophy and neurofibromatosis had been demonstrated by PETTE, and BIELSCHOWSKY had grossly schematically as links in a chain mentioned cerebellar atrophy, Friedreich's disease, hypertrophic neuropathy and myopathies. KRÜCKE for his part places the following diseases as links in a chain: cerebellar and pons atrophy, Friedreich's disease, neuropathic muscular atrophy, hypertrophic neuropathy and neurofibromatosis.

The undoubtedly existing connection between the neurofibromatosis and the abnormal pigmentations regularly appearing together with the disease has been difficult to explain.

In the works of SOLDAN (1899), H. BÜRKLE-DE LA CAMP (1931) and P. MASSON (1926 and 1931) we find a, as it seems, plausible explanation. SOLDAN found that pigmental naevi in most cases are the first discernible sign of a fibromatous process in the connective tissue of the sensory cutaneous nerves, and explained the often observed development of soft fibromata out of pigmental spots as a continuation of the fibromatosis observed in the naevi. MASSON observed that the characteristic of the naevi as of the neurofibromata in the nerve trunks is the Schwann's syncytium, but verifies otherwise SOLDAN's observation that the moles are formed through an abnormal proliferation of the end ramifications of the sensory nerves. BÜRKLE-DE LA CAMP collected in LEXER's clinic a large material of pigmental naevi and cu-

taneous fibromata in Recklinghausen-patients as well as in healthy persons. In all cases he found changes identical with those he could observe in typical cutaneous neurofibromata.

The consequence of these observations may be very far-reaching, considering the existence of some forms of pigmental naevi or small, more or less pigmented, cutaneous fibromata in nearly all people. One is reminded of what N. JONESCO-SISESTI and G. STRÖESCO pointed out at the international neurological congress in Copenhagen 1939, namely, that the multiformity of the hereditary family diseases of the nervous system must be ascribed to the fact that they genetically spring from a whole group of factors, a more or less close fusion of chromomeres. Together with the genetic factor there would be a dominant factor, which sometimes appears and in playing the rôle of a catalyzator makes it possible for the disease to arise.

Skeletal Changes in Neurofibromatosis.

The multiple neurofibromatosis is often associated with strange changes in the skeleton, which are difficult to explain.

Deformities of the spine: scolioses, kyphoscolioses and kyphoses are undoubtedly the most usual changes, these, my main theme, will be treated later on in detail.

Neurofibromata that grow expansively close to the surface of the bone are the cause of *pressure atrophy with erosion of the bone.*

C. ADRIAN (1901) already found the description of such cases. B. BROOKS and E. P. LEHMAN (1924) demonstrate that these changes can be seen as a slight irregularity in the periosteal or cortical outline or structure, or as big tumours on the surface of the bone or as embedded cystiform cavities in the bone. The X-ray findings then correspond to the picture of a bone cyst. These formations are neurofibromata springing from periosteal nerves, they are covered by a peripheral osseous growth, which BROOKS and LEHMAN could demonstrate by microscopic examination. O. PELLEGRINI (1933) saw decalcification and cystic changes in the metaphyses of the lower extremities disappear after 5 years' roentgenological observation, and does consequently not embrace BROOKS' and LEHMAN's explanations. An atrophy of the neurofibroma, which sometimes is observed in the skin, might be the explanation of the phenomenon observed by PELLEGRINI.

An *augmented growth of long bones,* usually of an entire extremity has been observed in neurofibromatosis. As a rule such an ab-

normal growth in length is associated with a neuromatous elephantiasis, or with a strong local neuromatous proliferation in the same extremity.

Such cases have been published by *e. g.* B. Brooks and E. P. Lehman (1924) and F. Nørgaard (1937). The skeletal parts that show abnormal growth are often more gracile and show on the roentgenogram a thinner corticalis than the corresponding bones on the healthy side. — If the epiphysis is destroyed by ingrowing neurofibromatous proliferations the growth may be arrested and an abnormally short extremity be the result, B. Brooks and E. P. Lehman (1924).

Changes in the skull and the facial bones are not unusual. A. Winckelbauer (1927) and T. Rosendal (1938) have studied them more closely.

The gravest changes, great deformities in the cranium, often exist under racemose neuromata or local elephantiasis-formations in the skin of the temporal region and on the eyelids. An asymmetrical development of the skull and the facial bones does also occur, further an augmented or diminished thickness and calcium amount in the cranial bones is seen. On the base of the skull, pressure atrophy occurs, caused by intracranial neurofibromata, T. Rosendal (1938); pictures that can be ascribed to a heightened intracranial pressure have also been observed, A. Winckelbauer (1927).

The described changes can be referred to the two earlier groups, pressure atrophy and growth anomaly, with the exception though of the defects in the temporal region in racemose neuroma, their character of pressure atrophies being very dubious.

Especially in the older literature skeletal changes are described, that are referred to an *osteomalacic softening* of the bone-substance, a condition that by Hoisnard (1898) is called "Cachexie osseuse". It is in the first place in the spine and in the pelvis that these osteomalacic pictures have been observed. The pelvis has in some cases a typically osteomalacic form with beak-like, outdrawn pubic bones and with the lateral parts compressed by the weight of the body. Such cases are described by C. Königsdorf (1889), du Mesnil (1891) and E. Kolepke (1911).

So called congenital pseudo-arthroses are also said to occur in neurofibromatosis; the question has been studied by Ducroquet and Cottard (1939). In addition typical congenital deformities like absence of fibula, luxation of the hip and others have been described in connection with the disease.

The attempts to explain the skeletal changes in neurofibroma-

tosis that have been briefly described above are unfortunately based more on, more or less, theoretical speculations than on observed facts. Exceptions are BROOKS' and LEHMAN's subperiosteal "bone cysts" and the observations of an evident pressure erosion caused by the expansive growth of the tumours, which are anatomically verified.

The said authors wanted further to explain all other skeletal changes so, that the bone becomes involved in the development of neurofibromatous tissue. If the diaphysis becomes involved into the tumorous growth the bone would become more porous and plastic, especially if hypertrophical changes in the lymphatic apparatus are associated with the neurofibromatosis, and the result would be a growth in length distributed all over the bone, instead of limited to the epiphyses. E. STAHNKE (1922) thought that the skeletal changes were likely to confirm the prevailing conception of the neurofibromatosis as an "anomaly in the broadest sense". He interpreted the abnormal local growth as a dystrophy and the cranial deformities observed by him as congenital, which in its turn is denied by A. WINCKELBAUER (1927), who tended to attribute the cranial changes to an augmented intracranial pressure. A. STALMANN (1933) expresses as his opinion that the skeletal changes develop on the basis of "a disposition of vegetative-dystrophic character in connection with the neurofibromatosis". As late as 1942 E. MONZARDO maintained that the skeletal changes were caused by an endocrine disturbance. W. KRÜCKE (1942) had the opportunity of examining the bone changes in a case of neuropathic muscular atrophy and found the changes corresponded to the picture M. B. SCHMIDT had characterized as "neurotic atrophy". He points out that the bone changes in neuropathic muscular atrophy, Friedreich's disease and neurofibromatosis clinically show comprehensive conformity, and that they depend on a direct trophic influence, that they undoubtedly are caused by the lesion of the nerves. S. HARALDSON (1945) does further point out that the skeletal changes are either primary, *i. e.* as the other symptoms, caused by the germinal lesion, or secondary to the development of the neurofibromata.

There are very few *histological researches* to support these theories. It has already been said that BROOKS' and LEHMAN's subperiosteal fibroma formation has been microscopically verified. A similar discovery is mentioned by F. P. WEBER and J. R. PERDRAU (1930) in a case where the tibia was slender and crooked with tumour like swellings, which turned out to be neurofibromata. An osteomalacic picture was seen by E. P. GOULD (1917/18), he speaks about osteoid tissue and decalcification. According to L. MICHAËLIS (1930) PICK, in whose institute GOULD made his examinations, is said to have made objections to GOULD's explanation. As no enostotic changes were found, he did not consider it to be osteomalacia, but rather a, so far, unknown bone disease. L. MORASCA (1939) saw atrophy of the bone trabeculae with an enlargement of the marrow cavity without the presence of

osteoclasts. J. HEINE (1927) examined microscopically the edge of a cranial defect. Near the edge he found trabeculae showing loss of calcium, the trabeculae were penetrated by Haversian canals and perforating vessels. A clear formation of lamellar strata was observed. The outlines of the bone trabeculae were notchy because of deep resorption lacunae filled by osteoid bone tissue. HEINE's microscopical findings in a vertebra will be reported in the following. Other histological examinations of skeletal deformities in neurofibroma-patients have probably not been published.

Deformities of the Spine in Neurofibromatosis.

In studying the question of spinal deformities in neurofibromatosis one finds a considerable number of casuistic reports in the literature, a summary of what these observations have revealed has not been done.

In the literature at my disposal I have found the description of 105 cases of spinal deformity in neurofibromatosis. In 11 cases (STALMANN's cases 4, 8, 12, 20, 23, 27 and 31, and the cases 3, 4, 5 and 6 of GRENET's and his coworkers') it has been the question of doubtful "formes frustes", these have not been included in the summary, which is based on the remaining 94 certain cases. Of these 74 have been studied in the original and 20 in abstracts.

Frequency. As already has been mentioned deformity of the spine is stated to be the most usual of the skeletal changes in neurofibromatosis. C. ADRIAN (1903) found in the literature reports of spinal deformity in 31 of 447 cases of neurofibromatosis (circ. 7 %). Among 35 cases of neurofibromatosis observed at an orthopaedic department A. STALMANN (1933) found deformity of the spine in 15 cases (circ. 43 %). Of STALMANN's 15 cases the diagnosis is very uncertain in 7 cases, see above, why the percentage probably will sink to circ. 23. One gets also the impression that among STALMANN's cases are several in which the deformities are caused by rachitis or hunger osteopathy. His material is collected in Germany during several years following the Great War and published in 1933. R. S. WEISS (1921) quotes a saying of Dr. ENGMAN's, who had seen a "lateral curvature of the spine" in all cases of neurofibromatosis observed by him. Since WEISS' attention had been roused, he found scoliosis in all the 15 neurofibromatosis-patients he afterwards had the opportunity to examine.

Secondary scolioses, which have been caused by other deformities have occurred in 17 cases. In 6 cases (BROOKS' & LEHMAN's case 2, 6 and 7, DECHAUME's case 1, PALMSTIERNA's case, NØRGAARD's case 1) the scoliosis was due to an asymmetric growth of the lower extremities. In CROUZON, BOUTTIER & MATHIEU's case the scoliosis was secondary to an amputation of one leg and in FREMMERT's case and STALMANN's cases 2, 6 and 35 to pseudo-arthroses in the lower extremities. Spontaneous fractures and arthropathies in one leg caused the seoliosis in ARMELIN's case 1, pelvis-asymmetry in LEHMAN's case and changes in hip, knee and tibia in MORASCA's case. Polyarthritis with ankyloses and contractures is specified as the cause of the secondary scoliosis in HEKTOEN & PREBLE's case. The weight of a voluminous tumour had probably in ANTELME's case occasioned the scoliosis, and lastly, the cause of a secondary scoliosis in KÖBNER's case was the asymmetric development of the arms. These secondary scolioses are of no great interest, and consequently I confine myself to mentioning them before passing to the analysis of the primary deformities.

Primary deformities of the spine. Under the heading primary deformities of the spine I have here from the literature grouped all the 77 cases in which the spinal deformity ought to be considered one way or another the direct result of the neurofibromatosis.

The age of the patient at the occurrence of the deformity is stated in 32 cases. Within the group 0—9 years fall 13 cases, of which 2 are said to be caused by trauma, in the group 10—19 years 14 cases, 20—29 years 3 cases of which one after trauma. In 2 cases the deformity arises later, in the one at the age of 40, in the other at the age of 42 in a woman after childbirth.

The age of the patient at the time of observation is stated in 71 cases. The number of cases within the different age-groups is the following: 0—9 years 4, 10—19 years 18, 20—29 years 13, 30—39 years 13, 40—49 years 15, 50—59 years 3, 60—69 years 4 and 70—79 years 1.

From the first series it is evident that the deformity usually arises in childhood or youth. That a great number of cases according to the second series have been observed at the age when spinal deformities usually begin to appear does not alter this fact. No evidence of a connection between the beginning of puberty and the occurrence of the spinal deformity can be found. In 10 cases only the deformity is said to have arisen at the age of 12—18 years.

The *sex* is mentioned in 69 cases, of these 44 are men and 25 women, which corresponds to a percentage of 64 for men and 36 for women. C. ADRIAN (1903) found among 447 cases of neurofibromatosis in the literature 65 % men and 35 % women. Sex is consequently of no importance to the genesis of deformities of the spine in neurofibromatosis-patients.

Detailed descriptions of the *nature of the spinal deformity* are given in 69 cases. Of these 24 are described as scolioses, 33 as kyphoscolioses and 12 as kyphoses.

Of the 24 *scolioses* an incomplete description is given in 14 cases, among these the scoliosis is termed slight in 11 and bad in 3 cases. — A *dorsal scoliosis* is mentioned 6 times. Among these we find scoliosis with convexity to left in 3 cases and scoliosis with convexity to right also in 3 cases. Case 2 of GRENET's and coworkers' is unique. The authors show the reproduction of a roentgenogram taken when the patient was 3 years old, the picture shows a slight scoliosis, which when the patient is 10 years old has developed to a monstrous acute-angular dorsal scoliosis with convexity to right. In 2 cases the scoliosis was located to the upper dorsal region with a compensatory curvature of the lower dorsal spine. — A *dorsolumbar scoliosis* is described in 4 cases, and of them 3 are described in detail. In one case there was a very pronounced scoliosis with convexity to left of the lower dorsal and lumbar spine. Dorsolumbar scolioses of a very high degree are described by BROOKS and LEHMAN (cases I and 5). In their case 1 a very strong scoliosis with convexity to right and a counter clock-wise torsion of nearly 90° of the lowest lumbar vertebrae is seen from the reproduced roentgenogram, and in case 5 as well one sees in the reproduction of the roentgenogram a monstrous acute-angular scoliosis with apex evidently at the 11th dorsal vertebra, which is badly twisted.

Of the 33 *kyphoscolioses* 12 are incompletely described, in half of these cases the deformity is nevertheless stated to have been bad. A *dorsal kyphoscoliosis* is mentioned in 15 cases. In 3 cases the dorsal location only is mentioned. A location to the upper dorsal spine is mentioned in 9 cases. Seven of these are published by STALMANN (this author's cases 5, 11, 15, 25, 26, 33 and 34), and of all these cases only kyphoscoliosis with a high placed hump is mentioned. In KOLEPKE's case 1 a strong kyphoscoliosis with a curvature with convexity to left from vertebra prominens to the 8th dorsal vertebra is mentioned, and in COPELAND, CRA-

VER & REESE's case a kyphosis and scoliosis to right with torsion of the upper dorsal vertebrae to right. In HARALDSON's case there was a pronounced kyphoscoliosis in the middle dorsal region and in ADRIAN's case 5 a strong kyphoscoliosis in the middle and lower dorsal region. In STAHNKE's case the spine was badly bent by the lowest dorsal vertebrae. — The kyphoscoliosis was in 4 cases located to the *dorsolumbar* region. Among these the reproductions of the roentgenograms of KOLEPKE's case 2 show a pronounced kyphoscoliosis with convexity to left with a strong torsion of the first two lumbar vertebrae. In NØRGAARD's case 2 there was a strong acute-angular gibbosity in regio dorso-lumbalis and a strong scoliosis. — In 2 cases only the kyphoscoliosis is described as located to the lumbar region, in both cases with convexity to left (BABONNEIX, TOURAINE & POLLET's case and TOURAINE & SOLENTE's case).

In 12 cases the deformity is described as a *kyphosis* or *gibbus*. In 4 cases the location of the kyphosis is not expressly stated, of these one case (HARBITZ' 1915 case 22) may have been of tuberculous origin. Twice a gibbus is mentioned without the location being mentioned. A gibbus formation in the cervical spine is mentioned twice, in KLOSE's case the apex lay at the 4th and in GORLITZER's case at the 5th—6th cervical vertebra. GENERSICH writes about a bow-shaped dorsolumbar kyphosis. In MICHAËLIS' two cases (the patients were brothers) there was a gibbus formation in the lower dorsal spine, and in MILLER's case a gibbus with the apex at the 1st lumbar vertebra.

The grouping can best be surveyed in the following table 1.

Table 1.

Primary deformities of the spine, 69 cases.

	Location not mentioned	Cervical	Dorsal			Dorso-lumbar	Lumbar
			upper	middle	lower		
Scoliosis 24	14	—	2	4	—	4	—
Kyphoscoliosis 33	12	—	9	5	1	4	2
Kyphosis and gibbus 12	6	2	—	—	2	2	—
Sum total 69....	32	2	11	9	3	10	2

In only $^1/_3$ of the cases we find a scoliosis, in $^2/_3$ of the cases we have graver deformities, kyphoscolioses and kyphoses. The cervical spine is only twice affected, the upper and middle

dorsal spine 20 times in all, while the lower dorsal and the dorsolumbar spine is deformed in 15 cases in all. There is consequently no for the neurofibromatosis typical kind of spinal deformity, it can be of varying location and degree.

Reports on *the occurrence of the cardinal symptoms of neurofibromatosis, skin and nerve tumours and abnormal pigmentations in patients with deformities of the spine* are obtained in 68 cases. Pigmentations in combination with cutaneous tumours are the most usual findings and are reported in 41 cases, in the next place come pigmentations, cutaneous and nerve tumours in 11 cases. Cutaneous tumours only are found in 8 cases, cutaneous and nerve tumours are reported in 4 cases. Pigmentations only are mentioned once in an abstract. Elephantiasis is mentioned 17 times and has in the grouping been referred to the cutaneous tumours.

The interesting question of *in which order the symptoms appear in neurofibromatosis-patients* is illustrated by data in 27 cases. As often as 21 times an abnormal pigmentation is stated to have been the patient's first symptom, among these cases the pigmentation was 11 times congenital. As following symptom cutaneous tumours appeared 12 times, in these cases the spinal deformity came only as third symptom, in one case followed by nerve tumours. After the pigmentation the deformity of the spine appeared as second symptom in 9 cases, among these cases the appearance of cutaneous tumours as third symptom is mentioned in 7 cases and of nerve tumours as third symptom in one case. In 5 cases it is reported that the spinal deformity appeared in the patient with nerve tumours and in only one case, which possibly had traumatic genesis (HIRSCH's case), it is said that a general neurofibromatosis appeared in a patient with deformity of the spine.

The neurofibromatosis-patients are often stated to be *poorly built and short*, even *dwarfs* are mentioned among them. In addition the deformity of the spine is the cause of a shortened body length which is mentioned 33 times among these cases. 15 times it is reported that the length of the body was 150 cm or less. The shortest of the patients, STALMANN's case 34, was 125 cm at the age of 30, but three other patients were 127 respectively 130 cm. In addition it is 4 times mentioned that the patient was a dwarf.

Pains or fatigue symptoms from the back are mentioned in only 9 cases. In HARALDSON's case fatigue symptoms and back-

ache are mentioned. NØRGAARD's 2nd patient had, because of back troubles, not been able to work for 3 years. Pains and fatigue in the upper dorsal region are mentioned by COPELAND, CRAVER and REESE, KOLEPKE reports in his 2nd case "rheumatoid" low back pain and MILLER pains in the region of the back. KÖNIGSDORF speaks about pains in arms, legs and back, and LION & GASNE about pains in ribs, hips and spine. Bad pain is mentioned only twice, ADRIAN (case 5) speaks about obstinate intercostal neuralgies and KOLEPKE in his 1st case about tearing pains in the back. All the 9 cases in connection with which pains are mentioned had bad deformities, kyphoses and kyphoscolioses.

That painful intercostal neurofibromata were the cause of the deformity of the spine in the sense that the patient seeks a position in which the pain is less felt, was assumed by ADRIAN in his 5th case. A painful intercostal "neuroma" was removed by operation in this case. At autopsy GENERSICH found large tumours on the spinal nerve roots intraspinally, the tumours proceeded into the strongly dilated intervertebral foramina. VEROCAY as well found at autopsy small tumours in the roots of the spinal nerves, in the 7th left cervical ganglion and in the 11th right thoracic ganglion tumours the size of a walnut were found besides. This patient had a slight scoliosis, while GENERSICH's patient had a strong kyphotic curvature of the spine in its dorsolumbar part. In HARALDSON's case the X-rays showed a considerable dilation of foramina intervertebralia in the cervical spine, due to tumorous formations on the nerve roots. The vertex of the kyphoscoliosis lay nevertheless at the 7th dorsal vertebra. Considering the scanty informations it does not seem probable that *radicular neurofibromata* are a usual cause of spinal deformity.

Neurological symptoms of a *compression of the spinal cord* are mentioned in 16 cases, and a closer examination of these cases is of interest. Compression of the spinal cord can in these cases be thought to arise either from intraspinal neurofibromata or from dislocation of vertebrae.

In HAUSHALTER's case a boy of 14 had for 2 years had difficulty in going and showed on examination a paraplegia. He had a considerable thoracic deformity, a big bow-shaped dorsolumbar kyphosis and a dorsal scoliosis, X-ray examination of the spine revealed no vertebral changes. LION & GASNE describe a 44-year-old woman, in which 4 years earlier a curvature of the spine had set in simultaneously with

paraplegia, the patient had pains in the back and showed a dorsal kyphoscoliosis. KLOSE's patient was a man aged 30, in whom a strong gibbus-like deformation of the cervical spine developed when the patient was 10—15 years old. A complete transversal lesion of the spinal cord with paralysis of the extremities, the bladder and rectum developed simultaneously. The paralysis healed spontaneously within 8 months, though the roentgenogram showed a dislocation backwards of the 4th cervical vertebra in relation to the 5th. A woman aged 37, who according to her statement had incurred a traumatic spinal damage with attending kyphoscoliosis, is cited by HIRSCH. She had for the last 3 years had a general neurofibromatosis with an especially pronounced location to the 5th and 6th dorsal segments, where the pigmentation also was strongest. The deformation of the back was also most strongly developed at the height of the 6th dorsal vertebra. The patient became pregnant a year after the cutaneous tumours had developed and in the 7th month symptoms of transversal lesion at the height of the 6th dorsal segment appeared. A few weeks after partus the paralysis was diminishing. DRAGANESCU and coworkers describe a 16-year-old boy with scoliosis, who showed symptoms of a slight spastic paraparesis. At myelography with lipiodol stop was found on the height of the scoliosis. GORLITZER's patient died from the sequels of a spinal cord compression. He presented an angular kyphosis with apex at the 5th and 6th cervical vertebra, and autopsy showed compression of medulla at the apex of the kyphosis. The cause of the compression was a "fibroma" the size of a date, but the dislocated vertebral bodies contributed also to the compression. A young man with acute-angular kyphosis in the lower dorsal spine is described by MICHAËLIS (case 1). He had 2 years earlier felt a transitory difficulty in walking, and had now for the last 6 months had an increasing paraplegia. On examination he showed a partial transverse lesion on the height of the 10th dorsal vertebra. MICHAËLIS' case 3 was a 10-year-old girl with strong gibbus and transverse lesion of the spinal cord. Treatment by jacket worked in this case a nearly complete retrogression of the paralysis. WULFFTEN's patient had a complete transverse lesion. STALMANN cites 4 cases connected with this question, which all showed spontaneous improvement of the paralysis. All the patients had a high placed hump. His case 5, a woman aged 22, had at the age of 21 had a transitory paralysis of both legs. Case 11 was a 41-year-old man, who at the age of 30 had a paralysis of both legs, the bladder and the rectum: the paralysis was spontaneously improved. A paralysis of both legs, bladder and rectum healed spontaneously after 3—4 months in his 15th patient, when she was 18 years old. A girl aged 13, STALMANN's case 26, had at the age of 12 a paralysis of the right hand and the legs. This paralysis was also healed, but a simultaneous bladder trouble remained. MILLER's patient, a 21-year-old man, had pains in the back at the same time as the fatal paralysis developed within a week. The patient's kyphoscoliosis did not noticeably change at this time. In GRZEŚ' case innervation disturbances in the legs are mentioned. HARALDSON's patient was a woman aged 26 with strong dorsal kyphosis, she was suf-

fering from ache and increasing forcclessness in the arms, later also in the legs, which were slightly spastic. The X-ray examination showed an intraspinal process in the upmost part of the cervical spine.

Judging from the literature it seems as if the symptoms of spinal cord compressure as a rule were due to intraspinal neurofibromata and not to the spinal deformity as such. The spontaneous remissions might be due to changes in the volume of these tumours depending on edema.

In 20 cases only there are descriptions of *X-ray examinations* of the deformed spine. 9 of these examinations reveal only the curvature of the spine as such, but nothing of the vertebral bodies. GORLITZER mentions only that the vertebral bodies were deformed at the site of the strongest spinal bends. A lateral dislocation of a vertebra in connection with torsion of the vertebra was observed by LAIGNEL-LAVASTINE & RAVIER. In KLOSE's case the 4th cervical vertebra showed wedge-like shape with the edge to the front, the vertebra had completely detached itself from the underlying vertebra and had slid backwards. COPELAND, CRAVER & REESE report that "the bodies of the vertebrae in the scoliotic region were wedge-shaped as a result of slight destruction", HARALDSON roentgenologically demonstrated a strong kyphoscoliosis with vertex at the 7th dorsal vertebra, which like the 8th vertebra was wedge-shaped and had edge excrescences which in the front were overbuilding. No signs of destruction of the vertebrae could be found. A loss of calcium in the vertebrae was demonstrated by KOLEPKE and TOLOSA-COLOMER, while WULFFTEN saw decalcification of some vertebrae which had sunk into each other. No reactive changes could be found in the surroundings. MILLER gives the following description of his findings: "The vertebral bodies were porotic and collapsed and owing to the destruction of the intervertebral disks could not be differentiated from each other at the apex of the curve." Also NØRGAARD saw collapse of several (2 or 3) vertebrae, but no signs of bone growth or fusion of the vertebrae. GERDSEN's case is unique. He found in his patient in the lower dorsal and lumbar spine an apparently horizontal fissure formation in the vertebrae on the roentgenogram. The phenomenon is due to large foramina nutricia. — As it appears the X-ray findings at hand are neither numerous nor particularly illuminating, certainly owing to the great technical difficulties connected with the production of detailed pictures of deformed parts of the spine.

Unfortunately does not even an analysis of reported *autopsy-records* give us fuller information as to the nature of the vertebral changes in these spinal deformities. Reports of autopsy are given in 12 appertaining cases. In 6 cases the deformity is mentioned after external examination only. GENERSICH and VEROCAY found the above mentioned root tumours and erosion of foramina intervertebralia, while GORLITZER found an intraspinal neurofibroma which had eroded a vertebral arch. DU MESNIL and KÖNIGSDORF evidently describe the same case with changes reminding of osteomalacia, no detailed description of the vertebrae is given by them either. Only HEINE has in one case examined the vertebrae more closely. He found the vertebral bodies and the spinous processes full of larger and smaller dark red foci consisting of dilated vessels. HEINE is also the only to report anything on microscopical examinations of the vertebrae in these cases. The patient was 77 years old so the finding of a general osteoporosis is not astonishing. The examined *foci consisted of ectasies of* capillaries, occasional dilated arteries and veins were also found. Neither are these findings astonishing when we know that angiomata occur in 10.7 % of 3,829 examined spines, H. JUNGHANNS (1939).

Especially in the older literature it is generally emphasized that the spinal deformity in neurofibromatosis is due to an, in this disease usual *osteomalacia*. Only three times did I find osteomalacic pelvic changes described in this connection. DU MESNIL's and KÖNIGSDORF's patient had a typically osteomalacic pelvis with protracted pubic bones ; ribs and sternum were abnormally flexible. In LAIGNEL-LAVASTINE & RAVIER's case the shape of the pelvis reminded of that in osteomalacia, while MARIE & COUVELAIRE describe the skeleton as "mou et friable". In KOLEPKE's case 2 the pelvis was completely asymmetrical, left caput femoris had forced the acetabulum deep into the pelvis. In his case 1 KOLEPKE tells that the ribs were strikingly elastically soft. NØRGAARD supposes that the spinal deformity in his case 2 is due to osteomalacia, but no typically osteomalacic bone changes are found.

The *calcium amount in the blood* has been examined in only 3 cases. WULFFTEN reports normal calcium amount. GERDSEN found 10.2 mgr % Ca, and HARALDSON normal mineral metabolism.

The *therapy* for these deformities has not been mentioned more than 4 times, in 3 of these cases treatment by jacket has been

tried. KOLEPKE (case 1) saw no improvement by plaster jacket and medical gymnastics. NØRGAARD's case 2 had worn leather jacket for 30 years when he, because of back troubles, became incapable of work. MICHAËLIS's case 3 had a gibbus and paralysis that when treated by jacket almost completely abated. HARALDSON's patient had a kyphoscoliosis that after treatment in plaster of Paris bed and by medical gymnastics was considerably improved.

Case Report.

The Orthopaedic Hospital of the Invalid Foundation. N:o 266/45, a girl, 14 years of age. Fig. 1, 2 and 3.

Family history (the informations given by the patient's mother). No informations about the paternal grandfather of the patient can be obtained. The patient's paternal grandmother, father and only sister have neither abnormal pigmentations nor cutaneous tumours. The patient's maternal grandfather is also free from symptoms, but his wife has small, raised cutaneous tumours in the face and on the trunk. The mother's only sister has a raised, pigmented spot on the upper lip and a number of small, pigmented spots on the arms. The patient's brother, who is two years old, has a hairy area in the lumbar region but no abnormal pigmentations. I had opportunity to examine the mother. She is dark-complexioned and has small, pigmented, not raised spots in the face and on the extensor side of the forearms, a similar spot is found in the back part of the left knee-joint, where she also has a small, soft cutaneous fibroma. Feeble-mindedness or congenital anomalies do not occur in the family.

Past history. The patient was born with a number of small, pigmented spots, which in the course of time have gradually augmented in size and number. In early childhood the first soft tumours developed in the skin, their number has gradually grown. When the patient at the age of 7 first went to school nothing abnormal was yet found in her back, but when she was 8 years of age it was observed on at school that her back was crooked. This deformity has since then slowly augmented. She has had some pain in the flanks, but no pain in the back. For the last two years the patient's right foot has gradually become deformed at the same time as a certain weakness has been observed in the same foot, but the patient has not limped. — Her psychical and physical health and development has otherwise been without remark.

Status praesens. The physical and mental development of the patient corresponds to that of her age. The thoracic organs, abdomen and urine without remarks. Lues reactions negative. The whole of the skin is unusually dark and of a dirty brownish shade that is most conspicuous in the face. Virile growth of hair on the upper lip. In the

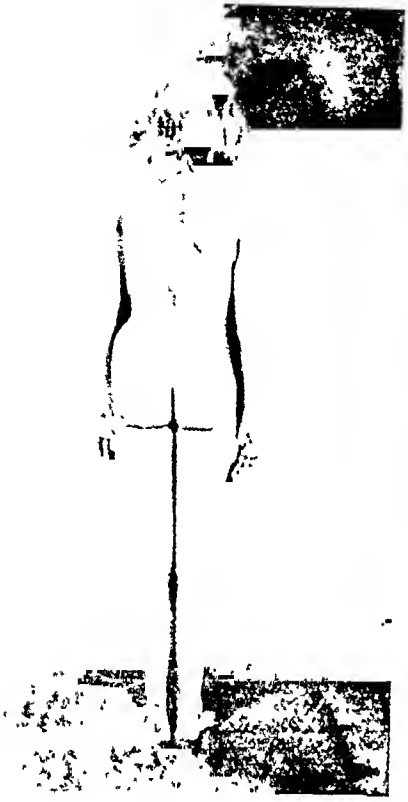

Fig. 1.

Fig. 2.



Fig. 3.

face and over the shoulders numerous, on the trunk and the extremities thinly scattered, oval, not raised, darkly pigmented spots, the size of a wheat-grain. On the trunk and the extremities about ten typical, "café au lait" coloured patches, varying in size from a finger tip to a hen's egg. Irregularly spread over the surface of the body there can be seen some tens of soft, lightly pigmented, sessile tumorous formations in the skin, some of them as big as the end of the thumb, and about the same number of livid, soft maculae, the size of a fingertip. — In the left calf a deep-lying, spool-shaped tumor is palpated and in the right upper arm on the medial side a hard, movable, spool-shaped tumor of a bean's size in a nerve trunk.

The patient's back is badly deformed by a dorsolumbar kyphoscoliosis. The kyphotic component is bow-shaped and not so prominent. The cranial part of the lumbar back makes a sharp bow to the right, the highest point of the bow lies at the second lumbar vertebra. Because of a strong rotation to the right (clockwise) of the vertebrae at the highest point of the scoliosis the transverse processes protrude in the lumbar region on the right side under the back musculature. The lower part of the dorsal spine forms a slight compensatory scoliosis to the left. The dorsolumbar part of the spine is stiff, the bending is done above and under the kyphoscoliosis. No pains in the back neither on movements nor on knocking.

The right foot is somewhat deformed, pes excavatus and hammer toe position.

No neurological symptoms from cranial nerves. Neither motory nor sensory disturbances in the upper extremities or the trunk. The abdominal reflexes normal. On both sides vigorous patellar reflexes and very vigorous Achilles reflexes, the last reflex more vigorous on the right foot. No patellar or foot clonus. BABINSKI's reflex is negative on the left, uncertainly positive on the right foot. In the same foot paralysis of musculi lumbricales. No disturbances in the functions of the bladder or the rectum. The sensibility intact in the lower extremities.

Chemical examination of the blood: Calcium 11.1 mgr %, inorganic phosphorus 4.2 mgr %. Citric acid 24.6 γ/ml, phosphatase 6.9 Bodansky unities: all normal values.

Histological examination of a cutaneous tumour (Dr. I. WALLGREN): Neurofibroma.

X-ray examination (Fig. 4 and 5): In the ventro-dorsal projection a very strong scoliotic bend to right of the dorsolumbar part of the spine with vertex at the 2nd lumbar vertebra is seen. This vertebra is twisted almost 45° in relation to the plane of the picture, the torsion is great in relation to the 3rd lumbar vertebra, while the vertebrae situated above it are seen to be twisted in upwards regularly decreasing degree. The form of the vertebral bodies does not in this projection seem to be changed, the 3rd lumbar vertebra is very indistinctly seen though. The calcium density of the vertebrae does not seem to be reduced. No sclerosis or other reactive changes. The intervertebral spaces preserved. The transverse processes of the 1st—4th lumbar vertebrae on both sides deformed, slender and bent. — In the side-projection a

strange deformity is revealed in the vertebral bodies of the three cranial lumbar vertebrae. The deformation is very pronounced in the 2nd vertebra. This is smaller than the other vertebrae. Its cranial contour measures 36 mm against 41 mm for the caudal contour of

Fig. 4.

Fig. 5.

1st vertebra. Because of this the caudal dorsal corner of the 1st vertebra is "overhanging", at the same time as the cranial ventral corner of the 2nd vertebra is somewhat protruding. The dorsal contours of the three first lumbar vertebrae are indistinctly seen but are probably of the same height. The vertebrae are also ventrally of the same height. A strong, "hour-glass"-shaped narrowing of the middle part of the

said vertebrae is conspicuous, it is in the first place the 2nd lumbar vertebra, the ventral contour of which makes a very strong inward bend. A similar bend is made by the ventral contours of the 1st and 3rd lumbar vertebrae. In all the mentioned vertebrae the dorsal contour does also show an inward bend. The dorsal-ventral measure at the middle of the vertebrae is for the 12th dorsal vertebra and the 1st—4th lumbar vertbrae: D. 12th 37, L. 1st 37, L. 2nd 18, L. 3rd 23 and L. 4th 37 mm. Hereby the vertebrae get a pronounced "hour-glass" shape that can be most distinctly seen on Fig. 5, which is a contour copy of the roentgenogram. Neither can any change in the calcium density of the vertebrae be found in the side projection, the bone structure of the deformed vertebrae is not homogeneous, but on the other hand it is in no way typically changed. Corticalis is intact. No destructive process is going on. The intervertebral spaces cranially and caudally of the 3rd lumbar vertebra cannot be distinguished, the intervertebral spaces seem otherwise to be unchanged. — The pelvis is asymmetrically developed as a sequel of the kyphoscoliosis. In the distal parts of both the femoral diaphyses a cortical clearness the size of a bean is seen (periosteal neurofibroma).

Therapy has been entered upon, medical gymnastics and jacket.

Epicrisis. In a young girl with the classical form of multiple neurofibromatosis a grave dorsolumbar kyphoscoliosis develops when she is 8 years of age. The deformity is slowly growing worse, but does not restrict her mobility. The X-ray examination reveals a strange, hour-glass shaped deformity of the three cranial lumbar vertebrae. The deformity is strongest developed in the 2nd lumbar vertebra, which is much smaller than the other vertebrae.

Discussion. As far as I have been able to ascertain my finding does not correspond to any known form of vertebral deformity. Its origin cannot without further researches be explained by help of the roentgenograms or the clinical findings. It may be excluded that we here were dealing with a metamere deformity. In general skeletal diseases, osteoporosis, hunger-osteopathy, osteomalacia and rachitis such deformations have not been described. Nor have similar findings been observed among the osteodystrophies, osteodystrophia deformans Paget, osteodystrophia fibrosa generalisata v. Recklinghausen and osteodystrophia fibrosa localisata, what is also not to be expected. We can also exclude the presence of a lipoidosis. In chondrodystrophia a shortening of the dorsoventral measure of the vertebral bodies is known, but my patient cannot be thought to have this vertebral deformity as the only symptom of chondrodystrophia. In osteogenesis imperfecta one sees evenly, from above downwards flattened vertebrae. In diseases of the hematopoietic and lymphatic apparatus such an

Zusammenfassung.

Nach einer allgemeinen Übersicht unserer Kenntnisse von der multiplen Neurofibromatose und den bei dieser Krankheit auftretenden Skelettveränderungen, werden 105 aus dem Schrifttum gesammelte Fälle von Wirbelsäulendeformität bei Neurofibromatose eingehend analysiert. — Verf. beschreibt einen Fall von multipler Neurofibromatose mit schwerer dorsolumbaler Kyphoskoliose, bei der röntgenologisch eine eigentümliche, sanduhrförmige Deformität der drei obersten Lendenwirbel festgestellt wurde. Als Erklärung dieser einzigartigen Deformität der Wirbelkörper wird eine trophoneurotische Wachstumsstörung angenommen. Diese Erklärung gilt wahrscheinlich auch für die an den übrigen flachen und röhrenförmigen Knochen beobachteten Wachstumsstörungen bei Neurofibromatose.

Résumé.

Après une revue générale des connaissances relatives à la neurofibromatose et des modifications du squelette concomitantes à la maladie, l'auteur analyse à fond 105 cas de difformité de la colonne vertébrale accompagnant la neurofibromatose, trouvés dans la littérature. L'auteur décrit un cas de neurofibromatose multiple accompagnée d'une cypho-scoliose dorso-lombaire accusée, dans laquelle la radiographie a décelé la présence d'une déformation en sablier des trois premières vertèbres lombaires. Il explique cette difformité unique des corps des vertèbres par un trouble neurotrophique de croissance. Cette explication s'applique probablement aussi aux autres troubles de croissance: os plats ou tubuliformes, observés dans la neurofibromatose.

Literature.

Adrian, C.: Beitr. klin. Chir. 1901: 31: 1. — Idem: Zbl. Grenzgeb. Med. u. Chir. 1903: 6: 81. — Antelme, F.: Bull. Soc. méd. l'Ile Maurice 1897, abstract. Ann. Derm. (Fr.) 1898: 9: 204. — Antoni, N.: Über Rückenmarkstumoren und Neurofibrome. München 1920. — Apert & Abricossoff: Presse méd. 1931, cit. Armelin. — Armelin, G.: Thèse. Paris 1932. — Babonneix, Touraine & Pollet: Rev. neur. (Fr.) 1925, cit. Armelin. — Bielschowsky, M.: J. Psychol. u. Neur. 1923: 29: 182. — Brault, J.: Bull. Soc. Chir. Par. 1905: 31: 692. — Brooks,

B. & LEHMAN, E. P.: Surg. etc. 1924: 38: 587. — BURGHART: Berl. klin. Wschr. 1899: 36: 179. — VON BÜNGNER, O.: Arch. klin. Chir. 1897: 55: 559. — BÜRKLE-DE LA CAMP, H.: Arch. klin. Chir. 1931: 167: 167. — CAMP, J. D.: Proc. Staff Meet. Mayo Clin. 1933: 8: 239. — CHIRAY & CORILLOS: Rev. neur. (Fr.) 1905, cit. KOLEPKE. — COLE, H. & SHAWAN, H.: Cleveld med. J. 1911, cit. PREISER & DAVENPORT. — COPELAND, M. M., CRAVER, L. F. & REESE, A. B.: Arch. Surg. (Am.) 1934: 29: 108. — CROUZON, BOUTTIER, H. & MATHIEU, R.: Bull. Soc. méd. Hôp. Par. 1921, cit. ARMELIN. — DECHAUME: Par. méd. 1927. cit. ARMELIN. — DRAGANESCU, S., DUMITRIU, F. & VASILIU, D. O.: Spital 1929: 49: 160, abstract. Zbl. Neur. — DUCROQUET & COTTARD: J. Chir. (Fr.) 1939: 53: 483, abstract. Zbl. Neur. — FREMMERT, H.: St. Petersburg. med. Zschr. 1872/73: 3: 197. — FRUHINSHOLZ, LOUYOT, J. & RICHON, J.: Presse méd. 1935: II: 1449, abstract. Zbl. Neur. — GENERSICH, A.: Virchows Arch. 1870: 49: 15. — GERDSEN, G.: Dissert. Berlin 1936. — GORLITZER, V.: Arch. Derm. (G.) 1930: 159: 510. — GOULD, E. P.: Quart. J. Med. 1917/18: 11: 221, cit. ARMELIN. — GRENET, H., DUCROQUET, R., ISAAC-GEORGES, P. & MACÉ, M.: Presse méd. 1934: 42: 2060. — GRZEŠ, R.: Čas. Lék. česk. 1939, p. 128, abstract. Zbl. Neur. — HABERMANN: Münch. med. Wschr. 1898: 45: 713. — HARALDSON, S.: Nord. Med. 1945: 25: 105. — HARBITZ, F.: Norsk Mag. Lægevidensk. 1909: 7: 81. — Idem: Beitr. path. Anat. 1916: 62: 503. — Idem: Norsk Mag. Lægevidensk. 1938: 99: 609. — Idem: Acta path. et microbiol. scand. 1942: 19: 448. — HAUSHALTER, P.: 13ième Congrès internat. de Méd. Paris 1900, Tome 7: 568. — HEINE, J.: Beitr. path. Anat. 1927: 78: 122. — HEKTOEN & PREBLE: Trans. Assoc. amer. Physicians 1900, cit. F. HARBITZ 1909. — HERXHEIMER, G. & ROTH, W.: Beitr. path. Anat. 1914: 58: 319. — HEUYER, G. & VIDART, L. Ann. méd.-psychol. 1940: 98: I: 218, abstract. Zbl. Neur. — HINTZ, A.: Wien. klin. Wschr. 1909: 22: 1156. — HIRSCH: E.: Med. Klin. 1927: 23: 983. — HÜRTHLE, K.: Dissert. Jena 1886. — JEANSELME, E.: Ann. Derm. (Fr.) 1898: 9: 991. — Idem: Bull. Soc. méd. Hôp. Par. 1915: 39: 1136. — JONESCO-SISESTI, N. & STRÖESCO, G.: 3ième Congrès internat. de Neur. Copenhague 1939, abstract. Zbl. Neur. 1940: 98: 555. — JUNGHANNS, H.: Die Pathologie der Wirbelsäule. Hdb. d. path. Anat. u. Hist. by LUBARSCH & HENKE, IX/4, Berlin 1939. — KIENBÖCK, R. & RÖSLER, H.: Neurofibromatose. Leipzig 1932. — KLOSE: Klin. Wschr. 1926: 5: 817. — KOLEPKE, E.: Z. orthop. Chir. 1911: 29: 367. — KRÜCKE, W.: Arch. Psychiatr. (G.) 1942: 115: 180. — KYRIELEIS, A.: Dissert. Göttingen 1885. — KÖBNER, H.: Virchows Arch. 1883: 93: 343. — KÖNIGSDORF, C.: Dissert. Würzburg 1889. — LAIGNEL-LAVASTINE & RAVIER: Bull. Soc. méd. Hôp. Par. 1927, cit. ARMELIN. — LEHMAN, E. P.: Arch. Derm. (Am.) 1927, cit. ARMELIN. — LEREDDE & BERTHERAND: Ann. Derm. (Fr.) 1898: 9: 46. — LION, G. & GASNE, G.: Bull. Soc. méd. Hôp. Par. 1904, cit. ARMELIN. — MARIE, P. & COUVELAIRE: Iconogr. Salpétrière 1900, cit. ARMELIN. — MASSON, P.: Ann. Surg. 1931: 93: 218. — MERKEN, P.: Wien. klin. Wschr. 1899: 12: 819. — DU MESNIL: Verh. physik.-med. Ges. Würzb. 1891: 24: 105. — MICHAËLIS, L.: Bruns' Beitr. 1930: 150: 574. — MILLER, A.: Arch. Surg. (Am.)

1936: 32: 109. — MONZARDO, E.: Acta med. patav. 1942: 3: 227, abstract. Zbl. Neur. — MOORE, B. H.: J. Bone Surg. 1941: 23: 109, abstract. Zbl. Radiol. — MORASCA, L.: Arch. Med. e Chir. 1939: 8: 353, abstract. Zbl. Radiol. — MÜLLER, H.: Berlin. klin. Wschr. 1882: 19: 687. — NØRGAARD, F.: Acta radiol. 1937: 18: 460. — OULMONT & HALLER: Bull. Soc. méd. Hôp. Par. 1909, cit. PREISER & DAVENPORT. — PALMSTIERNA, K.: Nord. med. Tskr. 1936: 11: 188. — PELLEGRINI, O.: Arch. Ortop. (It.) 1933: 49: 1021, abstract. Zbl. Neur. — PENFIELD, W.: Congrès internat. de Neur. Berne 1931, abstract. Zbl. Neur. 1932: 61: 436. — PENFIELD, W. & YOUNG, A. W.: Arch. Neur. (Am.) 1930: 23: 320, abstract. Zbl. Neur. — PEYRON, A., KOBOZIEFF, N. & ZIMMER, L.: Bull. Assoc. franç. Étude Canc. 1937: 26: 168, abstract. Zbl. Neur. — PREISER, S. A. & DAVENPORT, C. B.: Amer. J. med. Sci. 1918: 156: 507. — PUTSCHAR, W.: Die funktionelle Skeletumbau und die sogenannten Belastungsdeformitäten. Hdb. d. path. Anat. u. Hist. by LUBARSCH & HENKE, IX/3, Berlin 1937. — RADOVICI, A., PAPAZIAU, R. & FLORESCU, P.: Bull. Soc. méd. Hôp. Bucarest 1939: 21: 174, abstract. Zbl. Neur. — ROSENDAL, T.: Acta radiol. 1938: 19: 373. — SCHMIDT, M. B.: Rhachitis und Osteomalazie. Hdb. d. path. Anat. u. Hist. by LUBARSCH & HENKE, IX/1, Berlin 1929. — Idem: Atrophie und Hypertrophie des Knochens. Ibid., IX/3, Berlin 1937. — SCHMORL, G., & JUNGHANNS, H.: Die gesunde und kranke Wirbelsäule im Röntgenbild. Leipzig 1932. — SEITZ, J.: Virchows Arch. 1871: 52: 114. — SHARPE, J. C. & YOUNG, R. H.: J. amer. med. Ass. 1936: 106: 682. — Idem: Arch. int. Med. (Am.) 1937: 59: 299, abstract. Zbl. Neur. — SOLDAN: Arch. klin. Chir. 1899: 59: 261. — SOUQUES, ALAJOUANINE, LERMOYEZ & BERTRAND: Ann. Méd. 1922, cit. ARMELIN. — STAHNKE, E.: Dtsch. Z. Chir. 1922: 168: 6. — STALMANN, A.: Virchows Arch. 1933: 289: 96. — STARCK, H.: Dtsch. Arch. klin. Med. 1928: 162: 68. — TEICHERT, H.: Dissert. Würzburg 1887. — TOLOSA-COLOMER, A.: Rev. neur. (Fr.) 1929: I: 1177. — TOURAINE, A. & SOLENTE, G.: Bull. Soc. franç. Derm. 1938: 45: 313. — TRUEBLOOD, D.: West. J. Surg. etc. 1940: 48: 134. — WEBER, F. P. & PERDRAU, J. R.: Quart. J. Med. 1930: 23: 151. abstract. Zbl. Neur. — WEISS, R. S.: Arch. Derm. (Am.) 1921: 3: 144. — VEROCAY, J.: Beitr. path. Anat. 1910: 48: 1. — WESTPHALEN, H.: Virchows Arch. 1888: 114: 29. — VIGANÓ, A.: Arch. Ortop. (It.) 1935: 51: 563, abstract. Zbl. Neur. — WINKELBAUER, A.: Dtsch. Z. Chir. 1927: 205: 230. — VAN WULFFTEN, P. P. M.: Ndld. Tschr. Geneesk. 1931: II: 4239, abstract. Zbl. Neur. — ZIMMER, L.: Thèse. Paris 1936. — ZUSCH, O.: Virchows Arch. 1900: 160: 407.

Aus der Chirurgischen Universitätsklinik in Uppsala.
(Chef: Professor O. HULTÉN.)

Über Prolapsus recti bei Erwachsenen.

Von

O. HULTÉN.

Rectumprolapse bei Erwachsenen sind nicht Gegenstand grösseren Interesses seitens skandinavischer Chirurgen gewesen, und Aufsätze über diesen Gegenstand finden sich nur sparsam in der nordischen medizinischen Literatur. Mehr Aufmerksamkeit hat man dagegen Prolapsen bei Kindern zugewandt, obgleich diese ein leichteres Problem darstellen. Nur in Finland sind einige Artikel veröffentlicht worden, nämlich von PALMÉN 1919 und BARDY 1934, und aus Dänemark liegt ein Beitrag von FLEISCHER-HANSEN 1938 vor. Die ausländische Literatur enthält recht zahlreiche Mitteilungen über verschiedene Operationsmethoden; besonders fällt auf, dass russische Autoren so zahlreich vertreten sind. Man hat den Eindruck, dass Prolapse bei Erwachsenen in Russland viel gewöhnlicher sind als anderswo. PALMÉN gibt an, dass russische Kriegsgefangene, um sich invalid zu machen, bei sich selbst Rectumprolapse hervorriefen, indem sie einen Sack mit Erbsen in den Enddarm steckten. Die Erbsen quollen und nahmen an Volumen zu, worauf der Sack mit solcher Kraft ausgerissen wurde, dass das Rectum mitging. Auf diese Weise konnten Prolapse von 10—20 cm Länge entstehen.

Sonst werden Rectumprolapse selten durch plötzliche Gewalt hervorgerufen. Nach der jetzt herrschenden Auffassung ist der Rectumprolaps als eine Art Bruch, ein Gleitbruch, zu betrachten. Die Fossa Douglasi wird allmählich durch den Bauchdruck nach unten gepresst und buchtet die vordere Rectumwand ein. Der Sphinkter ani hält auf die Dauer nicht stand, sondern der Bruch presst sich durch den Analring und wird als ein Prolaps sichtbar. Es besteht ein wichtiger prinzipieller Unterschied zwischen einem solchen

Prolapsus *recti* und einem Prolapsus mucosae *ani*. Die Voraussetzung für einen Prolapsus ani ist eine Auflockerung des submukösen Gewebes. Wenn ein solcher Prolapsus ani hinreichend gross wird, kann er, besonders wenn das perirectale Gewebe locker ist, den untersten Teil der Rectumwand wohl mit sich ziehen, wobei ein Prolapsus ani et recti entsteht. Diese Prolapsform, welche die für Kinder typische ist, wird jedoch niemals so gross und ist nicht so schwer zu behandeln wie der Prolapsus recti bei Erwachsenen. Es gibt noch eine dritte form von Prolaps, nämlich Prolapsus *coli*

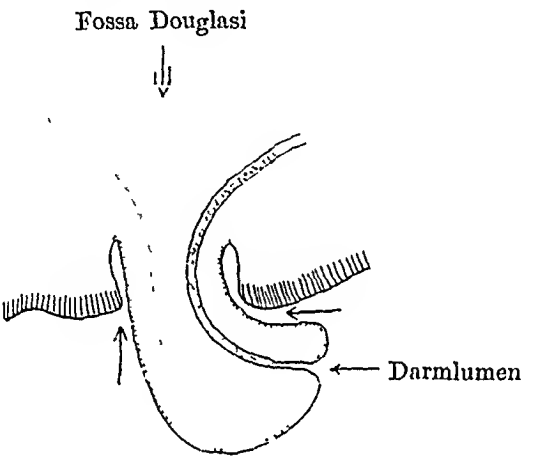

Abb. 1. Schematische Zeichnung des Prolapsus recti, welche die tief in den vorderen Teil des Prolapses hinabgepresste Fossa Douglasi zeigt. Zwei Pfeile bezeichnen die Umschlagsfalte, die sich bei P. recti findet, aber bei P. ani fehlt.

invaginati, der durch eine Einstülpung des Colons in das Rectum entsteht, aber dieser ist sehr selten und eher zu den Invaginationen als zu den Prolapsen zu rechnen. Ein wichtiger Unterschied zwischen P. recti und P. ani ist, dass man bei dem ersteren mit dem Finger in eine mehrere Zentimeter tiefe Umschlagsfalte zwischen dem Anus und dem Prolapsus kommen kann. Beim P. ani dagegen geht die Hautoberfläche direkt in die Mucosa des Prolapses über, und die Umschlagsfalte fehlt (s. Abb. 1).

Die Auffassung, dass der P. recti ein Gleitbruch der Fossa Douglasi ist, geht auf Untersuchungen des Anatomen Waldeyer über die Anatomie des Beckens gegen Ende des vorigen Jahrhunderts zurück, fand aber bei den Chirurgen erst um 1910 Beachtung, als die Franzosen Quénu und Duval sowie der Amerikaner Moschcowitz aus ihr die Konsequenz für die Behandlung zogen und eine Obliterierung der Fossa Douglasi vom Laparotomieschnitt aus statt der bis dahin üblichen perinealen Operationen

befürworteten. Die letzteren greifen ja das Übel nicht an der Wurzel an, sondern versuchen die Wirkungen statt der Ursache zu bekämpfen.

Die *perinealen Operationsmethoden* sind in der Hauptsache von dreierlei Art:

1. Methoden, welche bezwecken, den Anus zu verengern (Ringeinlegung, Injektionen usw.).
2. Methoden, welche bezwecken, das Rectum am Kreuzbein oder Steissbein zu fixieren (Kauterisation, EKEHORNS Operation, LOCKHART-MUMMERYS Operation).
3. Resektion des ganzen Prolapses (MIKULICZ) oder seiner Schleimhaut (JUVARA-DELORM).

Diese Methoden, welche bei P. ani indiziert sein können, sind bei P. recti theoretisch nicht richtig und auch nicht zuverlässig. Diese Form des Prolapses wird besten vom Laparotomieschnitt aus mit Obliteration der Fossa Douglasi nach QUÉNU-DUVAL und MOSCHCOWITZ angegriffen.

Abdominale Operationsmethoden:

1. Nur Obliterierung der Fossa Douglasi (MOSCHCOWITZ).
2. Obliterierung der Fossa Douglasi sowie Fixation des Colon pelvinum in besonderer Weise (QUÉNU-DUVAL).
3. Obliterierung der Fossa Douglasi sowie Resektion der Flexura sigmoidea und temporärer Anus iliacus (HULTÉN).

Ich habe fünf Operationen nach 3) und eine nach 1) ausgeführt, sämtliche mit gutem Resultat. Von einem Mittellinienschnitt unterhalb des Nabels legte ich die Fossa Douglasi frei, die in diesen Fällen ungewöhnlich tief ist und biz zum Anus hinabreicht. Die Wände der Fossa waren mit zahlreichen, bisweilen lockeren, bisweilen ödematösen Peritonealfalten bekleidet, die ungewöhnlich stark auf der Unterlage verschiebbar waren. Um eine zuverlässige Obliteration zu bekommen, kauterisierte ich das Endothel oberflächlich und legte dann 10—15 Tabaksbeutelnähte mit Seide, die eine oberhalb der andern bis zum Promontorium oder so weit hinauf, wie es möglich war. Ich habe den Eindruck, dass die zusammengenähte Schicht mindestens 10, oft 15 cm hoch war. Da das Peritoneum durch das wiederholte Gleiten aufgelockert ist, ist es sehr leicht, die Seidensuturen zusammenzuziehen. Diese sollen durch die Rectumserosa gehen und auch die Hinterseite der Vagina bzw. der Harnblase fassen.

MOSCHCOWITZ begnügt sich mit dieser Operation. QUÉNU und DUVAL fixieren ausserdem das Colon pelvinum und die Flexura

sigm. in besonderer Weise. Es kommt indes vor, dass die Darmpassage in den Tagen nach der Operation erschwert ist, weshalb man an der Mayo-Klinik, wo man einen Todesfall an Ileus nach einer Operation gemäss Moschcowitz hatte, empfiehlt, ein grobes Rohr durch das Rectum bis zum Colon hinauf zu legen. Dieses Rohr lässt sich leichter vor der Obliterierung der Fossa Douglasi einlegen als nachher.

In 5 meiner 6 Fälle lagerte ich die gewöhnlich sehr lange Sigmoideumschlinge durch einen besonderen Schnitt im linken Hypochondrium hervor und machte hier einen doppelläufigen Anus praeternaturalis in derselben Weise wie bei einer Operation nach Block-Mikulicz, wobei ich darauf sah, dass das Colon pelvinum stark nach oben gezogen und gestrafft wurde. Diesen Anus praeternaturalis schloss ich nach ein paar Wochen in gewöhnlicher Weise, indem ich die Scheidewand in dem »Doppellauf« abklemmte und die Mündung zusammennähte.

Durch dieses Verfahren erhalte ich volle Gewähr für gute Darmpassage nach der Operation, das Colon pelvinum wird verkürzt, und der Darm bekommt einen Halt im linken Hypochondrium. Die Operation ist zwar recht umständlich, da sie zu zwei verschiedenen Malen vorgenommen werden muss, und der Krankenhausaufenthalt ist recht lang, aber die Sicherheit gegen Rezidive scheint bedeutend zu sein. Dies zeigen meine Fälle, besonders zwei, die ich vor 7 Jahren operierte, und über die ich etwas näher berichten will.

In beiden Fällen handelte es sich um männliche Irrenhauspatienten mit hypochondrischen Ideen. Sie glaubten, niemals genügend Abführung zu haben, liefen ständig auf den Abort und pflegten auch mit den Fingern im Rectum zu bohren. Sie hatten mehr als doppelt faustgrosse Prolapse von 10 bzw. 15 cm Länge. Der eine Prolaps konnte erst in Narkose reponiert werden (Abb. 2).

Beide wurden mit Spinalanästhesie operiert. Nach der Operation pressten und drückten sie trotz aller Warnungen, so dass ich Rezidive befürchtete, aber solche traten in keinem der beiden Fälle während 7jähriger Beobachtungszeit ein. Die Voraussetzungen für Rezidiv sind sonst bei solchen Geisteskranken besonders gross. Die perinealen Operationsmethoden sind in derartigen Fällen ungeeignet, weil die Patienten ihre Finger nicht von dem operierten Gebiet lassen. Laparotomie ist wohl der einzige gangbare Weg.

Die übrigen 4 Patienten waren psychisch normal. Sie waren



Abb. 2. Der Rectumprolaps bei einem der geisteskranken Patienten, die der Verfasser operierte.

sämtlich Frauen, die beiden ältesten 64 bzw. 67 Jahre alt. Bei einer hatte der Prolaps viele Jahre bestanden. Ein befragter Arzt hatte ihr gesagt, dass es keine zuverlässige Operationsmethode gäbe, weshalb sie sich für unheilbar hielt. Sie wurde wegen einer anderen Krankheit ins Krankenhaus aufgenommen, und da entdeckte man den sehr grossen Prolaps. Sie ist nun nach 3 Jahren rezidivfrei; doch ist der Sphinkter infolge der langjährigen Dehnung, welcher er ausgesetzt war, noch immer sehr schlaff.

In keinem Fall habe ich etwas gegen die Sphinkterschlaffheit getan, obgleich sie sehr bedeutend ist und nach der Operation fortzubestehen pflegt. Ich wollte sehen, ob der abdominale Eingriff an sich selbst genügt, um den Prolaps zurückzuhalten. Dies war auch der Fall. Wenn diese operierten Patienten drücken, sieht man, wie sich der schlaffe Sphinkter öffnet, so dass die Schleimhaut sichtbar wird, aber die Darmwand prolabiert nicht. Ich hatte erwartet, dass der Sphinkter nach Beseitigung des Prolapses seinen normalen Tonus wiedergewinnen würde, aber die Nach-

untersuchung zeigte, dass die Schlaffheit sehr lange bestehenbleibt. Ob sie ständig ist, kann ich nicht sagen; hierzu ist eine noch längere Beobachtungszeit erforderlich.

Zusammenfassung.

Sowohl theoretisch als praktisch hat man zu unterscheiden zwischen Prolapsus ani (Schleimhautvorfall, am gewöhnlichsten bei Kindern), Prolapsus recti (ein Gleitbruch bei Erwachsenen) und Prolapsus coli invaginati (eine Invagination).

P. recti behandelt man am besten nach Quénu-Duval sowie Moschcowitz von einem Laparotomieschnitt aus mit Obliteration der Fossa Douglasi. Der Verfasser pflegt ausserdem eine Resektion der Flexura sigmoidea wie bei Block-Mikulicz' Operation vorzunehmen. Der doppelläufige Anus praeternaturalis wird in gewöhnlicher Weise nach 1—2 Wochen geschlossen.

Verf. hat 6 Patienten operiert, darunter 2 Geisteskranke, die alles taten, um Rezidiv hervorzurufen. Noch nach 7 Jahren waren die Prolapse jedoch nicht wiedergekommen. Dies führt Verf. als einen Beweis für die Effektivität der Operationsmethode an.

Summary.

Both from a theoretical as well as from a practical point of view, one should differentiate between prolapsus ani (most usually prolapse of the mucous membrane in children), prolapsus recti (rectal hernia in adults) and prolapsus coli invaginati (an invagination).

Prolapsus recti is best treated according to Quénu-Duval and Moschowitz by a laparotomy incision with obliteration of the fossa Douglasi. The author, in addition, usually performs a resection of the sigmoid flexure as in Block-Mikulicz' operation. The double tubed anus praeternaturalis is closed in the usual manner after one or two weeks.

The author has operated six patients among whom were two lunatics who used every endeavour to cause a relapse. After seven years the prolapses had not returned. The author claims this as evidence of the efficacy of the operative method.

Résumé.

Des points de vue tant théorique que pratique, on doit distinguer entre le prolapsus anal (procidence de la muqueuse, le plus habituellement chez des enfants), le prolapsus rectal (hernie par glissement, chez des adultes) et le prolapsus du colon invaginé (une invagination).

Le meilleur traitement du prolapsus rectal est celui de QUÉNU-DUVAL et de MOSCHOWITZ, par laparotomie médiane avec oblitération de la fosse de Douglas. En outre, l'auteur a coutume de pratiquer une resection de l'S iliaque, comme dans l'opération de BLOCH-MICKULICZ. L'anus en canon de fusil est fermé de la façon ordinaire, après 1—2 semaines.

L'auteur a opéré 6 malades, parmi lesquels deux aliénés qui firent tout pour provoquer une récidive. Pourtant, même après 7 ans, les prolapsus ne s'étaient pas reproduits. L'auteur relève ce fait comme preuve de l'efficacité de la méthode opératoire.

Litoratur.

BARDY: Om behandlingen av prolapsus recti. Finska läk.sällsk. handl. LXXVI, s. 769, 1931. — FLEISCHER-HANSEN: Om svære recidivtilfælde av rectalprolaps. Ugeskrift f. læger 1938, S. 969. — HOWET: Pathogénie et traitement chirurgical du prolapsus du rectum. Jour. chir. 45, 1935. — MOSCHCOWITZ: Pathogenesis, anatomy and cure of prolapse of the rectum. Surgery etc. 15, S. 7, 1912. — LOCKHART-MUMMERY: Rectal prolapse. Brit. med. Jour. 1939: 1, S. 315. — PALMÉN: Zur operativen Behandlung des Mastdarmvorfalles. Acta chir. LII, S. 617, 1919.

From the District Hospital of Kuopio.
(Chief: Professor MARTTI HÄMÄLÄINEN.)

On the Surgical Treatment of Scleroderma.

By

MARTTI HÄMÄLÄINEN and BROR-ÅKE SÖDERLUND.

Scleroderma is one of the diseases whose etiology is wholly unknown. Every attempt at explaining its causes has been defied. In consequence a rational therapy is still wanted.

Though scleroderma is considered to belong to the dermatology it has since 1922 with great success begun to be treated surgically, by an attack either on the sympathetic nervous system or the parathyroids. Consequently, in 1935 LERICHE clearly pronounced scleroderma to be a surgical disease (11). The surgical treatment of scleroderma is of course also symptomatic, but so good results have been attained that the internal treatment cannot show anything equivalent thereto.

As in the last two years four cases of scleroderma have been operated upon at the District Hospital of Kuopio, we thought it advisable to publish a report of these, Scandinavian literature having as yet presented only three separate operated cases (5, 7, 16).

It is not our intention to draw any far reaching conclusions as to the etiology, pathology and therapy of the disease on the basis of these few cases. But considering that scleroderma is a disease which comparatively seldom occurs in the practice of the professional surgeon, it may be advisable to go somewhat deeper into its history and into some theoretical investigations, with the reservation that, because of the war, French and Anglo-Saxon literature of the recent years has not been available.

Scleroderma is a skin disease characterized by callous parts in the skin and the underlying tissues. The skin often assumes a brownish tint. Later atrophies and degenerative processes set in

in the affected parts. Three different forms can be distinguished: the progressive diffuse scleroderma which usually is localized to the face, the neck and the trunk, the sclerodactylia, by which the distal parts of the limbs are affected, and the restricted scleroderma, characterized by plaques forming foci, which in later stages can be confluent. The disease has often a malignant course, though periods of spontaneous improvement may occur. The patients are greatly inconvenienced by the symptoms from the affected parts of the skin. They are sensitive to cold and have a feeling of pressure and pains that can be insufferable. The mobility is often restricted and total invalidity or even death may ensue.

Cracks often arise in the atrophied skin with attending lingering infections. The disease attacks persons of both sexes, though more often women. The etiology is, as already pointed out, unknown, and the internal treatment has not succeeded in showing any lasting results.

In 1922 LERICHE proposed to treat scleroderma surgically, *i. e.* by an intervention on the sympathetic nervous system, and in the same year BRÜNING made an one-sided resection of the neck sympaticus (9, 19). Since 1924 literature presents several publications from this sphere: BRÜNING & STAHL, HORN, ENDERLEN, KMENT, JERASEK, PETRIVALSKI, KUKULA, KAPPIS and others. Most of them have hereby applied a periarterial sympathectomy and the results reported have generally been encouraging. It has therefore been supposed that vascular disturbances play a decisive rôle in the pathogenesis of the disease. The same methods have, with great success, been applied to other diseases of vasospastic nature, as Raynaud's disease and angina pectoris, to mention some instances.

SUNDER-PLASSMAN and JAEGER have published two operated cases of scleroderma combined with Raynaud's disease, an incident often observed by American scientists (2, 3). Of the nine cases of Raynaud's disease treated by sympathectomy at the District Hospital of Kuopio, none showed any symptoms of scleroderma. SUNDER-PLASSMAN has rather categorically stated that the disease is due to pathologico-anatomically demonstrable changes in the sympathetic ganglia, but CRAIG, MCWINCHELL and KERMOHAN are of another opinion. These American authors find that the changes in the ganglia examined by them do not exceed the limits for the normal; at most they can be considered as degenerative senile changes. SUNDER-PLASSMAN considers the etiol-

ogy to be the same as in Winiwarter-Buerger's disease (Thromb-angitis obliterans juvenilis), and on this point, where most scientists are of diverging opinions, a schism has arisen. We shall not enter into this fruitless discussion. The etiology of the disease is still in the dark, and on this way no clearness in this respect has been gained.

In Europe LERICHE and his school bestowed a great deal of labour on the etiology and treatment of the disease. From 1924 date LERICHE's first published cases, which he treated by peri-arterial sympathectomy and cervical ramisection of ganglion stellatum (8). In certain cases he found a hypercalcaemia and had thereby recourse to a second method, *i. e.* parathyroidectomy. He has hereby had PAUTRIER's researches for authority and he assumes that the hypercalcaemia and the frequently found calcifications of the skin (Thieberge-Weissenbach's syndrome) are due to disturbances in glandula parathyreoidea (9). As basis for their theory LERICHE and JUNG made careful quantitative analyses of the amount of calcium in blood, urine and skin (12). In treating scleroderma LERICHE used both methods side by side, separately or in combination. Though we have not had the very latest literature at our disposal, it seems to us as if LERICHE had more and more gone in for sympaticus operations. LERICHE himself admits that there are many different forms of scleroderma, and that hypercalcaemia is by no means a constant phenomenon (10, 12).

Concerning parathyroidectomy in treating scleroderma a case published in 1931 by MOULONGUET may be mentioned. It concerns a patient with Thieberge-Weissenbach's syndrome and hypercalcaemia. In addition, the patient had in the left lobe of the thyroid a parathyroidea adenoma that was extirpated. In spite of this the disease progressed mercilessly. The blood calcium values were certainly lowered, but there was no result of the treatment (15).

Of American authors, ADSON, O'LEARY and BROWN already in 1930 published 16 cases treated by sympathectomy. These scientists suppose that scleroderma develops out of vascular (spastic) disturbances. The results were on the whole good. On the other hand, in 1939 GARLOCK and BERNHEIM, on the basis of 17 operated cases, argued for parathyroidectomy, even maintaining that no better method can be found (1, 2, 3).

In Estonia PUUSEPP in 1936 published two cases of scleroderma treated by stellectomy with good results. In Sweden LAURELL re-

ported a case of advanced scleroderma with facial changes operated on in 1938 by right-sided resection of gangl. med. et inf. The time of observation has been 4½ years, and the condition of the patient has greatly improved. In 1943 MYHRMAN and MALMSTRÖM likewise published a case of scleroderma with (*calcinosis circumscripta*), localized to face and fingers. The mobility of the fingers was already restricted. The case was treated by a double-sided high thoracal ganglionic sympathectomy. The mobility of the fingers did not improve, but subjectively the patient felt better and thought that the skin had become softer. At the annual meeting of Svensk Kirurgisk Förening in 1944 one of us (HÄMÄLÄINEN) reported two cases of scleroderma treated by sympathectomy; these cases are included in this series (18, 7, 16, 5).

From what has been said it appears that two operations have been reported to in treating scleroderma, but the cause of sympathectomy seems to have more advocates. The blood calcium proves to be normal, in most cases hardly exceeding the limits of the normal value. Already in goitre surgery every surgeon is of the opinion that, in his relation to parathyreoidea, he ought to apply the old rule of *Noli me tangere.* At the District Hospital of Kuopio the normal method for goitre operations is ligation of a. thyreoidea sup. et inf., in other words a so-called physiological parathyroidectomy according to LERICHE (9), whereby a. thyreoidea is ligated as proximally to its leaving a. carotis as possible. We have watched the changes in the blood calcium value before and after the operation and found that in certain cases it may be somewhat lowered, to rise again after a few days to normal values.

Sympathectomy performed by a skilled surgeon is, however, a relatively safe method, for which reason alone the operation ought to be preferred. In illustration of this we might be allowed to report some figures from the District Hospital of Kuopio. During the period 1937—1944, 748 sympathectomies were performed on 567 patients with only two deaths, both old men with arteriosclerotic thrombangitis.

Case Report.

Case No 1. M. S., farmer's wife, 38 years of age. Past history in short: Hereditarily nothing of interest except that a sister at the present is being treated at the District Hospital of Kuopio under the diagnosis: Dermatitis atrophicans Herxheimer. The patient has earlier been in good health. In March 1943 a white, glassily shining, smooth

callosity developed in the skin above the right breast. This focus had a violet coloured outer edge and was slowly growing harder and harder. Later similar maculae began to develop on the abdomen and at last above the left breast.

Status: Constitution ordinary, state of nutrition good. Above both breasts and on the lower part of the abdomen changes in the skin, about the size of a woman's palm: they are shiny in the middle, anaemic and surrounded by a violet coloured halo. On the abdomen cracks have formed in the lesioned part. In the epigastrium several small callous parts can be seen, which show a tendency to become confluent. The hands and feet are slightly cyanotic, though there is no acrocyanosis. From the organs of respiration and circulation nothing noteworthy. Blood picture normal. Blood calcium 8.4 mg %. Fåhræus-Westergren 20/45. WaR —, Kahn —, Diagnosis: Scleroderma.

In October 1943 the patient reenters. Now she complains of shooting pains, radiating from the right breast towards the armpit and of a slowly growing pressure on the intestines on the left side of the abdomen. On October 14, 1943, Sympathectomia lumbalis l. sin. (HÄMÄLÄINEN.) Ether anaesthesia. On October 22, 1943, Sympathectomia l. dx. is performed. (HÄMÄLÄINEN.) Ether anaesthesia. In both cases the two lowest lumbar ganglia are removed. The patient is discharged on October 30. No effect of the operation is observed, except that the patient reports that her legs feel hot. A month later the patient presents herself for further treatment. Now an evident improvement has set in. The skin carapace on the abdomen and above the right breast has been considerably loosened and the callosity above the left breast has almost entirely disappeared. On December 1, 1943 is further performed: Exhairesis nn. splanchnici maj. et min. Extirpatio gangl. lumb. II l. sin. (HÄMÄLÄINEN.) Ether. The patient is discharged on December 9, 1943.

Six months later, on May 5, 1944, the patient presents herself for after-examination. The callosities have now entirely disappeared. On the earlier affected parts now only a slight desquamation can be seen on the skin, which otherwise is soft and looks quite normal. On June 10, 1945, the patient returns for re-examination. Subjectively she is quite well and above all happy at having escaped the feared, daily growing pressure on the abdomen. On examination some small spots with lessened pigment-amount can be observed on the left side, surrounding the sympathectomy cicatrice. No new foci have formed. In this case the changes in the skin above the right breast disappeared, though on this side only the two lowest lumbar ganglia were removed. Literature presents several similar instances, in which an one-sided operation causes a striking improvement also of other, more distant foci.

Case No 2. E. H., farmer's daughter, 12 years of age. Encouraged by the good result in the former case we called this girl to the hospital. She was suffering from advanced diffuse scleroderma, the treatment of which had earlier been considered hopeless. In 1942 the

patient had been admitted to the hospital: large parts of the trunk and the extremities were then affected. The extent of the foci is the following: Along the lateral side of the right leg a focus is spreading from the lateral malleolus upwards, it is slowly growing broader and reaches its largest extent, about the size of two flat hands, in the right glutear region. On the outside of the left thigh, above the knee, a focus the size of a flat hand. In the sacral region a transverse focus. In the shoulder region smaller foci. Over the right deltoidea and trapezius region an area runs down towards the upper arm, spreading partly over fossa supra- and infraclavicularis. Another focus is found on the lateral and dorsal parts of the forearm, ending in the region of the knuckles. The lateral and dorsal parts of the arm and forearm are badly affected. On the breast five smaller foci are found. The abdomen is the seat of great changes. On the right side a focus from the symphysis to the umbilicus is seen, stretching laterally along the iliac crest up towards the rib bow. On the left side a similar focus of smaller extent, about 10 × 15 cm., between spina iliaca ant. sin. and the umbilicus. The worst changes are found in the regions of the left elbow and the right leg, where radiating cicatrices after healed chaps are seen. The skin in the affected parts is of very firm consistence, partly hard as bone, partly atrophied. Newly affected parts have a reddish violet colour. Because of the changes, the movements in the right hip and left elbow are restricted and painful. As a result of the cicatricial contractions a very pronounced atrophy is seen in the hip and the lower leg. The patient is leanish and looks tired. From the organs of respiration and circulation nothing noteworthy, blood calcium 10.9 mg %.

On October 27, 1944. Exhairesis nn. splanchnici et exstirpatio gangl. lumb. I et II l. dx. Ether. (HÄMÄLÄINEN.) Because of the induration and the cicatrices in the skin on the right side of the abdomen, the incision is made along the twelfth rib: splanchnicus and both the upper lumbar ganglia are resected. On November 6, 1944 the foci feel warmer and somewhat softer. The cicatrices are of the same character as earlier. On November 15, 1944. Sympathectomia lumb. l. sin. Ether. (HÄMÄLÄINEN.) The incision passes through the badly indurated skin, and one has a feeling of cutting in cicatricial tissue. Three ganglia (L. III, IV, V) are removed: the operation is rendered more difficult by a lymphadenitis in the retroperitoneal lymphatic system. On November 23, 1944, the wound healed p. p. i., and the patient feeling well. The skin carapaces have been loosened. The lesions situated on the abdomen are no longer sharply outlined and the skin has regained its former flexibility. The left leg feels normal. The skin on the outside of the right leg is very much improved, except the cicatrice and its nearest surroundings. The patient is discharged improved.

Re-examination on May 12, 1945. General condition strikingly good. App. nerv., circulat. et resp. nothing to be noted. Local status: the affected parts have now become quite soft and pliable. Extensive areas with thin and atrophied skin still remain, but complete restitution was not to be expected. This is certainly not astonishing, considering the grave lesions that had ensued from the infected ulcerations. On

Fig. 1.

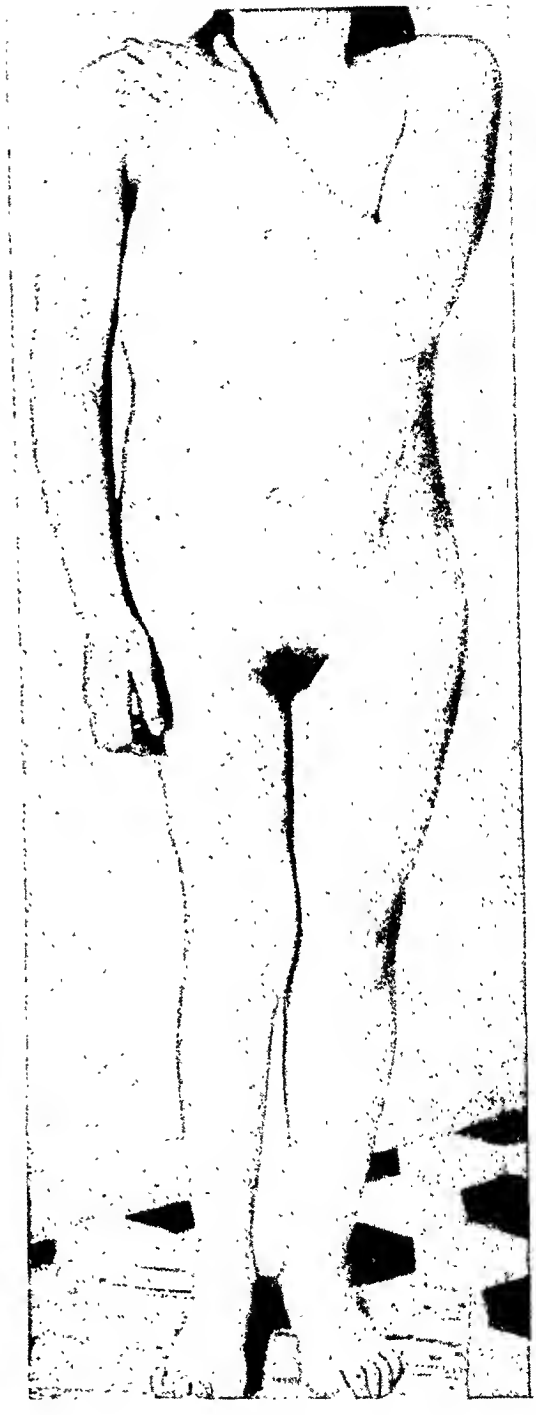

Fig. 2.

HÄMÄLÄINEN and SÖDERLUND: Surgical Treatment of Seleroderma.

Fig. 3.

the outside of the right leg a 55 cm. long and 5—3 cm. broad cicatrice is found, adherent to the underlying tissues. The right thigh and calf badly atrophied, the mobility of the knee is now 180—190°. The mobility of the hip also 180—190°. On the lateral and back sides of the left arm and forearm a cicatrice with pale, atrophied skin is seen: the same is found on the back of the right hand. These cicatrices are not fixed to the substratum, but freely movable. The mobility of the upper extremities quite normal. The skin of the trunk has completely regained its normal consistence and suppleness, only a brownish, spotwise pigmentation remains. The patient is feeling quite well and no new foci have developed. (See figs. 1, 2, 3.) — *Though in this case only a double-sided lumbar sympathectomy was performed, the areas on the upper extremities were so much improved that a stellectomy was not considered necessary.* In this apparently absolutely hopeless case the progress of the disease was anyhow arrested and an invalidated person was saved.

Case No 3. E. K., female adviser of domestic economy 38 years of age. Hereditarily nothing to be noted. She has generally enjoyed good health, except that she has several times had angina. In the spring 1934 the patient observed that the skin under her chin was gradually growing stiff and hard. In 1935 this stiffness gradually spread over the shoulders and the neck. About the new year 1938 she was treated at the Dermatological clinic of the University under the diagnosis Sclerodermia. She felt better for a time. She has also been suffering from an obstinate headache and has at times had a feeling of suffocation. She has observed that the skin of the face is very sensitive to cold and that the region round the mouth is feeling stiff. The patient is feeling dejected and oppressed. Last summer she had a sensation of pressure on the upper parts of the breast and the skin here felt tight when she breathed, especially on exertion.

Status: General condition good, nothing remarkable from the organs of respiration, circulation and digestion. WaR —, Kahn —, blood Ca 9.8 mg %. Colour and moisture of the skin normal. The patient looks as if she were wearing a mask, the facial expression is stiff and lifeless. The skin on the lower parts of the face feels drawn and somewhat indurated. The skin is fixed to the underlying tissues. The skin on breast, abdomen and shoulders is firmer than normal, but softer than that on neck and chin. The indurated parts cannot be lifted into folds. On abdomen, breast and back the skin can be lifted into folds, which nevertheless easily slip from the grasp. The movements of the mouth are slightly restricted. She can open the mouth about 3 cm. The movements of the neck are somewhat restricted, especially the backward bending. The movements of the arms normal.

Diagnosis: Sclerodermia diffusa.

On January 11, 1945, Exstirpatio gangl. thoracocervicalis et thoracalis II l. dx. Ether. (HÄMÄLÄINEN.) The operation technically very difficult because of two circumstances. The pathological changes are not limited to the skin only, but continue down to the skeleton and the

ribs. The tissues are oedematose and toughly rubberlike, they bleed easily, so that it is difficult to get a good hold with tweezers. Truncus thyreocervicalis and a. vertebralis must both be ligated. The plexus roots go beyond the neck of the first rib and cover gangl. stellatum; the orientation and operation are rendered more difficult. Gangl. stellatum lies partly under plexus, so that the upper pole must be left. Downwards truncus is detached without difficulty, but thoracalis II is easily detached. All the time during the operation plexus must be strongly stretched to the side with a blunt hook, in order to get at the ganglia. On January 18, 1945, the wound healed p. p. i., but the patient complains of pains in the right arm. No improvement can be found. The patient is discharged unimproved.

Re-examination on May 10, 1945. General condition good. Blood calcium 9.92 mg %. The changes in the skin have improved. The skin on the right side of the neck and the shoulder has become much softer, it has now a normal consistence and cannot be distinguished from normal skin. On the left side no improvement can be seen. Subjectively the patient reports that her face no longer feels stiff. She has no longer a feeling of pressure and the sensation of suffocation has disappeared. The headache is now localized to the right side of the head and is milder than before. She is still suffering from the sequelae of the plexus stretching. The right hand feels forceless and is easily benumbed. No sensibility disturbances. The fingers cannot be completely flexed. The forefinger is by a maximal bending 3 cm. from the palm and the little finger 1 cm. The others are 2.5—1.5 cm. The mobility of the thumb is complete. This is the sequel of the violent stretching plexus brachialis dx. was subjected to during the operation and these injuries can still be expected to disappear. The patient also wants the left side to be operated on, but the operation is put off till the plexus damage on the right side has improved.

This case presents a completely different pathologico-anatomical picture than the preceding ones. The changes in the skin are hard as in the two earlier related cases, but *they also stretch deep down into the musculature and the intermuscular connective tissue* and render the performance of the operation much more difficult. In this case no improvement has taken place on the other side of the neck and the shoulders.

Case No 4. P. K., businessman, 28 years of age, Kuopio. Hereditarily nothing noteworthy. At the age of nine he drunk lye and was afterwards treated for four years by probing of the oesophagus. Afterwards he felt well and was in good health. In the summer 1940 the skin on the lateral side of the left thigh began to grow darker and the vein net was here more sharply outlined. In August 1941 the skin in the said place grew firmer and stiffer and a short time afterwards the corresponding region on the right thigh and the lower legs and the sacral region changed. The skin in these regions was sensitive to pressure and was beginning to show chaps. The patient had a slightly heightened temperature (37.2—4° C) and had sometimes pains so that he found it difficult to walk. He served at the front, but was sent to a war hospital

to receive medical treatment. There both arms were rapidly affected. His condition did not improve in spite of energetic therapy with arsenic and various hormone preparations. He was discharged from military service because of his illness. The foci showed no tendency to spread. At times the symptoms abated a little to be aggravated again. The left side has all the time been more seriously affected. In October and November he was treated at the dermatological clinic of the University. He had then a sensation of a circular pressure round the lower extremities, the feet were easily benumbed, and he could not walk far. He was treated by Testoviron and Corticosteron. His condition improved during his stay at the hospital and the skin on the left leg became considerably softer. Since then he has at times had dispensary treatment with hormones.

The affected parts were sensitive to cold: the patient also observed that the perspiration in the affected parts was lessened. New foci did not form afterwards, but he is still suffering from a feeling of numbness and from compressing pains in the legs and arms. These pains are worse on the left side. The skin on the outside of the left leg has become thin and shiny: the veins are clearly outlined under the thin skin. At times the patient has been feeling better, but the disease is progressing. The patient has often been recommended to submit to an operation because of his illness, but he has not dared to do so. On May 4, 1945, the patient felt acute pains in the abdomen and nausea. The pains gradually concentrated to the right side of the abdomen and he was admitted to the hospital under the diagnosis Appendicitis ac. Scleroderma.

Status on admission: General condition good. Constitution ordinary. From the organs of respiration and circulation nothing to be noted. Abdomen: Abdominal wall soft. Distinct sensitivity to pressure and defence in McBurney's point. Rovsing +. Skin symptoms: On the lateral sides of the lower extremities, almost symmetrically placed changes in the skin, stretching down to the malleolus externus. The skin is here thin and pale and adherent to the underlying tissues and of a doughlike consistence. It is difficult to lift it up in folds: the veins are sharply outlined. In the ankle region chaps are seen in the skin. On both thighs a couple of spots, 4 × 7 cm., are found, which are firmer than the surrounding parts and feel thickened. In the region of the elbow joints, on the extensor side, an area, 5 × 6 cm., the skin is here of a reddish violet colour and feels firm and oedematose. In the sacral region an oval focus, 4 × 8 cm., of very firm consistence. The edges are of a light violet colour and the central part pale yellowish. Blood calcium 9.46 mg %. WaR —, Kahn —. It is suggested to the patient to have a left-sided lumbar sympathectomy performed in connection with the appendicectomy, to which the patient also consents.

On May 5, 1945, Appendicectomia et sympathectomia lumbalis l. sin. Ether. (Hämäläinen.) Appendix retrocaecal, gangrenous, not perforated. On the left side two large ganglia and truncus are obtained. The day after the operation the patient spontaneously reports that the legs feel warm and that the feeling of numbness has disappeared: the

skin is no longer pale, but of a reddish violet colour. May 14, 1945, the wounds healed p. p. i. The left leg and foot feel warm, 36° C, corresponding value on right side, 33° C. The skin on the left leg dry and scaly, it is easily lifted in folds. On the lateral side of the thigh a skin area can still be felt that is of a yellow colour and of firmer consistence. The patient is discharged. Will return later for renewed operation.

Which general conclusions are we justified to draw on the basis of these operated cases? As we have already mentioned, it has not been our intention to draw, from these few cases, any far reaching, hypothetical conclusions, of which the literature on this subject presents more than enough.

We are content to state that our cases show that scleroderma is not a therapeutically incurable disease. The time of observation is in our cases short, and scleroderma is certainly a disease that at times shows spontaneous improvement, but the first case described above is nevertheless a good example of the effect of the surgical treatment. The patient's illness had a strongly progressive tendency and showed already alarming symptoms. Six months after the operation the change in the skin had practically completely disappeared, and this state has now lasted one and a half year.

As in our cases no disturbances in the calcium metabolism have been observed, it is natural that no attacks have been made on the parathyroids. Besides, the histological changes in extirpated gangl. parathyreoidea, as they have been described in the literature, have been of rather problematic nature, and as to the hypercalcaemia, it has kept within almost physiological limits. We, for our part, recommend sympathectomy as the method of treatment, especially as the risk is smaller and the parathyroids are organs that we have learnt to respect because of the danger of tetany.

It would be a great step in the right direction if the surgical treatment of scleroderma would be known also by the dermatologists, so that the cases of scleroderma that are found to baffle all other treatment would be remitted to the professional surgeon. In the fight against this disfiguring and invalidizing disease, everything possible ought to be tried in order to mitigate the sufferings of the patients.

Summary.

After a short historical survey four cases of scleroderma treated by sympathectomy are described. Time of observation: $1^1/_2$ year and shorter; the results have so far been good. It is stated that scleroderma is not an incurable disease and that the surgical treatment is justified. Sympathectomy is preferred to parathyroidectomy, one of the reasons being that this operation is less risky. In conclusion the desirability of a co-operation between dermatologists and surgeons is stressed.

Zusammenfassung.

Nach einem kurzen geschichtlichen Überblick werden vier mittels Sympathektomie behandelte Fälle von Sklerodermie beschrieben. Die Beobachtungszeit ist $1^1/_2$ Jahre oder weniger, die Ergebnisse waren bisher gut. Es wird festgestellt, dass die Sklerodermie keine aussichtslose Krankheit darstellt, und dass die chirurgische Behandlung ihre Berechtigung hat. Die Sympathektomie wird der Parathyreoidektomie vorgezogen, u. a. wegen der geringeren Operationsgefahren. Schliesslich wird betont, dass ein Zusammenarbeiten der Dermatologen und Chirurgen bei der Behandlung der Sklerodermie wünschenswert ist.

Résumé.

Après un court historique, les auteurs décrivent quatre cas de sclérodermie traités par la sympathectomie. Temps d'observation: $1^1/_2$ an au moins. Jusqu'ici les résultats ont été bons. Les auteurs constatent que la sclérodermie n'est pas une affection sans espoir et que le traitement chirurgical est justifié. La sympathectomie est préférable à la parathyroïdectomie, surtout à cause des risques moindres de l'opération. En conclusion, l'auteur souligne l'utilité d'une collaboration entre le dermatologue et le chirurgien dans le traitement de la sclérodermie.

References.

1. ADSON, ALFRED W., O'LEARY, PAUL A. and GEORGE E. BROWN abstract. Zentralorgan f. d. ges. Chirurgie 53, 395, 1931. — 2. BERNHEIM, ALICE R. and JOHN H. GARLOCK: Ann. Surg. 1012—1025, 101 1935. — 3. BERNHEIM, ALICE R. and JOHN H. GARLOCK: Arch. Surgeon 543—555, 38. 1939. — 4. CRAIG, MCWINCHELL, K. and JAMES W KERNOHAN: Surg. etc. 767—778, 56, 1933. — 5. HÄMÄLÄINEN, M.: Nordisk Medicin 26, 869, 1945. — 6. JEANNENEY: Presse méd. I, 515, 1937. — 7. LAURELL, A.: Sv. Läkartidning 40, 170—172, 1943. — 8. LERICHE, R. & R. FONTAINE: Rev. de Chir. 65: 4, 285—318, 1927. — 9. LERICHE, R. & A. JUNG: Bull. soc. nat. chir. 57, 609—618, 1931. — 10. LERICHE, R.: Bull. soc. nat. chir. 58, 7—11, 1932. — 11. LERICHE, R.: Bull. soc. nat. chir. 61, 42—50, 1935. — 12. LERICHE, R. & A. JUNG: Presse méd. II, 1361—1363, 1935. — 13. LERICHE, R.: abstract. Zentralorgan f. d. ges. Chirurgie 106, 76, 1942. — 14. LERICHE, R. & R. GATE: abstract. Zentralorgan f. d. ges. Chirurgie: 106, 76, 1942. — 15. MOULONGUET, P.: Bull. soc. nat. chir. 57, 1529—5131, 1931. — 16. MYHRMAN, G. & G. MALM: Nordisk medicin. 1943. — 17. PLETNEFF, D. & TH. PLOTKIN: Presse méd.: II, 1653, 1935. — 18. PUUSEPP, L.: Sovet chir. 10, 732—735, 1936. — 19. SUNDER-PLASSMAN, P. & F. JAEGER: Dtsch. Z. Chir. 253, 263—292, 1940.

From the General Department of the State General Hospital of Tampere.
(Surgeon in Chief: V. TUOMIKOSKI, M. D.)

Indefinite Pain in the Right Flank and its Origin — a New Symptom of Ileitis.

By

K. R. INBERG.

Besides upper abdominal pain which depends on gastritis, gastroduodenal ulcer and other organic, pathologic changes acute or chronic pain conditions in the right flank and iliac fossa cause the most common diagnostic problem for the surgeon. In this connection the differential diagnosis of appendicitis must above all be taken into consideration. From diagnostic and differential diagnostic difficulties arise a glaring grievance in the ariving of patients into hospital treatment. The cases which demand an urgent operation come often — even nowadays — too late in spite of a repeating accentuation by the surgeons for an early operation. On the other side again patients who do not need an operation, are even too ready — often with recommendations from physicians — to come to the hospital because of an obscure pain in the right flank or iliac fossa. Also a useless appendicectomy which follows an unjust diagnosis, is in certain cases injurious and even dangerous.

Especially in cases of chronic pain, the importance of appendicitis has been overestimated. According to MARSHALL (1938) in dealing with acute right iliac fossa pain, the appendicitis might be correct diagnosis in 60 per cent., but in chronic cases not even in 10 per cent. The excessive accentuation of the importance of appendicitis has obviously happened at the cost of other intestinal inflammations near vermiform appendix. This is indeed easy to understand, because non-specific, limited inflammations in the ileum are insufficiently known. SPRENGEL's (1906) well known assertion, that appendicitis is the only cause to all inflammatory

conditions of the right iliac fossa, is only by and by verified as wrong. After CROHN and others (1932) published a paper on a chronic, obstructive inflammation of terminal ileum, the interest in this, later on as a new entity approved disease aroused and the subject was treated in the literature in an increasing manner. The disease in question is, however, not quite new, as among others a paper of mine from 1939 nearer reports. The etiology is still unknown. Over ten years I have been dealing with ileitis in its different forms.

Later on when I was about 2½ years within the period of 1935—1938 the substitute of the Chief Surgeon to the General Hospital of Tampere, I was exceptionally interested among abdominal diseases in non-specific inflammations of the intestines. The notes on the past history and symptoms and signs were attempted to make complete. In the observations on the operations I took part myself if possible. The operative findings show that the typical, chronic, obstructive form of regional ileitis which leads to resection is very rare. I could not observe a single certain case during the time just mentioned. The first case is from the year 1939 (No. 311). The disease appeared in a 15-year old boy. The operation was performed twice, the first time in an acute stage. — Non typical, acute or chronic, often wide spread inflammations of jejuno-ileum, especially of the latter, were a little more common. The differentiation of a certain stage of ileitis from an already earlier well known condition, named ileum terminale fixatum in which sear formations in mesenterium of terminal ileum are in foreground, is not possible in an inflammation stage of the last mentioned disease. In addition to that my microscopical examination of ileum show changes similar to those seen in the genuine form of ileitis. — The hyperplastic ileo-typhlitis, which earlier was considered nearly always caused by tuberculosis, proved also to be very uncommon (1 case). Instead of this I have more often observed an acute perforative or chronic sigmoiditis. — In connection with appendicectomy there was carried out a number of observations on inflammatory changes of the ileo-coecal region. A part of macroscopically normal vermiform appendices were investigated microscopically by comparing with normal cases. The same was done with other deposited tissue samples. In the General Hospital of Tampere between June 1st 1935 — May 31st 1938, there were treated 7,202 in-patients in all. During the same time the appendix was removed 840 times (19 per cent. of all operations). Among these in 124 cases vermiform appendix showed macroscopically no changes, but there were contemporaneous inflammatory conditions in ileo-coecal region. The group of diagnostic errors caused by extra-intestinal conditions, among others by diseases of the kidneys and ureter, pneumonia and so on, was very small compared with this. The changes were: hyperplastic lymphatic glands or their conglomerates and obvious inflammations of serosa or the deeper layers. The inflammation, which was located more often — that is in 90 cases — to the

terminal ileum or around it, appeared in general clearer as in some cases earlier published by me. An analysis of the symptoms and signs of the results of laboratory investigations and operative findings and comparison with the clinical picture of regional ileitis showed that in most cases the disease in question must be a mild form of ileitis. The pain and other symptoms received so their explanation in spite of negative findings with regard to appendicitis. According to my observations mesenteric lymphadenitis in adults at least very seldom can be held as a separate disease, for an accurate inspection or an microscopical examination usually showed contemporary intestinal changes. The enteric origin of mesenteric lymphadenitis is also nowadays quite commonly approved. — In the last years I have taken, according to my hospital experiences, a more and more conservative standpoint with regard to the treatment of abdominal cases with somewhat uncertain pain symptoms. Even exploratory operations in this connection I have had indicated only in exceptional cases, because in my opinion, at least to some extent, it is possible to clear the diagnosis on the ground of symptoms and signs. The war has broken off my possibilities to make continuous observations on the various forms of ileitis, its etiology, and the rate of occurrence.

According to my own investigations and literature studies the clinical picture characteristic as well to the progressive, severe inflammation, which often leads to complications as to its milder form can be defined quite exactly. A *progressive regional ileitis* is a chronic lesion. The disease, which appears usually in the years of growth or in young adults localizes mostly, but not always, in the terminal ileum. The inflammation shows a certain tendency to proceed to partial intestinal obstruction and intraperitoneal abscess and intestinal fistula formation. Sometimes the acute initial phase resembling appendicitis caused an appendicectomy, and this operation was understood to be in fault for the complications. It is true STRÖMBECK (1937) claims it as not being verified, that an acute stage should precede the chronic form. Symptoms and signs are intestinal pain, tenderness and diarrhea, sometimes with mucous and bloody stools. In addition to that there are observed general symptoms and signs of a slight infection: a moderate fever, loss of weight, and leucocytosis. Tenderness on pressure is situated in the right lower quadrant, as announced for example by ROSENBLATE and others (1936) and CABOT and ADAMS (1938). — Typical for the *mild form of ileitis* are abdominal pain, local tenderness, fever almost immediately in the beginning, and symptoms of intestinal disorders, chiefly diarrhea, flatulence, and borborygmus. The recurrence of the symptoms and signs during long periods — often during months and years

— usually in second or third decade is typical. The exacerbations with some resemblance of appendicitis also characterize the disease. The pain and especially tenderness localize in the right area of mesenterium. My follow-up inquiries, although small in number, have shown that this form of the condition does not give rise to intestinal stenosis. — Abdominal pain, general inflammatory and intestinal symptoms and signs unite so closely that, according to my opinion there can be spoken of a special syndrome — ileal syndrome. It is true, all the symptoms need not occur contemporarily — some of them can be lacking or are appearing less clearly. An accurate knowledge of the past history usually even then clears the presence of the typical syndrome.

Before the praeoperative diagnosis can be made, SNAPPER (1938) holds an X-ray investigation absolutely necessary. It seems to me that there is an attempt to pay too much attention to the string sign of KANTOR, first described by him in 1934 in connection with this disease. SCHINZ and others (1939) for example mention this as the only radiological sign of ileitis. In those cases of mine which concerned the mild form and in which an X-ray investigation was performed by a radiologist determining of a barium narrowness was not possible. This is obvious if we think that the pathologico-anatomic basis of the sign must be an infiltrated, thickwalled ileum with a simultaneously narrow lumen. Instead of that the statement of CABOT and ADAMS, according to which the barium meal usually shows a hypermotility and later a narrowing of the lumen, is more accurate. The determination of the hypermotility is quite important: several times this sign in those of my cases in which past history and objective examination made the presence of a mild ileitis possible remained as the only one verified by the radiologist. It should of course be remembered that this is no sign pathognomonic only for ileitis.

The diagnosis of ileitis mostly have had to be held uncertain. The symptoms and signs yet known are somewhat indefinite. The *differential diagnosis* between ileitis and appendicitis may be possible only at an operation.

During many years I have made some observations on local tenderness and pain, which facilitates the diagnosing of ileitis.

The question concerning abdominal pain has been treated in a wider extent on a theoretical and especially practical point of view among others in a paper of mine from the year 1938. Therefore I restrict myself to mention only the most central points of it. There are dis-

tinguished as well deep as superficial abdominal pain and tenderness. The sensations of pain are believed to be transmitted either by autonomous or cerebrospinal nervous system. The question is still finally unsettled. Taking into consideration the situation of the pain regarding the diseased organ, there is to be spoken of a local, farther on radiating or a referred pain. My observations, concerning gastric, duodenal and jejunal ulcer, seem to show that to the deep tenderness on pressure joints an inflammation-lymphangitis and lymphadenitis in the ligaments supporting the organ. My measurements showed a correspondence of the point of maximum tenderness with these inflammatory changes. My clinical observations which are confirmed by pathologico-anatomic examinations and in one case made radiological observations speak in favour of the origination of tenderness and pain, as transmitted by the cerebrospinal nerves, in the surroundings of the abdominal organs. I do not have any wishes to deny the importance of spasmodic contractions and dilatations of the digestive canal as causing pain sensations through stretching and pulling the cerebrospinal nerve end organs in the ligaments, but I am pointing out inflammation as probably the most general factor in the origin of abdominal pain. Of course inflammatory conditions cause pain except through mesenterium also through parietal peritoneum. Consequently, I deal with the question of pain from another point of view than many authors of the last years, for example BAUER (1939). They are excluding entirely pain joining visible anatomic lesions and inflammations restricting themselves to treat only the part played by sympathicus in different kind of pain conditions even in neuralgia. With our knowledge in its present phase, it does not seem at all certain, if the irritation of autonomous nerves in the organs produce a clear and distinct abdominal pain. — As a reason for my earlier pain studies were the microscopical investigations on the inflamed ileum and its mesenterium.

The tenderness and pain characteristic to both the severe and mild form of ileitis may remind of similar symptoms and signs, which are held to be typical for appendicitis. It is well known that in the diagnosis of appendicitis observing the position of the point of maximum tenderness has an important significance. From the fact, how the point of maximum tenderness corresponds with Mac Burney's point, the diagnosis may benefit. Only there is to be taken into consideration, that the latter point is not fixed, that is situated in the same place in all people suffering from appendicitis. The known distance from anterior superior iliac spine can be held only as a somewhat average measure from the prominence just mentioned. The area of maximum tenderness can be located in the line drawn to umbilicus or cranial or caudal from it. Sometimes, though very seldom, it can also be determined considerably nearer the umbilicus.

Already earlier in the literature there have been mentioned observations, although small in number, concerning the localization of the *tenderness on pressure* in ileitis to a point in the abdominal parietes which is not the same as Mac Burney's point. STRÖMBECK (1932) states in his paper on tuberculous and non-specific mesenterial lymphadenitis that a somewhat limited tenderness often was present in Kümmel's point K. KÜMMEL (1921) once pointed out in chronic appendicitis the lack of signs regarding Mac Burney's and Lanz's points so valuable in the

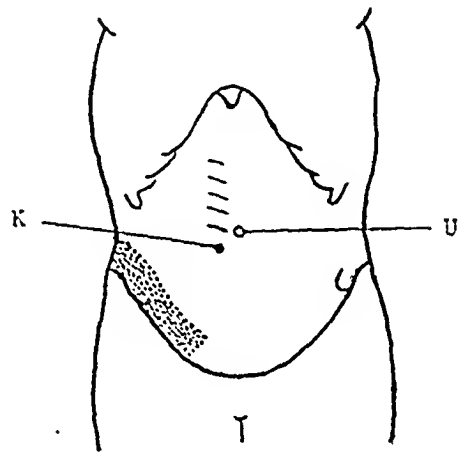

Fig. 1.

diagnosis of acute cases. Instead of that the tenderness is often situated nearer the umbilicus, about 1—2 cm downwards or to the right.

In my own cases, too, I observed — after becoming more familiar with the clinical picture of regional ileitis — the localizing of the deep tenderness distincter near umbilicus. Observations on the local tenderness have been made in 30 cases of ileitis. Of these 27 cases are to be kept as belonging to the mild form. The diagnosis has been verified by an operation. In three cases again symptoms of obstruction appearing in an earlier or later stage have led to a resection of the ileum or an ileo-transversostomy. The *point of maximum tenderness was situated 2—6 cm, on an average 3.5 cm* (fig. 1 — K) *to the right and below umbilicus* usually in the line drawn to anterior superior spine or a little caudal of it. As the length of the spino-umbilical line according to my measur-

ings[1] is 14.0 cm and as Mac Burney's point is situated near superior anterior spine — according to one definition 5—6 cm from it — points characteristic for ileitis and appendicitis do not congruate. — The point of greatest tenderness in my notes was described to have the size of 1—2 finger-tips.

I have also carried out observations according to which it seems possible to explain the appearance of the tenderness. Several times in my operations the measured point of maximum tenderness was seen to correspond with the greatest conglomerate

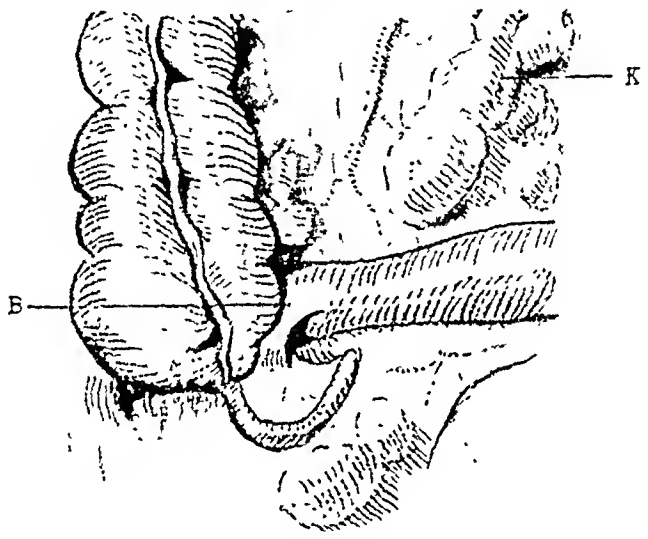

Fig. 2.

of lymphnodes, usually 5—6 cm, sometimes a little farther on from the ileo-coecal valve, several centimeters from ileum, near the base of its mesenterium (fig. 2 — K). From this point furthermore continued a string of enlarged lymphatic glands straight upwards in connection with inferior vena cava as high as it was possible to touch. Otherwise again in those cases where the maximum tenderness was to be found somewhere else the operation often showed a corresponding conglomerate. The greatest tenderness to pressure in perityphlitis and typhlitis is situated in general more laterally than in ileitis, on the cranial side of Mac Burney's point. The enlarged lymphnodules are in the ascending

[1] The measurings were carried out in 349 persons of West-Finland in an age 18—70. Persons with abnormal shape of the abdomen (adipositas, meteorism and so on) were excluded. With a stiff measuring-tape the shortest distance between superior anterior spine and umbilicus was measured. The estimations varied from 12 to 16.5 cm.

mesocolon. Often in ileitis also the wall of the coecum is slightly inflamed and there can be seen lymphatic glands both in the mesenterium and mesocolon. The inflammation in the terminal ileum usually however is intensely marked and the conglomerate similarly larger (fig. 2). The tenderness is then found in the typical place for ileitis. If the changes in the coecum are distinct it is of course convenient to speak of ileotyphlitis. In a severe, acute stage of ileitis, when the inflammation complicated by peritoneal irritation localizes in a wide area, enlarged lymphatic glands are to be found in different places in the right iliac fossa. This was seen in one case of my material, which I operated upon (No. 311/1939). Fig. 2 presents, with slight schematism, the operative findings in this case. The terminal ileum was inflamed severely and oedamatous, giving an impression of a rigid tube. A wider area was found tender, but the position of the point of maximum tenderness was typical. Wide spread tenderness often extending on the other side of Mac Burney's point was quite common. The slight pain sensation on pressure may sometimes be peritoneal in origin, partly again mesenterial. The deep tenderness is characterized by the moving of the point of greatest tenderness in congruence with the organ and its ligaments, when changing the position of the patient. In preferable conditions this can be demonstrated easily. — The opinion, that tenderness often corresponds with lymphadenitis, is confirmed also by the following observation of mine. Very often a narrow area as far as near the costal margin was found tender. This is schematically drawn in fig. 1, from which for the sake of clearness the area in the right iliac fossa and round the umbilicus is excluded.

Some anatomical and clinical features are also to be taken into consideration. The basis of the mesenterium with a length, according to TREVES, of 6 inches begins just on the left side of the second lumbar vertebra, and follows an oblique line running downwards to the right iliac fossa. It crosses the aorta and also the vertebral column in the level of the forth lumbar vertebra, and ends just caudal of the spino-umbilical line in ileo-coecal junction (TREVES, CORNING). The umbilicus is projected upon the intervertebral disc between the third and fourth lumbar vertebra. From these circumstances follows that the end of mesenterium with its typical conglomerate of lymphnodules must be situated near the umbilicus on the right side and just under the spino-umbilical line. — In 21 operations where an acute inflamed

vermiform appendix was removed part of the intestinal canal presenting itself — sometimes under the covering omentum and once under the tip of the appendix — in the wound placed in the tender point, was ileo-coecal valve (fig. 2 — B). This region again almost exactly corresponds with the lowest regional lymphatic glands situated in the base of the mesenteriole, behind the intestine. Besides of this I have not found out that Kümmel's points should be characteristic for the very uncommon chronic appendicitis. KÜMMEL's material might have consisted of cases of ileitis, although he denies the presence of pathologic changes in the appendices.

The *pain* in ileitis, especially in an acute stage and in the exacerbations, very often begins in the same way as in appendicitis — in epigastrium and then in some hours moves towards the umbilicus and to the right of it. MORLEY (1931) points out, that ileal pain as a real, vague intestinal pain is to be felt in the middle line above the umbilicus. According to JONES (1938) pain in the area below umbilicus again points at the ileum. The latter standpoint seems to me more likely.

Besides probably mesenterial and peritoneal pain from the backwall of abdominal cavity, I have observed still another kind of pain in ileitis. The pain is referred, that is, it is not situated in the area of "real" ileal pain. My first observation, made in the year 1936, is from a female patient, treated in hospital 4. II.—11. II. (No. 232). The patient had in addition to a protracted right side abdominal burning an obstinate pain in the right flank and iliac fossa close to the iliac crest (fig. 1). Later on I have noted this separate pain symptom altogether in 32 cases of ileitis. My observations concern with one exception the mild form of the disease. All patients have been operated upon. Very often the pain is announced to be clearest in the flank on both sides of the highest point of iliac crest. The painful area also is slightly tender. The right side pain has often irritated the patients, because they have believed to suffer from an appendicitis. To this disease usually, however, does not belong a separate, limited flank or iliac fossa pain. In gangrenous appendicitis, which diagnosis consequently is to be held certain, the lacking of this symptom was noted by me in a consecutive series of 26 cases. The pain symptom I have observed is strictly to be separated from HEAD's sign already on account of its regularity. The differentiation should also be made from intercostal neuralgia, myalgia and so on.

In out-patient departments, in my private practice, and in the army some of the patients with abdominal disorders I have examined, announced that they were suffering from a right side flank pain. The examination was made because an appendicitis was suspected. In certain seasons, above all in winter time, but sometimes in the summer, the number of these cases, occasionally, has not been quite insignificant. Because the diagnosis has not been verified at an operation it is better, at least in this connection, to speak about the ileal syndrome than ileitis. The flank pain symptom belongs consequently quite constantly to the syndrome just mentioned. Sometimes, however, this symptom is lacking from an otherwise typical syndrome, but the fault seems then to be at least to some extent in the defective intelligence of the patient. The possibility that the syndrome could occur also in other abdominal diseases must remain unsettled for the present in lack of enough versatile and sufficient observations. For example the relation of ileitis to the so called fermentation dyspepsia, the importance of which among others SVARTZ (1934) has pointed out, is not clear, because the stools in my cases were not examined in regard to Welch-Fraenkels bacillus. Therefore can not be excluded with certainty, that some of the cases should belong to this disease. The fermentation dyspepsia namely localizes in coecal region and among other signs there is mentioned a right side tenderness. I do not believe that the diagnosis in most of cases of ileitis operated upon should not be correct. Among others my bacteriological observations although defective and interrupted speak against it. There were found cocci regularly in the peritoneal fluid and in mesenteric glands. The same observation has partly been made earlier somewhere else. Of course it is possible that mild cases with different diagnoses without operative or post mortem verification belong to the same group of diseases looked upon from different angles by the surgeon and the physician. At all events, it is the duty of the surgeons to try to solve the problem of the ileal syndrome, with which they have the opportunity to come into contact for differential diagnostic reasons.

It seems to me possible to give a satisfactory explanation on the origin of the referred pain, typical for ileitis, by taking into consideration certain anatomical and pathologico-anatomical facts, above all the position of the inflammatory changes in relation to the cerebrospinal nerves. My account on the operative

findings and the tenderness symptom facilitate the understanding of the origin of the pain.

Fig. 3 shows the back wall of the abdominal cavity after removing the peritoneum. It has been drawn combining certain details from the text-books of CORNING, SOBOTTA, SPALTEHOLZ and others. On the right side there are seen the three spinal nerve trunks of the lumbar segments. The relation of their origin to each other and to certain fixed points has been observed. The projection of the umbilicus and Kümmel's point in regard to the spine has been marked (fig. 3 — U and K). Iliohypogastric nerve (fig. 3 — I. H. N.), which is situated

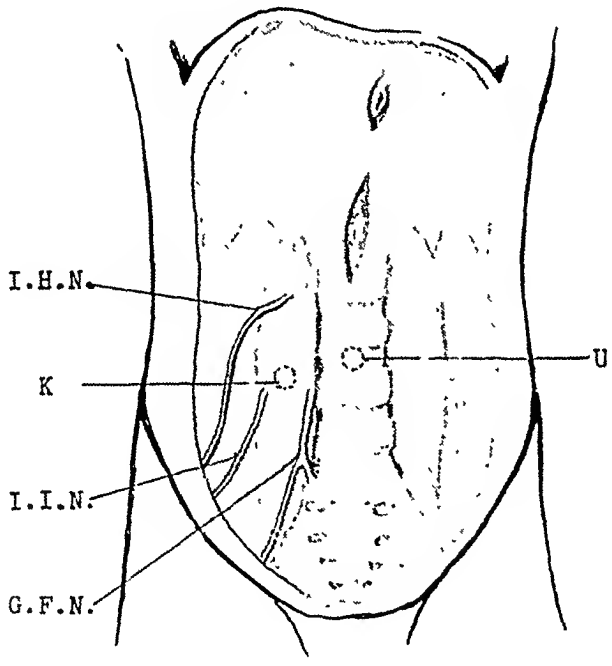

Fig. 3.

uppermost, is a mixed nerve like both the others. It comes from L_1, and perforates the psoas magnus muscle to the inner surface of quadratus lumborum. After perforating the transversus abdominis above the iliac crest, the nerve is to be found between the muscle just mentioned and internal oblique and terminates in the region of the subcutaneous inguinal ring (fig. 4 — I. H. N.). The middlemost—ilioinguinal nerve (Fig. 3 — I. I. N.) — also arises from L_1. It is thinner and inconstant. The direction of course is the same (fig. 4 — I. I. N.). Sometimes it lies just beside the former nerve. The third nerve — genitofemoralis — arises from L_2 and is situated more medial (fig. 3 — G. F. N.).

The flank pain observed by me reminds of neuralgia and it appears in a narrow area (figs. 1 and 4), where two nerves with their branches are lying near the surface. The lymphadenitis is situated

near these nerves. It is true, the point of maximum tenderness and the corresponding conglomerate may remain just a little in the inner side of the nerve, in case this perforates the psoas magnus muscle in the lateral margin (fig. 3). The string of enlarged lymphatic glands, which continues upwards from the basis of the mesenterium, instead, very probably crosses the iliohypogastric nerve. Inflammation in the lymphnodes easily spreads to the covering peritoneum in a somewhat wider area as my microscopy of mesenteritis shows. Therefore the inflammation probably reaches the ilioinguinal nerve. BRAUN indeed claims that the irrita-

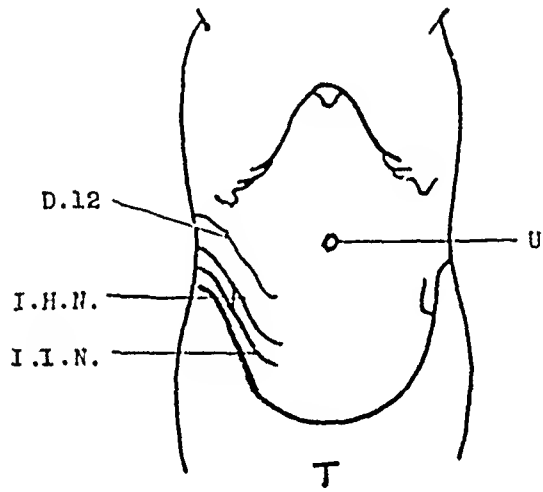

Fig. 4.

tion of the nerve trunk causes only a slight sensation of pain, but numerous observations show the arising of back ache through irritation of the cerebrospinal nerves in the retro-peritoneal space. Also a chemical irritament, that is blood, produces pain in the back when coming into contact with the nerves mentioned before. This is shown by an observation of mine from one case (No. 2187/1938), where a calcified aneurysma of the abdominal aorta had caused a large retro-peritoneal hematoma. — It is well known that also sinusitis can be the causative factor of an inflammation in nerves near by.

The flank pain symptom seems to be explained in the best way by considering it as a neuritis in iliohypogastric and probably in the adjoining nerve caused by an inflammation close by.

My opinion is supported further by the fact that the pain dis-

appeared in connection with a diagnostic analgesia. The novocaine injection was performed three finger broad in the abdominal muscles on the highest part of the iliac crest or a little caudal, close to the bone. For the present there are only few observations. In three cases, however, the phenomenon appeared distinct. MARSHALL has already in 1936 recommended test-blockade in cases of uncertain flank pain conditions, in which the pain is suspected to arise from diseases of the spine, neuritis, neuralgia and so on. According to MARSHALL it is not possible to make use of this method of examination when the presence of a disease in the spinal cord, for example herpes zoster, or arising of the pain deeper in the body can be suspected. Although he does not explain it nearer, this is probable, because pain in those cases can be referred in a wide area, that is in peritoneum or pleura, skin (Head's sign), and in the tissues between. — The lacking of a typical iliohypogastric neuralgia from the clinical picture of appendicitis depends on a different kind of lymphadenitis.

I have not seen the pain symptom described by me mentioned in the literature up to 1941. ALTSCHÜLER (1938), however, has described the tenderness beside the iliac crest and local muscular rigidity in the same area as a reliable sign in retrocoecal and chronic appendicitis. Also in one of our military hospitals — as far as I know — right side myalgia has been considered as characteristic for the acute stage of the disease. These observations may concern the same symptom.

Already earlier COPE has pointed out the differential diagnostic significance of psoas and obturator tests and of determination of tenderness, arising in the nerves of lumbar segments, in recto-vesical and recto-uterine pouches. The branches of the nerves of dorsal segments descend on ventral side considerably below the corresponding segment. Thus greater part of the anterior wall of the abdominal cavity gets its nerves from the dorsal cord (fig. 4). Pain arising from the lungs (pleura) or the heart can so be referred in the abdominal area. It is therefore important to observe the appearance or lacking of tenderness also in posterior part of the abdominal cavity. The flank pain symptom, when it occurs, can consequently be used as an aid in the differential diagnosis between intra-thoracic and abdominal conditions.

It is obvious, that from my observations on the points of tenderness also radiography can benefit. According to many modern authors (OPPENHEIMER 1931, BOWEN 1938, SCHINZ and others)

notice should be paid to the tender points in the radiological examination of appendicitis. I cannot, however, agree with the last mentioned authors in it, that the examination in acute stage never should be well founded. There are many abdominal cases presenting themselves with slight acute symptoms and signs — inflammations of ileum, appendix and so on — in which confirming of the diagnose decidedly is well grounded. — Making conclusions of pathological changes of the intestines from outline radiography alone is uncertain.

An useless appendicectomy is always a rejectable operation. Especially when the symptoms arise from an ileitis, the condition may continue. The dissatisfied patient, however, combines his pain- and other symptoms with the operation and thinks he is suffering from adhesions. Also the operation can cause an increase of the inflammation and thus indirectly fistula formation and even outbreak of an obstruction. — In diagnosing the incompletely known ileitis different methods of examination are well grounded and in the clinical examination of this condition the observation of all the symptoms and signs is necessary.

Summary.

The progressive, regional ileitis according to the observations made in operations by the author is very rare, the milder form of the condition instead is more common. The symptoms and signs in both forms are somewhat identical. The principal difference is in the intensity. The differentiation from appendicitis has caused most difficulties. An explorative operation in this connection is not often necessary, because, at least to some extent, it is already possible to determine from symptoms and signs the nature of the disease. — The point of maximum tenderness was situated in 30 cases of ileitis, 3 of which belonged to the severe form, on an average 3.5 cm to the right and below of umbilicus. In operations the measured point of maximum tenderness was seen to correspond with the greatest conglomerate of lymphnodes, usually 5—6 cm., sometimes a little farther on from the ileo-coecal valve, several centimeters from ileum, near the base of its mesenterium. From this point still continued a string of enlarged lymphatic glands straight upwards crossing very probably the iliohypogastric nerve.

Except mesenterial and peritoneal pain from the back wall of

abdominal cavity, the author has observed still another and quite a characteristic pain symptom in ileitis. The pain is referred and is not situated in the area of "real" ileal pain. It is announced to be clearest in the right flank on both sides of the highest point of iliac crest and in iliac fossa close to the bone. This separate pain symptom was noted altogether in 32 cases of ileitis. — It is possible to give a rational explanation of the origin of the tenderness and pain in ileitis. The flank pain reminds of neuralgia and it appears in a narrow area, where two nerves — the iliohypogastric and ilioinguinal — are lying near the surface. The lacking of typical iliohypogastric neuralgia from the clinical picture of appendicitis depends on a different kind of corresponding and irritating lymphadenitis. The pain disappeared in connection with a diagnostic analgesia. The test-blockade was performed three finger broad in the abdominal muscles on the highest part of the iliac crest, close to the bone.

Zusammenfassung.

Die fortschreitende, regionäre Ileitis ist nach den Beobachtungen des Verfassers äusserst selten, die mildere Form der Krankheit ist dagegen viel gewöhnlicher. Die Symptome sind in beiden Formen einander ähnlich. Der hauptsächliche Unterschied besteht in der Intensität. Die Unterscheidung von der Appendizitis verursacht am meisten Schwierigkeiten. Die explorative Operation in diesem Zusammenhange ist im allgemeinen nicht begründet, weil die Diagnose schon infolge der Symptome gestellt werden kann. — Die grösste Druckempfindlichkeit war in 30 Fällen von Ileitis, von denen 3 zu der schweren Gruppe der Ileitis gehörten, 2—6 cm, durchschnittlich 3.5 cm von dem Nabel rechts hinab. In den Operationen konnte festgestellt werden, mit der Hilfe der Messungen, dass der Punkt der grössten Empfindlichkeit der grössten Häufung der Lymphdrüsen entsprach, gewöhnlich in einer Entfernung von 5—6 cm, bisweilen auch ein wenig weiter weg von der Valvula ileo-coecalis, in einer Entfernung von mehreren Zentimetern von dem Ileum, in der Nähe von dem Basis seines Mesenteriums. Von dieser Stelle ab setzte sich ein von Lymphdrüsen gebildeter, empfindlicher Strang gerade hinauf n. iliohypogastricus kreuzend.

Ausser dem sogenannten Darmschmerz und ausser dem Rükkenschmerz, der von dem Reiz des hinteren Peritoneums herrührt,

hat der Verfasser festgestellt, dass mit der Ileitis noch ein anderes und für sie ganz bezeichnendes Schmerzsymptom verbunden ist. Der Schmerz ist ein sogenannter Fernschmerz, das heisst, er befindet sich nicht auf dem Gebiete des eigentlichen Ileumschmerzes, sondern in der rechten Seite und in der Darmbeingrube ganz neben crista iliaca. Dieses getrennte Schmerzsymptom ist in allem in 32 Ileitis-Fällen festgestellt worden. Gleichermassen wie die der Ileitis eigentümliche Empfindlichkeitserscheinung, kann auch das Schmerzsymptom vernunftsgemäss erklärt werden. Der obenerwähnte Seitenschmerz erinnert seiner Beschaffenheit nach, vor allem seiner Begränzung nach an die Neuralgie und er kommt auf einem Gebiete vor, wo zwei Nerven — n. iliohypogastricus und n. ilioinguinalis — in der Nähe der Haut laufen. Der Mangel der Iliohypogastricus-Neuralgie bei dem Krankheitsbild der Appendizitis kommt von einer verschiedenartigen Lymphdrüsenentzündung. Man konnte feststellen, dass das Schmerzsymptom nach dem Zustandebringen der diagnostischen Analgesie verschwand. Die Probeblockade wurde in den Bauchmuskeln auf einem drei Finger breiten Gebiete neben der crista iliaca, auf deren höchsten Punkt gemacht.

Résumé.

L'iléitis progressif régional selon les observations d'opération de l'auteur est très rare, la forme plus bénigne de la maladie est beaucoup plus ordinaire. Les symptomes dans toutes les deux sont très semblables. Principalement il n'y a qu'une différence dans l'intensité. La distinction de l'appendicite offre les plusieurs de difficultés. L'opération explorative n'est pas motivée puisqu'on peut poser la diagnose déjà sur la base des symptômes. — Maximum de la tendresse était situé dans 30 cas de l'ileitis, dont 3 appartenaient au groupe de l'ileitis grave 2—6 cm, en moyenne 3.5 cm du nombril. On pouvait constater dans les opérations à l'aide de mesurages que maximum de la tendresse correspondait au plus grand assemblage des glandes lymphatiques en général à une distance de 5—6 cm quelquefois un peu plus loin de la valvule ileo-coecalis, à une distance de plusieurs cm de l'iléon pres de la base de son mésentère. De ce point continua encore un courant formé par les glandes lymphatiques montant directement de long de la veine cave inférieure.

Au surplus de ce qu'on dit de la douleur intéstinale et de la douleur du dos émanante de l'irritation de la péritoine l'auteur a constaté qu'un autre symptome de douleur se joint aussi à l'iléitis. Cette douleur est spécialement typique pour l'iléitis. La douleur est une douleur à distance; cela veut dire elle n'est pas située dans la région spéciale de la douleur de l'iléon, mais dans le flanc droit et dans le creux de l'os iliaque tout à fait à côté de crista iliaca. Plus tard ce symptôme isolé de la douleur a été constaté dans 32 cas de l'iléitis. De même que le phénomène de la sensibilité particulier a l'iléitis, le symptôme de la douleur peut être expliqué d'une façon raisonnable. La douleur constatée du flanc ressemble quant à sa qualité, avant tout quant à son caractère limité à la névralgie et elle se trouve dans une région ou deux nerfs — n. iliohypogastricus et n. ilioinguinalis — coulent de près de l'épiderme. Le manque de la névralgie iliohypogastrique de l'image de maladie de l'appendicite provient d'une inflammation différente des glandes lymphatiques. On pouvait constater que le symptôme de la douleur disparaissait après l'exécution de l'analgésie. Le blocus d'essai était exécuté dans les muscles abdominaux dans une étendue de trois doigts à côté de crista iliaca dans son point le plus haut.

Literature.

ALTSCHÜLER, E.: Lancet 1938: *1:* 891. — BAUER, G.: Nord. Med. 1939: *2:* 1371. — BOWEN, W. H.: Appendicitis. Cambridge 1937. — BRAUN, H.: Örtliche Betäubung. Leipzig 1925. — CABOT, R. C. and F. D. ADAMS: Physical Diagnosis. London 1938. — COPE, Z.: The Early Diagnosis of the Acute Abdomen. London 1935. — CORNING, H. K.: Lehrbuch der Topografischen Anatomie. München 1922. — CROHN, GINZBURG and OPPENHEIMER: J. Amer. med. Assoc. 1932: *99:* 1326. — INBERG, K. R.: Duodecim. 1938: *11:* 923. — INBERG, K. R.: Duodecim. 1939: *2:* 143. — JONES, CH. M.: Quoted by CABOT and ADAMS. — KANTOR, J. L.: J. amer. med. Assoc. 1934: *103:* 2016. — KÜMMEL, H.: Münch. med. Wschr. 1921: *2:* 1328. — MARSHALL, C. J.: Chronic Diseases of the Abdomen. London 1938. — MARSHALL, C. J.: Lancet. 1936: *2:* 242. — MORLEY, J.: Abdominal Pain. Edinburgh 1931. — OPPENHEIMER, A.: Fortschr. Röntgenstr. 1931: *44:* 600. — ROSENBLATE, A. J., A. A. GOLDSMITH and A. A. STRAUSS: J. amer. med. Assoc. 1936: *106:* 1797. — SCHINZ, H. R., BAENSCH, W. and FRIEDL, E.: Lehrbuch der Röntgendiagnostik. 4. Aufl. II: Innere Organe. Leipzig 1939. — SNAPPER, I.: Pseudo-tuberculosis in Man. II. Regional Ileitis. Haarlem 1938. — SOBOTTA, J.: Deskriptive Anatomie. III. München 1922. —

SPALTEHOLZ, W.: Handatlas der Anatomie des Menschen. Leipzig 1922. — SPRENGEL: Die Appendicitis. Deutsche Chirurgie. 1906: *46* D. — STRÖMBECK, J. P.: Acta chir. scand. 1932: *70*, Suppl. 17—20. — STRÖMBECK, J. P.: Acta chir. scand. 1937: *80*, Suppl. 40. — SVARTZ, N.: Nord. med. Tskr. 1934: *7*: 419. — TREVES, F.: Surgical Applied Anatomy. Ninth Ed. London 1934. — TREVES, F.: Intestinal Obstruction. London 1884.

De l'hôpital orthopédique de la Fondation des Invalides à Helsinki.
(Chef: le prof. F. LANGENSKIÖLD.)

Sur les opérations plastiques du pouce.

Par

K. E. KALLIO.

En tenant compte de l'inconvénient pénible que l'absence du pouce occasionne à l'homme, on pourrait penser que l'on trouverait dans la littérature médicale un nombre imposant d'expériences à cet égard. Cependant ce n'est pas le cas. A en juger par ce qui a été publié, il semble qu'aucun chirurgien n'ait acquis une très grande routine dans les opérations plastiques du pouce. Il a été relaté peut-être un cas, parfois deux, mais très rarement trois cas à la fois. Etant ainsi il me semble permis de participer à la discussion de cette question.

Mes matériaux se portent sur 10 nouveaux cas. Parmi ceux-ci toutes les phases opératoires, dans quatre cas, (5, 6, 7, 10), ont été faites par mon chef, le professeur F. LANGENSKIÖLD, que je veux remercier de son obligeance de me permettre de les publier. Les autres six cas (1, 2, 3, 4, 8, 9) ont été opérés par moi-même.

Suivant la méthode qui a été pratiquée je veux subdiviser mes cas en deux groupes, à savoir les opérations plastiques adjacentes ou entourantes, dans lesquelles le nouveau pouce est formé par les matériaux de la main endommagée elle-même, et les opérations plastiques éloignées, dans lesquelles les matériaux nécessaires sont transplantés d'autres parties du corps.

I. L'opération plastique adjacente ou entourante.

A. Phalangisatio oss. mc. I. a. m. Huguier.

1. *J. R.* Un écolier de 19 ans. J. N:o 76/VIII. Le 23. 6. 44 sa main gauche fut blessée par un éclat d'obus, de sorte que le doigt médius s'en alla complètement, des premières phalanges du pouce et de l'index



Cas 1. Avant et après l'opération.

il est resté des moignons, longs d'env. 1 cm. et du 4e métacarpien un bout de 2 cm. env. Seulement le petit doigt est resté intact. — Le 14. 2. 45 *opération* (KALLIO). Anesthésie du plexus. Incision typique, de sorte qu'il se forme un clapet cutané dorsal et volaire. Le m. interosseux et une grande partie de l'adducteur sont enlevés. Les clapets cutanés s'appliquent à leurs places d'une manière idéale. — Le 3. 5. 45, à la sortie du blessé de l'hôpital, la sensation de contact et la mobilité du nouveau pouce, d'une longueur de 4 cm., étaient bonnes, la force même était assez grande. *A l'examen ultérieur* le blessé a répondu par une lettre du 4. 8. 45 que le fonctionnement du pouce s'est amélioré et qu'il a bien appris à s'en servir.

2. *J. P.* Chauffeur de 33 ans. J. N:o 288/VI. — Le 12. 1. 44 il se fut frappé par une hache, de sorte que le pouce gauche manque. Il ne donne son consentement qu'à une phalangisation. — Le 2. 3. 45 *opération* (KALLIO). Comme dans le cas précédent. — Le 4. 8. 45 *examen ultérieur*. Un pouce, long de 3 cm.: la sensation de contact est bonne, la mobilité est complète et la force considérable. Exerce son ancien métier.

Cas 2. Après l'opération.

B. Phalangisatio oss. mc. I. per exstirpation. oss. mc. II a. m. Perthes.

3. *T. K.* Un magasinier de 25 ans. J. N:o 48/V. — Le 6. 11. 42 une amorce d'une grenade à main a sauté dans la main. Il reste de la première phalange du pouce gauche 1 cm., l'index manque, de la première phalange du doigt médius il reste 4 cm., la première phalange de l'annulaire reste, ainsi que le petit doigt en entier. De plus il y a dans le dos de la main une défectuosité cutanée large, couvrant la cicatrice mince. — Le 26. 3. 43 *opération* (Kallio). Anesthésie du plexus. Le 2e mc. est enlevé suivant Perthes. Il se forme une fourche profonde entre le 1er et le 3e mc. — La défectuosité cutanée primitive nuit à la guérison du bord médial de la fourche. Par suite opération à deux reprises le 9.6 et le 25.6: au bord de la paume on transplante de la peau de l'abdomen. — *A l'examen ultérieur* le 23. 9. 45 on constate que le sensation de contact de la main est bonne partout, sauf dans le morceau de la peau transplantée. «Le pouce», long de 4 cm., se serre bien au bord du 3e métacarpien et s'oppose irréprochablement. La force est assez bonne. Le blessé s'est habitué à se servir de la main.

4. *A. M.* Monteur de bicyclettes de 25 ans. J. N:o 257/IV. — Le 17. 4. 42 l'amorce de projectile de l'instrument de jet d'un obus a éclaté à son examen. De la main gauche il est resté un moignon du 2:e métacarpien, un moignon de la première phalange du doigt médius et les premières phalanges de l'annulaire et du petit doigt, mais le pouce manque complètement. — Le 5. 1. 44, *opération* (Kallio). Comme dans le cas précédent. Le 14. 8. 45 *examen ultérieur.* — La sensation de contact, la mobilité et la force du pouce sont bonnes. Le blessé travaille comme chauffeur dans un bateau.

Cas 3. Après l'opération.

Comme promoteur de l'opération plastique adjacente est considéré Huguier, qui en 1852 pratiqua la première fois la phalangisation du premier métacarpien (mc.). Ensuite Klapp a fait l'opération plus connue. Cette opération comprend, comme on le sait, l'incision qui fend par le milieu la peau du pli du pouce, continuant dorsalement le long du bord du 1er mc. et volairement à peu près le long du pli de la peau arqué, siégeant dans la racine du thénar. Il se forme alors un clapet cutané dorsal et volaire. Le 1er m. interosseux et la tête transverse du m. adducteur du pouce sont enlevés. Finalement le clapet cutané dorsal est suturé dans le fond de la paume et le clapet volaire dans le dos de la paume. En publiant en 1938 trois cas de phalangisation Köster mentionne qu'il n'a trouvé dans la littérature que 45 cas analogues. D'après lui, parmi les 38 cas, dont le résultat a été publié, il n'y a eu que deux cas où le résultat aurait été moins bon. Il propose même directement la phalangisation comme procédé normal dans le traitement d'une défectuosité du pouce, vu qu'à son avis, on peut faire au moyen de celui-ci plus facilement et plus rapidement un pouce avec bonne sensibilité, de la mobilité et de la force. Plus tard Palmstierna, Garzia, Meyer-Wildisen et Sipov ont publié des articles sur la phalangisation, chacun sur un cas.



Cas 4. Avant et après l'opération.

S'il manque de la main, sauf le pouce, aussi un ou deux doigts, PERTHES a rendu la phalangisation plus efficace en enlevant le 2e me., mais s'il ne reste que les os du me. il a proposé l'enlèvement tant du 2e me. que du 3e me. pour qu'il se produise une fourche plus large. Par contre, SCHOSSENER s'est contenté même, dans le cas mentionné, de l'enlèvement seulement du 2e me.

Une contribution intéressante rel. à la question de l'opération plastique adjacente constitue le procédé dit la transplantation des doigts, inventé par LUKSCH en 1903. Par cette méthode un doigt de la même main est transplanté à la place du pouce (entre autres MACHOL, HUECK, MAYER et MÜHSAM). BUZELLO a transplanté avec l'index aussi une partie du 2e me. Le même principe a été suivi également par ISELIN dans son procédé de la «Restauration du pouce par pollicisation du deuxième métacarpien»,

procédé par lequel il se dit avoir obtenu un bon résultat trois fois. Aussi ZSULYEVITSCH a réussi une fois. Dans un cas analogue PORZELT a réséqué une partie du 2e mc., ainsi que la première phalange de l'index. MEYER a procédé de la même manière en faisant un pouce du doigt médius. — Comme un inconvénient ennuyeux de toutes ces méthodes de transplantation des doigts, qui sont intéressantes du point de vue technique, il faut considérer la circonstance qu'on est obligé en les pratiquant, d'endommager la main déjà défectueuse et de sacrifier un des doigts sains et d'occasioner encore de nouvelles surfaces cicatricielles dans la main.

Dans un cas, où, sauf l'absence du pouce et l'index, les autres doigts étaient amputés, SPITZY et JENNER ont enlevé, à mon avis à bon droit, *la partie proximale du 2e mc., en la transplantant* comme allongement du bout distal du 2e mc.

Dans mes propres matériaux il y a deux cas de phalangisation simple (1 et 2). Dans le premier cas, où il ne restait intact qu'un doigt de la main, le petit doigt, et où il n'y avait que très peu des premières phalanges du pouce et de l'index, la phalangisation était, à mon avis, le procédé le plus approprié. Dans l'autre cas, par contre, il n'était question que d'une défectuosité du pouce d'une main d'ailleurs saine. Dans ce cas-là on aurait pu pratiquer l'opération plastique éloignée, mais le malade n'y était pas disposé et cela sûrement parce qu'il était dans le même service hospitalier que le malade précédent qui y restait encore pour obtenir un traitement d'exercice. Même si l'on, de différents côtés, a été mis en garde contre la possibilité de casser l'adducteur (HOFFMANN et KRAFT) et qu'il a été encore proposé de transplanter l'insertion du muscle mentionné dans la racine du 1er mc. (BONNET-CARCASSONNE, OMBREDANNE, WIERCEJEWSKI), j'ai enlevé dans tous les deux cas le 1er m. interosseux, ainsi que la plus grande partie de l'adducteur. Néanmoins il est resté chez le nouveau pouce une bonne faculté d'adduction, circonstance qui appuie l'hypothèse de BOSH-ARANA, KLAPP et PERTHES, que les muscles opposant et fléchisseur pourvoient aussi suffisamment à l'adduction du pouce. Particulièrement réussi est, à mon avis, l'incision cutanée, comprise dans le procédé, à l'aide de laquelle la région opératoire y aussi se revêtit bien de la peau sans tension. Dans tous les deux cas on a obtenu un pouce fort, très sensible et irréprochablement mobile, même s'il, dans l'un de ces cas, est court, dû à la longueur du métacarpe.

Deux fois (3, 4) j'ai fait la phalangisation du 1er mc. en en-



Cas 5. Après l'opération.

fectuosité osseuse d'une grandeur de quelques cm. env. et le malade avait perdu le métacarpe du pouce, le long de l'articulation métacarpo-phalangienne. — Le 24. 11. 41. *Phase I.* Comme dans le cas précédent (N:o 5). — Le 5. 1. 42 *osteotomia et allongatio per transplantationem ossis libera ossis metacarp. III m. dx.* La fracture du 3e métacarpien est détachée par un ciseau, l'ouverture peut s'élargir jusqu'à plus de 2 cm. Dans celle-ci on place un morceau d'os qui est scié du tibia et maintenu par la tension. Une attelle plâtrée est appliquée avec les doigts un peu courbés. — Le 21. 1. 42. *Phase II.* De la novoc. On découpe le bout latéral de la saucisse et le ferme. — Le 18. 2. 42. *Phase III.* De la novoe. Comme la troisième phase dans le cas précédent. La main est plâtrée et fixée par une attelle dans la torse. Le 18. 3. 42. *Phase IV.* De la novoe. La saucisse du pouce est découpée de la torse. Bandage plâtré. Cours: Suppuration du bout du pouce. Le 24. 8. 42. Le nouveau pouce est bien guéri. Un peu cyanotique. Le 6. 11. 42. On enlève un peu de la partie molle qui en est de trop. Au début du mois de décembre le malade a gelé son nouveau pouce. Une défectuosité grande comme un ongle s'était produite qui cependant guérissait au bout de deux ou trois mois.

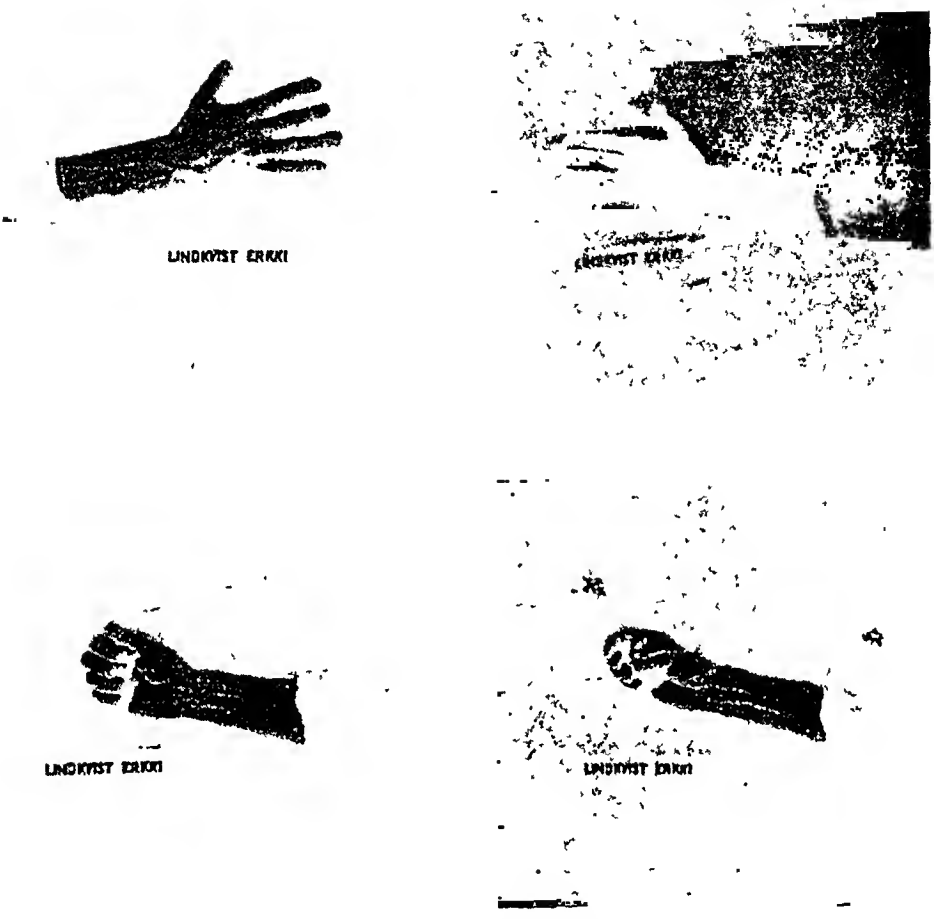

Cas 6. Après l'opération.

Le 30. 7. 45, *examen ultérieur*. Un pouce de 6 cm. cosmétiquement beau. Fait mal au toucher d'une aiguille, la sensation thermique est assez grande. La sensation de contact dans le bout est plus faible que dans la racine. Les mouvements sont bons, l'opposition est complète, la force est bonne. La main se ferme bien. Dans l'extension le troisième doigt reste 15°. Le malade a fait toutes sortes de travaux d'agriculture.

7. *A. A.* Agriculteur de 33 ans. J. N:o 192/I. Opérateur: LANGENSKIÖLD. — Le 10. 9. 41 le malade se fut blessé par une grenade à main perdant l'index et le pouce de la main gauche, ainsi que le premier métacarpien avec le capitulum. Le 23. 2. 42. *Phase I.* Comme dans le cas précédent. Cours: Dans la région opératoire il se produit de l'exanthème. Plusieurs permissions. — Le 11. 11. 42. *Resectio oss. metacarp. II et transplantatio libera ossis ad stil. rotund. abdominalis.* De l'éther. Vu que le morceau d'os pris de la crête s'était considérablement nécrosé on l'enlève et à sa place on transplante une partie du deuxième métacarpien. — Le 8. 1. 43. *Phase II.* De la novoc. Le bout latéral de la saucisse est détaché et le bout libre du morceau d'os est enfoncé

dans le premier métacarpien. Suture de la peau. Bandage adhésif. — Le 27. 1. 43. *Phase III.* De la novoc. On détache la saucisse complètement de l'abdomen. On suture le bout «du pouce» et plâtre la main. — Cours: Un bandage plâtré jusqu'au 16. 3. 43, mais le transplant ne s'est pas ossifié. — Le 5. 11. 43. *Ecostéosynthese.* De la novoc. On découvre le bout du transplant osseux et l'enfonce de nouveau dans le premier métacarpien.

Cas 7. Après l'opération.

Le 7. 7. 44, *examen ultérieur.* Le nouveau pouce bien formé, long de 4 cm., est maintenant ferme. L'opposition est possible jusqu'à la première phalange du doigt médius, mais les mouvements sont bons. La sensibilité est bonne en serrant le pouce. La sensation d'un point d'aiguille manque comme aussi la sensation thermique.

8. *I. P.* Agriculteur de 32 ans. J. N:o 72/II. Opérateur: Kallio. — Le 14. 11. 41 le malade mit le pied sur une mine. Il manque de la main droite l'index, du doigt médius deux articulations distales, ainsi que le pouce, dont il ne reste qu'un moignon de 1 cm. Un moignon de 11 cm. reste de l'antibrachium gauche. Fract. expl. cruris sin. *Phase I.* Comme dans les cas précédents N:os 5—7. — Le 1. 8. 42. *Phase II.* De la novoc. Le bout latéral de la saucisse est détaché et suturé. — Le malade séjourne de temps en temps à domicile. — Le 13. 1. 43. *Phase III.* Anesthésie du plexus. On découvre le bout du transplant osseux et l'enfonce dans la première phalange, longue de 1 cm. et ensuite on suture la peau. Un bandage adhésif. — Le 22. 2. 43. *Phase IV.* De la novoc. Le bout distal de la saucisse est détaché de l'abdomen et suturé. Le transplant ne s'est pas ossifié. — Cours: Au bout du pouce il se forme de la nécrose. On tient le pouce plâtré pendant plusieurs mois, période pendant laquelle le malade est à domicile. Le 6. 11. 43. *Transplantatio libera ossis.* Anesthésie du plexus dans la main et anesthésie locale dans la jambe. On détache du tibia un copeau d'os et on l'enfonce dans le premier métacarpien, à côté du transplant précédent, pour le consolider. Bandage plâtré. On garde le bandage plâtré jusqu'au 1. 4. 44, moment où l'ossification est ferme.



Cas 8. Avant et après l'opération.

Le 27. 4. 45, *examen ultérieur*. Le nouveau pouce est cosmétiquement bien réussi, il a une épaisseur naturelle et une longeur de 4.5 cm. env. Il sent un contact fort et un point d'aiguille profond, mais très faiblement la température. Il est ferme et assez fort. Les mouvements sont bons et il oppose en face de quatre doigts. Vu que l'autre main manque, le pouce a été très utile.

9. *A. S.* Agriculteur de 31 ans. J. N:o 188/VI. Opérateur: Kallio. — Le 4. 9. 41 une grenade à main arracha le pouce gauche, en lésant en même temps les dents et les yeux. Le 23. 11. 42. *Phase I.* Comme dans les cas 5 à 8. — Le 21. 1. 43. *Phase II.* De la novoc. On détache le bout latéral du tube cutané osseux. — Le 4. 2. 43 il désire retourner à la maison. — Le 23. 3. 43. *Phase III.* Anesthésie du plexus. Le tube cutané est réuni à la main, comme dans le cas précédent. Bandage adhésif. — Le 26. 3. 43. En dormant la nuit le malade arrache la main, suture. — Le 24. 4. 42. *Phase IV.* De la novoc. On détache la saucisse de la torse et, délibérée ainsi, on plâtre la main. — Cours: Dans le

Cas 9. Avant et après l'opération.

transplant d'os il se produit une infection et une nécrose. — Par suite de la guerre le malade doit entre temps accomplir son service militaire pendant une année. — Le 6. 10. 44. *Transplantatio ossis libera.* Anesthésie du plexus et rachianesthésie. On enlève le précédent transplant osseux détaché. Un nouveau transplant est pris du tibia, dont le bout est enfoncé dans le métacarpe. — Le 20. 12. 44. On ouvre le plâtre. La consolidation est bonne.

Le 7. 4. 45, *examen ultérieur.* Le nouveau pouce est ferme et fort. Il est bien sensible au contact, faiblement à un point d'aiguille et il a même la sensation thermique. Il oppose en face de tous les doigts. — Le malade a fait tous les travaux dans son ancien métier.

10. *M. L.* Dessinateur de machines. J. N:o 43/VII. Opérateur: Langenskiöld. — Le 12. 6. 44 il perdit le pouce et le premier métacarpien de la main droite par un éclat d'obus. En même temps fract. bomb. oss. mc. II. capituli radii et olecrani ulnae dx. L'articulation huméro-cubitale est restée presque raide, au poignet il reste un peu de mobilité. Le malade est disposé à obtenir un nouveau pouce raide. — Le 9. 1. 45. *Phase I. Applicatio stili rotundi abdominalis.* De l'éther. Dans la peau de l'abdomen on forme une saucisse cutanée de l'épaisseur d'un pouce. — Le 20. 11. 45. *Phase II.* De l'éther. Dans la région du premier métacarpien on fait par un ciseau une poche osseuse, dans laquelle on frappe le bout d'un transplant d'os, pris du tibia, d'une



Cas 10. Avant et après l'opération.

longueur de 8 cm. Le transplant d'os, qu'on a cloué ainsi dans la main, est poussé dans la saucisse décrite, qui est suturée ensuite dans la peau du poignet. Bandage plâtré. — Le 3. 4. 45. *Phase III.* De la novoc. On détache le tube cutané de l'abdomen et forme le bout du pouce pour qu'il s'applique bien. Bandage plâtré. Le 11. 6. 45. La consolidation est bonne. On laisse le plâtre ouvert pour protéger le pouce. Le malade se rend à la maison.

Le 13. 8. 45, *examen ultérieur.* Cosmétiquement le pouce raide, long de 5 cm, est bien réussi, mais il lui manque encore de la sensibilité. A son bout il n'y a que l'index qui l'atteint. Les doigts II à V fonctionnent bien.

L'opération plastique éloignée, faite par suite d'une défectuosité du pouce, s'associe, comme on le sait, au nom de Nicoladoni (1891). Sa première méthode consiste dans la formation, dans une ou plusieurs phases, d'un tube cutané, contenant de l'os, dont on doit faire ensuite un pouce en le réunissant au premier métacarpien. Cependant cela n'a pas réussi au promoteur lui-même. Mais plus tard l'opération a été souvent pratiquée avec succès (v. Arlt, Manasse, Neuhauser, Schepelmann, Lexer,

RIETZ, DIAL, DESPLAS). Pour ces opérations plastiques on a utilisé de la peau provenant de l'abdomen ou de la poitrine, ainsi que de l'os du tibia, du péroné, de la côte, du clavicule, du métacarpe ou de la crête iliaque.

La deuxième méthode de NICOLADONI, inventée en 1898, tend à ce que le deuxième orteil, directement stylisé tel quel, se change en un pouce actif en le réunissant au premier métacarpien. Le promoteur a pu, en effet, dans deux ou trois cas faire ainsi un pouce, mais il n'est pas arrivé à un résultat idéal, c'est-à-d. à la mobilité complète du nouvel organe. Le procédé mentionné n'a pas non plus réussi à plusieurs d'autres qui l'ont tenté. (KLEINSCHMIDT, PORZEILT, HALLBERG, KRAUSE, GREGOIRE). Il n'y a que cinq chirurgiens, autant que je sache, qui ont pu faire un nouveau pouce d'un orteil, idéal du point de vue de la mobilité, à savoir: KLEMM, ESSER, KRAFT, RIEDEL et OEHLECKER. Encore, il y a peu de temps, un russe KAZAKEVITSCH a ainsi formé deux pouces et NOVICKIJ un pouce, dans lesquels le fonctionnement a été bon, d'après ce qui a été communiqué, mais il ne ressort pas des rapports si les résultats sont idéaux. La position de la deuxième méthode de NICOLADONI est à considérer encore, à ce moment-ci, comme très modeste. Par ce procédé on peut bien arriver au meilleur résultat cosmétique, mais la suture tendineuse ne conduit pas à un résultat idéal. Comme il en a été le cas en général, la valeur fonctionnelle du nouvel organe n'est pas meilleur que le pouce de la première méthode de NICOLADONI et du point de vue de la sensibilité les résultats obtenus par les deux procédés sont équivalents. DUEÑO a objecté qu'un pouce fait d'un orteil s'atrophie avec le temps et l'on a critiqué l'opération aussi de ce qu'il faut sacrifier un orteil de la jambe saine et que la position est difficile pour le malade. A mon avis ces observations sont moins importantes. De toute évidence la deuxième méthode de NICOLADONI va maintenir sa position en pratique.

Parmi les méthodes plastiques éloignées il faut mentionner aussi à ce propos le procédé intéressant de JOYCE, procédé par lequel on transplante le quatrième doigt de la main saine pour en faire un pouce. A cet égard l'opération se distingue à son avantage des autres méthodes de transplantation des doigts.

Dans mes matériaux la première méthode de NICOLADONI a été utilisée dans cinq cas (5, 6, 7, 8, 9). Les malades sont des hommes à l'âge de 22 à 23 ans. Chez quatre de ces individus les lésions de la main sont survenues dans la guerre par des blessures et un

s'est gelé la main. Quatre sont de leur profession des agriculteurs et un employé de bureau. Concernant le choix de la méthode on aurait très bien pu faire la phalangisation de PERTHES dans le cas numéro 8, si le malade, dont l'un des avant-bras était amputé, ne s'était pas absolument opposé à ce procédé par des raisons cosmétiques. Dans le cas numéro 7, où l'index, le pouce, ainsi que le premier métacarpien avec le capitulum manquaient, on aurait pu penser aussi à pratiquer la méthode de SPITZY, c'est-à d. à allonger le premier métacarpien en y transplantant comme rallonge une partie du deuxième métacarpien, mais à peine n'aurait-on obtenu un résultat pratique aussi bon que par l'opération plastique éloignée.

Dans quatre cas on a effectué l'opération en quatre phases. Dans trois de ces cas (6, 8, 9) on a détaché dans la deuxième phase le bout latéral de la saucisse. Dans un cas (5) le détachement final du bout médial de la torse a été fait avec prudence en deux phases. Le septième cas, où l'opération a été effectuée avec succès en trois phases, montre que les phases intermédiaires supplémentaires mentionnées plus haut ne sont pas nécessaires. La première phase a été faite d'après la première méthode de NICOLADONI, seulement avec la modification, présentée par LANGENSKIÖLD, que le morceau d'os pris de la crête iliaque, enfermé dans le tube cutané, n'a pas été détaché à part des parties molles, afin de mieux maintenir sa nutrition. En dépit de cela le transplant de l'os s'est résorbé dans quatre cas. Dans les cas 5, 7 et 9 on a dû enlever le reste de l'os de la saucisse et mettre à sa place un transplant du tibia (5, 9) ou un morceau du deuxième métacarpien (7). Dans le cas 8 on n'a pas enlevé le reste du transplant, mais on a mis pour le consolider un copeau du tibia. Une fois seulement (6) de mes cinq cas le morceau d'os enveloppé dans le tube de NICOLADONI a vécu si bien qu'il s'est attaché tout simplement au premier métacarpien.

Dans tous les cinq cas la phase de la réunion a été faite ainsi que le bout premier métacarpien a été creusé et ensuite le bout du transplant osseux dans la saucisse a été enfoncé dans le canal ainsi né. Lorsque le transplant à réunir a siégé dans le tube cutané mou cela a rendu techniquement plus difficile la réunion des os. Cette phase a une fois (5) été effectuée sous la narcose, deux fois (6, 7) sous anesthésie locale et deux fois sous anesthésie du plexus (8, 9). Les procédés dernièrement mentionnés, notamment l'anesthésie locale, sont, à mon avis, les plus recommandables,

en tenant compte de la fixation de la main dans la torse. Une fois (6) la phase a été pratiquée par une combinaison de bandage plâtré et adhésif, mais dans les autres cas on a utilisé un emplâtre simple qui n'a pas immobilisé suffisamment. Ainsi un malade (9) bandagé de cette manière a arraché en dormant la saucisse de la main trois jours après l'opération. Dans un cas (7), bien que le transplant osseux fût viable, il ne s'est pas ossifié avant d'être enfoncé de nouveau dans le premier métacarpien.

Dans mes cinq cas relatés où la première méthode de Nicoladoni a été pratiquée, la lenteur du traitement attire l'attention. Il faut cependant considérer que pour les invalides de guerre en cause, les longues permissions en vue du traitement ont été très désirables et pendant la guerre on les leur a accordé aussi largement. Il n'y a bien un malade (9) qui au milieu du traitement a fait son service militaire pendant toute une année. En partie, les autres lésions attrapées dans la guerre ont naturellement aussi prolongé le traitement des blessés. Il faut reconnaître, autant que je voie, que les périodes intermédiaires (5, 6, 8, 9) inutiles pour la chose en elle-même, ont pris du temps. Tout de même on ne peut pas nier que la première méthode de Nicoladoni telle quelle ne se soit montrée lente. En effet, sans tenir compte de la pratique prudente du procédé un morceau d'os dans le tube cutané s'est nécrosé et partiellement résorbé dans quatre cas sur cinq, amenant une nouvelle transplantation d'os libre et par conséquent une perte de temps précieux.

Les examens ultérieurs montrent les résultats du traitement. Un (5) a été fait quatre, un trois (6), et un (8) et deux (7, 9) six mois après que le traitement ait été définitivement terminé, en moyenne par conséquent au cours d'un an et huit mois. Tous les malades ont repris leur ancien métier, même s'il est difficile pour un agriculteur (6) chez qui un des avant-bras est amputé. L'épaisseur du nouveau pouce dans tous les cas est appropriée. Aussi la longueur s'applique bien, sauf dans un cas (9) où le pouce aurait pu être un peu plus long. On peut dire que les pouces, du point de vue cosmétique, sont bien réussis. Dans tous les cas la sensibilité du pouce est si grande qu'il sent un contact lourd. Dans quatre cas le pouce sent en outre les points d'aiguille et il y est même de la sensation thermique. Dans un cas (6) le pouce est directement sensible à des points d'aiguille. La sensation est la meilleure à la racine et la plus mauvaise au bout. Dans tous les cas on a dû pendant l'hiver garder le pouce du froid et des tra-

vaux en dehors. La fermeté et la force sont assez bonnes dans tous les cas. L'aptitude au travail a également été bonne. Dans les pouces la mobilité nécessaire du métacarpe est complète et l'opposition en face des autres doigts est possible jusqu'au troisième ou au quatrième doigt au minimum. Tous les malades, sans exception, sont très contents des résultats.

Les cas graves, dans lesquels il manque, sauf le pouce, aussi le premier métacarpien, constituent une étude à part. LAUENSTEIN est le premier qui en 1888, dans un cas pareil, par la méthode plastique adjacente, a formé un pouce en utilisant l'ostéotomie pour le deuxième métacarpien. Il a tourné le métacarpien 90°, de sorte que l'index s'est dirigé contre les autres doigts. Aussi GABRIEL et GUERMONPREZ ont publié leur expériences dans des cas analogues d'ostéotomie. Dans un cas correspondant NOESSKE a fait un pouce en réséquant le deuxième métacarpien. Le même procédé a été employé par BUNNEL et PORZELT. PERTHES, par contre, a tout d'abord déplacé tout le deuxième métacarpien avec le doigt à la région de l'os multangulum majus et ensuite il a pratiqué l'ostéotomie de version. La méthode de PERTHES est appuyée par WITTEK qui l'a pratiquée dans deux cas. Evidemment le problème est difficile à résoudre. Parmi les méthodes plastiques adjacentes mentionnées il n'y a pas une seule qui donne un résultat satisfaisant du point de vue cosmétique et il n'y a non plus aucune garantie complète de la mobilité et de la force du pouce ainsi fait, même si le sens du toucher serait gardé. D'un autre côté la pratique de la méthode plastique éloignée n'a été mentionnée que deux fois dans la littérature médicale, autant que je sache. Par la deuxième méthode de NICOLADONI ESSER a en effet transplanté l'os du métatarse avec les orteils à la place du premier métacarpien et il a réussi à faire un pouce mobile. Dans l'autre cas on a, à l'aide de la première méthode de NICOLADONI, formé un pouce raide (PIERCE & O'CONNOR). ANGLESIO souligne particulièrement la valeur pratique même d'un pouce raide qui est bien appliqué.

Dans mes propres matériaux il y a un cas, où, à défaut du premier métacarpien, l'on a fait un pouce raide en utilisant un procédé de transplantation éloignée simple, procédé qui a été pratiqué même antérieurement, paraît-il, dans les opérations plastiques du pouce. L'opération dont la technique a été relatée dans la casuistique (10) a été effectuée en trois phases et elle a donné comme résultat un pouce raide, cosmétiquement parfait, appli-

qué en position d'opposition modérée. Le tout a été terminé en moins de six mois. Même qu'il est raide, ce pouce rend service au malade. Il peut presser son doigt en face de celui-ci. La main a en même temps obtenu un aspect rappelant le normal, circonstance que le malade apprécie beaucoup. Ce cas démontre la supériorité de cette méthode en comparaison avec la transplantation osseuse libre ordinaire, suivant la première méthode de NICOLADONI. La fixation du transplant d'os dans la main peut en effet se faire plus facilement et il n'est pas trop difficile de pousser le fausset d'os dans la saucisse. Le morceau d'os, dont le second bout est déjà primairement enfoncé dans le tissu osseux, se plaît apparemment mieux dans son nouvel entourage que s'il avait été appliqué seulement dans la saucisse cutanée, suivant la première méthode de NICOLADONI et l'opération plastique éloignée peut s'achever ainsi au plus vite.

Quant au point de vue de la médecine d'assurance par rapport aux défectuosités du pouce je ne peux pas approuver la manière dont on estime le premier métacarpien. Si celui-ci manque complètement l'invalidité est considérée à être seulement 5 % plus grande que lorsque les phalanges du pouce sont absentes. En pratique la différence est beaucoup plus grande, et les possibilités du chirurgien de réparer une main diminuent considérablement quand il s'agit de la perte du premier métacarpien. Je voudrais même proposer que l'invalidité dans l'absence du premier métacarpien serait estimée à 10—15 % plus que s'il y a une exarticulation du pouce dans l'articulation métacarpo-phalangienne.

Et puis, comment sont estimés les nouveaux pouces faits par les procédés opératoires plastiques dans la médecine d'assurance? Autant que je sache cette question n'a pas encore été discutée dans la littérature. A mon avis la phalangisation, suivant HUGUIER, d'un premier métacarpien bien réussi, baisse l'invalidité avec 5 % au moins. D'un autre côté, dans la phalangisation de PERTHES l'enlèvement du deuxième métacarpien devrait, au fond, d'après l'usage schématique habituel de l'assurance, augmenter l'invalidité avec 10 %, mais en réalité la valeur pratique de la main monte au contraire, d'après mon estimation, avec 5—10 %. Le cas montre à quelles conclusions absurdes, à cet égard, les schémas pourraient conduire. Les procédés de transplantation des doigts, même s'ils sont associés au sacrifice d'un doigt sain avec des surfaces cicatricielles correspondantes et, selon toute probabilité, à un sens du toucher diminué, peuvent bien aussi, paraît-

il, diminuer l'invalidité. Dans l'opération suivant la première méthode de NICOLADONI un pouce raide est formé, ayant même de la sensibilité, sans que l'opération endommage la main. On pourrait supposer par suite que ce pouce aussi baisserait l'invalidité avec 5—10 %, de même qu'un pouce formé suivant la deuxième méthode de NICOLADONI, dans lequel le tendon ne fonctionne pas. Un pouce fait d'après la deuxième méthode de NICOLADONI, idéal à l'égard du fonctionnement, bien que le procédé soit associé à une sensation de contact diminuée et à la perte d'un orteil, peut, à mon avis, baisser l'invalidité avec 10 % env. Cependant on doit, bien entendu, faire un examen minutieux de chaque cas particulier.

Finalement je voudrais présenter tout ce qui précède dans les conclusions suivantes:

1:o. Dans les cas de défectuosité du pouce il y a toujours lieu de faire une opération de réparation plastique.

2:o. Afin d'arriver à une grande expérience il faudrait concentrer les cas chez des opérateurs déterminés, qui examinent quel procédé plastique serait le plus approprié selon le cas.

3:o. La meilleure sensibilité et le résultat le plus rapide sont obtenus par l'opération plastique adjacente ou entourante, qui du point de vue cosmétique, est moins satisfaisante.

4:o. A l'aide des méthodes de phalangisation (HUGUIER, PERTHES) on peut obtenir dans des cas déterminés, de bons résultats à l'égard du fonctionnement.

5:o. Par les méthodes plastiques éloignées on peut former les plus beaux pouces et cela se fait sans que la main à opérer ne soit d'aucune manière endommagée. L'inconvénient de ces méthodes sont les différentes phases opératoires, un temps de traitement plus long et une sensation de contact plus mauvaise, qui cependant s'améliore avec le temps, devenant même parfois assez bonne.

6:o. Quant à la première méthode de NICOLADONI il y a lieu de la rejeter, vu que, premièrement le séjour préliminaire du transplant de l'os dans le tube cutané s'est montré être inutile et que, deuxièmement, celui-ci s'y résorbe souvent, ce qui est inquiétant. La manière la plus facile, la plus rapide et manifestement la plus sûre c'est de clouer le transplant osseux libre directement dans le bout du premier métacarpien et de l'y pousser de son bout libre dans le tube cutané préparé dans la phase précédente. En même temps on suture ce tube dans la peau de la main.

7:o. L'invalidité due aux défectuosités du pouce devrait être estimée à 10—15 % de plus dans l'absence aussi du premier métacarpien et pas, à 5 % de plus, ce qui est fixé en général dans la médecine d'assurance. Les nouveaux pouces faits à l'aide des opérations plastiques peuvent baisser l'invalidité avec 5—10 % environ.

Résumé.

Dans l'article présent l'auteur donne un aperçu critique des méthodes différentes de l'opération plastique du pouce et de la littérature y relative. Il relate de plus 10 nouveaux cas illustrés par des figures et des examens ultérieurs. Les opérations plastiques entourantes, desquelles on s'est servies dans deux cas de phalangisation du premier métacarpien, suivant la méthode de Huguier, et dans deux cas d'enlèvement du deuxième métacarpien, suivant le procédé de Perthes, ont donné rapidement des résultats fonctionnels satisfaisants. Dans l'absence des phalanges du pouce on a pratiqué cinq fois la première méthode éloignée de Nicoladoni, où un tube cutané, contenant un os librement transplanté, est suturé dans la main. Dans ces opérations le transplant osseux dans le tube cutané s'est résorbé dans quatre cas, amenant de nouvelles transplantations osseuses et une perte inutile de temps. Dans tous les cas on a finalement réussi à faire un pouce avec bon aspect et avec mobilité du premier métacarpien et même avec une force assez grande. L'examen ultérieur montre que tous les pouces, sauf les bouts, ont la sensation de contact et de points d'aiguille. Quatre de ces cas ont de plus la sensation thermique.

Dans un cas où, sauf le pouce, aussi le premier métacarpien a manqué, on a pratiqué l'opération plastique éloignée en trois phases avec un résultat excellent. Dans ce cas-là on a cloué dans la deuxième phase le transplant osseux libre directement dans l'os multangulum majus. Fixé là-dedans on l'a poussé dans le tube cutané, préparé dans la première phase de la peau de l'abdomen, et en même temps on a suturé ce tube cutané dans la main. Dans le traitement des défectuosités du pouce l'auteur recommande cette méthode et il propose, dans ces cas-là, de rejeter la première méthode de Nicoladoni.

L'auteur propose de plus que l'invalidité due à la défectuosité

du pouce dans la médecine d'assurance serait estimée à 10—15 % de plus dans l'absence aussi du premier métacarpien. Les pouces faits par les opérations plastiques peuvent, à l'avis de l'auteur, baisser l'invalidité avec 5—10 % environ.

Summary.

The essay gives a critical resumé of the different methods for carrying out plastic surgery on the thumb as well as about the literature dealing with this subject and, at the same time, gives an account of ten new cases with photographs and the postoperative examinations. The plastics with material from the nearest surroundings of which 2 phalangizations of mc I according to Huguier and 2 phalangizations by the removal of mc II according to Perthes have speedily led to satisfactory functional results. In the case where the thumb phalanx is missing, Nicoladoni's first method for distant plastic, in which skin tubes containing freshly transplanted bone is sewn to the hand, has been used five times. In these cases the transplanted bone in the skin tubes has resorbed in 4 cases which necessitated fresh bone transplantation and a further loss of time. In all cases a thumb was finally achieved which has a satisfactory appearance and mobility of mc I and, in addition, quite a lot of power. All the thumbs, with the exception of the ends of them, are sensitive to touch and pin-prick and 4 of them are even sensitive to heat.

In one case where both the thumb and mc I were missing, a distant plastic was performed in three stages with excellent results. A free bone transplantation as pounded in at the second stage into the multangulum majus and when it was fixed there it was, in one stage, passed into a skin tube made from the abdominal skin and at the same time sutured to the hand. A corresponding operation is recommended by the author for use instead of Nicoladoni's first method which should preferably not be resorted to any more.

The author suggests that invalidity caused by a defect of the thumb should be judged within the sphere of insurance medicine 10—15 % higher when even mc I is missing. The reconstructed thumb can, in the author's opinion, reduce invalidity by 5—10 %.

Zusammenfassung.

Diese Arbeit bringt eine kritische Durchsicht der verschiedenen Methoden der Daumenplastik sowie der diesbezüglichen Literatur und berichtet über 10 neue Fälle mit Photographien und Nachuntersuchungen. Die Plastiken mit Material aus der nächsten Umgebung, darunter 2 Phalangisationen des Metacarpale I nach Huguier und 2 Phalangisationen mit Abtragung des Metacarpale II nach Perthes, führten rasch befriedigende funktionelle Ergebnisse herbei. In denjenigen Fällen, wo die Daumenphalangen fehlten, kam in 5 Fällen die erste Methode Nicoladoni's zur Fernplastik zur Verwendung, bei der eine frei transplantierte Knochen enthaltende Hautröhre an die Hand genäht wird. Bei diesen Fällen wurde 4 mal das in der Hautröhre enthaltene Knochentransplantat resorbiert, was erneute Knochentransplantationen und weiteren Zeitverlust mitsichbrachte. In sämtlichen Fällen erzielte man zuletzt einen Daumen von befriedigendem Aussehen und ein bewegliches Metacarpale I sowie ausserdem recht gute Kraft. Sämtliche Daumen empfinden, ausser am Daumenende, Berührung und Nadelstiche, vier von ihnen sogar Wärme.

In 1 Falle, wo ausser dem Daumen auch das Metacarpale I fehlte, wurde mit ausgezeichnetem Erfolg eine dreizeitige Fernplastik vorgenommen. In der zweiten Sitzung wurde ein freies Knochentransplantat direkt in das Os multangulum majus geschlagen und, nach Befestigung daselbst, in eine bei der ersten Sitzung aus Bauchhaut gebildete Hautröhre gebracht, die gleichzeitig mit der Hand vernäht wurde. Ein entsprechendes Verfahren empfiehlt Verf. anstatt Nicoladoni's erster Methode, die nicht mehr verwendet werden sollte. Verf. schlägt vor, dass die durch den Daumendefekt verursachte Invalidität auf 10—15 % mehr berechnet werde, wenn auch das Metacarpale I fehlt. Die rekonstruierten Daumen können nach Verf.s Ansicht die Invalidität um etwa 5—10 % vermindern.

Littérature.

Anglesio, B.: Réf. par Z. org. f. d. ges. Chir. 77: 313: 1936. — Bonnet, P. & F. Carcassonne: Ref. par Köster. — Bosh-Arana: Surg. etc. 40: 859: 1925. — Bunnel, Sterling: Surg. etc. 52: 245: 1931. — Buzello, A.: Zbl. f. Chir. 63: 2945: 1936. — Desplas, B.: Réf. par Z. org. f. d. ges. Chir. 82: 624: 1937. — Dial, D.: Réf. par Z. org. f. d. ges.

Chir.: 1939. — Dueño, F.: Réf. par Z. org. f. d. ges. Chir. 107: 619: 1943. — Esser, J. F. S.: Bruns Beitr. 108: 244: 1917. — Gabriel, E.: Münch. med. W. 83: 1391: 1936. — Garzia, D. F.: Réf. par Z. org. f. d. ges. Chir. 94: 475: 1939. — Gueulette, Guermonpreg, Gregoire: Ref. par Köster. — Hoffmann, E.: Deutsche med. W. 45: 839: 1919. — Hueck, H.: Deutsche Z. f. Chir. 153: 321: 1920. — Huguier, P. C.: Réf. par Köster. — Iselin, Marc, et Jean Murat: Presse méd. II: 1099: 1937. — Jenner, Verral: Réf. par Köster. — Kazakevitsch, I.: Réf. par Z. org. f. d. ges. Chir. 582: 1941. — Klapp, R.: Deutsche Z. f. Chir. 118: 479: 1921. — Kleinschmidt, O.: Arch. f. klin. Chir. 164: 809: 1931. — Klemm: Arch. f. klin. Chir. 96: 190: 1911. — Kraft, R.: Deutsche Z. f. Chir. 226: 426: 1930. — Köster, K. H.: Acta orthop. scand. IX: 115: 1938. — Lauenstein, C.: Réf. par Köster. — Lexer, E.: Die ges. Wiederherstellungschirurgie 1931. — Liniger, H. und G. Molineus: Der Rentenmann. Leipzig 1940. — Luksch, L.: Zbl. f. Chir. 30: 153: 190. — Luksch, L.: Münch. med. W. 63: 881: 1916. — Machol: Bruns. Beitr. 114: 181: 1919. — Meyer, H.: Bruns Beitr. 119: 386: 1920. — Meyer-Wildisen, R.: Réf. par Z. org. f. d. ges. Chir. 90: 365: 1940. — Mühsam, E.: Zbl. f. Chir. 53: 585: 1926. — Muskat: Deutsche med. W. 45: 1432: 1919. — Neuhauser, H.: Deutsche med. W. 46: 165: 1920. — Nicoladoni, C.: Wien. klin. W. 10: 663: 1897. — Nicoladoni, C.: Arch. f. klin. Chir. 61: 606: 1900. — Noesske, K.: Münch. med. W. 56: 1403: 1909 et 67: 465: 1920. — Nordin, J.: Invaliditet vid olyeksfallsskador. Stockholm 1932. — Novickij, I. F.: Réf. par Z. org. f. d. ges. Chir. 94: 474: 1939. — Oehlecker, F.: Arch. f. klin. Chir. 189: 674: 1937. — Payr: Münch. med. W. 64: 1115, 1917. — Perthes, G.: Münch. med. W. 64: 1221: 1917. — Perthes, G.: Zbl. f. Chir. 48: 669: 1921. — Pierce, George Warren & Gerald Brown O'Connor: Surg. etc. 65: 523: 1937. — Porzelt, W.: Arch. f. klin. Chir. 135: 340: 1925. — Porzelt, W.: Chirurg 5: 61: 1933. — Porzelt, W.: Zbl. f. Chir. 62: 2248: 1935 et 64: 550: 1937. — Riedel, G.: Réf. par Köster. — Rietz, T.: Svenska läk.sällsk. förhandl. 445: 1916. — Schosserer, W.: Deutsche Z. f. Chir. 233: 435: 1931. — Sipov, A.: Réf. par Z. org. f. d. ges. Chir. 78: 231: 1936. — Spitzy: Münch. med. W. 64: 1622: 1917. — Tierny, A. et Iselin: Ref. par Z. org. f. d. ges. Chir. 87: 74: 1938. — Wiercejewski, I.: Münch. med. W. 66: 19: 1919. — Wittek, A.: Chirurg. 13: 577: 1941. — Zsuluevich, I.: Chirurg. 10: 433: 1938.

De l'hôpital départemental de Hämeenlinna, Finlande.
(L'ancien Chef, le maître de conférence: A. R. KLOSSNER.)

Sur l'endométriose se présentant dans l'anse sigmoïde.

Par

A. R. KLOSSNER.

Dans la littérature mondiale la question de l'endométriose a pris de si grandes proportions qu'il n'est plus dans le pouvoir d'un seul homme d'en donner une idée exacte. Aussi dans notre pays on a porté beaucoup d'attention à ce sujet. Cela a eu lieu presque uniquement de la part des gynécologues, comme on pourrait s'y attendre WICHMANN (1934), CHYDENIUS (1935), RAURAMO (1936), TURUNEN (1933 et 1938), HERBERZ (1933), tandis qu'il n'y a eu que très peu de chirurgiens qui se sont occupés de cette maladie. Ainsi PETERSON (1931) et KÄRKI (1932) ont publié des cas d'endométriose, se produisant dans la cicatrice d'une laparotomie, PALMÉN (1927) a donné publicité à trois cas d'adénome ombilical et NYLANDER (1938) à un cas d'adénosarcome rectal.

Comme j'ai eu sous mon traitement, il y a quelque temps, un cas qui peut offrir de l'intérêt même à de vastes cercles de chirurgiens, je prie de le présenter brièvement dans le suivant:

N:o 1676/43 L. E. Le 29. 8. 43 une veuve de 43 ans fut reçue à l'hôpital départemental de Hämeenlinna. Diagnostic: *Cysta dermoides ovarii dx. Salpingo-oophoritis chr., l. sin. Endometriosis flexurae sigmoideae.*

Anamnèse: La malade a passé par un seul accouchement il y a 20 ans. Celui-ci a été normal, sans fièvre. Il n'y a pas eu d'avortements. Les menstrues sont irrégulières, d'une durée de trois jours et elles sont précédées par des douleurs. Une fois les menstrues étaient absentes pendant tout un été sans cause connue. La malade e eu de la leucorrhée.

En 1926 la malade fut traitée par le professeur WICHMANN. Elle avait à ce moment-là une tumeur dans le bas-ventre, de la grosseur, de l'un côté, d'un œuf de pigéon, et de l'autre, d'un œuf de poule, à cause

de quoi elle fut traitée par les rayons X. Ce traitement a fait bon effet. L'état général s'était amélioré et elle avait grossi. En même temps les douleurs abdominales avaient disparu. Pendant ces dernières deux ou trois années la malade a eu de nouveau des douleurs dans le bas-ventre, qui se sont aggravées ces derniers temps. En même temps elle a senti des douleurs dans tout l'abdomen. Elle a eu des coliques venteuses et le ventre était gonflé. Les selles ont été lentes et souvent elle a senti du gargouillement. Parfois elle a eu de la diarrhée, ce qui lui a donné de soulagement. Au cours de ce dernier mois la malade a eu trois accès de douleurs graves vers minuit. En même temps elle a eu des vomissements. Le médecin communal qui fut appelé constata, en palpant, du côté gauche du ventre, une résistance molle, ainsi qu'un état rappelant l'occlusion. Il a conseillé la malade de se rendre à l'hôpital, ce qu'elle n'a pas fait cependant. Cinq jours plus tard environ, vers minuit, il s'est produit de nouveau un accès pareil au précédent, accès qui a passé également quand la malade s'est couché. Deux, trois jours après il y a eu encore un troisième accès, ce qui décida finalement la malade à se rendre à l'hôpital. Aussi les menstrues qui avaient continué à être irrégulières étaient devenues encore plus douloureuses ces derniers temps.

État actuel: La malade a maigri. L'état général moyen. Les poumons et le cœur — 0. LA 25/43. L'épreuve de Sahli 79 %. Le ventre est gonflé et fait mal partout. A cause de la sensibilité au toucher on ne peut pas palper minutieusement. On a l'impression pourtant que le côté gauche est plus plein.

Le vagin est ample. La portion est normale, lisse. L'os utérin est fixé. Le corps de l'utérus, de la grosseur ordinaire, est dans la flexion de version droite et tourné à gauche.

Du côté droit de l'utérus on sent une résistance à peu près de la grosseur d'un poing, nettement limitée, un peu mobile et pas sensible au toucher.

On décide de faire passer la nuit. L'accès de douleurs passe et l'état d'occlusion cède de nouveau.

Le 3. 9. 43 *opération: Amputatio uteri supravaginalis. S.-O.-ectomia bilat.* (TURTOLA). De l'éther.

Une incision longitudinale de l'ombilic jusqu'à l'union pubienne. Dans la cavité abdominale on constate que les deux annexes et l'utérus forment ensemble un amas de tumeurs. Par un examen plus minutieux on observe que les annexes gauches sont enflées et adhérées au feuillet postérieur du ligament large, de même qu'à la surface postérieure de 'utérus. Du côté droit, dans la région des annexes, siège une tumeur de la grosseur d'une orange, fixée à la région entourante, à parois relativement dures. Le corps utérin est de la grosseur normale et l'on y trouve quelques myomes centrifuges, gros comme quelques bouts de doigts. En détachant les tumeurs du côté droit, la capsule se rompt et le contenu en bouillie du kyste dermoïde s'écoule. La paroi du kyste est par endroits dure comme de l'os. On détache les adhérences complètement. Il ne se présente nulle part de liquide ressemblant à du goudron et du chocolat, caractéristique pour les kystes goudronnés. Les

adhérences ont plutôt un aspect inflammatoire. On enlève les deux annexes et fait une amputation utérine supra-vaginale de la manière usuelle.

Secondairement on constate de plus, au milieu de l'anse sigmoïde, une tumeur de l'épaisseur de deux ou trois doigts, tumeur qui avait obstrué l'intestin presque complètement. La partie sigmoïdale, située au-dessus de celle-ci, s'était dilatée, ayant l'épaisseur env. d'une cuisse. Dans le mésocôlon on constate des glandes dures en abondance, grosses comme des haricots et même plus. Puisqu'on soupçonne un carcinome sigmoïdal on soumet une des glandes à un examen microscopique. (Un examen histologique de la glande fait plus tard a montré que celle-ci était dilatée par suite d'une inflammation et qu'il n'y avait pas de cellules cancéreuses.) Les parois du ventre sont fermées de la manière usuelle et aucune mesure n'est prise, lors de cette opération, à l'égard de la tumeur rencontrée dans l'anse sigmoïde.

Bien que l'examen microscopique ait donné un résultat négatif par rapport au cancer, on est quand même de l'avis, sur la base de l'examen macroscopique, que la tumeur en question est un carcinome sigmoïdal.

Le 14. 9. 43, *opération: Lateropositio flexurae sigmoideae* (Klossner). De l'éther.

Une incision dans la région de la cavité iliaque gauche. On tire l'anse sigmoïde, où l'on rencontre, immédiatement au milieu de celle-ci, dans la partie inférieure, la tumeur décrite. Vu que dans l'opération précédente on avait serré le péritoine, la traction de la tumeur présente maintenant de grandes difficultés. En dilatant la plaie vers le bas on réussit finalement et l'on fixe ensuite l'intestin au péritoine et aux parois abdominales par quelques sutures au catgut.

Le 18. 9. 43, *opération: Extirpatio flexurae sigmoideae et electrocoagulatio* (Klossner). De l'éther.

On coupe l'anse sigmoïde qu'on a tirée. Après cela on observe que la ligne opératoire dans la partie aborale de l'intestin passe assez près de la tumeur. A cause de cela on cautérise le bout aboral par une pointe diathermique, puisqu'on est toujours de l'avis qu'il s'agit d'un cancer. Les jours suivants la malade se porte bien. Peu à peu la température commence à monter et il se produit une suppuration méchante dans le pli de l'aisne, ainsi qu'une tuméfaction considérable dans les organes génitaux externes. Lorsqu'on ouvre un peu la plaie il en vient du pus en abondance de la région près de l'anse sigmoïde. Ensuite, au bout d'une semaine, l'inflammation se calme. La malade se rend entre temps à la maison pour se remettre et pour arranger ses affaires.

Le 2. 11. 43, *opération: Seclusio fistulae stercoralis* (Klossner). De l'éther.

On ferme la fistule de la manière usuelle. La plaie se guérit sans troubles. La malade se rend à la maison en convalescente.

Constatation macroscopique. La partie enlevée de l'intestin est longue de 20 cm. environ. Du bout oral elle a, non ouverte, une largeur de 10—12 cm. environ, dans le bout aboral se rencontre une strieture annulaire, qui a contracté l'intestin, de sorte qu'il ne laisse passer que le

petit doigt. En ouvrant cet intestin le long de toute son étendue, on constate à sa grande surprise, que la muqueuse est ferme partout et que c'est une couche musculaire épaisse qui forme la stricture, dont la surface opératoire est presque argentée et dure (figure 1). En examinant la muqueuse plus minutieusement on constate qu'elle est peut-être un peu atrophiée au-dessus de la stricture. On ne constate rien d'autre extraordinaire. Ce n'est que maintenant qu'on comprend qu'il ne s'agit pas d'un cancer, mais de quelque autre maladie.

Constatation microscopique. On se sert de plusieurs dizaines de préparations, prises, soit de la région de la stricture, soit plus haut. Les premières présentent toutes, sans exception, la même image. De leur partie principale il y a *une couche musculaire annulaire* très épaisse, dépassant au moins de quatre ou cinq fois la normale et du côté extérieur, une couche longitudinale (dans le cas où il en existe). Dans la couche musculaire, la submuqueuse et la subséreuse s'observent des cavités tapissées d'épithélium, de différentes grosseurs et de différentes formes ou des tubes glandulaires qui rappellent, à s'y méprendre, la muqueuse utérine (figure 2). La grosseur varie de toutes petites cavités de la section transversale du tube glandulaire jusqu'à des cavités mesurant deux à trois fois le champ visuel.[1] De leur forme elles sont rondes, ovales, allongées, à trous ou asymétriques. Le plus souvent les parois de celles-ci sont lisses, il y en a aussi avec des plis. Dans quelques petites formations s'observent même de véritables faussets fibroépithéliaux qui sont enfoncés dans les cavités (figure 3).

L'épithélium recouvrant ces cavités est partout d'une rangée unique, par endroits on trouve de l'épithélium cylindrique haut (figure 4), par endroits de l'épithélium plus bas, et même aplati. La membrane basale est partout intacte. L'épithélium cylindrique haut, par contre, forme de très belles rangées. Les bouts des cellules allant dans la direction du lumen peuvent être épais et l'on y observe une proéminence en forme de houppe.

Souvent ces cavités sont vides. Parfois il y a dans celles-ci des cellules singulières, enflées, contenant des pigments, dont le plasma est vacuolisé. Elles rappellent, à s'y tromper, les cellules dénommées «Herzfehlerzellen» (figure 5).

Ces cavités, recouvertes d'épithélium cylindrique, sont entourées, presque sans exception, de tissu conjonctif mou, très riche en cellules, d'un aspect presque embryonnaire, «de stroma cytogène», où il y a très abondamment de cellules d'infiltration (figure 6). La plupart de ces cellules sont des lymphocytes. Il y en a aussi des éosinophiles, ainsi qu'un peu de cellules blanches à noyaux en lames, des cellules plasmatiques et des macrophages.

Dans ces kystes qui sont recouverts d'épithélium bas, cet épithélium est parfois détaché de la membrane basilaire. Ils sont entourés d'un tissu conjonctif assez pauvre en cellules. Celui-ci est sans homogénité et parfois même complètement sans structure (figure 7 et 8).

(A mon avis l'épithélium des kystes du premier type représente la

[1] Par le champ visuel on entend un grossissement par l'objectif N:o 10 de Zeiss, verre ocul. 7.

phase active, tandis que celui du dernier type est regressivement altérant, peut-être même améliorant.)

En examinant les différentes couches de la paroi de l'intestin on constate que la muqueuse est partout normale. La submuqueuse consiste en du tissu conjonctif très mou, oedémateux et collagène. Elle contient de nombreuses cavités remplies de liquide, les vaisseaux sanguins sont très sanguifères. On rencontre déjà dans cette couche ou plutôt dans les régions adjacentes de celle-ci et de la couche musculaire, les cavités déjà décrites, recouvertes d'épithélium et des tubes glandulaires (figure 9 et 10). La couche musculaire est, comme on l'a déjà dit, très ferme et l'on y rencontre par-ci par-là les dites cavités et des tubes glandulaires (figure 11). Il manque dans ces kystes, presque sans exception, «du stroma cytogène» ou aussi il y en a très peu, en général à l'autre bout du kyste.

La couche inférieure de la séreuse consiste en du tissu conjonctif très mou. Entre celle-ci et la couche musculaire on rencontre des formations glandulaires rappelant le plus la muqueuse utérine. Dans ce tissu de soutien on constate par endroits des marques fortes d'une inflammation chronique, marques perceptibles jusqu'à la formation des cellules géantes. (Il se peut que cela résulte des deux opérations pratiquées ou du long séjour de l'intestin du côté extérieur des couvertures abdominales.) Ces marques sont, soit isolées, soit en amas (figure 12). Cependant elles ne sont nulle part du type de Langhans.

On ne rencontre du tissu élastique en abondance que dans la submuqueuse, souvent même en grands amas. Ce tissu manque régulièrement autour des kystes, au moins autour de ceux où il y a «du stroma cytogène» en abondance. On peut en trouver cependant un peu dans les parois des kystes confinant au tissu conjonctif ferme.

Dans les préparations prises de la partie supérieure de la stricture on ne constate rien d'autre anormal que ce que la muqueuse a un aspect peut-être plus atrophié qu'en règle générale.

Le cas qui vient d'être décrit est une endométriose hétérotopique, se présentant dans la portion inférieure de l'anse sigmoïde, où l'on a constaté du tissu étranger, sauf dans la muqueuse, partout dans les parois de l'intestin, dans la submuqueuse, dans la couche musculaire et dans la subséreuse. Particulièrement abondamment ce tissu a été constaté dans le système musculaire annulaire qui en même temps s'était beaucoup épaissi.

Mes constatations pathologico-anatomiques s'accordent dans toutes les particularités entièrement avec les descriptions antérieures faites par d'autres investigateurs (Harbitz, Oehlecker, Konjetzny etc.). Il n'y a que le tissu élastique qui s'est présenté autrement que chez Konjetzny.

En Finlande un cas analogue n'a pas été publié une seule fois, autant que je sache. Dans la littérature mondiale on en a vu, par contre, quelques cas. Spencer (1913) est le premier qui a décrit

une endométriose pareille, rencontrée dans l'anse sigmoïde. Après lui, entre autres, GROSS (1925) en a publié 1 cas, KONJETZNY (1935) 2 cas, MASSON (1935) 14 cas, de la Clinique de Mayo, LAMARE, LARCET et ISIPOR (1938), PAPIN (1939), JOSEFSSON (1939), SBAROUNIS-TRICORPHOS (1939), GRAFF (1940) et PATTON (1941), chacun un cas, ainsi que GRAFF (1940) 2 cas.

Si nous tenons compte des endométrioses se présentant dans la région de l'anse sigmoïde rectale, le nombre des cas monte considérablement, si je ne nomme que les suivants: MICHAEL (1937), SCHULER (1931), OEHLECKER (1932), MASSON (1935), CATTEL (1937), HENSCHEN (1941) et HULTÉN (1941). Ici on n'a pas encore observé les cas, où la maladie a été constatée simultanément dans plusieurs endroits, comme p. ex. dans les organes génitaux et le rectum, dans les organes génitaux et le vagin rectal du canal de Fontana ou dans les organes génitaux et la vessie, etc.

Associés à une endométriose localisée ailleurs, des foyers pareils, parsemés dans l'anse sigmoïde, ont été rencontrés par TURUNEN seulement dans notre pays 5 fois sur 200 cas.

Par rapport à son apparition l'endométriose est subdivisée en deux grands groupes: *l'endométriose interne et externe.* Le premier groupe se rapporte à l'endométriose se présentant dans l'utérus et les tubes et le dernier celle qui se rencontre partout ailleurs.

L'endométriose externe a encore été subdivisée par TURUNEN comme suit:

Endometriosis externa.

I. E. *extraperitonealis* (primaria)	II. E. *intraperitonealis*
1. E. portionis	1. E. serosae pelvis
2. E. vaginae	2. E. retrocervicalis
3. E. perinei	3. E. retrouterina
4. E. cicatric. post. lapar.	4. E. ovarii
	5. E. intestini

E. extraperitonealis secundaria

1. E. spatii recto-genitalis
2. E. recti et intestini
3. E. vesicae urinariae
4. E. canalis inguinalis
5. E. umbilici.

Dans les conditions actuelles il est difficile de donner une idée exacte de la fréquence de l'endométriose dans l'intestin.

Si nous nous bornons pour le moment à parler des cas qui se

rencontrent seulement dans l'anse sigmoïde et les régions adjacentes du rectum, il faut dire, que le tableau pathologico-anatomique y a varié un peu. L'essentiel dans la maladie est une strieture dans les parois de l'intestin. Dans tous les cas la muqueuse a été intacte. Seulement dans la partie supérieure de la strieture KONJETZNY a constaté des altérations ulcéreuses et inflammatoires, qu'il considère comme consécutives à une occlusion intestinale chronique (colitis stereoralis). Dans tous les cas la submuqueuse a été molle, contenant beaucoup de liquide. A l'égard de la couche musculaire, par contre, les cas décrits par différents auteurs présentent des dissemblances. Ainsi, dans le premier cas de KONJETZNY les formations de nature kystseuse siégeaient uniquement dans le système musculaire annulaire, tandis que dans l'autre cas celui-ci était complètement détaché, les altérations se rencontrant dans le système musculaire longitudinale ou plus exactement dans l'épaisissement ressemblant à un myome, situé à l'extérieur de la paroi intestinale. En proche parenté avec ce dernier cas on peut considérer celui publié par LAMARE, LARGET et ISIPOR, où la muqueuse, la submuqueuse et la couche musculaire sont restées intactes, mais où l'on a trouvé par contre dans la subséreuse et le mésentérium un épaisissement gros de plusieurs cm., où l'on a rencontré des kystes tapissés d'épithélium. A ce propos il faut mentionner aussi le cas de GROSS. Il s'agit d'une femme de 62 ans, opérée antérieurement à cause d'un cancer de l'intestin rectal. Après l'opération il fut constaté dans la submuqueuse et le système musculaire de l'anse sigmoïde une croissance épithéliale hétérotopique. Ce phénomène a dévié des constatations antérieures par rapport à l'endométriose dans ceci, qu'il manquait de l'épithélium cylindrique pour tapisser les cavités, ainsi que «du stroma cytogène» autour de celles-ci. Ces altérations, ainsi que le sang menstruel rencontré dans les cavités, ont été expliquées par l'auteur comme des métamorphoses regressives, résultant de la ménopause. Dans mon propre cas on n'a observé rien de pareil, si l'on ne compte pas quelque cavité rencontrée dans la subséreuse, d'où l'épithélium manquait. Des altérations ont été rencontrées dans toutes les couches intestinales, sauf dans la muqueuse, comme il en a été déjà dit.

D'autre part *le tableau clinique* a été assez conforme. L'âge moyen des malades a été un peu plus de 40 ans. Le sujet le plus jeune avait 29 ans (LAMARE, LARGET et ISIPOR) et le sujet le plus vieux 62 ans (GROSS).

Fig. 1

Fig. 2.

KLOSSNER: Sur l'endométriose se présentant dans l'anse sigmoïde.

Fig. 3.

Fig. 4.

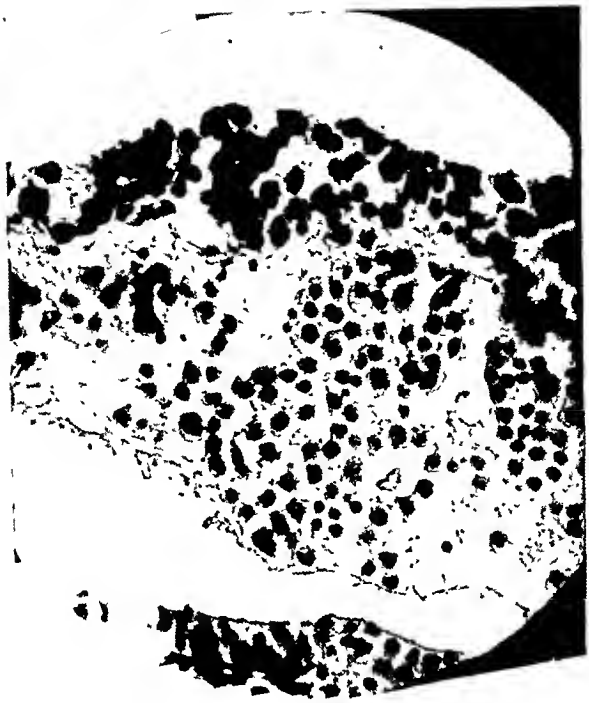

Fig. 5.

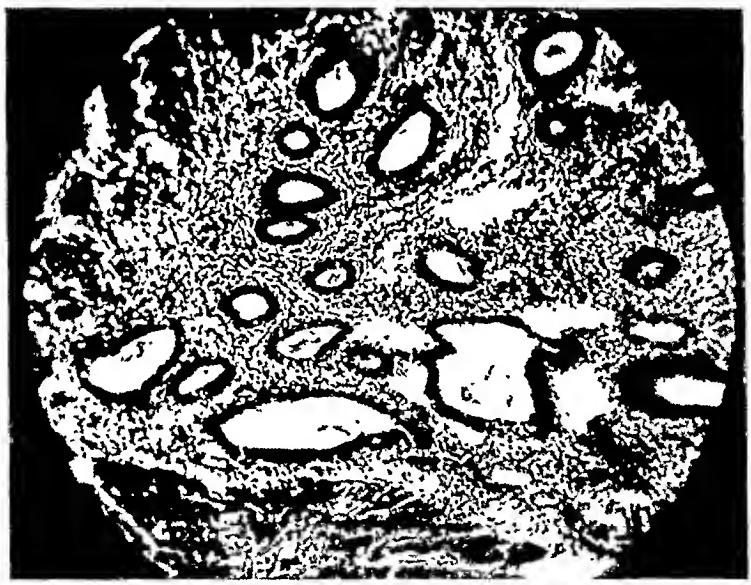

Fig. 6.

KLOSSNER: Sur l'endométriose se présentant dans l'anse sigmoïde.



Fig. 7.

Fig. 8.



Fig. 9.

Fig. 10.

KLOSSNER: Sur l'endométriose se présentant dans l'anse sigsmoïde.

Fig. 11.

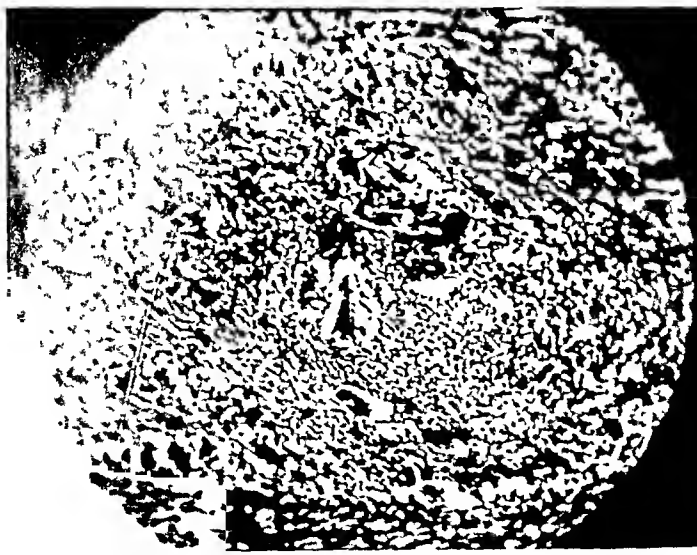

Fig. 12.

Les premiers symptômes de la maladie ont été, sans exception, des coliques venteuses, des douleurs et une constipation intermittente, terminant par un état de subiléus ou par une occlusion complète. La plupart des cas ont été opérés immédiatement dès l'arrivée à l'hôpital, dans une phase d'occlusion complète. Il est à observer qu'un état pareil a pu varier d'après le stade des menstrues.

Dans les cas, où le rectum ou les régions adjacentes de celui-ci et de l'anse sigmoïde ont été atteints, le tableau clinique a été à peu près le même que dans les cas précédents. Pourtant on trouve plus de symptômes dans les cas du rectum. Je suis ici principalement l'exposé de HULTÉN. Communs pour ces cas sont les coliques venteuses et la constipation, qui peuvent augmenter pendant la période des menstrues et diminuer pendant l'intervalle. Avec le temps la constipation devient pourtant plus grave et se décharge parfois comme une diarrhée. Des ténesmes peuvent se présenter assez tôt. Dans plusieurs cas l'épanchement de sang du rectum manque complètement, circonstance que HULTÉN considère comme un signe très important pour le diagnostic différentiel à l'égard du cancer. Dans les cas avancés les menstrues sont chaque fois très pénibles pour la malade.

Le palpage effectué par le rectum donne quelques points d'appui. Avant tout on sent dans le rectum une stricture annulaire, recouvert d'une muqueuse intacte, lisse. Autour du rectum on sent une infiltration ferme, sensible, qui est attachée au bassin et qui enferme l'une ou les deux annexes. Comme symptôme important HULTÉN considère encore ceci, qu'il ne reste dans la gaine des taches de sang comme il en est souvent le cas dans les carcinomes.

A l'examen par la rectoscopie on observe le rétrécissement déjà décrit, ainsi qu'une muqueuse intacte, lisse. Dans les cas rares seulement, où le tissu de l'endométriose a pénétré par la muqueuse, on peut remarquer des formations ressemblant à des polypes, dont on peut prendre un morceau à essai pour l'examen microscopique. KONJETZNY, comme aussi FÜRST et SKORPIL veut qu'on fasse la rectoscopie plusieurs fois, vu que le cycle menstruel a une grande influence sur le tableau clinique.

Dans le même sens vont les observations de JUDD-FOULDS et MEYER. Dans un cas FÜRST et SKORPIL ont constaté, pendant les menstrues, une grande tumeur dans la paroi antérieure du rectum, qui était recouverte d'une muqueuse enflée, en partie dé-

chirée et sanglante. Cette tumeur a obstrué tout l'intestin. Quelques jours après les menstrues les douleurs avaient disparu et l'on ne sentait qu'un endroit dur, recouvert d'une muqueuse déchirée.

L'examen par les rayons X à l'aide d'une substance ombrageante donne, dans les cas bas, très peu d'appui. Dans les cas de l'anse sigmoïde cet examen est pourtant plus positif.

L'établissement du diagnostic dans les cas du rectum, ainsi que dans les cas, où l'affection est localisée dans une région adjacente du rectum et de l'anse sigmoïde, ne donne pas beaucoup de difficultés, si l'on y pense seulement. La situation est toute autre dans les cas d'endométriose pure dans l'anse sigmoïde. Il n'y en a pas, à beaucoup près, autant de symptômes comme dans les cas précédents. Les seuls symptômes sont ceux de l'iléus avec ses douleurs, qui peuvent augmenter pendant la période des menstrues, comme il en a été déjà dit, et disparaître pendant l'intervalle. Dans ces cas-là un examen par les rayons X, à l'aide d'une substance ombrageante, peut être d'une grande utilité. On a observé dans ces cas-là que la ligne de démarcation du dessin de la hauteur est intacte, vu que la muqueuse dans cet endroit-là est intacte. Cette circonstance est considérée par plusieurs auteurs, p. ex. Josefsson et Hultén comme très importante du point de vue du diagnostic différentiel.

En faisant l'examen mentionné il faut considérer toutes sortes d'obstructions intestinales chroniques, comme le carcinome, le sarcome, la tuberculose, la syphilis et le lymphogranulome. Quant il s'agit des cas de l'anse sigmoïde, ces cas différents sont directement impossibles à distinguer l'un de l'autre uniquement à l'aide de moyens cliniques. La syphilis amène déjà des difficultés. Bien que la réaction de Wassermann soit positive, il n'est pas du tout dit, que la stricture soit due à la syphilis. D'autre part, s'il est question d'une phase d'occlusion, on n'a pas même le temps d'essayer un traitement ex juvantibus, il n'y a que de faire une opération immédiatement. Si l'on trouve des signes de la tuberculose dans d'autres parties du corps, il faut toujours présumer l'éventualité de l'apparition de cette maladie. Dans le lymphogranulome la réaction de Freid est positive.

Il y a toujours lieu de faire une opération, à mon avis, lorsqu'on a constaté un rétrécissement ou un état d'occlusion. Chez les vieilles femmes on a parfois essayé un traitement des ovaires par les rayons X (Oehlecker, Fürst et Skorpil).

On a eu recours à ce traitement dans les cas où le rétrécissement n'a pas été trop grand.

Vu qu'on ne peut pas établir le diagnostic différentiel à l'égard du carcinome, en tout cas pas avec une sûreté absolue, une opération est le seul traitement juste, à mon avis, afin d'éviter une erreur fatale. D'autre part, il est plus difficile de dire ce qu'il faut faire dans les cas qui ne présentent pas de strictures. Dans quelques cas on a observé que les symptômes ont disparu après l'extirpation pure et simple des ovaires (SAMPSON, MEIGA, SCHWEITZER).

Quelques auteurs ont essayé une castration par les rayons X et ils ont constaté de bons résultats par ce traitement, comme il en a été déjà dit. Par les raisons déjà mentionnées je me placerais absolument sur la base du traitement chirurgical.

Le pronostic est en général bon. Des récidives après l'opération ne sont jamais survenues, semble-t-il (KONJETZNY). Dans mon propre cas il a écoulé bientôt neuf mois après l'opération et la malade se porte bien.

Dans les cas stricturants le traitement est clair, comme il a été déjà dit. Au devant il faut enlever quelque obstacle ou tourner celui-ci d'une façon ou d'une autre, et suivre tout à fait les mêmes méthodes que pour le cancer. Seulement on n'est pas obligé d'être aussi radical, à l'égard des glandes, comme dans le cancer.

De ma propre part je suis de l'avis que la méthode dans deux phases, la traction de l'anse sigmoïde et sa rupture plus tard est plus sûre et moins menaçante pour la vie de la malade que la résection dans une phase. Tout dépend finalement de la nature des cas et avant tout de la mentalité du chirurgien.

Finalement voici un bref coup d'œil sur les *théories par rapport à la naissance de l'endométriose.*

A l'égard de la genèse de l'endométriose interne tous les investigateurs sont du même avis. Cette affection se développe dans la phase post-fœtale par la muqueuse de l'utérus et du tube. Quant à la naissance de l'endométriose externe les opinions sont très partagées.

Depuis longtemps il y a trois groupes de théories, à l'aide desquelles je veux donner l'explication suivante. Les voici:

1. Les théories se basent sur les troubles de développement.
2. Les théories de l'implantation.
3. Les théories des métastases.

BABES (1882) est le premier qui a traité la naissance de l'endo-

métriose et il a cru que les tubes glandulaires, rencontrés dans un myome, provenaient des canaux de Müller. BREAS expliqua que les tubes tiraient leur origine des canaux de Gartner.

RECKLINGHAUSEN (1896) les considérait comme un corps de Wolff, des restes du rein primitif. La théorie a eu beaucoup de partisans, dont il faut nommer, entre autres, ASCHOFF, BLUHM, PICK et PFANNENSTIEL.

La même année IVANOFF (1896) a publié la théorie dite *séro-épithéliale*, suivant laquelle aussi bien l'épithélium de la séreuse que celui de l'utérus proviendrait de l'épithélium *du côlon* et pourrait se changer, dans des conditions déterminées, p. ex. par l'influence d'une infection, en de la muqueuse utérine, soit métaplastique, soit protoplastique et ensuite se modifier en des foyers de l'endométriose. Cette théorie également a beaucoup de partisans, dont le plus remarquable est peut-être MEYER. De plus, LAUCHE a observé que, l'épithélium de la séreuse par l'influence d'une infection, envoie dans la profondeur de longs tubes glandulaires et des rétrécissements, tous recouverts d'épithélium cylindrique. Est-ce bien de l'épithélium utérin proprement dit ou non, voilà une question qu'on n'a pu trancher avec sûreté.

A cette théorie s'associe le plus intimement l'exposé de HELM sur la théorie étendue dite *séro-épithéliale*. Suivant cette théorie il naîtrait des endométrioses «sur les lieux» du tissu mésenchymateux. Il continue encore: «La théorie séro-épithéliale devient plus vaste par l'hypothèse, que des élements cellulaires, particulièrement capables de se développer, provenant du mésothélium, de l'épithélium germinatif et de l'endothélium, ainsi que le mésenchyme, qui est en relation génétique et en dépendance formative avec ceux-ci, par une constitution hormonale déterminée, liée au sexe, peuvent éprouver une différenciation dans la direction des produits de l'épithélium de Müller.»

Je reviendrai à cette question dans le suivant.

D'après *la théorie de l'implantation* que SAMPSON (1921) a été le premier de présenter, l'endométriose naît de cette manière, que la muqueuse de l'utérus, pendant la période des menstrues, pénètre dans la cavité péritonéale, en premier lieu, dans les ovaires et dans le repli de Douglas. D'après TURUNEN ces morceaux muqueux étrangers tomberaient d'abord dans le fond du bassin, de sorte qu'on rencontre de l'endométriose, à un stade précoce, dans le repli de Douglas et ensuite seulement, à un stade plus avancé, dans les ovaires.

Cette théorie a été modifiée par PHILIPP et HUBER (1939) de cette manière que, pendant la période des menstrues, ce n'est pas la muqueuse de l'utérus qui se dégage, mais celle des trompes utérines, de sorte qu'il serait question d'une endométriose tubaire dans la partie intra-murale de celles-ci. De cette région la muqueuse se mettrait en mouvement, d'après HUBER, aussi par l'influence des contractions tubaires. TURTOLA (1942) qui a beaucoup de mérite comme investigateur de l'endométriose tubaire, est arrivé au résultat que l'endométriose tubaire se présente dans 92.8 %, associée à l'endométriose externe intra-péritonéale.

Il reste encore à discuter les théories *métastatiques*. HALBAN (1925) a estimé que les tubes glandulaires, situés dans l'utérus, peuvent se développer dans la couche musculaire et de là, le long des glandes lymphatiques, pénétrer jusqu'à la submuqueuse. Il considère alors comme possible que quelques-uns de ces tubes glandulaires pourraient s'égarer dans le vaisseau lymphatique et par cette voie-là s'éloigner de l'utérus. Il a trouvé dans les nœuds lymphatiques des tubes glandulaires utérins typiques, comme aussi WOLFF et KONJETZNY.

On estime cependant que l'endométriose ne se répand pas uniquement le long des vaisseaux lymphatiques, mais aussi le long des vaisseaux sanguins. SAMPSON est le premier qui a constaté de la muqueuse utérine dans les veines. La même observation a été faite plus tard par ASCHEIM, HUBER et PHILIPP, ainsi que par TURTOLA.

Et puis, comment faut-il expliquer les différents états morbides?

A l'aide de la théorie de l'implantation on pourrait expliquer d'une manière satisfaisante tous ces types d'endométriose externe intrapéritonéale. Aussi dans mon propre cas je pourrais présumer qu'il serait question d'une endométriose tubaire — malheureusement un examen n'a pas été fait — d'où l'affection s'est répandue à la surface de l'intestin. Dans le repli de Douglas il n'y a eu rien en effet qui l'aurait indiqué et une autre observation parle aussi contre cette explication. Si un tissu étranger du dehors aurait pénétré par la paroi intestinale, on pourrait présumer qu'on trouverait, siégeant au-dessous de la muqueuse, le tissu cellulaire le plus frais et dans une phase active. Dans mes préparations le cas était tout le contraire.

Une autre possibilité serait, bien entendu, une infection lymphogène.

Bien que je n'aie rien à dire personnellement sur la base de mon

propre cas à l'égard de cette théorie métastatique, je veux examiner la question encore un peu dans le suivant.

HART, SCHWARZ et CROSSEN ont constaté de l'endométriose dans les poumons. Ce phénomène devrait pouvoir s'expliquer ainsi, que l'endométriose s'y est répandue tout simplement par les voies sanguines. D'autre part, il est plus difficile d'expliquer les cas de BIEBL (1933), NAVRATIL et KRAMER, ainsi que celui de MANK. Dans les premiers cas on a constaté de l'endométriose dans le haut du bras et dans le dernier dans les cuisses. A l'aide de la propagation hématogène on ne peut pas expliquer ces cas autrement qu'en présumant qu'il y a eu simultanément un foramen oval ouvert. Aussi la théorie du système lymphatique est difficile d'y appliquer, bien qu'elle soit cependant possible. Il y a un rapport direct entre le ligament rond, le long de l'utérus, et le pli de l'aisne. De même il y a un rapport de la main, soit à l'aisselle et au cou ou par les mamelles aux glandes lymphatiques intercostales antérieures, postérieures et de là au tronc. Dans un système comme celui du réseau des vaisseaux lymphatiques où la pression est basse, il devrait pouvoir naître, par une raison ou par une autre, même de la régurgitation.

BIEBL lui-même rejette cette théorie lymphogénésique et soutient l'opinion de HELM, en l'étendant de la manière suivante: «que chez la femme pubère, le mésenchyme, dans le sens le plus vaste du mot, est rendu capable de développer des formations endométriosiques dans n'importe quelle région, phénomène auquel la cause dégageante proprement dite, est sûrement à chercher, d'un côté, dans un effet d'excitation due aux hormones, et, de l'autre, propablement dans une sensibilité constitutionnelle correspondante».

Comme résumé de tout ce qui précède je voudrais dire:

L'endométriose hétérotopique n'est plus une maladie qui offre de l'intérêt uniquement aux gynécologues. Aussi les chirurgiens doivent s'en occuper sérieusement et tenir compte de son apparition éventuelle même dans notre domaine d'activité.

Résumé.

L'auteur décrit un cas d'endométriose hétérotopique, se produisant dans l'anse sigmoïde, qui doit être le premier cas constaté en Finlande.

Il s'agit d'une femme de 43 ans qui est venue à l'hôpital à l'occasion d'un état de sub-iléus, qui s'est apaisé cependant vite. Le gynécologue qui l'a traité a constaté dans le bas-ventre une grande tumeur, à cause de quoi il pratiqua: Amputatio uteri supravaginalis. S.-O.-ectomia bilat. Secondairement il a constaté dans l'anse sigmoïde une tumeur stricturante, de la grosseur de deux à trois doigts, qu'il a cru être un carcinome. A cause de cela il a envoyé la malade, 11 jours plus tard, au traitement d'un chirurgien avec le diagnostic: Carc. fl. sigmoid. Lors d'une nouvelle opération on a tiré l'anse sigmoïde qu'on a coupé quelques jours plus tard. A l'examen microscopique il fut constaté que la tumeur était une endométriose hétérotopique. L'auteur donne une description minutieuse de la structure pathologico-anatomique de la tumeur et du tableau clinique du cas et discute ensuite le diagnostic, le traitement et l'origine de la maladie.

En publiant ce cas l'auteur a voulu attirer l'attention de ses collègues aussi sur cette maladie, vu qu'il n'est pas toujours facile de la distinguer du carcinome. Ce n'est plus uniquement aux gynécologues que cette maladie offre de l'intérêt, aussi les chirurgiens doivent s'en occuper.

Summary.

The author describes a case of heterotopia endometriosis in the sigmoid flexure, in all probability the first case which has been diagnosed in Finland.

The patient was a 43 year old married woman who presented a subileus condition when she was admitted to hospital. The ileus condition, however, soon passed over. The gynecologist in charge of the case diagnosed a large tumor in the bottom of the abdomen and therefore performed: amputatio uteri supravaginalis. S.-O.-ectomia bilateralis. He also observed a stenosed tumor in the sigmoid flexure which was as thick as two fingers. He believed that the tumor was a carcinoma. For this reason he transferred the patient eleven days later to the surgical side for surgical treatment diagnosed: Carc. fl. sigmoid. At a new operation the sigmoid flexure was exposed and divided some days later. A microscopic examination showed that the tumor was a heterotopia endometriosis. The author gives a detailed pathoanatomic description of the structure of the tumor and of the clinical picture

which the case presented: he also describes the diagnosis, treatment and the genesis of the disease.

By publishing the details of this case the author wishes to draw the attention of colleagues to this disease as it is not always easy to distinguish it from carcinoma. The disease is not only interesting for gynecologists but surgeons should also bear it in mind.

Zusammenfassung.

Verf. beschreibt einen Fall von heterotoper Endometriose der Flexura sigmoidea, wahrscheinlich der erste im Lande beschriebene Fall.

Die Patientin war eine 43jährige Frau, die bei der Aufnahme in die Klinik einen Subileuszustand aufwies. Der Ileuszustand öste si ch jedoch bald. Der behandelnde Gynäkologe stellte einen grossen Tumor am Boden der Bauchhöhle fest und nahm deshalb Amputatio uteri supravaginalis, S.-O.-ectomia bilateralis vor. Als Nebenbefund beobachtete er einen stenosierenden, etwa zwei Finger dicken Tumor der Flexura sigmoidea. Er hielt den Tumor für einen Krebs. Deshalb wurde die Kranke 11 Tage später mit der Diagnose Carc. flex. sigmoid. in chirurgische Behandlung übergeführt. Bei erneuter Operation wurde die Sigmoideumschlinge hervorgelegt und einige Tage später durchtrennt. Bei mikroskopischer Untersuchung wurde festgestellt, dass der Tumor eine heterotope Endometriose war. Verf. gibt eine eingehende pathologisch-anatomische Beschreibung des Baues der Tumors und des klinischen Bildes, das der Fall darbot, und berührt darauf die Diagnose, die Behandlung und die Krankheitsgenese.

Durch Veröffentlichung dieses Falles hat Verf. die Kollegen auch auf diese Krankheit aufmerksam machen wollen, da sie nicht immer leicht vom Krebs zu unterscheiden ist. Die Krankheit interessiert heutzutage nicht nur den Gynäkologen. Auch der Chirurg muss daran denken.

Littérature.

Ascheim: Gynéc. et Obstétr. *40*, 1939. — Aschoff: Mschr. Geburtsh. 1899. — Babes: réf. par Turtola. — Biebl: Zbl. Chir. *65*, 1938. — Cattel: réf. par Z. org. Chir. *87*, 1938. — Chydenius: Finska Läk.-sällsk. Hdl. *75*, 1933. — Crossen: Amer. J. Obstetr. *7*, 1927. — Fürst: réf. par Konjetzny. — Graff: Zbl. Gynäk. 1940. — Gross: Frankf. Z. Path. *33*, 1925. — Halban: Arch. Gynäk. *124*, 1935. — Harbitz: Acta

chir. scand. *74*, suppl. *30*, 1934. — HARBITZ: Nord. med. tidskr. 1936. — HART: Frankf. Z. Pathol. *10*, 1912. — HENSCHEN: Schweiz. med. Wschr. *2*, 1941. — HERBERZ: Mschr. Geburtsh. 1933. — HUBER: Z. Geburtsh. *117*, 1938. — HUBER: Arch. Gynäk. *166*, 1938. — HUBER: Zbl. Gynäk. *14*, 1939. — HULTÉN: Nord. Med. 1941. — IVANOFF: Mschr. Geburtsh. *7*, 1898. — JOSEFSSON: Acta obstetr. scand. *19*, 1939. — KONJETZNY: Chirurg. 1935. — KRAMER: Klin. Wschr. *2*, 1936. — KRAMER: Klin. Wschr. *48*, 1936. — KÄRKI: Duodecim *8*, 1932. — LAMARE, LARGET et ISOPOR: Ann. d'Anat. path. *15*, 1938. — MANKIN: Arch. Gynäk. *159*, 1935. — MASSON: Ann. Surg. *102*, 1935. — MICHAEL: réf. par Z. org. Chir. *41*, 1928. — NAVRATIL: Klin. Wschr. *2*, 1936. — NAVRATIL: Klin. Wschr. *48*, 1936. — NAVRATIL: Klin. Wschr. *1*, 1939. — NYLANDER: Zbl. Chir. *65*, 1938. — OEHLECKER: Zbl. Chir. *59*, 1932. — PALMÉN: Acta chir. scand. *62*, 1927. — PATTON: Amer. J. Surg. *53*, 1941. — PETERSON: Finska Läk.sällsk. Hdl. *73*, 1931. — PFANNENSTIEL: réf. par TURTOLA. — PHILIPP et HUBER: Zbl. Gynäk. *63*, 1939. — PICK: Virch. Arch. *156*, 1899. — RAURAMO: Duodecim *11*, 1936. — RECKLINGHAUSEN: réf. par HARBITZ. — SAMPSON: Amer. J. Obstetr. *4*, 1922. — SAMPSON: Amer. J. Obstetr. *10*, 1925. — SAMPSON: Amer. J. Obstetr. *12*, 1926. — SAMPSON, Amer. J. Obstetr. *14*, 1927. — SAMPSON: Amer. J. Obstetr. *16*, 1928. — SAMPSON: Amer. J. Obstetr. *20*, 1930. — SAMPSON: Amer. J. Obstetr. *24*, 1932. — SAMPSON: Amer. Journ. Path. *3*, 1927. — SBAROUNIS-TRICORPHOS: réf. par Z. org. Chir. *95*, 1939. — SCHULER: Zbl. Chir. 1931. — SCHWARZ: Amer. J. Obstetr.: *7*, 1924. — SKORPIL: réf. par KONJETZNY. — TURTOLA: Acta obstetr. scand. *22*, suppl. 1, 1942. — TURUNEN: Duodecim *2*, 1937. — TURUNEN: Acta obstetr. scand. *18*, 1938. — TURUNEN: Acta obstetr. scand. *19*, 1939. — WICHMANN: Acta obstetr. scand. *13*, 1934. — WOLFF: Frankf. Z. Path. *40*, 1930.

Sur les Epididymites aiguës non specifiques.

Par

AULIS KORHONEN.

La guerre amène souvent avec elle plusieurs sortes de maladies presque épidémiques qu'on rencontre relativement peu en temps de paix et alors seulement sporadiquement. Ces expériences se sont renouvelées maintenant comme pendant la guerre mondiale précédente.

Une de ces maladies est l'épididymite aiguë non spécifique qui s'est rencontrée pendant ces deux dernières années dans des proportions tout à fait frappantes dans l'armée, moins dans la population civile.

Il paraît que les conceptions sur le début de processus clinique de l'épididymite non spécifique sont encore partiellement vagues, partiellement fausses. Aussi appelle-t-on l'épididymite chronique non spécifique le type dont le début est aigu, subaigu ou chronique et qui devient chronique (Kappis, Anschütz etc.). Par conséquent la maladie est considérée en règle générale comme chronique. Toutefois les différentes autorités ne mentionnent point combien de temps la maladie a duré avant qu'on l'ait estimée comme chronique. La cause en est évidemment qu'on attribuait à la maladie un caractère tuberculeux car dans ses débuts il était impossible de la distinguer de la tuberculose d'après des symptomes cliniques et des examens. Aussi s'est-on servi comme traitement de l'épididymectomie qui seule a été considérée adéquate et assez expérimentée. Mais quand les examens histologiques avaient démontré qu'on ne pouvait constater aucun signe typiquement tuberculeux, mais seulement des changements généraux inflammatoires non spécifiques, on était contraint de changer d'avis sur la genèse de ces épididymites. Elles n'étaient

donc pas provoquées par la tuberculose. Et elles ne restaient pas toutes chroniques.

L'épididymite née après la guerre mondiale précédente (1914—1918) n'a évidemment pas été très répandue, car la littérature médicale ne présente qu'une vingtaine de publications sur ce sujet.

Je mentionne ci-dessous le chiffre des cas les plus nombreux et les plus importants.

Sur les 606 cas de CAMBELL il y avait 326 (54 %) non spécifiques, sur les 58 cas de LEMPERT 33 (57 %), sur les 192 cas de LJUNGREN 83 (43 %) sur les 90 de REINECKEN 52 (57 %), sur les 115 cas de STEVENS 35 (31 %), sur les 58 cas de SÖDERLUND 6 (10 %) et sur les 300 de WILDBOLZ 26 (12 %). Chez nous JÄRVINEN vient de publier 18 (57 %) cas non spécifiques sur 30 cas.

Les autres publications ne reposent que sur quelques cas isolés.

La matière examinée.

La matière a été recueillie dans son ensemble dans les hôpitaux militaires de la zone de guerre et tous mes malades étaient des soldats. J'ai examiné tous les cas personnellement et j'ai soigné mes malades jusqu'à ce qu'ils soient renvoyés, aptes au service, dans leurs unités. La durée d'observation après la sortie de l'hôpital des malades a varié de 1 à 6 mois. Le total de mes cas est 40. De plus j'ai soigné partiellement dans ces mêmes hopitaux, partiellement ailleurs presque autant d'épididymites aiguës non spécifiques que je n'ai pas pu soigner jusqu'à la guérison pour certaines raisons, mais qu'on a dû renvoyer ailleurs quand les manifestations s'étaient calmées. Ces cas ne sont pas inclus dans la matière que j'ai traitée bien qu'eux aussi aient contribué à mes expériences cliniques considérablement à ce sujet, car je n'ai pas eu d'occasion d'en éliminer des cas qui peut-être étaient tuberculeux ou supçonnés comme tels.

L'âge de mes sujets a varié assez régulièrement de 21 à 34 ans, donc tous en service militaire. De ceux qui avaient de 24—26 ans il y avait quelque peu plus, environ 20 % du total.

18 (45 %) étaient mariés et 22 (55 %) non mariés.

De toute façon tous les malades s'étaient accouplés. Le temps écoulé entre le dernier coït et le commencement de l'épididymite est montré dans le tableau que voici:

Moins d'un mois	de 1 à 2 mois	de 2 à 3 mois	de 3 à 4 mois
8	15	15	2

L'épididymite a donc apparu le plus souvent 2 ou 3 mois après le dernier coït. Dans chacun de ces deux groupes il y avait 15 cas (37.5 %). Réunis ces groupes nous donnent le total de 30 cas (75 %).

Les malades eux-êmes ont constaté la sensibilité croissante de l'épididyme qui gonflait au cours de la journée, 26 cas quand les malades étaient en mouvement ou au travail, 14 pendant la nuit quand les malades étaient réveillés par des douleurs.

L'épididymite s'est rencontrée unilatéralement sur 38 cas (95 %) dont 18 du côté droit, 20 du côté gauche, la différence entre les épididymites unilatérales étant alors à cet égard presque nulle. Il n'y avait que 2 cas bilatéraux. Dans tous ces deux cas l'épididyme gonflait par intervalles de 2 ou 3 jours.

Selon les malades les douleurs débutaient dans tous les cas dans la partie inférieure, c'est-à-dire dans la partie caudale de l'épididyme laquelle partie s'est montrée la plus gonflée à l'examen.

8 seulement de mes malades ont signalé des douleurs en urinant et surtout la pollacisurie, principalement au cours de la journée. Il n'y avait que 3 malades qui souffraient de pollacisurie même la nuit 2 ou 3 fois. Chez tous les malades les douleurs de pollacisurie ont disparu au cours des 3 ou 4 premiers jours du début de la maladie.

Aucun des malades n'avait d'écoulement de pus ni d'autres sécrétions anormales de l'urètre.

La prostate de tous les malades fut examinée également en la palpant du doigt par le rectum. Dans aucun des cas on ne pouvait constater dans la prostate rien d'exceptionel, elle n'était même pas sensible au toucher. Au microscope on n'a constaté ni de bactéries ni de cellules inflammatoires dans la sécretion de la prostate obtenue par la palpation.

Dans la vessie de tous les malades on a fait des prélèvements d'urine par le cathéter. La réaction de l'urine était partout acide, on n'y trouvait ni albumine ni bactéries. Il y avait des globules blancs en 21 cas, de plus il y avait des globules rouges en 12 cas et puis des cellules épithéliales en 11 cas, toutefois dans les proportions insignifiantes. On n'y rencontrait pas non plus de bacilles tuberculeux. Le résultat de la culture de Löwenstein que j'eus l'occasion de faire, était partout négatif.

On n'a trouvé de gonocoque dans aucun cas, bienqu'on ait fait des prélèvements sur l'orifice de l'urètre de tous les malades.

Dans tous les cas les réactions Wassermann et Kahn se sont montrées négatives.

La réaction de sédimentation (WESTERGREN) après une heure était comme suit:

moins de 10	11—20	21—30	31—40	41—50	51—60
0	24	12	8	0	2

Tous les malades avaient la fièvre pendant les premiers commencements de la maladie à peu près 37.5—38°, dans 3 cas jusqu'à 39°. La fièvre disparaissait tout de même au cours des premiers jours, au plus tard au bout d'une semaine depuis l'entrée du malade dans l'hôpital.

Comme il était convenu par avance qu'on enverrait toutes les épididymites aiguës non spécifiques dans ces hôpitaux où je travaillait, la majorité étaient soumis à mes soins 2 ou 3 jours après la contraction de la maladie; le reste au cours de la première semaine.

Les malades suivaient le traitement dans l'hôpital jusqu'à ce que toutes les manifestations aient disparu et que la réaction de sédimentation (WESTERGREN) soit normale, après quoi on leur a donné une convalescence d'une quinzaine de jours. Après la convalescence ils revenaient pour l'examen de contrôle ou bien ils étaient renvoyés, aptes au service, directement dans leurs unités. Le gonflement de l'épididyme était alors complètement disparu dans 25 cas, dans 15 il y en restait un léger gonflement dans la partie caudale de l'épididyme. La surface de l'épididyme était dans tous les cas tout à fait lisse et de consistance normale. On conseilla aux malades de revenir à l'hôpital en cas de récidive. Deux d'entre eux seulement sont revenus au bout de huit jours à cause du gonflement et de la sensibilité du même l'épididyme survenus par suite d'une longue marche à laquelle tous les deux avaient participé tout de suite après la sortie de l'hôpital. Après un repos d'une quinzaine de jours les symptômes avaient de nouveau disparu complètement et ne récidivèrent plus.

Tous les malades ont suivi un traitement conservateur avec les compresses, le suspensoir sous le scrotum jusqu'à ce que les manifestations les plus aiguës se fussent calmées, après quoi on a appliquée des compresses chaudes. En dehors de cela on a donné du sulfathiazole 0.5 gr trois fois par jour au cours de la phase de fièvre. De cette manière on a procédé jusqu'à ce que la sensibilité fût disparue et que la réaction de sédimentation fût normale.

Les malades étaient renseignés sur toutes les possibilités qu'on pouvait supposer avoir concourues à l'inflammation de l'épididyme.

Il n'y a pas eu d'anomalies sexuelles comme masturbation ou homosexualité d'après les informations des malades que j'ai questionnés confidentiellement tête à tête sur ce sujet.

Parmi mes cas il y avait relativement peu de maladies antérieures dignes d'être mentionnées. Il y en avait un qui avait eu l'urétrite simplex 3 semaines avant le commencement de l'épididymite guérie en 5 jours à la pneumolysine. Huit jours après on constatait des stries de sang dans le sperme après le coït. Un autre avait eu la blennorragie 4 mois auparavant, également guérie à la pneumolysine en 5 jours. Un troisième avait eu une légère épididymite du même côté 2 mois auparavant, mais guérie spontanément en 3 jours. L'un avait souffert de polyurie de temps en temps au cours de la journée bienqu'on n'ait pu constaté rien d'anormal dans la vessie. Un autre avait eu l'hépatite 2 ans auparavant. De plus il y avait encore un malade qui avait eu une infiltration tuberculeuse dans la pointe d'un poumon guérie après traitement sans suite.

Aucun n'avait eu de lésions dans la région génitale excepté un des cas mentionnés ci-dessus, chez lequel on avait constaté des stries de sang dans le sperme après le coït.

Sur la pathogénie et l'étiologie.

Tous les chercheurs sont d'avis que l'épididymite aiguë non spécifique est inflammatoire par sa genèse. Par contre on n'est pas unanime quant au bacille ou au virus qui la provoque en chaque cas particulier. D'ailleurs plusieurs facteurs soit généraux soit locaux, peuvent entrer en ligne de compte.

Dans la littérature médicale on rencontre une grande variété d'opinions quant à la bactérie qui provoque l'épididymite non spécifique. D'après Dorn et Flesch-Thebesius ce sont les peu virulents staphylocoques qui en seraient la cause en provoquant une légère infection générale d'abord et qui passeraient ensuite par les reins, toutefois sans les endommager, jusqu'aux voies urinaires inférieures. Ici ils n'enflammeraient que la vessie et la partie postérieure de l'urètre, par où ils aboutiraient à l'épididyme. Cette conception me paraît assez probante car pour quelle raison les reins, qui fonctionneraient en ce cas comme premier filtre de

bactéries, ne seraient-ils donc pas enflammés. Il y en a qui considèrent que l'épididymite est provoquée par ces bactéries à l'état normal apathogénique, qui se trouvent dans l'urètre sain, tels que les staphylocoques, les microcoques, les streptocoques hémolytiques et dont la virulence s'accroît ensuite par une raison quelconque de sorte qu'ils deviennent pathogéniques. On pourrait signaler comme telles causes les refroidissements, les lésions ainsi que la baisse de la résistence générale. Toutefois plusieurs trouvent cette explication insuffisante et également à mon avis elle ne semble pas avoir assez de poids, car on pouvait croire que ces bactéries produiraient d'abord des manifestations inflammatoires visibles dans la partie postérieure de l'urètre. Il n'en est tout de même pas ainsi. Puhl a prétendu pourtant avoir trouvé dans ses examens urètroscopiques dans la partie postérieure de l'urètre des altérations inflammatoires telles que la dilatation des orifices des voies grandulaires ainsi que des membranes de fibrine n'ayant tout de même pas causé de troubles subjectifs. Même cette hypothèse paraît étrange si nous prenons en considération avec quelle sensibilité la partie postérieure de l'urètre réagit à la fonction de la vessie. Car c'est justement là l'origine de la suspectibilité des réflexes qui règlent les sphincters de la vessie.

Les opinions des chercheurs varient aussi quant à la propagation des facteurs provoquant l'épididymite. Ce sont alors soit les voies sanguines et lymphatiques soit l'épithélium de la cavité du canal séminifère qui entrent en ligne de compte.

Plusieurs (Kappis, Seifert, Schäffer, Dietel, Wehner, Cambell, Dorn, Flesch-Thebesius, Burmeister, Cahn, Lempert, Frey, Järvinen etc.) estiment que la propagation par le canal séminifère, c'est-à-dire par voie canaliculaire, est la plus générale considérant alors la partie postérieure enflammée de l'urètre comme le point de départ le plus voisin de l'inflammation.

On a constaté que le liquide dans le ductus deferens est centripète, alors il se dirige de l'épididyme vers l'urètre. Le fait que la propagation des bactéries sans mobilité peut être centrifuge le long de la membrane muqueuse du ductus deferens présuppose quelque trouble dans le péristaltisme du ductus deferens. Akutsu, Oppenheim et Löw ont constaté sur cobaye et lapin que par l'irritation électrique du ductus deferens et du nervus hypogastricus on peut produire des mouvements antipéristaltiques dans le ductus deferens, donc des mouvements vers l'épididyme. On a émis l'hypothèse qu'également en connexion du traumatisme de pareils

mouvements se produisent (SIMMOND, SCHÄFFER, OPPENHEIM, LÖW) même quand il s'agit de toutes petites lésions si elles sont fréquentes.

S'il en était ainsi la propagation centrifuge serait facile à comprendre.

Toutefois les recherches de FREY lui ont donné des résultats contraires. FREY prétend que les irritations mécaniques, thermiques ou électriques ne se produisent pas, en tout cas pas chez les animaux, de mouvements centrifuges vers le ductus deferens et que par conséquent les mouvements du ductus deferens ne peuvent pas étendre l'infection du ductus deferens à l'épididyme.

LOMMEL a émis l'hypothèse que le contenu de ductus deferens peut se propager dans la direction centrifuge bien que le péristaltisme soit normal si dans la partie centrale du ductus deferens se trouve quelque obstacle causant l'accumulation de la sécrétion.

SEIFERT est de l'avis que la pression élevée dans l'urètre peut amener la pénétration des bactéries et des sécrétions inflammatoires dans le ductus deferens et dans l'épididyme, surtout si l'orifice du ductus deferens dans la paroi de l'urètre est ouvert pour quelque raison.

Certes, toutes les possibilités mentionnées ci-dessus peuvent concourir à l'inflammation de la prostate et de l'urètre surtout quand il s'agit d'inflammation maligne. Mais ces causes ne nous offrent pas assez d'explication quand malgré les investigations renouvelées des épididymites quasi épidémiques on ne trouve aucun signe inflammatoire ni dans la prostate ni dans l'urètre ni dans les voies urinaires en général.

Revenons maintenant à la propagation par voie sanguine et lymphatique. Il paraît que les vaisseaux lymphatiques jouent à ce propos un rôle moins important bienqu'on ne puisse pas exclure cette possibilité totalement. Ce sont donc les vaisseaux sanguins qui nous importent. WILDBOLZ, ROVSING et BOSHAMER ont insisté sur l'importance que la propagation hématogène de l'inflammation peut avoir soit dans les épididymites non spécifiques soit dans les épididymites tuberculeuses. Cela paraît d'ailleurs assez naturel ces cas étant alors comparables à des affections rénales inflammatoires, à ces néphropyélites non spécifiques ainsi qu'à des tuberculoses rénales qu'on considère également provoquées par voie hématogène.

On a insisté également sur le rôle du traumatisme dans la genèse des épididymites non spécifiques surtout dans les régions

de l'urètre. Il va de soi que les rétrécissements cicatriciels causés par des lésions peuvent contribuer à la naissance de l'inflammation dans l'urètre. On a surtout souligné l'importance des lésions insignifiantes mais fréquentes (KAPPIS, WEHNER, SCHÄFFER etc.) car l'inflammation siège facilement dans les plis nés par des ruptures de la muqueuse. Les lésions fréquentes peuvent ré-enflammer une inflammation restée latente.

Les lésions directes et indirectes causées par les sports ont été aussi considérées comme facteurs étiologiques et également les excès sexuels ainsi que la masturbation.

Les recherches.

Avant qu'on puisse élucider la nature non spécifique de l'inflammation en traitant la pathogénie et l'étiologie de l'épididymite non spécifique, il faut pouvoir en exclure les inflammations spécifiques certaines. En cette occurrence peuvent être prises en considération surtout les inflammations syphilitiques, blennorragiques et tuberculeuses dont la fréquence s'est augmentée excessivement pendant la récente guerre.

La syphilis dans l'épididyme est en général assez rare, car elle siège le plus souvent dans le testicule. Aux dires de mes malades aucun d'eux n'a eu de syphilis et aussi les réactions WASSERMANN et KAHN se sont montrées négatives dans tous les cas. Et chez aucun d'eux on n'a constaté ailleurs de signes syphilitiques à l'examen de sorte que j'estime qu'on peut exclure cette possibilité avec certitude.

Un deuxième facteur important spécifique est la blennorragie. Outre le fait qu'elle provoque souvent l'épididymite comme une complication directe elle peut la provoquer aussi comme suite d'une infection secondaire laquelle infection se rencontre souvent en connexion de la blennorragie. Également les autres complications de la blennorragie comme la prostatite et la sténose de l'urètre peuvent provoquer l'épididymite non spécifique soit par leur foyers de bactéries soit en causant des troubles de l'ecoulement du liquide dans le ductus deferens. Un seul de mes malades avait eu 4 mois auparavant la blennorragie guérie toutefois en 5 jours totalement sans complications. Je peux donc exclure les facteurs prédisposants de la blennorragie.

La tuberculose par contre est un facteur important comme je l'ai mentionné d'ailleurs ci-desus. L'épididymite tuberculeuse

n'est jamais primaire étant toujours de nature endogène secondaire le foyer primaire se trouvant quelque part en dehors de l'appareil urogénital. En cas d'affection de celui-ci la tuberculose peut se présenter uniquement dans l'épididyme ou bien comme complication de la tuberculose rénale ou de la tuberculose de la vessie.

Chez un seul de mes malades il y avait eu six mois auparavant une condensation tuberculeuse dans la pointe de l'autre poumon guérie sans complication. On ne pouvait constater chez lui après cela aucun autre signe tuberculeux. Chez les autres malades jamais aucun signe tuberculeux ne s'était rencontré et même objectivement on ne pouvait constater rien de tuberculeux. La culture de LÖWENSTEIN, faite de l'urètre dans 15 cas a donné des résultats négatifs partout. Je n'ai pas eu l'occasion de faire d'inoculation sur cobaye. J'observe particulièrement en cette occurrence que j'ai choisi mes malades de telle manière que les cas soupçonnés tuberculeux ont été éliminés dès le commencement, car j'avais l'intention d'investiguer explicitement les épididymites non spécifiques. Prenant en considération les points de vue mentionnés ci-dessus comme aussi la rapide guérison et l'observation des sujets après la guérison j'estime qu'on peut exclure la possibilité de la tuberculose de mes cas avec assez de certitude.

Si nous passons ensuite à l'étude des facteurs non spécifiques qui peuvent entrer en ligne de compte en sens étiologique nous voyons qu'eux non plus ne nous offrent pas assez de points d'appui.

La répartition des cas parmi des classes en service militaire était assez égale.

Quant aux mariés et non mariés il n'y avait pas de différence notable, d'ailleurs tous avaient eu des rapports sexuels pendant la permission. Le plus souvent d'épididymite aparaissait 2—3 mois après le dernier coït (cette définition du temps ne devra pourtant pas avoir beaucoup d'importance). On a émis l'hypothèse que la privation d'une longue durée ainsi que le spermastase produiraient le gonflement de l'épididyme. Selon moi cette conception ne paraît pas juste, car l'éjaculation physiologique spontanée se produit régulièrement par intervalles de deux ou trois semaines.

L'examen des facteurs étiologiques nous amène à conclure qu'il s'est agi apparemment d'une infection, par surcroît d'une infection presque épidémique. Par contre il est plus difficile de constater de quelle manière l'agent provocateur de l'inflammation a abouti à l'épididyme ainsi que de savoir si le foyer primaire s'est trouvé quelque part ailleurs.

Tous les malades étaient en bonne santé immédiatement avant la contraction de l'épididymite. Aucun d'eux n'avait subi d'investigation instrumentale dans les voies urinaires et aucun n'avait été frappé par une lésion quelconque.

En examinant l'épididymite non spécifique nous cherchons des foyers d'inflammation naturellement aussi dans les voies urinaires. JÄRVINEN a dans ses matériaux, qui comprennent 18 épididymites non spécifiques, constaté des globules blancs dans l'urine dans 15 cas, mais il n'a pas trouvé de bactéries dans le sédiment coloré de l'urine ou dans la culture dans un seul cas. Néanmoins JÄRVINEN estime, se basant uniquement sur ce fait, que plus de quatre cinquièmes de ses cas avaient des signes d'irritation dans la partie postérieure de l'urètre et dans la vessie bien que seulement quelques-uns des malades eussent au début de leur maladie des symptômes subjectifs de l'urètre.

Sur mes 40 cas il y avait des globules blancs dans 21 cas, dans 12 des globules rouges et enfin des cellules épithéliales dans 11 cas se rencontrant tous dans des proportions tout à fait insignifiantes. Huit malades souffraient de pollacisurie, 2 ou 3 fois pendant la nuit, les troubles étant tout de même assez légers et disparaissaient au cours des 3 ou 4 premiers jours. Aucun n'avait de signe de l'urétrite de manière que de l'urètre ait sorti des sécrétions anormales.

JÄRVINEN mentionne en dehors de cela que 5 de ses cas avaient eu des signes cliniques de la prostatite bien qu'il n'expose pas plus précisément de quelle nature ils étaient. Je n'ai pu décelé de signes de prostatite dans aucun de mes cas malgré mes recherches minutieuses et même répétées. Il en ressort que je ne peux pas tirer de mes cas la même conclusion que JÄRVINEN à savoir «qu'au point de vue pratique dans tous les cas non spécifiques se rencontrent les symptômes d'irritations de l'urètre et de la prostate».

Se basant sur ses examens microscopiques JÄRVINEN constate que dans un tiers de ses cas seulement la partie caudale de l'épididyme était enflammée tandis que la partie supérieure était sans symptômes ou seulement légèrement enflammée. Également dans le ductus deferens il avait rencontré partout, sauf dans un cas, des signes cliniques ou microscopiques de l'inflammation. Par conséquent JÄRVINEN conclut que l'urétrite et la prostatite sont les facteurs provocateurs de l'épididymite et que l'inflammation s'est propagée à l'épididyme le long du ductus deferens.

Les malades que j'ai examinés ont signalé eux-mêmes que la sensibilité et le gonflement avaient commencé dans la partie caudale de l'épididyme laquelle partie également à l'examen s'est montrée toujours la plus enflammée sauf dans 4 cas, où la sensibilité et le gonflement avaient commencé à l'autre extrémité. En dehors de cela 18 malades se sont plaints de douleurs dans la région de l'aine et on constatait à la palpation qu'elles provenaient du ductus deferens. Cette sensibilité disparaissait régulièrement au bout de quelques jours ou dans une semaine et toujours plus tôt que dans l'épididyme. Par surcroît selon ces malades qui avaient signalé la sensibilité dans la région de l'aine cette sensibilité s'était manifestée en général 1 ou 2 jours après les premiers signes de la sensibilité dans l'épididyme.

En cette occurence on pouvait aussi exposer quelques points de vue de la propagation de la tuberculose, qui, eux aussi, sont contradictoires. Quand la tuberculose se rencontre dans les autres organes comme dans la tuberculose rénale on en trouve aussi dans l'épididyme, dans les vésicules séminales ainsi que dans la prostate. Krogius mentionne que cela n'exige pas de rapport causal direct avec la tuberculose des voies génitales et urinaires comme on l'a supposé auparavant. Au contraire toutes les expériences antérieures portent à croire que la tuberculose rénale et la tuberculose de l'épididyme sont nées par voie hématogène, chacune indépendamment, car souvent chez un malade dont les reins et l'épididyme sont atteints de tuberculose la vessie et la prostate sont restées parfaitement saines. Ce point de vue me paraît probant. L'opinion de Järvinen selon laquelle l'épididymite non spécifique proviendrait de l'urétrite non spécifique et de la prostatite se propageant le long du ductus deferens à l'épididyme ne me paraît donc pas vraisemblable surtout à cause du fait que la propagation s'effectuerait alors à contre-sens. La même divergence des points de vue se rencontre également dans la littérature sur l'épididymite blennorragique, bien que plusieurs investigateurs (Ullman etc.) soient d'avis que la propagation s'effectue par voie sanguine et lymphatique du ductus deferens. Je me range à côté de ceux (Boshamer etc.) qui supposent que l'agent provocateur de l'inflammation est venu par voie hématogène dans l'épididyme d'où il se propage dans le sens de l'écoulement au ductus deferens. Les douleurs dans celui-ci peuvent partiellement provenir des réflexes spasmodiques causés par l'inflammation de l'épididyme.

Parmi les facteurs énoncés j'ai déja signalé le rôle prétendu du traumatisme dans la genèse de l'épididymite. Ce sont surtout les petites lésions fréquentes qui paraissent avoir une tendance à jouer un rôle plus significatif. Sont considérées comme telles les efforts physiques, le sport, même la danse et on prétent qu'ils causeraient de petites ruptures dans la membrane muqueuse de l'urètre dans lesquelles les bactéries siégeraient. Je n'ai rien trouvé dans mes cas qui soutienne ce genre d'hypothèse que je trouve assez spécieux. Tous mes cas se sont réncontrés pendant l'époque où l'activité sur nos fronts était assez faible, par conséquant les efforts physiques qu'on y exigeait des soldats n'étaient pas spécialement lourds. Quant à la danse elle était défendue pendant la guerre (clandestinement aussi on dansait bien peu). Alors cette possibilité peut également être exclue avec certitude. Je ne peux non plus révéler dans la matière que j'ai examinée des lésions causées par le sport, car aucun de mes malades n'était spécialement sportif par ex. aucun d'eux n'avait participé aux concours de ski effectués dans les unités. Tous mes cas ont été recueillis pendant l'hiver. Je suis d'avis que chez nous l'épididymite non spécifique se rencontre assez rarement parmi les hommes sportifs et qu'elle n'a été de nature épidémique dans aucun cas.

On a également accusé le défecteuses conditions hygiéniques sur les fronts. Toutefois les soldats avaient l'occasion de se baigner une ou deux fois par semaine. On changeait de sous-vêtements une fois par semaine. On doit pourtant admettre que le cantonnement où il y a peu d'espaces offre une occasion favorable à la propagation de l'infection.

En résumé de tout ce qu'on vient d'exposer je voudrais soutenir que cette épididymite aiguë non spécifique qui s'est rencontrée dans notre armée pendant notre récente guerre presque épidémiquement a été une maladie infectieuse. Elle n'a pas été provoquée par les bactéries ordinaires de pus, mais évidemment par quelque virus qu'on ne peut pas découvrir par les moyens d'investigation habituels. La maladie semble être facilement contagieuse. De quelle manière la maladie se propage-t-elle, est incertain. Il est possible qu'il s'agisse de l'infection par contact favorisée par le cantonnement. On ne sait pas par quelle voie le virus s'étend dans l'organisme car il ne provoque aucune réaction avant de s'installer dans l'épididyme. Le virus qui a une certaine prédilection pour l'épididyme y aboutit vraisemblablement par voie hématogène provoquant en règle générale d'abord l'inflammation

dans la partie caudale de l'épididyme où elle se localise ou bien s'étend dans la partie supérieure et dans le ductus deferens dans celui-ci en sens centripète, alors avec l'écoulement testifuge. Le virus n'est pas de nature à affecter les voies urinaires, bienqu'il puisse provoquer quelquefois des manifestations secondaires d'irritation de la vessie et de la partie postérieure de l'urètre.

Symptomatologie.

La symptomatologie de l'épididymite aiguë non spécifique est assez typique. Les manifestations commencent visiblement aiguës, bien qu'elles ne soient pas très fortes en règle générale. La température s'élève jusqu'à 37.5—38° à peu près, accompagnée parfois de légers frissons qui ne sont pourtant jamais très prononcés. Dans 3 cas seulement la température s'est élevée jusqu'à 39°. La température redevient normale dans 2—3 jours ou bien elle se tient subfébrile une huitaine de jours. Dès les débuts l'épididyme devient sensible à la palpation et gonfle simultanément. Le gonflement peut être très léger mais peut aussi atteindre les proportions d'un œuf de poule et se rencontre en général dans la partie caudale, laquelle partie paraît légèrement bosselée à la palpation. Parfois on rencontre aussi une légère hydrocèle qui disparaît tout de même au cours des premiers jours. La peau du scrotum du côté inflammé est légèrement rougeâtre. Une légère pollacisurie ne se rencontre que très rarement, parmi mes sujets seulement dans 8 cas, et disparaît au cours de 3—4 jours. Dans aucun de mes cas je n'ai rencontré d'écoulement de pus ou quelque autre sécrétion anormale de l'urètre.

Toutes les manifestations primaires mentionnées plus haut disparaissent assez rapidement sauf la sensibilité et le gonflement de l'épididyme. Celle-là disparaît assez vite, en général dans une ou deux semaines tandis que celui-ci persiste plus longtemps la durée en étant assez variable. Le plus souvent il disparaît totalement au cours de 6—8 semaines. Il est rare que le gonflement persiste 6 mois, encore plus rarement plus longtemps, auquel cas il y a lieu de soupçonner quelques complications.

Lempert, Dorn, et Flesch-Thebesius ont soutenu l'opinion qu'aussi bien dans les épididymites non spécifiques que dans les épididymites tuberculeuses on rencontre des formations fistuleuses sur la surface du scrotum. Je n'ai trouvé de fistule parmi aucun de mes cas.

En ce qui concerne la réaction de sédimentation JÄRVINEN signale qu'elle a été toujours normale chez ses malades ou bien très peu élevée. Les matériaux que j'ai examinés m'ont donné des résultats tout à fait contraires comme le tableau plus haut nous a révélé. Cela provient évidemment du fait que les cas de JÄRVINEN étaient plus avancés. Dans la phase primitive de la maladie la réaction n'était normale chez aucun étant en règle générale entre 10 et 30 mm après une heure s'approchant le plus ordinairement de 20 mm. A la disparition des autres symptômes la réaction de sédimentation s'est baissée régulièrement assez vite redevenant normale au bout de deux ou trois semaines.

D'après quelques savants (FLESCH-THEBESIUS etc.) la tendance à la récidive serait un caractéristique de l'épididymite. De mes malades deux seulement se sont présentés au contrôle à peu près au bout d'une semaine à cause du léger gonflement et de la sensibilité du même épididyme par suite d'une longue marche à laquelle ils avaient participé tout de suite après être sortis de l'hôpital. Les symptômes disparaissaient au cours d'un repos de deux semaines, il n'y eut pas de récidive depuis. Je suis donc de l'avis contraire: l'épididymite aiguë non spécifique n'a pas de tendance à la récidive.

Dans deux cas seulement elle s'est rencontrée simultanément dans chaque épididyme. Les investigations ne révèlent pas pourquoi elle ne se rencontre en général qu'unilatéralement.

Aucun complication ne s'est manifestée parmi mes cas.

On a prétendu (CAMBELL) que l'épididymite bilatérale amenerait comme complication tardive la stérilité qui serait alors le résultat, comme celui de l'épididymite blennorragique de l'obturation de ces canaux qui se terminent à la papille située dans la partie caudale de l'épididyme, au point de départ du canal spermatique. En effet, il en est souvent ainsi dans les épididymites bilatérales blennorragiques. Moi aussi j'ai eu l'occasion de la constater après l'examen du sperme et du liquide du testicule par ponction sur une trentaine de malades qui sont restés sans enfants. Serait ce le cas aussi dans les épididymites non spécifiques il est impossible de le savoir, car personne, à ce que je sais, ne l'a encore examiné à fond. Les modifications inflammatoires qui se trouvent dans l'image microscopique de l'épididymite non spécifique ne prouvent rien quant à l'obturation permanente des canaux (bien que JÄRVINEN le suppose) ces altérations étant évidemment très rever-

sibles, car les symptômes cliniques également disparaissent en règle générale rapidement.

Le diagnostic différentiel.

En traitant l'épididymite non spécifique il faut prendre en considération la syphilis, la blennorragie et la tuberculose en ce qui concerne le diagnostic différentiel.

Les données anamnestiques ne sont pas sans importance bien-qu'elle ne soient pas décisives, car en dehors des maladies qu'on vient de mentionner une infection secondaire banale affectant l'épididyme, ou une épididymite non spécifique comme une maladie toute différente, peuvent survenir.

La syphilis comme déjà mentionné, se rencontre dans l'épididyme si rarement que nous pouvons l'exclure pratiquement, surtout si les réactions Wassermann et Kahn ont été négatives.

L'épididymite blennorragique a un début en général plus aigu, ses manifestations sont assez fortes, la température plus élevée, la fièvre est suivie de frissons et l'épididyme est si sensible «qu'il fait mal même à le regarder». L'épais écoulement de pus de l'urètre, la constatation des gonocoques et la réaction de fixation de complément apportent des éclaircissements à la question, bien que les gonocoques disparaissent pendant la phase de fièvre. Toutefois les manifestations peuvent être aussi plus légères selon le type et la virulence du gonocoque et alors l'établissement du diagnostic différentiel peut amener des difficultés.

C'est toutefois la tuberculose qui nous donne le plus de mal. Bien que la tuberculose dans l'épididyme commence «doucement» elle peut aussi avoir un début aigu et ressemble alors à l'épididymite non spécifique de telle façon qu'on ne peut pas, se basant sur les symptômes cliniques, la distinguer dans sa phase primitive.

La palpation non plus ne nous donne de certitude. Quelques chercheurs (Demel) ont émis l'hypothèse que l'épididyme tuberculeux est plus induré, sa surface est plus bosselé, les bosses étant en relief, que dans les cas non spécifiques. Les types de transition sont tout de même si variés que ce serait pure fantaisie de s'y attacher de l'importance. Dans les débuts l'épididymite tuberculeuse diffère de l'epididymite non spécifique seulement en ce que celle-là se rencontre plus souvent bilatéralement que l'épididymite non spécifique et que le type tuberculeux souvent produit des fistules dans la surface du scrotum tandis que dans les



Fig. 1.

AULIS KORHONEN: Sur les Epididymites aiguës non specifiques.

épididymites non spécifiques il n'y en a pas ou bien très rarement. Parmi mes cas je n'en ai pas trouvé une seule fois.

Il y a des divergences d'opinion quant à savoir si la présence des modifications inflammatoires de la prostate est typique de cette maladie ou non. Selon la majorité la présence de la prostatite semble annoncer la tuberculose. Dans la matière traitée par JÄRVINEN 5 cas épididymites non spécifiques se sont présentés où il a rencontré des modifications dans la prostate ce qui lui paraît tout naturel. Cela ne nous étonne pas si nous nous souvenons de sa conception de la pathogénie, c'est-à-dire que l'infection descend le long des voies urinaires. Je n'ai trouvé dans aucun de mes cas de signes de prostatite malgré mes soigneuses recherches renouvelées ce qui me paraît plus naturel d'ailleurs, car selon moi l'épididymite non spécifique n'est pas provoquée par l'infection par voies urinaires, mais provient d'autre part de l'organisme et par voie hématogène.

Les examens de l'urine ne nous donnent pas d'indications sûres car dans toutes les épididymites on peut ou non rencontrer dans l'urine des modifications inflammatoires. JÄRVINEN signale avoir rencontré des globules blancs dans tous ses cas excepté dans 4, mais nullepart des bactéries. Il suppose que cette pyurie aseptique provient évidemment de l'urétrite postérieure. Sur mes sujets il y avait des globules blancs dans 21 cas, des globules rouges dans 12 et enfin des cellules épithéliales dans 11 cas, toutefois dans des proportions tout à fait insignifiantes. On n'a rencontré de bactéries dans aucun cas. Je suis d'avis que la scareité des globules dans l'urine ne provient sûrement pas de l'urétrite postérieure, car je n'ai découvert aucun signe de l'urétrite, mais ce seraient les facteurs toxiques et l'irritation provoquée par l'infection générale ainsi que par l'épididymite locale qui en sont cause.

Le traitement.

Cette épididymite aiguë non spécifique, qui s'est rencontrée dans l'armée assez fréquemment pendant notre récente guerre, parfois presque épidémiquement et qui n'était pas provoquée par les bactéries ordinaires du pus, mais causée selon toutes les apparences par quelque virus et qui avait une certaine prédilection pour l'épididyme, était par sa nature une maladie locale. Quant à son agent provocateur et sa nature elle est à mon avis comparable à une autre maladie épidémique qui s'est recontrée simul-

tanément, c'est-à-dire l'hépatite aiguë. C'est évidemment le virus qui a provoqué ces deux maladies, bien que leur affinité soit différente. Le pronostic de toutes les deux est bon.

Il n'avait pas de tendance à se propager et ne provoquait pas de foyers d'inflammation ailleurs ni de complications locales. Comme les symptômes paraissaient s'apaiser spontanément au cours des premiers jours, il semblait plus naturel, au moins au commencement, de se contenter du traitement conservateur. On mettait le malade au lit, on plaçait un suspensoir sous le scrotum ainsi qu'une compresse, plus tard quand la fièvre s'était abaissée, des applications chaudes. En dehors de cela on donnait au malade pendant la phase de fièvre du sulfathiazole 0.5 gr trois fois par jour. Tous les malades soumis à mes soins immédiatement sans qu'on les aient transportés dans quelque véhicule cahotant, ont guéri par ces simples moyens. La durée de traitement était de 4 à 6 semaines l'intervention chirurgicale n'ayant été nécessaires dans aucun cas.

La plupart des chercheurs se rangent au côté du traitement conservateur (Boshamer etc.).

Bien que tous mes cas aient guéri favorablement par les moyens conservateurs il est tout de même possible que l'état de quelques-uns de ces malades qui ne peuvent pas être soignés dès les débuts de la maladie étant transportés d'un endroit à l'autre dans les véhicules, s'aggrave de telle façon, que le traitement conservateur qu'il faut toujours, à mon avis, essayer d'abord, n'a pas été efficace. Il s'est formé alors dans l'épididyme des nécroses tissulaires et des abcès, l'épididyme tout entier étant gonflé de telle sorte que l'épididymectomie peut être indiquée. De toute manière le pourcentage de tels cas est assez peu élevé.

Le choix des méthodes de traitement est plus difficile dans les cas, où nous ne pouvons pas nous rendre compte, ce qui arrive surtout dans les cas sporadiques, s'il s'agit d'une épididymite non spécifique ou tuberculeuse. Même dans ce cas il y a lieu de suivre un traitement conservateur en surveillant l'évolution du processus car la tuberculose dans l'épididyme progresse lentement. Ainsi un délai dans les début de la maladie ne cause aucun inconvénient au contraire on peut consacrer ce temps de délai à l'amélioration de l'état général du malade. La durée d'attente dépendra naturellement de l'évolution des symptômes généraux et locaux. S'il ne survient pas de symptômes alarmants tels que la fièvre continue, les fistules ou une altération de l'état général, je proposerais

une attente de six mois au moins, après quoi l'épididymectomie peut être indiquée. En procédant ainsi nous évitons une quantité d'ectomies si nuisibles au malade.

Quant à l'opinion de JÄRVINEN que «bei allen unspezifisch aussehenden Nebenhodenentzündungen die Epididymectomie nach ganz denselben Prinzipen auszuführen, wie wenn sie tuberkulöse Epididymitiden wären», je suis catégoriquement d'un autre avis.

Encore faut-il tenir compte du fait que l'épididymectomie est une opération mutilante de sorte qu'on ne doit pas l'effectuer à la légère. En dehors de cela il n'est point rare qu'une telle mutilation chez les individus plus sensibles puisse causer des complexes d'infériorité qui de leur côté peuvent amener une névrose sexuelle ou un état de dépression comme je l'ai pu constater pendant cette querre chez quelques-uns de ceux qui ont subi l'épididymectomie.

J'ai opéré moi-même 4 cas soignés auparavant par d'autres médecins et qui ne sont tout de même pas inclus dans la matière que j'ai traitée pour cette raison. Tous mes cas avaient été considérés auparavant commes des épididymites non spécifiques mais parce que le gonflement et la sensibilité avaient persisté déjà 6—7 mois j'ai supposé qu'il y avait dans l'épididyme des abcès ou une tuberculose. Je dois ajouter, il est vrai, que ces malades avaient été debout tout le temps. Pourtant chez aucun d'eux on ne pouvait constater de tuberculose ou des abcès à l'examen anatomo-pathologique. Dans le tissu interstitiel il n'y avait que de cellules inflammatoires typiques. Je cite ici la déclaration du professeur Uotila sur ces cas: «Dans le spécimen on voit du tissu de l'épididyme d'aspect normal contenant dans la cavité de la glande une quantité considérable de spermatozoïdes. Malgré le fait qu'on a pris des découpures en plusieurs plans on ne trouve dans la préparation d'autre pathologique que quelques lymphocytes et quelques plasmocytes par-ci et par-la dans le tissu interstitiel. On n'a rien putrouver qui annonçât la tuberculose.» (Voir l'image.)

Bien que le temps d'attente ait été long on aurait donc pu dans ces cas attendre encore plus longtemps.

Conclusion.

Cette épididymite aiguë non spécifique qui s'est rencontrée pendant notre récente guerre dans l'armée presque épidémique-

ment, était une maladie infectieuse contractée surtout par de jeunes soldats de 20 à 30 ans. Les mariés et les non-mariés contractaient la maladie presque dans les mêmes proportions (c'est-à-dire 44 % et 55 %). La maladie a commencé par une considérable élévation de température qui disparaissait tout de même au bout d'une semaine. La sensibilité et le gonflement de l'épididyme commençaient presque toujours dans la partie caudale dans 65 % des cas au cours de la journée. Les mouvements et les efforts des malades ont donc pu concourir à la maladie. Elle s'est rencontrée unilatéralement dans 95 % des cas, le nombre des cas du côté droit ayant été à peu près le même que le nombre de ceux du côté gauche. Il y avait une légère pollacisurie dans 20 % des cas dans les débuts de la maladie et qui disparaissait au bout des premiers 3—4 jours. Dans 80 % des cas on a rencontré dans l'urine pendant les premiers jours des granulocytes ainsi que des cellules épithéliales dans des proportions peu élevées. La réaction de sédimentation s'était élevée toujours au commencement jusqu'à 20—30 mm environ au cours d'une heure redevenant normale au bout de deux ou trois semaines. Il n'y avait pas de sécrétion anormale de l'urètre ni jamais de manifestations du côté de la prostate. On n'a pas trouvé de bactérie dans l'urine ni de bacilles tuberculeux ni de gonocoques. Les réactions Wassermann et Kahn étaient négatives. Seulement dans 5 % des cas une légère récidive s'est manifestée par suite d'une longue marche à laquelle ils avaient participé tout de suite après la sortie de l'hôpital. Le traitement était dans tous les cas conservateur: le malade gardait le lit, le scrotum soutenu par le suspensoir, on donnait du sulfathiazole 0.5 gr trois fois par jour pendant la phase de fièvre, d'abord les compresses ensuite des applications chaudes. La durée moyenne de traitement était environ 4—6 semaines mais on surveillait les malades encore de 1—6 mois après leur sortie de l'hôpital. La maladie n'est pas provoquée par des bactéries ordinaires de pus, qui peuvent se rencontrer secondairement dans les cas restés chroniques, mais évidemment par quelque virus, qu'on n'a pas pu découvrir par les moyens d'investigations habituels. La maladie paraît être très contagieuse. On ne peut pas dire avec certitude de quelle manière la maladie se propage d'une personne à l'autre, probablement il s'agit d'une infection par contact à laquelle le cantonnement où il y a peu d'espace est favorable. On ne sait non plus par quelles voies le virus s'achemine dans l'organisme, car il ne provoque aucun signe avant d'aboutir

à l'épididyme. Quant à son agent provocateur, à sa nature et à son pronostic la maladie est bien comparable à une autre maladie presque épidémique rencontrée simultanément c'est-à-dire l'hépatite aiguë bien que ce virus ait une certaine prédilection pour l'épididyme. Il est évident que le virus aboutit à l'épididyme par voie hématogène causant le plus souvent une inflammation dans la partie caudale où il se localise ou bien il se propage de là dans la partie supérieure ainsi que dans le ductus deferens, dans celui-ci en sens centripète alors avec l'écoulement qui s'effectue en sens testifuge. Le virus n'est pas de nature à affecter les voies urinaires, bien qu'il puisse provoquer parfois des manifestations secondaires dans la vessie et dans la partie postérieure de l'urètre. La maladie n'a pas de tendance à se propager, elle ne provoque pas de foyers d'inflammations ailleurs ni complications comme par ex. des fistules. Les manifestations s'apaisent, si le malade est soumis au traitement immédiatement, déjà au cours des premiers jours et la sensibilité dans l'épididyme au cours d'une ou deux semaines. Le gonflement disparaît plus lentement, parfois persistant de 6 à 8 semaines en moyenne, parfois encore plus longtemps. La durée moyenne du traitement est de 4 à 6 semaines. Le pronostic est bon. Je ne sais pas si comme complication tardive l'épididyme, qui a été atteint, reste stérile, car cette question n'a pas encore été élucidée quoique ce ne soit pas impossible. L'opération, l'épididymectomie, est contre-indiquée outre les cas où par manque de premiers soins ou peut-être pour quelques autre raison la maladie devient chronique formant des nécroses tissulaires. Je soutiendrais une attente de six mois environ. L'épididymectomie est une opération mutilante qu'on ne doit pas effectuer sans des indications bien motivées, de toute façon pas avec les mêmes indications que dans l'épididymite tuberculeuse. Si on le fait néanmoins, la chirurgie fait fausse route. L'opération a pour effet la stérilité de l'épididyme opéré. La stérilité et la mutilation peuvent provoquer à des individus qui ont un système nerveux plus sensible que d'ordinaire, une complexe d'infériorité qui peut de son côté amener des névroses sexuelles et des états de dépression.

Résumé.

La matière examinée comprend 40 cas d'épididymites aiguës non spécifiques. Ce sont surtout les sujets de 20 à 30 ans qui la contractent. En règle générale elle ne se rencontre qu'unilatérale-

ment, dans la partie caudale. Ses symptômes sont: en dehors du gonflement et de la sensibilité, une élévation sensible de la température (qui disparaît à peu près dans une semaine) ainsi que l'élévation de la réaction de sédimentation de 20—30 mm (qui redevient normale au bout de 2—3 semaines). Une légère pollacisurie ne se rencontre que rarement. Il n'y a pas de sécrétions pathologiques de l'urètre, la prostate est également sans symptômes. On ne rencontre jamais de bactéries dans l'urine. Le traitement est conservateur: le malade garde le lit, le suspensoir sous le scrotum, du sulfathiazole 0.5 gr par jour pendant la phase de fièvre, d'abord une compresse, ensuite des applications chaudes. La durée moyenne du traitement est de 4 à 6 semaines. La sensibilité de l'épididyme disparaît dans 1—2 semaines, le gonflement persiste 6—8 semaines, même plus longtemps quelquefois. Le pronostic est bon. Il n'y a de récidive que très rarement. La maladie est contagieuse. Elle n'est pas provoquée par des bactéries ordinaires de pus, mais évidemment par quelques virus dont on ne connaît pas avec certitude la propagation d'une personne à l'autre. Il est probable qu'il s'agit de l'infection par contact dans les lieux trop peuplés comme par ex. dans le cantonnement des soldats. L'agent provocateur de la maladie s'étend évidemment par voie hématogène à l'épididyme sans affecter les voies urinaires. De l'épididyme il peut se propager au ductus deferens avec écoulement testifuge. La maladie n'a pas de tendance à se propager et ne provoque pas de complications comme fistules. La maladie est par sa nature, par son agent provocateur et par son pronostic comparable à une autre maladie, l'hépatite aiguë, qui s'est rencontrée simultanément presque d'une manière épidémique, bien que le virus de l'épididymite ait une prédilection spéciale pour l'épididyme. Les symptômes de la maladies s'apaisent assez vite si les malades sont soumis immédiatement au traitement, sinon la maladie peut être de longue durée. Le traitement opératoire, l'epididymectomie est contre-indiqué sauf dans les cas où par négligence des premiers soins ou pour d'autre raisons la maladie devient chronique. Au minimum un délai de six mois est souhaitable. L'épididymectomie est une opération mutilante à laquelle on ne doit pas avoir recours sans indications bien motivées, en tous cas pas avec les mêmes indications que dans les épididymites tuberculeuses. En faisant ainsi la chirurgie fait fausse route.

Summary.

The material comprises 40 cases of acute aspecific epididymitis. This illness is contracted chiefly by young persons, viz. from 20 to 30 years of age. It generally appears unilaterally only in the caudal part. To the symptoms of this illness belongs, besides swelling and tenderness, moderate increase in temperature, which disappears in about one week and a rise of 20—30 mm in the red-cell sedimentation value, which turns normal in the course of two to three weeks. Slight strangury troubles are but seldom met with, no pathologic secretion appears in the urethra and no symptoms from the prostata either. Bacteria are never found in the urine. Conservative treatment is taken recourse to, viz. rest in bed, suspensorium, 0.5 gram sulphatiazol three times per diem during the fever period, compresses to begin with, thereupon heat. The average time of treatment comprises four to six weeks. The tenderness of the epididymis disappears in the course of one to two weeks, but it remains swollen from six to eight weeks, sometimes for a still longer time. The prognosis is favourable, recurrences are very rare. The illness is contagious. It is not caused by any ordinary pus-bacteria, but obviously by some virus, whose manner of spreading from one person to another is not known with any amount of certainty. In overcrowded places, *e. g.* in underground shelters for soldiers contact-infection probably plays the most important rôle. The virus wanders into the epididymis along the haematogenic way, without affecting the urinary passages. It may be spread from the epididymis to ductus deferens with the stream of fluid running in the testifugal direction. This disease does not show any predisposition towards spreading, neither does it evoke complications, as *e. g.* fistulae. According to its origination and prognosis the illness in question is chiefly of the same nature as acute hepatitis, which appeared simultaneously and was also epidemic, even though the virus of the former has a particular affinity for the epididymis. The disease symptoms subside fairly soon, if the patients are able to come immediately under treatment, but otherwise some of them may be of longer duration. Contraindication for operative treatment, epididymectomy, is at hand, except in such cases where the disease turns chronic owing to neglected initial treatment or some other reasons. This may be expected to occur after about half a year at least. Epididymectomy is a mutilating operation, which must not

be taken recourse to without strong indications, and not by any means when the indication is the same as in tuberculous epididymitis. If that is done, we are going astray in surgery.

Zusammenfassung.

Das untersuchte Material umfasst 40 Fälle von akuter, unspezifischer Epididymitis. Es werden besonders Männer im Alter von 20—30 Jahren befallen. Im allgemeinen findet man die Krankheit nur einseitig und in der kaudalen Partie. Die Symptome sind: ausser der Schwellung und der Empfindlichkeit auch eine merkbare Temperatursteigerung (die in einer Woche fast ganz verschwindet) sowie eine Erhöhung der Blutsenkungsgeschwindigkeit auf 20—30 mm (die nach 2—3 Wochen wieder auf Normalwerte sinkt). Nur selten findet man eine leichte Pollakisurie. In der Harnröhre liegt keine abnorme Sekretion vor, und auch die Prostata zeigt keine Symptome. Niemals findet man Bakterien im Harn. Die Behandlung ist konservativ: Bettlage, Suspensorium, Sulfathiazol 0.5 g täglich während der Fieberperiode, zuerst Kompressen, später heisse Umschläge. Die Behandlung dauert durchschnittlich 4—6 Wochen. Die Empfindlichkeit der Epididymis verschwindet nach 1—2 Wochen. Die Schwellung bleibt 6—8 Wochen lang, manchmal sogar länger, bestehen. Die Prognose ist gut. Nur sehr selten kommen Rückfälle vor. Die Krankheit ist ansteckend. Sie wird nicht durch gewöhnliche Eiterbakterien hervorgerufen, sondern offenbar durch irgendein Virus, dessen Verbreitungsweg von Mensch zu Mensch nicht sicher bekannt ist. Wahrscheinlich handelt es sich um Kontaktinfektion in übervölkerten Wohnstätten, wie z. B. in Soldatenbaracken. Der Krankheitserreger verbreitet sich offenbar auf dem Blutwege und erreicht die Epididymis, ohne die Harnwege anzugreifen. Von der Epididymis aus kann er sich mit dem Samenstrom in das Vas deferens verbreiten. Die Krankheit zeigt keine Neigung zur weiteren Verbreitung und gibt keine Komplikationen, wie Fisteln. Insbezug auf ihre Natur, ihren Erreger und ihre Prognose erinnert die Krankheit an eine andere: die akute Hepatitis, die gleichzeitig in fast epidemischer Weise vorgekommen ist, obgleich das Virus der Epididymitis eine besondere Vorliebe für die Epididymis zeigt. Falls die Kranken sofort in Behandlung kommen, klingen die Krankheitssymptome recht schnell ab, andernfalls kann die Krankheit langwierig werden. Chirurgi-

sche Behandlung, also Epididymektomie, ist kontraindiziert, ausser in Fällen, wo die Krankheit durch Vernachlässigung der ersten Behandlung oder aus anderen Gründen chronisch geworden ist. Mindestens sechs Monate langes Zuwarten ist wünschenswert. Die Epididymektomie stellt einen verstümmelnden Eingriff dar, zu dem man nicht ohne schwerwiegende Indikationen greifen soll, jedenfalls nicht auf die gleichen Indikationen hin wie bei tuberkulöser Epididymitis. Hierdurch würde die Chirurgie auf Abwege geraten.

Bibliographie.

AKUTSU: Frey. — ANSCHÜTZ: Lempert. — BOSHAMER: Lehrbuch der Urologie. Gustav Fischer, Jena 1939. — BURMEISTER u. CAHN: Münch. med. Wschr. 1926: 1481. — CAMPBELL: Amer. med. Sci. 1928: 176: 386. — DEMEL: Järvinen. — DIETEL: Z. Ur. 1924: 18: 326. — DORN: Beitr. klin. Chir. 1920: Vol. LXXXIII: 307. — FLESCH-THEBESIUS: Bruns Beitr. 1921: 123: 633. — FREY: Dtsch. Z. Chir.: 1929: 218: 333. — JÄRVINEN: Acta chir. scand. 1944: Vol. XC. Suppl. 90. — KAPPIS: Dtsch. med. Wschr. 1919: 540. — KROGIUS: Urinvägarnas kirurgiska sjukdomar. Mercator, Helsingfors, 1923. — LEMPERT: Dtsch. Z. Chir. 1932: 235: 414. — Ljungren: Acta chir. scand. 1939: Vol. LXXXIII: 307. — LOMMEL: Z. ur. Chir. 1914/15: 214. — OPPENHEIM u. Löw: Virchows Arch. 1905: 182: 39. — PUHL: Zbl. Chir. 1930: 922 — REINECKE: Dtsch. Z. Chir. 1923: 180: 130. — SCHÄFFER: Med. Klin. 1921: 335. — SEIFERT: Zbl. Chir. 1930: 13 u. 46. — SIMMONDS: Virchows Arch. 1914: 216: 45. — STEVENS: J. Ur. 1923: 10: 85. — SÖDERLUND: Acta chir. scand. 1923: Vol. LV: 513. — WEHNER: Lichtenberg, Voelker, Wildbolz: Handbuch der Urologie. Bd. V. Julius Springer, Berlin, 1928. — WILDBOLZ: Z. ur. Chir. 1929: 28: 468. — ULLMAN: Riecke. Lehrbuch der Haut- und Geschlechtskrankheiten. Gustav Fischer, Jena 1923.

From the Deaconess Hospital in Helsingfors.
(Prof. F. LANGENSKIÖLD.)

Gustatory Local Hyperhidrosis Following Injuries in the Parotid Region.

By

A. LANGENSKIÖLD.

Gustatory local hyperhidrosis of the face is a rare phenomenon and interesting as a pathophysiological occurrence. In the two cases which have induced this paper, the patients have, after suppurating processes in the parotid region, been troubled by rich transpiration within a limited skin area in the face when eating.

Case 1. P. C. A doctor's wife from Helsingfors. Born in 1892. Examined ambulantly in the spring 1945.

Anamnesis: Admission the 21st of August 1936 in the Konkordia Hospital in Helsingfors, diagnosis *Cholelithiasis.* Aug. 25th 1936 *Cholecystectomy.* Complication: *Suppurating parotitis* on the left side. Aug. 31st: *Incisio.* Then fever during two weeks. The suppuration still continued during a couple of weeks. No signs of facial paralysis of any degree. When the patient ceased wearing a bandage, she observed that when beginning to eat, she felt in her left cheek a burning heat. A few minutes after the beginning of the meal the left cheek and temple were wet with sweat. During the meals the secretion generally was so abundant that it ran down her cheeks. The symptoms have remained almost unchanged since then, thus over 8 years.

The patient has noticed that the symptoms are more marked when she eats something acid. Spicy and delicate food causes a stronger reaction than a tasteless one. Mastication only does not produce the phenomenon. When the patient is exposed to strong heat, and perspires richly in other parts of the body, the affected left cheek clearly remains less moist than the sound right cheek.

The patient is troubled by the perspiration at meals and it is particularly disturbing in social life. Since the time following the acute illness, the patient is also troubled by an almost constant singing in her left ear. This does not vary in connection with meals. The patient

has for a long time been rather stout, and has been treated for heart insufficiency. Otherwise no earlier illnesses with neurological symptoms.

Status praesens: Patient is rather corpulent. Slightly anaemic. The general condition otherwise satisfactory. In the left parotid region an incision scar, about 5 cm long, somewhat contracted, beginning between the lobe of the ear and the mastoid processus reaching down behind the mandibular angle. The right parotid region is considerably more plump than the left one. The face is otherwise symmetric, no signs of facial paralysis. The pupils are of the same size, round, reacting to light.

The patient provokes her symptoms by means of eating pickled mushrooms. Within one minute after the first mouthful, a distinct redness appears on the left cheek and temple. After a couple of minutes small drops of perspiration appear in the pores of the said region and in the scalp in the left temporal region. The drops grow and conjoin, and, after a while, run down the cheek. A close examination showed that the region in which the redness and perspiration appears, rather closely corresponds to the area innervated by the auriculotemporal nerve. After the meal the perspiration ceases, the redness remains and diminishes gradually within about 15 minutes. There is evident hyperalgesia and hyperesthesia in the whole region of the auriculotemporal nerve. The limits of the hyperesthesia are difficult to establish, but, on the whole, they seem to coincide with those of the hyperhidrotic area.

In order to contribute to the investigation of the much discussed pathogenesis of this syndrome, it was important, as will appear from the following, to establish the existence of a peripheral sensitization to acetylcholine within the hyperhidrotic area. A test with an intracutaneous injection of acetylcholine was made in the following way:

For a quantitative estimation of the transpiration caused by the injection Minor's iodine method was used (List & Peet). The skin was coated with a solution of iodine and powdered with starch (which turns black by perspiration). With a fine needle 0.1 cc of 1 : 1,000 solution of acetylcholine chloride was injected symmetrically intracutaneously in both temporal regions. The test gave the following result: Within a minute a somewhat diffusedly limited redness appeared on both sides within an area of 2 to 3 cm in diameter. No black colour could be seen on the right side. On the left side, however, there were after about one minute within an area of about 1 cm in diameter around the place of the injection some 40 distinct black spots to be seen. These conjoined after 3 minutes in the furrows of the skin. Another test without iodine did not show any visible perspiration on the right side. On the left side drops of perspiration were distinctly noticed on and around the place of injection. Also this test produced redness of equal size on both sides.

Case 2. L. T. Farmer from Pälkäne. Born in 1891. Admission in the surgical department of the Deaconess Hospital in Helsingfors the 6th

of May 1924. Diagnosis: *Hyperhidrosis region. submaxillaris l. dx. Asymmetria oris.*

Anamnesis: At the age of 16 the patient was operated for tubercular cervical lymphatic glands on both sides. After the operation he had, during some months, a fistula on the right side, running with mattery secretion. Otherwise generally of good health. About two years after the operation, the patient noticed that the skin around the right operation scar was covered by a transparent fluid matter when he smoked, and particularly when he was eating. In the beginning this area covered the whole of the right mandible up to and in front of the ear, but gradually the perspiration diminished, remaining intensive within a small area on the chin. Acid or salty food caused a more intensive secretion than other food. The patient thinks he has noticed that the secretion is less when eating outdoors in cold weather. He generally perspires easily. When perspiring because of hot weather or exertion, the perspiration was equally strong on both sides.

Status praesens: General condition good. On the right side of the throat a scar, beginning some two cm below the lobe of the ear, running towards the hyoid bone a little over the middle line. On the left side a similar scar some centimetres lower down on the throat. On the middle line between the chin and the hyoid bone several scars about $^1/_2 \times 1$ cm in size. When laughing or grimacing the right corner of the mouth does not move as easily as the left one.

When the patient eats herring, numerous small limpid drops appear on a limited area of the size of about 2×3 cm under the chin to the right of the middle line. An examination of this liquor does not show any rhodanic alkalis.

May 7th, 1924. *Excisio cutis region. submaxillaris l. dx. Neurotomia rami marginal. mandib. n. facialis l. sin.* The patient is given a piece of bread to eat, with a stick of lunar caustic the distinct limits of the perspiration area are drawn up whereupon this area is excised. — May 12th, the wounds are healed by first intention. There is no perspiration caused by eating. When the patient laughs, his mouth is symmetrical.

Renewed examination, Aug. 24th, 1945. The patient has been, on the whole, well since 1924. He is, however, troubled by a growing deafness which is already quite far advanced. The hearing of the right ear is somewhat better. The patient states that before the operation in 1924 he had continually to wipe the right side of his face during meals. After the operation the condition improved considerably, but the skin in front of the ear and along the right mandible still perspired to a certain degree when the patient ate something acid. The symptoms diminished, however, gradually, and lately this complaint has not caught the patient's attention. Yet he has noticed a certain moisture appearing on the left cheek when eating something acid. He has never had any other subjective symptoms in the cheek except transpiration. Yet a certain redness used to appear. When asked to show the area which used to perspire, the patient marked an area corresponding to that innervated by the auriculotemporal nerve reaching up to the scalp before the ear. *Objective examination:* When the patient has eaten

a sour apple, the skin before the right ear and along the mandible feels somewhat moister than the left cheek. There is no hyperemia, neither can drops of perspiration be observed. Smearing of the posterior part of the tongue with diluted acetic acid causes a rich flow of saliva from both parotid ducts, nor does this test, however, cause perspiration on the cheek. In the region innervated by the auriculotemporal nerve a clear hypersensibility to all qualities can be observed on the right side. The pupils are small, equal in size, round, reacting to light.

Occurrence, Etiology and Symptoms.

The onesided local hyperhidrosis of the face provoked by gustatory stimulation was already described by BAILLARGER in 1853. Since then some 90 cases have been described in the world literature. In over 60 of these cases the syndrome has appeared after suppurating, mostly incised parotitis (PAYNE, HIGIER, ANDRÉ-THOMAS, FRIDBERG, VAUGHAN, TRIOUMPHOFF, SOSON-JAROSEVIČ, NOICA & BAGDASAR, POKROFFSKY, ROYER, LEMAITRE & BAUDOUIN, DOBROTWORSKY, SCHIPIZYN, JARIN). The syndrome seems to be much more frequent in Russia than elsewhere because suppurating parotitis was very common during the epidemic of exanthematic fever in 1919—1921. A Russian author (TRIOUMPHOFF) thus observed 14 cases, while most of the other reports comprise one or a few cases only.

The syndrome has been observed, besides after suppurating parotitis also after an exstirpation of tumors of the parotid gland (NEEDLES, LIST & PEET), after suppurating lymphadenitis in the parotid region (RAYMOND, LIPSZTAT, THYGESEN), after traumatic lesions in the said region with secondary suppuration (FREY, NEW & BOZER, GUTTMANN & LIST 1928). It is important for the establishment of the pathogenesis of this syndrome that it may appear also as a result on injuries and illnesses which are not directly localized to the parotid region. It has thus been observed after cervical sympathectomy (LIST & PEET, GUTTMANN 1931), after injuries on the cervical sympathetic (LIST & PEET), in connection with cervical ribs (SCHNEIDER), with encephalitis after influenza (VAMOS), and with syringomyelia (KAMINSKY, GUTTMANN 1928).

Gustatory hyperhidrosis in the face is caused, in most cases, by a parotitis, and limited to the innervation area of the auriculotemporal nerve (from the third branch of the trigeminal nerve) or part of it. By this reason the complaint has been given the name of "*auriculotemporal syndrome*" (FREY). This term is,

however, so far incorrect as the hyperhidrosis in some cases comprises also regions of the skin innervated by the cervical plexus: Mostly the innervation area of the greater auricular nerve, sometimes also the lesser occipital nerve, the supraclavicular nerves and n. cutaneus colli. In addition hereto regions supplied by other branches of the trigeminal nerve may show the syndrome. On the other hand, the area innervated by the auriculotemporal nerve may show quite normal conditions while adjacent regions have the syndrome. When this has occurred after a sympathectomy or in central affections, the whole left part of the face has generally been affected.

It is typical for the development of the condition that the patient cannot state the exact time for the beginning of the symptoms. They appear, however, generally some weeks up to some months after the acute stage of the parotitis or the traumatic lesion respectively.

The symptoms are very characteristic and are similarly described by most authors. Immediately or within some minutes after the patient has begun eating, hyperemia appears within an area of the skin of the face, or the face and the neck, this area being constant in each different case. Immediately after the vasodilatation perspiration appears within the same area and this perspiration is mostly very embarrassing. Acid food always provokes the symptoms most strongly, in some cases they appear only when the patient has taken acid food. They also appear more distinctly when the food is tasty or heavily seasoned than when the opposite is the case. Mastication of inedible matters or mechanical stimulation of the oral mucosa does not generally provoke the symptoms. The actual gustatory stimulation is thus important for the provocation of the phenomenon. Several authors have tried to stimulate different parts of the oral mucosa with vinegar. It appeared that the symptoms were most obvious by stimulation of the posterior third part of the tongue which is, as we know, innervated by the glossopharyngeal nerve. All these facts correspond with the observation of TRIOUMPHOFF that the occurrence of hyperhidrosis and hyperemia respectively depends on if and to which degree the stimulation in question starts the secretion of the parotid gland. In one case only the phenomenon has been connected with the function of the submaxillary gland (UPRUS, GAYLOR & CARDMICHAEL). The etiology was here an injury of nervus cutaneus colli. Injection of procaine in the

lingual nerve counteracted temporarily the symptoms. That the syndrome is connected with the centrifugal pathways running to the salivary glands is also manifested by the fact that it can in some cases be released as a conditional reflex at the sight of delicate food.

Information about the function of the parotid gland in cases which show the syndrome, is comparatively rare. The gland seems often to be very atrophic, yet secretion can generally be proved. While the typical syndrome generally consists of vasodilatation and perspiration whereby the areas of these processes do not need to coincide, the syndrome can also in rare cases be accompanied by pains. (TRIOUMPHOFF, FRIDBERG, LIST & PEET). In most cases the subjective symptoms are also typical, as in my case 1. The sensibility of the hyperhidrotic areas also varies in different cases. Sometimes it seems to be normal, mostly there is, however, hypesthesia or hyperesthesia to all qualities, the former being somewhat more common. The disturbances of sensibility mostly comprise a larger area than the hyperhidrosis. Facial paralysis can sometimes be established as subordinate symptom, but it has no direct connection with the syndrome.

The relation of the gustatory hyperhidrosis to the adequate stimulus of sweating, viz. general warming of the body, is interesting. In cases where there is a reason to presume an interruption in the preganglionic neuron of the sympathetic nerve supply to the sweat glands, as is the case after sympathectomy or in syringomyelia, there seems to be a complete anhidrosis by general warming in the gustatory hyperhidrotic region. In those cases, however, which have had a local process in the parotid region, there is mostly only a slight hypohidrosis or a normal symmetric reaction to warming. Several authors have examined the reaction of their patients to a subcutaneous injection of pilocarpine and they all seem to have come to the same result: After pilocarpine doses of some cg perspiration appears quicker and at the beginning more richly in the gustatory hyperhidrotic area than on the sound side, whereas, during a later phase of the action of pilocarpine, this side shows a richer secretion.

Mechanism and Pathogenesis.

The mechanism of the gustatory local hyperhidrosis of the face is a pathophysiological problem which has been the subject

of many hypotheses. Before discussing the different theories a summary of the course of the secretory pathways in the cranial nerves might be motivated.

Like the rest of the sweat glands of the body those of the face are also innervated by the sympathetic and the peripheral pathways to the glands consist of two neurons, the preganglionic and the postganglionic. The preganglionic fibers set out from the upper thoracal segments of the spinal cord, running through the white rami communicantes to the sympathetic chain in the upper thoracal region, then upwards in the cervical sympathetic trunk. They join the postganglionic fibers in the upper cervical ganglion. The course of the postganglionic fibers cannot be considered definitely established but the peripheral distribution of these fibers goes in the trigeminal nerve. Some of these fibers probably reach this nerve through the periarterial plexus of the external carotid artery, while others possibly run in the internal carotid nerve, the tympanic plexus or the deep petrosal nerve reaching by means of these the trigeminal branches (List & Peet). The facial nerve probably contains sweat fibers only to the extent in which it receives anastomoses from the auriculotemporal nerve and the great auricular nerve.

The postganglionic sweat gland fibers are cholinergic sympathetic fibers, viz. the transmission of nerve impulses to the sweat glands occurs by means of a liberation of acetylcholine as is the case with parasympathetic fibers, and their effect can be inhibited by atropine and strengthened by eserine and pilocarpine. These properties also apply to the parasympathetic secretory fibers to the salivary glands, the function of which seems to be decisive for the origination of the gustatory hyperhidrosis. The parasympathetic secretory pathway for the parotid gland sets out from the salivary nucleus in the medulla oblongata, running in the glossopharyngeal nerve to the petrous ganglion from where it passes by the tympanic nerve and the lesser superficial petrosal nerve and the synapses in the otic ganglion to the auriculotemporal nerve which gives out the parotid rami to the gland. The salivary glands are contrary to the sweat glands doubly innervated. The sympathetic pathway to the parotid gland runs in the cervical sympathetic trunk up to the upper cervical ganglion from where the postganglionic neuron passes to the gland along the branches of the external carotid artery. The postganglionic sympathetic neuron is adrenergic, viz. the transmission of nerve impulses is done by means of sympathin which has the properties of adrenaline.

What is then the mechanism of this phenomenon? Almost all authors express more or less diverging theories. As to the fundamental idea these theories can, however, be divided into four principal groups:

1. The phenomenon is due to the circumstance that the centrifugal pathway to the salivary gland in the auriculotemporal

nerve after an injury on this nerve, has regenerated into the pathways to the sweat glands running in the same nerve. (ANDRÉ-THOMAS, PAYNE). This theory is contrary to the fact that the phenomenon sometimes is not limited to the innervation area of the auriculotemporal nerve, but may also comprise areas of the skin innervated by other nerves which do not contain any salivary gland fibers. This fact precludes also the idea that it might be the question of transmission of impulses from the salivary gland fibers to adjacent sweat gland fibers in the same nerve. The latter mechanism might be possible in the cervical sympathetic but the syndrome may also occur after a cervical sympathectomy.

2. Contraction of the scar in the parotid region has caused a state of irritation of the sympathetic fibers leading to the skin and this irritation increases with swelling of the parotid gland by function (TRIOUMPHOFF, NOICA & BAGDASAR, NEEDLES etc.). This theory does not explain why the phenomenon occurs by affections in the central nervous system or the cervical sympathetic, thus in cases where no cicatrization in the parotid region is present.

3. The phenomenon originates in a normally existing reflex which has been deprived of normally existing inhibitory factors (VÁMOS, KAMINSKY, SCHIPIZYN).

4. The phenomenon is a "humoral reflex" which depends on the fact that in adjacent tissue diffundated parasympathetic substance (acethylcholine) from cholinergic nerve endings of the salivary gland influences the sensitized cholinergic nerve—sweat gland system in the skin (LIST & PEET).

It is a well-known fact that hyperemia and perspiration occurs in some otherwise quite sound persons symmetrically in the face in connection with meals. A classical example of this phenomenon was the well-known physiologist BROWN-SÉQUARD, who, in 1859, demonstrated his affection himself to the Societé de Biologie. The explanation may easily be found to be that both this phenomenon and the local gustatory hyperhidrosis are reflexes originating through normal pathways. This explanation should presuppose a double innervation of the sweat glands, a fact which has neither anatomically nor physiologically been established. Besides, this idea is contrary to the fact that the function of the centrifugal pathway of the salivary gland is decisive for the occurrence of gustatory sweating.

The researches of the last 20 years of the autonomic nervous

system have proved the existence of so-called humoral reflexes, viz. that the influence of the autonomic nerves by means of active chemical substances (acethylcholine and sympathin) which are generally constituted at the nerve endings, can be passed over to organs more or less distant from these. That the stimulation of salivary gland nerves after injection of eserine can be transferred in a humoral way from the stimulated gland to the corresponding gland on the opposite side causing both hyperemia and secretion has been shown by BABKIN, STAVRAKY & ALLEY. GIBBS & SZELÖCZEY proved that blood from a stimulated salivary gland contains acetylcholine. — The statement of LIST & PEET that the gustatory hyperhidrosis of the face is such a humoral reflex, is, as a matter of fact, so far the only statement which is not contrary to any of the facts known in connection with this phenomenon. It is very probable that there is in this syndrome a hypersensibility to acetylcholine in the nerve — sweat gland system (-vessel & -pilomotormuscle respectively) on account of the increased secretion provoked by pilocarpine and mecholyl in these cases. These tests do not, however, admit conclusions as to the points of attack with certainty being only peripheral or not. In the discussion published in connection with the paper of LIST & PEET, LIST states that tests with intracutaneous acetylcholine injections have not been made.

Acetylcholine is so quickly destroyed in the blood vessels that conclusions as to a purely peripheral increased irritability to this substance by local intracutaneous injections of small doses well can be drawn. Based upon tests made in my case 1. it can be established that such increased irritability to acetylcholine exists in the nerve — sweat gland system in the skin area in question. According to LIST & PEET this increased irritability is a result of denervation in cases where the hyperhidrosis is caused by an injury on the sympathetic ganglia or the sympathetic trunk, while it is the result of a cicatrization which has influenced the fibers to the sweat glands in the auriculotemporal nerve in cases of parotitis.

The probable explanation of this syndrome thus seems to be that there is an increased irritability in the autonomic synapses in a limited skin area near the big salivary glands after an injury in the parotid region or on the sympathetic. When the patient is eating, acetylcholine is constituted in the salivary glands in connection with their function and this substance diffundates

in the surrounding tissue enough to cause sweat secretion and hyperemia in the supersensitive area. EDELSTEIN has proved that acetylcholine easily and quickly diffundates in the tissues. That the obliteration of veins and lympahtic vessels which might, in most cases, be a normal result of the accomplished suppurating process, may cause an increased circulation of fluid from the salivary gland towards the skin seems probable.

Prognosis and Therapy.

As far as the duration of the symptoms in these cases is concerned, the prognosis seems to be bad. In most of the published cases the symptoms have, at the time of examination, continued already several years, in one of the cases of LIST & PEET the condition had been unchanged during 48 years, in both cases of POKROFFSKY and PAYNE over 30 years. In a few cases, as in my case 2, the symptoms have shown a tendency to diminish spontaneously.

As these patients mostly are very embarrassed by their affection, a therapy of some kind has, in most cases, been attempted, often, however, without success. Atropine reduces temporarily the symptoms, but disturbs the taking of food on account of a reduced salivary secretion. A therapy which obviously is effective, is resection of the nerve or nerves within the innervation area of which the phenomenon occurs. This agrees with the experience that postganglionically denervated sweat glands after a short period of increased irritability atrophy totally and cease secreting (HYNDMAN & WOLKIN). Exstirpation of the upper cervical ganglion might thus also be of effect. Whether the therapy is worth a Horner's syndrome is, however, doubtful. One of the cases of TRIOUMPHOFF was free of symptoms after resection of the great auricular nerve, one of the cases of DOBROTWORSKY after resection of the above nerve and the lesser occipital nerve. SOSON-JAROSEWIČ resected the auriculotemporal nerve, the infraorbital nerve, the great auricular nerve and the supraclavicular nerves of one of his patients. Most authors seem, however, to have abandoned resection of the auriculotemporal nerve, which most often might have been considered, obviously because of the danger of a lesion of the facial nerve.

X-ray treatment has been tried by NEEDLES who reached a temporary result, but who did not have the opportunity of com-

pleting the therapy. TRIOUMPHOFF states that he has attained obvious improvement in three cases by means of local clay packing which is also recommended by FRIDBERG. This treatment is supposed to soften the scar, and thus reduce the symptoms.

In my case 1 the patient has not yet been subject to any treatment. Excision of the affected skin area in case 2 which was possible because of the unusually limited area, and which led to comparative freedom from trouble, has probably not been made earlier in any case.

Summary.

Gustatory local hyperhidrosis in the face is a rare syndrome. Within a limited skin area in the face, mostly within the area innervated by the auriculotemporal nerve on either side, rich sweating and redness occurs when the patient is eating. The author describes the syndrome and discusses the pathogenesis at issue based upon two observed cases. The syndrome mostly occurs after a suppurating parotitis as on one of the described cases. In the second case the syndrome occurred after an operation of tubercular cervical lymphomata with ensuing suppuration. It may appear also after traumatic lesions or exstirpation of tumors in the parotid region, after cervical sympathectomy and in syringomyelia. The symptoms are closely connected with the function of the salivary glands. Tests made in one of the cases with intracutaneous injections of acetylcholine prove that there is an increased irritability to this substance in the nerve — sweat gland system in the affected skin area. This fact supports the idea that the mechanism of the syndrome is a "humoral reflex". This is caused when parasympathetic substance (acetylcholine) diffundated from an adjacent salivary gland, affects the autonomic organs sensitized by a nerve injury, in a limited area of the skin. Spontaneous healing is rare. Resection of the corresponding cutaneous nerves counteract the symptoms.

Zusammenfassung.

Die gustatorische lokale Gesichtshyperhidrose ist ein seltenes Syndrom. Es besteht darin, dass einseitig innerhalb eines begrenzten Hautgebietes des Gesichts, und zwar am häufigsten in dem Innervationsgebiete des Nervus auriculotemporalis, starkes

Schwitzen und Erröten beim Essen auftreten. Der Verfasser beschreibt das Syndrom und bespricht seine umstrittene Pathogenese auf Grund zweier beobachteter Fälle. Das Syndrom tritt am häufigsten nach einer eitrigen Parotitis wie in dem einen der beschriebenen Fälle auf. In dem anderen Falle ersehien das Syndrom nach Operation wegen tuberkulöser Lymphdrüsen am Halse mit nachfolgender Eiterung. Das Syndrom kann auch nach traumatischen Verletzungen oder Exstirpation von Tumoren im Parotisgebiete, nach cervikaler Sympathectomie und bei Syringomyelie erfolgen. Die Symptome stehen mit der Tätigkeit der Speicheldrüsen in engem Zusammenhange. Die in dem einen Falle ausgeführten Versuche mit intrakutaner Injektion von Acetylcholin beweisen dass eine Überempfindlichkeit des Systems Nerv-Schweissdrüse gegen diesen Stoff im affizierten Hautgebiete vorhanden ist. Diese Tatsache spricht stark dafür, dass der Mechanismus des Syndroms ein »humoraler Reflex« ist. Dieser kommt dadurch zustande, dass aus einer naheliegenden Speicheldrüse ausdiffundierte Parasympathieussubstanz (Acetylcholin), die durch eine Nervenbeschädigung sensibilisierten vegetativen Organe eines begrenzten Innervationsgebietes der Haut beeinflusst. Spontane Heilung ist selten. Resektion von entsprechenden Hautnerven hebt das Syndrom auf.

Résumé.

L'éphidrose gustative locale de la face est un syndrome rare. Il consiste en une sudation abondante et un rougissement d'une partie circonscrite unilatérale du visage, en général de la zone d'innervation du nerf auriculo-temporal, lesquels se produisent quand le malade mange. L'auteur décrit le syndrome et discute sa pathogénie contestée en raison de deux cas observés. Le syndrome apparait le plus souvent après une parotidite suppurative, comme dans un des cas décrits. Dans l'autre cas le syndrome est apparu après une extirpation des glandes lymphatiques tuberculeuses suivie d'une suppuration. Il peut aussi se présenter après des lésions traumatiques ou une extirpation de tumeurs dans la région parotidienne, après une sympathectomie cervicale et comme un symptôme de syringomyélie. Les symptômes sont intimement en rapport avec le fonctionnement des glandes salivaires. Des expériences exécutées dans un des cas décrits avec des injections intra-cutanées d'acetylcholine ont prouvé une hypersensibilité du système nerf — glande sudoripare de la partie affec-

tée de la peau. Ce fait soutient fortement la conception que le mécanisme du syndrome est un «reflexe humoral». Celui-ci est produit par l'effet qu'a la substance de parasympathique (acetylcholine), diffusée d'une glande salivaire proche, sur les organes végétatifs d'une zone d'innervation circonscrite de la peau, lesquels ont été sensibilisés par une lésion de nerf. Une guérisson spontanée est rare. Une résection des nerfs cutanés correspondants élimine les symptômes.

References.

André-Thomas: Rev. neur. 1927. *1.* 447. — Babkin, B. P.: G. W. Stavraky and A. Alley: Amer. J. Physiol. 1932. *101.* 2. — Baillarger: Gaz. méd. Par. 1853. 13. Quoted from S. Botkin, Berl. klin. Wschr. 1875. 81. — Dobrotworsky, W.: Nov. chir. Arch. 1924. *5.* Quoted from Zbl. ges. Chir. 1925. *24.* 1322. — Edelstein, I. A.: Bull. Biol. et Méd. exper. URSS 1939. *8.* 226. Quoted from Ber. Ges. Physiol. 1940. *118.* 656. — Frey, L.: Rev. neur. 1923. *2.* 97. — Fridberg, D.: Dtsch. Z. Nervenhk. 1931. *121.* 225. — Gibbs, O. S. and J. Szelöczey: Arch. exper. Path. 1932. *168.* 64. — Guttmann, L.: Z. Neur. 1931. *135.* 1. — Guttmann, L. and C. F. List: Z. Neur. 1928. *116.* 504. — Higier, S.: Polska Gaz. lek. 1926. *19.* 5. Quoted from Rev. neur. 1927. *1.* 147. — Hyndman, O. R. and J. Wolkin: Arch. Neurol. & Psychiatr. 1941. *45.* 992. — Jarin, S.: Vrač. Delo, 1928. *11.* 649. Quoted from Z. org. Chir. 1929. *47.* 257. — Kaminsky, S. D.: Dtsch. Z. Nervenhk. 1929. *109.* 296. — Lemaitre, F. and E. Baudouin: Ann. Oto-Laryng. 1934. 774. Quoted from Zbl. Neur. 1935. *75.* 532. — Lipsztat, J.: Neur. polska 1922. *6.* 383. Quoted from Zbl. Neur. 1922. *30.* 318. — List, C. F. and M. M. Peet: Arch. Neurol. & Psychiatr. 1938. *39.* 1228. — List, C. F. and M. M. Peet: Arch. Neurol. & Psychiatr. 1938. *40.* 443. — Needles, W.: Arch. Neurol. & Psychiatr. 1936. *35.* 357. — New, G. B. and H. E. Bozer: Minnesota Med. 1922. *5.* 652. Quoted from Vaughan, 1925. — Noica et Bagdasar: Rev. neur. 1926. *I.* 225. — Payne, R. T.: Lancet 1940. *I.* 634. — Pokroffsky: Berl. klin. Wschr. 1875. *12.* 164. — Raymond, P.: Arch. de Neurol. 188. *15.* 54. — Royer, J.: Sur la phys. de l'homme et des anim. 1857. Quoted from S. Botkin, Berl. klin. Wschr. 1875. *12.* 81. — Schipizyn, W. P.: Westn. Chir. i pogr. 1925. *4.* 313. Quoted from Zbl. ges. Chir. 1926. *12.* 747. — Schneider, M. E.: Mschr. Psychiatr. 1938. *98.* 125. — Soson-Jarosevič, A.: Sovrem. Psichonevr. 1928. *7.* 304. Quoted from Zbl. Nervenhk. 1930. *54.* 82. — Thygesen, P.: Ugeskr. f. Læger 1943. *105.* 771. — Trioumphoff, A.: Presse méd. 1926. *34.* 1350. — Uprus, V., J. B. Gaylor and E. A. Cardmichael: Brain 1934. *57.* 443. Quoted from Zbl. Nervenhk. 1935. *76.* 302. — Vámos, L.: Derm. Wschr. 1938. *107.* 1147. — Vaughan, V. T.: J. amer. med. Assoc. 1925. *84.* 583.

From The Municipal Hospital, Vasa.
(Chief: L. J. LINDSTRÖM, M. D.)

On Repositioned Luxation Fracture of the VI Cervical Vertebra with Transverse Paralysis of the Spinal Marrow.

By

L. J. LINDSTRÖM, M. D.

We are indebted to BÖHLER's great eminence for the introduction of active repositioning of vertebral fractures with subsequent fixations. If a fracture of the vertebral column is combined with paralysations it is our indubitable duty to carry out a repositioning at *the earliest possible moment*, says BÖHLER, for the purpose of restoring the space in the spinal canal and removing every detrimental pressure on the spinal marrow and the roots of the nerves. He stresses particularly that in the case of paralysations repositioning is a measure of equal urgency as in a case of acute perforation in the abdominal cavity or a haemorrhage in progress.

When in fractures or paralysations a statement has to be made whether the spinal marrow has been injured or not, an X-ray picture cannot give reliable information. A repositioning should always be attempted if the injured person is viable and *immediately*, before an oedema has time to develop.

What has been said of spinal column fractures with paralysis refers, of course, in a still higher degree to injuries of the cervical vertebra. In luxation fractures of the upper cervical vertebra the patient dies, as a rule, in a few days on account of paralysis in the respiratory organs. BÖHLER advises repositioning and plaster-of-Paris encasement in such fractures as well. But in cases combined with paralysis he wishes to reposition those cases only in which there is still a certain mobility in the legs. "Schlaffe Lähmung beider Beine und Priapismus zeigen, dass das Rückenmark zer-

stört ist. Hier ist jede Behandlung aussichtslos. Die Einrichtung soll deshalb unterlassen werden." In another connection BÖHLER points out that in luxations in which the arch of the vertebra is fractured, there is a possibility that the spinal marrow has not been injured even if the dislocation is rather great.

A. STAPF stated, however, that repositioning in fractures of the lower cervical vertebrae must be attempted in certain cases, even if there is a weak paralysation of the extremities. The cases

Fig. 1.

I have treated and reported below of luxation fractures in the VI cervical vertebra combined with total paralysis of the lower and upper extremities support this conception.

As regards repositioning of cervical vertebrae certain technical equipment must be ready beforehand in the hospitals, as there is generally no spare time for making arrangements. These fractures are not uncommon in our days and the hospitals should be prepared to receive them. They often occur in traffic accidents and in sports, especially in wrestling and swimming.

The obligatory arrangements are as follows:

1. A spring balance, capacity 50 kilograms.
2. A strong Glisson sling.
3. A contrivance for counterbalance, for instance, a strong belt with firm hooks to fasten around the waist — such as used by firemen.
4. A pulley with rope attached.

5. Strong staples fixed in the wall for attaching the pulley and the counterbalance.

6. An X-ray apparatus for controlling the repositioning.

7. A board, 150 centimeters in length, 3—4 cm broad and 1 cm thick (used when applying plaster-of-Paris encasings).

8. Cotton-wool and plaster-of-Paris bandages.

A corporal, 23 years of age, farmer by profession, called up for military service in 1940, was injured on September 7, 1943 in a wrestling practice at the front. He was thrown head first to the ground and his neck was bent forward. He did not feel any pain at the moment but lost mobility and feeling immediately. He was at once taken to the nearest war-hospital in Petroskoj. In the report on the disease from the hospital we find the following:

"7. 9. 43. General condition good. The patient lies on his back with legs outstretched, the arms bent at elbows and the neck stiff in medial position. He can only move the elbow joints actively. Shape of neck usual but mentions tenderness in the lower cervical vertebrae if pressed and if the neck is moved passively. The neck can be moved passively rather freely. Sensibility intact although slightly reduced in lower extremities. Jerks intact. Priapismus.

8. 9. X-ray picture of cervical vertebrae shows no fracture or luxation (the X-ray picture includes only the upper 5 cervical vertebrae).

9. 9. Patellar jerks extinct.

16. 9. The weak paralysation of the legs unchanged. There is active mobility in elbow joints only. Sensibility as before. The patient cannot pass urine. A permanent slack erectio penis is present.

Notwithstanding the negative X-ray finding we have probably here a fracture of the V cervical vertebra with a lesion of medulla cum prognosi pessima.

Major medical — — — — — — —"

In this condition the patient was transported by hospital-train to the far off Vasa. He was placed on a stretcher with no support for his neck. He arrived in the evening of September 17, and was placed in my ward.

Notwithstanding the long journey the general condition of this strong man was still satisfactory. Temperature 38—39 C. ax. on account of infection of the urinary passage caused by catheter ademeure. S. R. 67/hour. He was able to raise both shoulders and his wrist slightly. Weak paralysis in the rest of his body. There was an impetiginous eczema on his lower extremities and on the left heel a decubitus wound.

A lateral picture of the cervical vertebrae reveals a compression fracture in C VI body of the vertebra which is luxated dorsally. In the vertebral arch there is a fracture and proc. articularis is displaced dorsally. In C VI proc. articularis probably also fractured. (Fig. 2.)

There is evidently a flexion fracture and dorsal luxation of C VI with transverse paralysis of the spinal marrow. Ten days had elapsed

since the accident but the patient's general condition was still good. As the dislocation of the vertebra was slight, the spinal marrow was probably not much damaged. The patient was strong and viable and after sulphatiazol treatment his temperature had decreased. Despite the longstanding compression of the spinal marrow I wished to try to save the patient's life by an attempt at repositioning. There was nothing to lose by it.

The first repositioning attempt was made on September 22. After local anaesthesia in the lower vertebra of the neck and one ampulla

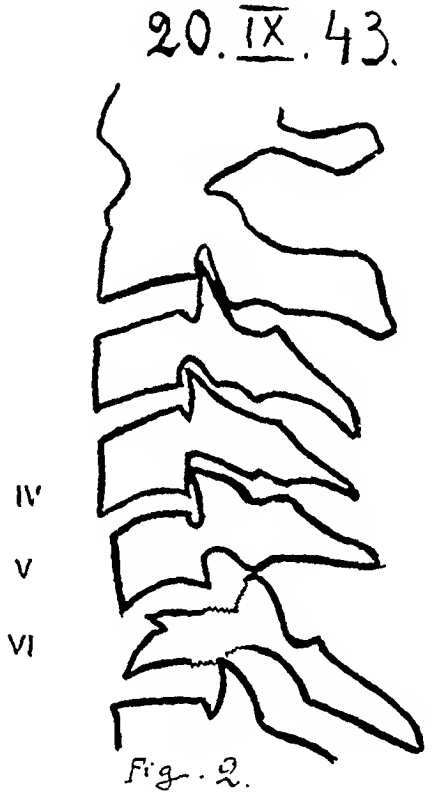

Fig. 2.

of scophedal i. v. having been administered the patient's neck was subjected to strain with 25 kg/15 min. followed by 38 kg/30 min. The repositioning was not successful. Another attempt was made on the following day, September 23. Local anaesthesia was again administered. The neck was subjected to a strain of 38—40 kg/25 min. The vertebra now became fairly replaced and the patient's neck was encased in plaster-of-Paris collar, according to Böhler. (Fig. 3.) The process of the disease was as follows:

25. 9. Patellar jerks returned.

27. 9. Clonic contraction in right leg.

5. 10. Intestine functions spontaneously and the patient is able to pass urine, but half a liter of residual urine remains.

18. 10. (25 days p. op.) Slight jerks in right knee observed and slight movements in the big toes. In left leg also very slight mobility stated.

28. 10. Plaster-of-Paris dressing changed.

2. 11. The patient can move both legs in bed.

11. 11. (49 days p. op.) Plaster-of-Paris encasing, which inconveniences greatly, removed, and the neck fixed in Glisson sling. Mobility in right leg fairly satisfactory but the left leg unsatisfactory. Left ankle

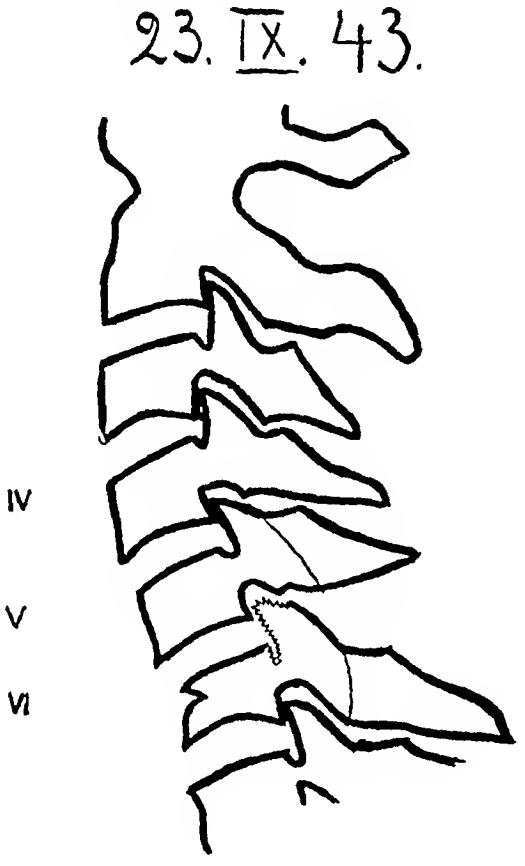

Fig. 3.

immobile. Mobility of fingers partly returned. Urine passed spontaneously and the bladder emptied almost completely.

9. 12. The patient is able to feed himself.

23. 12. (3 months p. op.) The patient's legs begin to support him in a "push-chair".

22. 1. 44. The patient moves about fairly easily in the "push-chair" and stands without support for a moment.

He improved slowly. An examination 15 months after the accident revealed a strong man in good general condition. He usually uses a stick but is able to take a few steps without support. He is able to walk half a kilometer without difficulty. Mode of walking somewhat spastic. The right leg is quite normal in all joints. The active mobility

of the hip joint and the knee of the left leg reduced, the left knee has a certain recurvate position and he drags the outer side of his foot somewhat. The muscularity of his trunk is good, he has no difficulty in bending and stretching his body. Shoulder and elbow joints function normally, flexor of hands good, but there is a certain radial paresis in both sides. He is able to flex the wrists dorsally only if his fingers are bent.

A later examination, almost two years after the accident, reveals a further improved condition. The patient still uses a stick but he is able to walk about 3 kilometers without resting. His mode of walking is still spastic, the patellar jerks are lively and there is a slight clonus of the feet. The joints of the right leg are normal but the left wrist cannot be dorsally flexed more than 90°. The hands are not so good as the legs. The muscles of his right hand cannot be fully extended and mm. interossei are paralysed. The fist of his left hand cannot be completely closed but the extension of the fingers is slightly better than on the right side. The man still has no work.

My case was thus a transverse paralysis of the vertebral column caused by a luxation fracture of the VI cervical vertebra. The dislocation of the vertebra was not specially great. Repositioning of the vertebra took place 16 days after the trauma. The paralysations were reduced to a great extent notwithstanding the delay. The bladder and the intestines functioned again after 12—14 days, and 3 months later he was able to stand on his legs. There is reason to believe that the patient would have recovered completely if repositioning had taken place directly after the accident.

This case teaches us not to despair about luxations and fractures of vertebrae combined with paralysis, but to attempt repositioning if the patient seems viable. Furthermore we should bear in mind Böhler's counsel to give injuries of this kind immediate care. To be able to intervene without delay, all apparatuses for repositioning of cervical vertebrae should be in order and ready for use in all hospitals.

Summary.

Report on a case of luxation fracture in a man, aged 23, combined with transverse paralysation of the spinal marrow. The man was injured in wrestling and the neck bent forward. He immediately lost mobility of his entire body except shoulders and elbow joints. Repositioning according to Böhler was not undertaken until 16 days after the trauma. In spite of the delay the

patient recovered and the paralysations were almost cured. Three months later his legs were able to support him and 15 months later he was able to walk fairly well and his upper extremities were almost normal. The author stresses the importance of treating fractures of the spinal column and luxations combined with paralysis as urgent surgical operations and to undertake repositioning at once. For this purpose all technical arrangements for repositioning of cervical vertebral fractures must be ready for use in every hospital.

Zusammenfassung.

Wiedergabe eines Falles von Luxationsfraktur bei einem 23-jährigen Manne, kombiniert mit Querschnittslähmung des Rükkenmarks. Die Verletzung trat beim Ringkampf auf, durch Vornüberbeugung des Kopfes. Er verlor sogleich das Bewegungsvermögen im ganzen Körper mit Ausnahme der Schultern und Ellenbogengelenke. Reposition nach Böhler wurde erst 16 Tage nach dem Trauma vorgenommen. Trotzdem erholte der Kranke sich, und die Lähmungen gingen grösstenteils zurück. Nach 3 Monaten begann er, auf den Beinen stehen zu können, und nach 15 Monaten konnte er, wenn auch mangelhaft, gehen und seine oberen Extremitäten fast normal gebrauchen. Verf. betont, wie wichtig es ist, von Lähmungen begleitete Wirbelsäulenfrakturen und -luxationen als eilende Operationsfälle zu betrachten und sofort zu reponieren. Um dies zu ermöglichen, sollten die technischen Vorkehrungen zur Reposition von Frakturen der Halswirbel in jedem Krankenhause gebrauchsfertig bereit stehen.

Résumé.

Relation d'une fracture par luxation de la colonne cervicale chez un homme de 23 ans, combinée à une paralysie transverse d'origine médullaire. Lésion au cours d'une lutte dans laquelle la nuque fut ployée en avant. Perte immédiate de la motricité dans tout le corps à l'exception des articulations de l'épaule et du coude. Réduction suivant Böhler 16 jours après le traumatisme. Ce nonobstant, le malade se rétablit et les paralysies rétrocédèrent en majeure partie. Au bout de trois mois, le malade pouvait se tenir sur ses jambes et au bout de 15 mois il pouvait marcher, mais avec difficulté; il avait aussi l'usage de ses extrémités su-

périeures. L'auteur souligne l'importance du fait que les fractures et les luxations de la colonne vertébrale suivies de paralysie soient traités comme des cas d'urgence et réduites immédiatement. Afin de rendre l'intervention possible, les dispositifs techniques nécessaires à la réduction de fractures des vertèbres cervicales doivent être prêts à fonctionner dans tous les hôpitaux.

Literature.

Böhler: Die Technik der Knochenbruchbehandlung, Wien 1943. — Stapf, A.: Zbl. f. Chir. 1943. p. 828.

Aus der chirurgischen Abteilung des Maria-Krankenhauses in Helsingfors.
(Vorstand: Doz. Dr. med. A. PELKONEN.)

Über einen Fall von Paragangliom mit seltener Lokalisation.

Von

PEHR MALM.

Ein operierter Fall von Paragangliom, der ausserhalb der Nebenniere liegt und ein Passagehindernis im Duodenum bildet, ist eine so grosse Rarität, dass die Publizierung dieses Falles angebracht sein dürfte, obwohl die Untersuchung und die Angaben in der Krankengeschichte Mängel aufweisen, welche teils darauf beruhen, dass die Diagnose erst nach der Operation durch die histologische Untersuchung gestellt werden konnte, teils auf dem durch den Krieg bedingten hochgeschraubten Arbeitstempo und dem Mangel an Personal.

Einen operierten Tumor, der vom chromaffinen System ausgeht und so lokalisiert ist wie der unten beschriebene Fall, habe ich in der Literatur nicht angetroffen. Einen operierten Tumor mit etwas ähnlicher Lokalisation hat STANGL (1902) beschrieben.

Die Patientin, eine 53-jährige Hausgehilfin, wurde am 12. 4. 1943 (Journ. Nr. 1067/43) in die chirurgische Abteilung des Maria-Krankenhauses in Helsingfors aufgenommen. 20 Jahre früher war sie wegen Leistenbruch operiert worden, und vor 16 Jahren war wegen Uterusmyom und verwachsener Appendix eine supravaginale Uterusamputation (Chrobak) und Appendicectomie ausgeführt worden. Seit mehreren Jahren hatte sie nun Schmerzen im oberen Teil des Bauches gehabt. Sie fühlte die Schmerzen die ganze Zeit, aber sie wurden regelmässig schlimmer einige Stunden nach den Mahlzeiten sowie oft in der Nacht. Periodeweise litt sie an Erbrechen einige Stunden nach den Mahlzeiten, ohne dass es zu Blutbrechen kam. Die Schmerzen strahlten auch in den Rücken aus. Oft fühlte sie sich müde, hatte Schwindel und Kopfschmerzen. Die Darmtätigkeit war immer träge gewesen. St. pr.: Allgemeinbefinden gut. Lungen und Herz o. B. Blutdruck 160 mm Hg. Rechts im Epigastrium, direkt unter dem rechten Rippen-

bogen, war eine glatte Resistenz zu fühlen, die etwas beweglich zu sein schien. Über das Probefrühstück, das poliklinisch vor der Aufnahme ins Krankenhaus genommen wurde, fanden sich nur die Angaben: Kongo —, Lackmus schwach alkalisch. Die Röntgenuntersuchung zeigte einen verlängerten Hakenmagen mit vermehrter Sekretion. Die Wände sind glatt und weich, die Peristaltik regelmässig. Der Bulbus duodeni ist etwas uneben, kommt aber auf Druck gut heraus. Empfindlichkeit in der Pylorusgegend. Der Ventrikel leert sich langsamer als gewöhnlich. R. D.: Ptosis ventriculi (Ulcus duodeni?).

13. 4. 1943. Laparotomia. Exstirpatio tumoris retroperitonealis (Aethernarkose, Op. A. Pelkonen). Mediansehnitt oberhalb des Nabels. Der Ventrikel ist gross, Pylorus frei. Direkt hinter dem Pylorus und dem Duodenum fühlt man retroperitoneal einen glatten, etwas beweglichen Tumor, der nicht an der Pankreas befestigt ist. Nachdem das Peritoneum durchschnitten ist, wird der Tumor besser sichtbar, wobei sich zeigt, dass er direkt auf der Aorta und der Vena cava inf. liegt. Die rechte Niere wird lateral vom Tumor und frei davon palpiert. Der Tumor wird teils scharf, teils stumpf abgeschält. Eine geringe Blutung aus der Wand der Vena cava kann gut ligiert werden. Peritonealsutur mit Catgut. Die Bauchwunde wird exakt geschlossen.

Der Tumor hat die Grösse eines grösseren Hühnereis, und seine Form ähnelt einer Niere. In der Mitte befindet sich ein Hohlraum ohne Öffnung. Die Schnittfläche erinnert etwas an Nierengewebe mit stellenweise missfarbenen, runden Partien (Abb. 1). Histologische Untersuchung (Doz. I. Wallgren): Im Präparat sieht man reichlich polygonale, plasmareiche Zellen von verschiedener Form und Grösse. In vielen Zellen reichlich Pigment. An einer Stelle ist ein schräg durchschnittener Nerv sichtbar. Der Tumor ist offensichtlich vom chromaffinen Gewebe ausgegangen. P. A. D.: Paraganglioma. (Abb. 2 und 3).

In den Tagen nach der Operation war die Patientin sehr angegriffen. Sie war sehr müde, erbrach sich während der zwei ersten Tage oft und hie und da noch bis zum 9. Tag. Sie wurde ikterisch, und am fünften Tag bekam sie Diarrhöe, welche 5 Tage dauerte. Erst nach einer Woche begann sie sich etwas zu erholen. Zwei Wochen nach der Operation wurde eine linksseitige Pleuritis festgestellt, wodurch der Aufenthalt im Krankenhaus so viel verlängert wurde, dass sie erst 39 Tage nach der Operation entlassen werden konnte.

Am 7. 10. 1943 wurde sie wegen eines Bruchs in der Operationsnarbe operiert, und 11 Tage später konnte sie als Konvaleszent aus dem Krankenhaus entlassen werden.

Bei der Nachuntersuchung am 17. 1. 1945, ca. 1 Jahr und 9 Monate nach der Operation, klagte sie über »rheumatische Schmerzen« im Rücken und in den Beinen. Seit sie sich nach der Operation erholt hatte, hatte sie weder Kopfschmerzen noch Erbrechen noch irgendwelche andere Bauchbeschwerden gehabt, nur der Stuhlgang war immer noch ständig träge. Im Bauch konnte keine Resistenz palpiert werden. Bei tiefer Palpation war die Narbe im Epigastrium empfindlich und rechts davon desgleichen ein handgrosses Gebiet. Das Probefrühstück zeigte keine Retention und neutralen Mageninhalt vor dem

Fig. 1. Der Tumor aufgeschnitten.



Fig. 2.

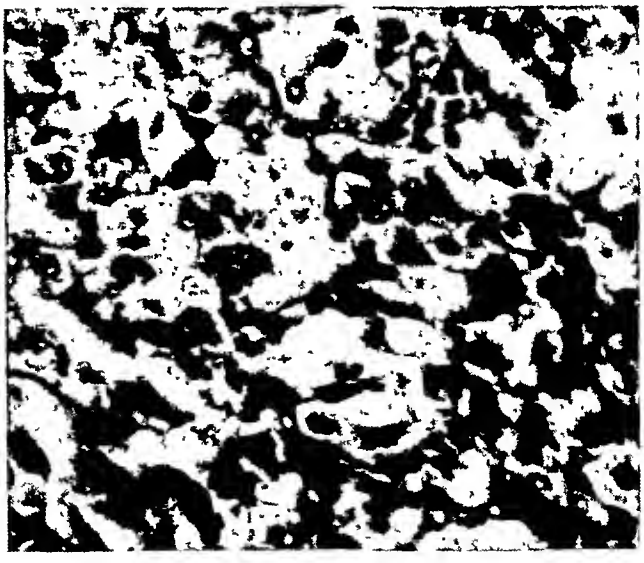

Fig. 3.

Frühstück. Nach dem Probefrühstück 25 cem gut digerierter Mageninhalt, HCl 55, TA 86. Die Röntgenuntersuchung des Ventrikels zeigte einen Hakenmagen von gewöhnlicher Form mit etwas vermehrter Sekretion. Die Wände waren weich und glatt, die Peristaltik lebhafter als gewöhnlich. Der Bulbus duodeni war etwas nach links gezogen und trat auf Druck gut hervor. Empfindlichkeit auf Druck in der Pylorusgegend. Der Ventrikel entleerte sich in gewöhnlicher Weise. Im Bulbus duodeni blieb etwas Barium zurück. R. D.: Adhaesiones. Blutdruck 180/100. EKG: In der II Schaltung eine ventrikuläre Extrasystole. EKG im übrigen normal bis auf eine leichte Verlängerung der Leitzeit, P ist gross und breit, stellenweise geteilt. Blutbild: Hgb 73/85 %, E 4,258,000, I 0.99, L 4,500, reichlich normale Thrombozyten. Diff.: Stabk. 1 %, Segm. 48 %, Lymphoz. 46.5 %, Monoz. 4.5 %, SR 1. St.: 2 mm, 2. St.: 7 mm, WR —, Kahn —. Steril genommener Urin: Klar, gelb, sauer, Heller —, einige vereinzelte Leukozyten und Epithelzellen. Gramfärbung: Keine Bakterien, Röntgendurchleuchtung des Thorax: Im linken Diaphragma eine kleine Adhärenz, der Sinus beiderseits frei. In den Lungen keine pathologischen Schatten. Herz von gewöhnlicher Grösse, seine Bewegungen etwas schlapp, der obere Teil der Aorta thoracica etwas prominierend. Reichlich Gase in der Flexura lienalis colonis.

Epikrisis: Die Patientin ist eine 53-jährige Frau mit langwierigen Bauchbeschwerden, welche Symptome eines Passagehindernisses im Duodenum, einen palpablen Tumor im Epigastrium und Achylie zeigt. Blutdruck 160 mm Hg. Die richtige Diagnose kann vor der Operation nicht gestellt werden. Bei der Operation kommt ein retroperitonealer Tumor zum Vorschein, der auf der Aorta und der Vena cava inf. liegt, und welcher von hinten auf das Duodenum drückt sowie an der Pankreas und Niere nicht befestigt ist. P. A. D.: Paragangliom. Nachdem die Patientin nach der Operation in den ersten Tagen äusserst mitgenommen war, wurde sie ikterisch, bekommt eine linksseitige Pleuritis, von welcher sie sich langsam erholt. Ein postoperativer Bruch wird später operiert. Bei der Nachuntersuchung fast 2 Jahre später lassen sich keine Zeichen von Rezidiv wahrnehmen, und die Bauchbeschwerden sind verschwunden. Auf eine Nachfrage bei ihrem Arbeitsgeber, welcher Arzt ist, am 24. 9. 1945, teilt dieser mit, dass sie in der letzten Zeit über Sodbrennen geklagt hat.

Das chromaffine System, das zu Beginn des Jahrhunderts von Kohn näher untersucht und beschrieben worden ist, umfasst ausser den Carotisdrüsen und dem Nebennierenmark das sog. Zukkerkandls Organ, welches neben der Aorta an der Ausgangsstelle

der A. mesenterica superior liegt. Ausserdem finden sich selbständige chromaffine Zellanhäufungen an den distalen Nierenpolen, an den AA. renales, in der nächsten Umgebung der Nebennieren, am os coccygis und in den Ganglienzellen im Grenzstrang und viszeralen Sympathicusplexus. Alle diese Paraganglien, wie sie auch genannt werden, produzieren Adrenalin.

Die aus dem Nebennierenmark stammenden Tumoren können in drei Gruppen eingeteilt werden:

1. Die Paragangliome (ALÉZAIS und PEYRON) oder, wie man sie auch nennt, die Phäochromocytome (L. PICK) gehen von chromaffinen Zellen aus.
2. Hie Ganglioneurome gehen von reifen Ganglienzellen aus.
3. Die Sympathoblastome oder Sympathogoniome gehen von embryonalen Zellen aus.

Die zu den zwei ersten Gruppen zählenden Tumoren kommen meistens bei Personen in mittleren Jahren vor und scheinen fast immer benign zu sein. DISTEFANO beschreibt jedoch einen Obduktionsbefund von einem kindskopfgrossen linksseitigen Paragangliom mit Metastasen in der Leber, den Hilusdrüsen und den Lungen. Die Tumoren der dritten Gruppe werden fast ausschliesslich bei Kindern angetroffen und sind malign.

J. P. STRÖMBECK und HEDBERG haben 1939 im Zusammenhang mit einem von ihnen beschriebenen Fall aus der Literatur 80 Fälle von Nebennierenparagangliom zusammengestellt, von welchen der grösste Teil bei Autopsien angetroffen worden war. Sie fanden 19 operierte Fälle, von welchen 7 kurz nach der Operation starben, alle unter Zeichen von schwerem Schock.

Im Jahre 1938 haben BRUNSCHWIG und HUMPHREYS in Amerika aus der Literatur eine Zusammenstellung von 103, meistens bei Obduktionen angetroffenen gutartigen Tumoren aus dem chromaffinen Nebennierengewebe veröffentlicht. Der Tumor lag 13 mal ausserhalb, aber in der Nähe der Nebenniere. Aus der Publikation der gleichen Verfasser vom Jahre 1940, welche mir zur Verfügung stand, geht nicht hervor, ob irgendeiner von diesen 13 Fällen bei der Operation angetroffen worden war, es ist nur gesagt, dass der grösste Teil von der ganzen Zusammenstellung bei Autopsien erhalten wurde. PAUL LINDE hat im Jahre 1942 aus der chirurgischen Abteilung der Heilanstalt Prinzessin Lovisa in Stockholm einen Fall von glücklich operiertem rechtsseitigem Nebennierentumor bei einem 5 Monate alten Knaben beschrieben. Dies war der jüngste Fall, den ich angetroffen habe. Im Jahre

1902 demonstrierte E. STANGL in Wien einen von A. v. EISELSBERG operierten Fall von Tumor im chromaffinen System ausserhalb der Nebenniere. Der Tumor lag auf der Aorta an ihrer Teilungsstelle. In KIRSCHNER-NORDMANNS »Die Chirurgie« vom Jahre 1928 wird dieser Fall als der einzige *operativ* behandelte Fall von retroperitonealem Paragangliom bezeichnet. Man kann also wohl behaupten, dass die retroperitonealen, ausserhalb der Nebenniere gelegenen Paragangliome grosse Raritäten sind, die sehr selten operiert werden, weil die richtige Diagnose nicht gestellt wird, und etwas weniger selten als Nebenbefund bei Obduktionen angetroffen werden. Wie wir aber gesehen haben, sind auch die Nebennierenparagangliome selten. Im pathologisch-anatomischen Institut in Basel wurden jedoch innerhalb eines Jahres (1911) bei 700 Sektionen nicht weniger als drei Fälle von Nebennierenmarktumor angetroffen (HEDINGER 1, HERDE 2). Dies verlockt einen ganz natürlich zu der Annahme, dass sie vielleicht doch nicht ganz so selten sind, wie es den Anschein hat, wenn man sie nur diagnostizieren könnte. Sie sind aber meistens recht klein und wegen ihrer Lokalisation unmöglich zu palpieren, und gewöhnlich geben sie auch keine sicheren klinischen Symptome. Es gibt jedoch eine Gruppe von diesen Nebennierenmarktumoren, die sich leichter diagnostizieren lassen, und zwar die Fälle, welche mit paroxysmaler Hypertonie verlaufen. Die Steigerungen des Blutdrucks treten hier auf in Attacken mit neurovaskulären Störungen, abwechselndem Erröten und Erbleichen, ausserdem Kopfschmerzen, Übelsein, Müdigkeit und Tachycardie. Diese Anfälle sind äusserst charakteristisch, und J. P. STRÖMBECK und T. P. HEDBERG haben im Jahre 1939 ausführlich über einen sehr typischen Fall berichtet.

Das histologische Bild bekommt ein charakteristisches Aussehen durch die verschieden grossen polygonalen Zellen, die verschieden grossen Kerne und das Vorkommen von Pigment. Am typischsten für diese Tumorform ist jedoch das Vorkommen von chromaffiner Substanz. Um die Chromaffinität herauszubekommen, muss das Präparat in einer kaliumbichromathaltigen Flüssigkeit fixiert werden, z. B. nach ORTH (Formaldehyd solut. pur. 10 Teile, Müller'sche Lösung 90 Teile (Müller'sche Lösung = Kalium bichromicum 2.5 g, Natrium sulfuricum 1.0 g, Aq. 100 ccm)). Das Präparat vom Maria-Krankenhaus war leider nur in Formalin fixiert worden, wodurch die Untersuchung auf chromaffine Substaz unmöglich gemacht wurde. Das histologische Bild

ist indessen so charakteristisch, dass die Natur des Tumors schon auf Grund dessen klar hervorgehen dürfte.

Wenn wir einmal die Diagnose Nebennierenmarktumor gestellt haben, so hat der Patient auch deutliche Beschwerden davon, und die Operationsindikationen sind klar. Wir müssen ja bedenken, dass der Tumor, obwohl er histologisch fast immer benign ist, in physiologischem Sinne bösartig ist. Ein Fall mit paroxysmaler Hypertonie kann nämlich zum Tode führen unter einer Attacke mit Lungenödem wie in einem von L'Abbé und Doumer beschriebenen Fall. Oder die Hypertonie kann permanent werden, und eine Herzhypertrophie entwickelt sich. Leider können wir uns kaum gegen das Risiko schützen, dass die andere Nebenniere atrophisch ist oder vollkommen fehlt. Denn die einzige Untersuchungsmethode, die uns in diesem Falle zur Verfügung steht, nämlich die Untersuchung mit Lufteinblasung in die Fettkapsel der Niere (Cahill), kann uns im Stiche lassen. Ein auf diese Weise diagnostizierter, von Strömbeck operierter Fall von Cortextumor ist von Josephson beschrieben worden, wo das Röntgenogramm nicht zeigte, dass die andere Nebenniere stark atrophiert war, und der Patient starb in suprarenaler Insuffizienz.

Die retroperitonealen, ausserhalb der Nebenniere gelegenen Paragangliome werden selbstverständlich entfernt, wenn sie angetroffen werden und entfernt werden können, denn die Natur des Tumors wird hier ja erst bei der histologischen Untersuchung geklärt. Ausserdem sollte die Schockgefahr in diesem Fall geringer sein, wenn wir nicht gleichzeitig Cortexgewebe entfernen, da der Tumor von einer von den umhergestreuten, retroperitonealen, chromaffinen Zellanhäufungen ausgeht. Die *echten* accessorischen Nebennieren, welche sowohl Cortex- als auch Markgewebe enthalten, sind bei Erwachsenen selten.

Die Schnittführung bei der Operation der retroperitonealen Paragangliomen muss natürlich vollständig von der Lage des Tumors abhängen. Ebenso wie bei den Nebennierentumoren muss man auch hier einen genügend grossen Schnitt ausführen, um den Tumor bequem behandeln zu können. Ausser der Gefahr der suprarenalen Insuffizienz nach der Entfernung von Nebennierentumoren müssen wir nämlich auch mit Blutdruckkrisen unter der Operation selbst rechnen, was vermutlich darauf beruht, dass unter der Manipulation des Tumors Adrenalin in den Blutumlauf gepresst wird. Dies ist wahrscheinlich die Ursache für mehrere von

den Todesfällen unter oder unmittelbar nach der Operation gewesen (HOLST). CAHILL, LOEB und andere versuchen dies zu vermeiden, indem sie die Venen des Tumors ligieren, ehe sie allzu viel damit manipulieren. STRÖMBECK schlägt eine allem Anschein nach effektivere Methode vor, indem er die Kapsel incidiert und einen Teil des Tumors entleert, ehe er ihn entfernt.

Da aus der Literatur hervorgeht, dass die meisten Nebennierenmarktumoren bei Obduktionen angetroffen worden sind, ohne dass sie bei Lebzeiten klinische Symptome gaben, könnte man sich die Möglichkeit denken, dass man einen derartigen Tumor als Nebenbefund z. B. bei einer aus anderen Gründen ausgeführten Laparotomie oder bei einer Nierenoperation antrifft. Ob man dann gleichzeitig auch den Nebennierentumor entfernen soll, muss natürlich von Fall zu Fall entschieden werden. Es dürfte jedoch angebracht sein, genau die Risiken zu erwägen, welche die Entfernung eines solchen Tumors mit sich bringt. Ich möchte nur erinnern an die 19 operierten Fälle in der Statistik von STRÖMBECK und HEDBERG, von welchen 7 kurz nach der Operation mit allen Zeichen von schwerem Schock starben, und dies betraf nicht nur die Fälle mit paroxysmaler Hypertension. Dieser Schock beruht offensichtlich auf einer ungenügenden Funktion der zurückgebliebenen Nebenniere, und man sollte versuchen, über die kritische Periode mit Hilfe von Cortin, adrenalinähnlichen Präparaten und gewöhnlicher Schocktherapie hinwegzukommen. Man könnte sich auch denken, dass die Entfernung des adrenalinproduzierenden Tumors eine Senkung des Blutzuckers erzeugt, was zum Auftreten des schweren postoperativen Schocks beitragen könnte. Der Blutzucker wurde in dem hier beschriebenen Fall leider nicht untersucht, welcher ja ebenfalls einen schweren postoperativen Schock hatte, ohne dass das Cortexgewebe entfernt worden war.

Nachdem die Patienten die postoperative Krise überwunden haben, erholen sie sich gewöhnlich ohne weitere Komplikationen. Der Ikterus im Falle aus dem Maria-Krankenhaus in Helsingfors war wahrscheinlich durch eine retroperitoneale Blutung mit Kompression des Choledochus verursacht worden, und die Pleuritis war wohl auf einen undiagnostizierten pneumonischen Herd zurückzuführen. Die Fälle mit paroxysmaler Hypertension wurden endgültig geheilt, und Angaben über Rezidiv finden sich nicht.

Zusammenfassung.

Eine 53-jährige Frau, welche im Jahre 1943 in der chirurgischen Abteilung des Maria-Krankenhauses in Helsingfors operiert wurde, hatte einen palpabeln Tumor im Epigastrium, verlangsamte Vertrikelentleerung und Achylie. Ausserdem Schmerzen, welche in den Rücken ausstrahlten und einige Stunden nach den Mahlzeiten schlimmer wurden, Müdigkeitsgefühl, Schwindel und Kopfschmerzen. Blutdruck 160 mm Hg. Der Tumor, welcher bei der Operation entfernt wurde, war stark hühnereigross, lag retroperitoneal hinter dem Pylorus und dem Duodenum auf der Aorta und der Vena cava inf. und war nicht an der Pankreas oder der Niere befestigt. Die histologische Untersuchung, welche von Doz. I. Wallgren durchgeführt wurde, zeigte ein Paragangliom. Ein Jahr und 9 Monate nach der Operation ist die Patientin gesund, keine Zeichen von Rezidiv. In der Literatur findet sich nur ein einziger früherer operierter Fall von retroperitonealem, ausserhalb der Nebenniere gelegenem Paragangliom, welcher von Stangl im Jahre 1902 demonstriert worden war. Hier lag der Tumor auf der Aorta in der Nähe ihrer Teilungsstelle. Einige andere Fälle von derartigen Tumoren in der Nähe der Nebennieren sind ausserdem bei Obduktionen angetroffen worden.

Von den Nebennierenmarktumoren dürften nur diejenigen, welche mit paroxysmaler Tachycardie verlaufen, vor der Operation diagnostiziert werden können. Die Operationsindikationen, die Ursachen für den schweren Operationsschock sowie die Mittel zu dessen Verhinderung werden diskutiert.

Summary.

A 53-year-old woman who was operated in 1943 in the surgical department of Maria Hospital in Helsingfors had a palpable tumor in the epigastrium, prolonged emptying of the ventricle and achylia. In addition she had pains which radiated through the back and became worse some hours after meals, a feeling of tiredness, giddiness and headache. Her blood pressure was 160 mm Hg. The tumor, which was removed by operation was the size of a rather large hen's egg, lay retroperitoneally behind the pylorus and the duodenum on the aorta and vena cava inf. and was not fixed in the pancreas or the kidneys. The histological ex-

amination which was made by Dr. I. WALLGREN, showed a paraganglioma. One year and nine months after the operation the patient was well; no signs of a relapse. In the literature one has come across only one previously operated case of a retroperitoneal paraganglioma situated outside the suprarenal gland which was demonstrated by STANGL 1902. There the tumor lay on the aorta where that vessel branches off. Some other cases of similar tumors in the neighbourhood of the suprarenal gland have also been encountered at post mortem examinations.

Of tumors in the medulla of the suprarenal gland only those which pass away with paroxysmal tachycardia should be possible to diagnose before the operation. Operation indications, the reason for and the manner of preventing the severe operation shock are discussed.

Résumé.

Une femme de 53 ans, opérée en 1943 dans la division chirurgicale de l'hôpital Ste-Marie à Helsingfors, était affectée d'une tumeur palpable dans l'épigastre, d'un retard de l'évacuation stomacale et d'achylie. Elle ressentait en outre des douleurs irradiant dans le dos avec paroxysme quelques heures après les repas, de la fatigue, des vertiges et de la céphalalgie. Pression sanguine: 160 mm Hg. La tumeur rétropéritonéale enlevée à l'opération était de la grosseur d'un œuf de poule, placée derrière le pylore et le duodénum, sur l'aorte et la veine cave inférieure et n'adhérait ni au rein ni au pancréas. A l'examen histologique effectué par le professeur agrégé I. WALLGREN, la tumeur se révéla être un paragangliome. Un an et neuf mois après l'opération, la malade est en bonne santé sans signes de récidive. Dans la littérature, on ne trouve qu'un cas antérieur (démontré par STANGL en 1902) opéré de paragangliome rétropéritonéal, situé à l'extérieur d'une capsule surrénale. La tumeur reposait sur l'aorte et était située à la bifurcation de celle-ci. On a trouvé à l'autopsie quelques autres cas de tumeurs semblables dans le voisinage des capsules surrénales.

Des tumeurs médullaires des capsules surrénales, il n'y a que celles donnant lieu à une tachycardie paroxystique qui peuvent être diagnostiquées avant l'opération. L'auteur discute les indications, l'étiologie des graves phénomènes de shock à l'opération et la prophylaxie de ceux-ci.

Literaturverzeichnis.

ALÉZAIS und PEYRON: Cit. COENEN. — BERGSTRAND, H.: Hygiea 82: 321: 1920. — BORCH-JOHNSEN, E.: Acta Chir. Scand. 80: 171: 1937. — BRUNSCHWIG und HUMPHREYS: J. am. med. ass. 115: 355: 1940. — CAHILL, G. F.: J. Urol. 34: 238: 1935. — COENEN, H.: Kirschner-Nordmanns »Die Chirurgie« Teil II, 1928 und 1940. — DISTEFANO: Z. org. 71: 1934. — HEDINGER: Cit. HERDE. — HERDE, M.: Langenbecks Arch. f. klin. Chir. 97: 937: 1912. — HOLST: Cit. STRÖMBECK und HEDBERG. — KAWASHIMA: Virchows Archiv f. pathol. Anat. 203: 66: 1911. — L'ABBÉ und DOUMER: Cit. BORCH-JOHNSEN. — LINDE, PAUL: Nord. Med. 1: 897: 1942. — MAYO, CH.: J. am. med. ass. 89: 1047: 1927. — PICK, L.: Cit. COENEN. — STANGL, E.: Wiener klin. Wschr. 23: 1902. — STRÖMBECK, J. P., und T. P. HEDBERG: Acta Chir. Scand. 82: 177: 1939. — SUZUKI, SEIZO: Berl. klin. Wschr. 1644: 1909 und 1623: 1910.

From the Sanatorium Kiljavannummen Parantola.
(Chief: Docent ERKKI LARMOLA, M. D.; Surgeon: Professor P. E. A. NYLANDER, M. D.)

On Extrapleural Pneumolysis in Pulmonary Tuberculosis.

By

P. E. A. NYLANDER,
Professor of Surgery at the University of Helsinki, and
K. KIVIKANERVO, M. D.

Opinions differ regarding extrapleural pneumolysis. TUFFIER is mentioned as the originator of this procedure and various modifications have been used fairly extensively on the continent during the last decade (GRAF, SCHMIDT, BRUNNER, MONOD, KLEESATTEL). In Anglo-American literature we also find a considerable number of publications on this subject from prewar years. At Brompton Hospital this treatment was adopted in 1936. It appears as if less interest was taken in this procedure in the Scandinavian countries, but publications dealing with the question have begun to appear during recent years (HOLST, KJAER, GRAVESEN, GULLBRING, KIVIKANERVO etc.).

It should be noted that the investigations on extrapleural pneumolysis are often based on limited material, in which the time of observation has been comparatively short. There have been many opposers of the method who condemn it altogether (SAUERBRUCH), chiefly on account of the complications associated with it. Some are of the opinion that the procedure should be completed as soon as possible by thoracoplasty (HOYT and TATE), or recommend it as an emergency measure when other active methods of treatment cannot be applied (OVERHOLT, TUBBS, and CHURCHILL). These statements date, however, from the time before the war. Unfortunately it has not been possible for us to follow closely the development of Anglo-American opinion on the subject during recent years.

The following is a report on the conclusions we have arrived at after having used this method of treatment since 1937.[1] For the sake of conformity we here give a series of cases treated at one hospital only; thus the postoperative treatment has been in charge of the same phthisiologist (KIVIKANERVO).

Material.

The material comprises a connected series of 118 pneumolysis cases in 115 patients, 47 men and 68 women. The youngest patient was 13 years of age, the oldest 50. A close statistical distribution of the material will be found in Table I. It shows the type of cases in which this therapeutic method has been applied. As the procedure is, however, fairly new and has been continually further developed, the table does not reveal our present opinion concerning its applicability. When adopting the procedure at the sanatorium, in 1939, we were in the beginning obliged to resort to experience gained elsewhere with regard to the indications, the technique of the operation and postoperative treatment. The principle initially followed was to employ this procedure only in cases where other surgical treatment could not be applied. The early results, often very satisfactory, made us inclined to use the method also in other cases until failures occurred. On the basis of our experience, success as well as failure, we have during the course of years been able to form an opinion regarding the nature of the cases in which pneumolysis should be applied. Our opinion will be reported in detail under the heading "Indications".

Table I.

Patient material.

Men 47, women 68, total 115.
Youngest patient 13, oldest 50 years of age.

	per cent
1. The cases were:	
a) principally productive	52.1
b) » exudative	47.9
2. The time elapsed after the discovery of the disease:	
a) 1—2 years	66.5
b) 3—5 »	12.2
c) more than 5 years	21.3

[1] The first cases operated on by one of the authors (NYLANDER) were described by NORDSTRÖM at the meeting of the Association of Phthisiologists in Finland, in 1938.

	per cent
3. Age of patients:	
a) 11—20	9.7
b) 21—30	44.3
c) 31—40	39.1
d) 41—50	6.9
4. Pulmonary changes:	
A. Size of cavity:	
a) small cavity	50.4
b) plum-sized cavity	43.5
c) apple-sized cavity	6.1
B. Location of cavity and extent of the disease:	
a) cases in which the cavity did not extend below the dorsal insertion of the sixth rib	87.8
b) cases in which the cavity was located below the dorsal insertion of the sixth rib	12.2
c) bilateral cases	49.6

During this time there have been changes with regard to the stating of the indications as well as to the operative technique. A closer survey of the importance of these changes with the purpose of obtaining successful operations will follow later on. The operative technique employed by us may be described as follows:

The operations have been performed under local anesthesia with the patient in the sitting posture. The approach is from the back and an oblique incision is made at the apex of the shoulder-blade on the level of the second or third thoracic vertebra. A piece, 6—8 cm. in length, is removed aperiostally, generally from the fourth, occasionally from the fifth rib, depending on the location of the cavity. Particular care must be attached to the ligation of the blood vessels as well as the careful closure of the approach in strata. In stripping the pleura the loosening of it from the chest wall has been aimed at and the pressure of the pleura inward has been avoided.

Regarding *the postoperative treatment* it may be mentioned that the collapse has been maintained initially by air refills generally later followed by oil. Only in exceptional cases pneumothorax has been maintained until the process in the lung has been healed. In these few pneumothorax cases normal re-expansion of the lung was obtained (See case 1). A successful result in this respect was doubted earlier. Also after oleothorax the lung appears to be able to re-expand fairly well. It may be mentioned here that our opinion as regards establishing extrapleural oleothorax in order to maintain a permanent collapse has been corroborated in the course of years. In a great number of the cases the oil has remained for years in the extrapleural space without causing any noticeable deleterious effect. We here refer to KIVIKANERVO's publication (3). If the lung has been stripped sufficiently far down and no complications have occurred, the postoperative treatment is simple

and easy. We have continually attached importance to the levelling of the air pressure to slightly negative immediately after the operation, which has been pointed out in a previous publication by KIVIKANERVO. High, positive pressures have been avoided as a rule as they have a deleterious effect particularly at the early postoperative stage. (Fig. 1. Fig, 2. Fig. 3.)

Case 1. M. K. ♀, 29 years of age. Pulmonary tuberculosis noted in 1939. General condition good. No fever. Sedimentation rate 53 mm. per hour. Sputum positive. At the apex of the right lung a plum-sized cavity and in the infraclavicular area a weak, sharply demarcated shadow. A similar shadow appears at the left apex (Fig. 1). Pneumolysis performed July 3rd, 1940 (Fig. 2 immediately following the operation). The collapse was maintained by refills of air. In the winter 1945 fresh changes appeared in the left lung, for which reason intrapleural collapse therapy was started. On May 22nd, 1945, a cutting of the adhesions was performed in order to complete the collapse. Extrapleural collapse therapy on the right side was stopped in spring 1945. Fig. 3 after re-expansion of lung.

The results of the treatment are shown in Table II. At the end of the observation period 91 patients survived, of these 67 without bacilli. 24 patients still had positive sputum and most of them were unable to work. The deaths were all so-called delayed cases. *The earliest death took place 3 months after the operation.* Considering that the treatment has been applied often in very difficult cases, in which no other collapse therapy was possible, these results may, in our opinion, be considered rather good. Undoubtedly the results would have been even better during peace conditions. One of the greatest advantages of pneumolysis is that bilateral collapse treatment is possible on account of excellent selectivity. In several cases, owing to war-time difficulties, the processes in the opposite lung, appearing at a later date, could not be treated in time. The question of bilateral collapse treatment will be dealt with later on in this paper.

Table II.

Results of treatment.

	per cent
1. Results of treatment with regard to survivors:	
a) open	25.7
b) closed	74.3
c) capable of work, fully or partially	68.5
2. Mortality:	
a) early deaths (time of observation 3 months after operation)	0.0
b) later deaths	20.9
(among these are included one man, fit for active service, killed in the war, one patient died of renal disease, and one of acute pneumonia 2 years following the operation).	

A short casuistic summary of the deaths and the cases in which tubercle bacilli were still found in the sputum is given below:

In three cases, as mentioned above, death was caused neither by the operation nor by tuberculosis. In eight cases death may be attributed to the operation, six of them on account of a bronchial fistula, two because of further activation of the process. In the remaining thirteen cases the cause of death was pulmonary tuberculosis. Of these several were cases in which the disease had reached such an advanced stage that operative treatment was too late. In some cases the disease grew worse on the operated side probably owing to defective collapse, but in eight cases at least the process in the opposite lung first showed signs of deterioration. In several of them bilateral collapse therapy was not possible to start in time. (The sanatorium was evacuated twice to give room to wounded soldiers.)

At the end of the observation period 24 patients still had positive sputum. In eight cases the collapse may be considered fully satisfactory: apparently the bacilli came from the opposite lung. In some of these cases a collapse therapy has been recently started or is planned on this side. In the remaining cases some complication (tuberculous infection of the space, perforation of the lung, haemothorax) or the appearance of adhesions must be considered the cause of defective collapse.

In the following some views are given based on experience gained during these years as regards indications, operative technique and postoperative treatment. We also wish to express our opinion regarding the possibilities of developing the procedure further.

Indications.

The possibilities of success at the start of active treatment very greatly depends on the general power of resistance of the body. It is therefore necessary to attempt to improve the general condition as much as possible prior to operative treatment. This holds good also with regard to extrapleural pneumolysis.

The nature of the disease which may be considered to be much influenced by the general resistive power of the body, plays an important part from the point of view of stating the indications for a pneumolysis. Productive forms of the disease are suitable for being treated by pneumolysis. On the other hand, severe complications, in particular specific extrapleural empyemas, often appear in connection with exudative types of the disease. In every third case, approximately, a tuberculous infection arises in the extrapleural space and 10—15 per cent. of them later develop into empyemas. These extrapleural empyema cavities generally

heal, but often at the cost of the collapse, which of course jeopardizes the result of the treatment. We have found that extrapleural empyemas are more stubborn in exudative than in productive forms of the disease. Thus, the exudative character of the disease is an important contraindication to pneumolysis. No other surgical methods of collapse can be employed, as a rule, in these exudative forms. Therefore the application of pneumolysis must be taken into account if conditions are favourable in other ways, for instance as regards the location of the cavity, and if no severe extrapleural formations of inelastic fibrous tissue are present. It may be mentioned that bronchogenic disseminations and pneumonias occur much more often in connection with thoracoplasty than with pneumolysis. Comparing these two methods of operation one of the authors has found that bronchogenic disseminations and pneumonias are encountered three times more often in connection with the former. This in spite of the fact that the cases where a thoracoplasty was applied were of less exudative character and the disease was not so far advanced as in the cases in which pneumolysis was performed. *Even if the exudative types of the disease are not suitable to be treated by means of pneumolysis, yet the application of this collapse therapy opens increased possibilities for the treatment of these exudative types,* as the drawbacks arising in the form of extrapleural empyemas are much less pronounced compared with the disseminations and pneumonias appearing in connection with thoracoplasty.

In addition to the nature of the disease, the suitability of the collapse therapy depends on the *type of cavity,* and particularly on *its location and size.* Already before the introduction of pneumolysis there were divergencies of opinion as regards the general indications for collapse therapy, whether pneumothorax should always first be attempted in cases of thick-walled, so called tertiary cavities and thoracoplasty applied only after the failure of the former (Graf, Gullbring, Törning, etc.), or whether in these cases attempts at pneumothorax should be entirely abandoned and a thoracoplasty always performed at once (Sauerbruch, Schmidt, Kremer). The supporters of the latter opinion have stressed that such rigid-walled cavities are difficult to bring into collapse by means of pneumothorax and that they also show a very poor cicatrization capacity, and should therefore be brought into permanent collapse by performing a thoracoplasty. After the introduction of extrapleural pneumothorax Schmidt consistently

maintained that the most ideal method of collapse in cases of tertiary cavitation was a thoracoplasty, whereas thin-walled secondary cavities were more suitable to be treated by extrapleural pneumothorax. Only in cases where a thoracoplasty was contraindicated pneumolysis was in his opinion to be used also in cases of tertiary cavitation.

When treating cases of thick-walled tertiary cavitation by the pneumolysis method we have found that the cavities close comparatively well, if only the lung is loosened far enough. The stripping is, however, often rendered difficult by the adhesions that have had time to develop in this kind of old processes. We shall return to them later on in another connection. As for the poor cicatrization capacity of tertiary cavities, we are of the opinion that great importance should not be attached to it, because the extrapleural pneumothorax may be converted into permanent oleothorax if necessary. Thus, *the type of cavity wall is of importance only on account of compromising adhesions appearing more often in connection with old thick-walled cases than in connection with fresh thin-walled cavities.*

The question *whether the cavity is located near the surface of the lung or deeper in the lung tissue* seems to be particularly important. The greatest disadvantage of pneumolysis is the appearance of lung perforations, the cause of which has not yet been fully revealed. In the first instance one might think that the perforations are due to ischemic necrotic formation on the surface of the lung when the cavity is cortical and dense adhesions are present. In one case of pneumolysis, in which stripping was difficult, a bronchial fistula appeared at a later period. On opening the extrapleural space we found, on the surface of the lung, areas indicating necrosis. Although we can produce no histologic proofs, we have arrived at the same opinion as HOYT and TATE, that in cases with long duration the tissue overlying the cavity may derive some of its blood supply through the endothoracic fascia, so that separation of the parietal pleura may interfere with blood supply and allow rupture of cavities by necrosis. *Thus it seems advisable to refrain from pneumolysis in cases where the cavities are located mainly on the surface and moreover adhere strongly to the chest wall.* The same applies to cases with particularly large cavities. In the seven cases among our patient material, in which the cavity was of the size of a small apple, perforations appeared three times, whereas perforations in the whole material reach only

the figure of 7.7 per cent. Taking these circumstances into account in stating the indications we have been able during these years to bring about a considerable decrease in the appearance of perforations. While there were 18.6 per cent. of such cases in 1939—40, the corresponding figure in the following years averaged 4.5 per cent.

Theoretically it would seem possible to prevent entirely the appearance of lung perforations by avoiding operation in cases where the cavity is very superficial and at the same time adherent to the chest wall. At present investigation methods are still unsatisfactory and these facts cannot be determined with absolute certainty in border cases. It is of course possible to use Monaldi's cavity suction method together with a thoracoplasty. If this is contraindicated pneumolysis must be considered, as an extreme measure, because the superficiality of the cavity, especially if there are no dense adhesions, does not necessarily cause a perforation. It may be mentioned that GRAVESEN has since 1939 used an apicoplasty combined with extrafascial pneumo-oleothorax in cases not suitable for pneumolysis because of the risk of a cavity perforation arising.

As known, the treatment by thoracoplasty of cavities located especially in the anterior part of the lung presents certain difficulties (*e. g.* DENK, GULLBRING, KIVIKANERVO). On the other hand, there is nothing to prevent the application of pneumolysis in this respect. In pneumolysis the difficulties in establishing a collapse increase if the cavity is located lower down. Although a total stripping of the lung is performed, the extrapleural space created often contracts at the base and the treatment may be unsuccessful. When thoracoplasty has been contraindicated we have applied pneumolysis with success in special cases, the cavity being located as low down as at the level of the eighth rib. An example of this is Case 2. If pneumolysis in two stages were employed — the possibility thereof is described later on in this paper — the low location of the cavity would no longer be of importance. (Fig. 4. Fig. 5.)

Case 2. K. K. ♀, 27 years of age. Pulmonary tuberculosis since 1941. General condition good. No temperature. Sedimentation rate 29 mm. per hour. Sputum positive. In the upper and central field of the left lung two about plum-sized cavities, the lower extends caudally to the level of the dorsal insertion of the eighth rib. In the upper and central field of the right lung a slight mottled shadow appears (Fig. 4). In Fig. 5 both cavities are seen fully closed by operation.

Fig. 1.

Fig. 2.

NYLANDER and KIVIKANERVO: Extrapleural Pneumolysis.

Fig. 3.

Fig. 4.

Fig. 5.

Fig. 6.

NYLANDER and KIVIKANERVO: Extrapleural Pneumolysis.

Fig 7.

Fig. 8.

The importance of *adhesions* has been dealt with when speaking of the type of the cavity and its superficial location and should be emphasized once more in connection with the indications. The adhesions may cause lung perforations and even actually prevent the application of pneumolysis. As they may misleadingly resemble atelectiasis in an ordinary roentgenogram it is difficult to distinguish them beforehand, but *in clear cases where the patient is known to have had serious pleural affection, for instance in connection with pneumothorax, pneumolysis must be considered contraindicated.* (Fig. 6. Fig. 7. Fig. 8.)

Case 3. M. S. ♀. Age 22. Pulmonary tuberculosis since 1938. General condition good. No temperature. Sedimentation rate 16 mm. per hour. Sputum positive. In the upper lateral part of the left lung field a thin-walled cavity of the size of a small plum. Also at the right apex slight mottled appearance (Fig. 6). June 1st, 1939, pneumolysis l. sin. In 1944 a cavity of the size of a large plum appeared at the right apex (Fig. 7). April 5th, 1945, pneumolysis l. dx. Fig. 8 taken September 1945.

The possibilities of treating *bilateral pulmonary tuberculosis* have greatly increased since the introduction of extrapleural pneumolysis therapy. Earlier the possibilities for active treatment were fairly limited in these cases, if pneumothorax could not be applied. In pneumolysis the healthy lung tissue is preservable to greater extent than in any other surgical collapse therapy. It is possible to carry out pneumolysis on both sides (see Case 3), or only on one side and apply some other collapse therapy for the treatment of the collateral lung. As seen from Table III bilateral collapse treatment has been possible in 16.6 per cent. of the cases of this material. Acute or chronic respiratory insufficiency was not noticed in any of the cases. It may be pointed out that bilateral collapse treatment in connection with thoracoplasty at the sanatorium reached the figure of only 2.5 per cent during the same period. Our experience as regards the selectivity of pneumolysis convincingly shows that the application of this method in bilateral cases may be extended considerably.

Table III.

Additional collapse treatment.

	per cent
1. On the contralateral side:	
a) Intrapleural pneumothorax	13.9
b) Extrapleural »	1.9
c) Thoracoplasty	0.9
2. On the operated side:	
a) Exhairesis n. phrenici	6.1
b) Thoracoplasty	6.1

Pneumolysis seems to cause *but slight disturbance in the circulatory system.* In a comparative study by one of the authors regarding postoperative dangers in thoracoplasty and pneumolysis, in connection with the former more or less serious circulatory disturbances appeared in 9.2 per cent of the cases; after pneumolysis slight disturbances occurred only in 1.7 per cent. The explanation of this appears to be pneumolysis not causing the same kind of pathologic conditions as thoracoplasty because the thorax remains practically intact. Postoperative shock is often very slight, as has been emphasized in the literature. *Thus pneumolysis therapy may be used also when the function of the circulatory system is no longer quite normal.* The application of pneumolysis on individuals of a more advanced age is thus possible. The oldest patient in our material was 50 years of age. It seems possible, however, to raise the age limit considerably in suitable cases.

When considering the appropriateness of pneumolysis therapy attention must be paid also to bronchial diseases, specific as well as non specific. We have often noticed that *such cases, in which expectoration has become difficult and severe coughing appears, are more often followed by further complications.* One might think that in particular *stenosal bronchial diseases* predispose the patient to such attacks of coughing.

Finally it may be added that *the results have generally been more satisfactory in women than in men;* this fact should perhaps also be given some consideration when stating the indications.

Operative Technique.

In the beginning we carried out the stripping of the lung in a rather limited area. As the collapse was unsatisfactory and difficult to maintain we soon found that more extensive stripping was called for. The results are more certain and postoperative treatment is easier if the loosening of the lung is extended in all directions as far down as possible. At one point only, *i. e.* when loosening the lung from the mediastinum, an exception should be made. Earlier we regularly separated the lung completely from the mediastinum as far as the hilus. Opinions differ with regard to the extent of the stripping at this point. GRAF has especially stressed the fact that the lung may not be separated medially as far as the hilus because the cavitation area of the lung will

drop down to the floor of the space and will not contract as well as might be possible. Later we began to approach GRAF's opinion as regards this point and followed his procedure at first only in certain cases, *i. e.* when the cavity was located fairly low laterally. In the last years we have made it a rule *to leave the lung unstripped some distance above the hilus.* The part of the lung where the cavity is located now remains hanging above the hilus. The cavity may be compressed against the mediastinum and will not drop to the floor of the space where there is no fixed base for compression. In exceptional cases, when the cavity is located directly above the hilus the stripping must of course be carried out as far as the hilus medially in order to mobilize the cavitation area. The stripping at other points must in these cases be undertaken as completely as possible in order to eliminate the danger of the cavity dropping to the floor of the space. Earlier, when we did not attach enough importance to this fact, three cases occurred in which the cavity that had moved too far down owing to the medial stripping of the lung, reached the floor of the pneumolysis space, and in two of these cases closure was not possible even by additional collapse treatment.

Extrapleural scar-like adhesions were present in various degrees in this material in 24 cases. When dividing these adhesions great care is recommended as it is possible to damage the lung and to cause a rupture of the cavity if it is located near the adhesion. We have generally separated the surroundings of the adhesion first and only as a final measure the adherence itself either by preparing the way bluntly or by cutting; both ends must be ligated carefully. In one case a perforation of the cavity occurred when dividing the adhesions and in seven cases the pleura was damaged; in three of the latter an extensive intrapleural pneumothorax arose in consequence thereof in the lower part of the lung and subsequently severe asphyxia set in. *We subsequently observe great care in the division of the dense extrapleural adhesions and our opinion of the advisability of abandoning pneumolysis rather than attempting it with violence in the presence of such adhesions has become corroborated.*

The extrapleural space is susceptible to secondary infection. It is not known for certain from where these infections arise. Some authors are of the opinion that they originate in the stripping area (MUTSCHLER), others again consider them exogenic (GRAF). In the beginning we noted a fairly great number of these infec-

tions, but during the last years they have been rare. These infections having been caused by pus bacteria speaks for their exogenic character in our opinion. Thus it is not surprising that various authors find perfect asepsis essential. We join OVERHOLT and TUBBS in stating that obviously "extreme care should be taken in maintaining absolute asepsis as infection in the pneumothorax space is likely to prove disastrous". While treating this series we have had no opportunity of using penicillin which in the future will no doubt improve the success of the treatment.

Postoperative Treatment.

Fluid, hemorrhage or exudation are always present in the pneumolysis space in various degrees. If they are particularly abundant they must be considered complications because they have a disturbing effect on the healing of the space and render postoperative treatment difficult. Hemorrhage generally appears on the first and second postoperative day. The exudation usually reaches its limit within a few days following the operation, then decreases slowly and ceases completely in many cases within four weeks on an average, at which time the space is dry. In the meantime the surfaces in the wall have changed into capsula containing fibrous tissue which can scarcely be distinguished macroscopically from an ordinary pleural leaf. The appearance of the superficial cellular layers of this capsule has become changed in a certain respect. Also their function has changed in that they now tolerate the action of air. In ordinary cases the space remains dry and the collapse can be maintained by means of air refills similarly as in intrapleural pneumothorax. This may be considered the ideal development of the wall of the pneumolysis space. All cases do not, however, present this simple development. There are often complications which render postoperative treatment difficult and may jeopardize the result. The most essential question in postoperative treatment is how to deal with these complications. In the ideal cases mentioned above treatment is simple.

The complications may be divided into two groups according to their order of appearance. The first group includes *large postoperative hemorrhages, non-specific infections and particularly strong formation of exudate,* all of which appear fairly soon after the

operation as has been mentioned already. The second group comprises *specific infections and perforations of the lung* which arise later, usually 6—9 weeks following the operation. Hemorrhages render postoperative treatment difficult because coagulations as a rule occur in connection with them. It may be difficult to remove these coagulations from the space, and if left there, they disturb the process of healing and the maintenance of the collapse. In these cases of hemorrhage the healing is disturbed especially if other complications occur simultaneously, particularly specific infections. Maintaining the collapse becomes difficult owing to hemorrhage because the blood clot in process of organization on the floor of the pneumolysis space causes the space to become obliterated. By means of a careful operative technique it is possible to keep the appearance of these hemorrhages within reasonable limits. In some of the hemorrhage cases, especially when aspiration has been performed at the early postoperative stage, no blood clot appears, but occasionally such extensive coagulations are formed that they cannot be removed even with a catheter.

If it were possible to find some means of eliminating the drawbacks due to blood clot a great improvement in this therapy would be attained. Attempts have been made to infuse oil into the space during the operation but according to our opinion it is not possible to prevent coagulation thereby and it has also proved deleterious in other ways. Additional pneumolysis might be performed if the space seems likely to become obliterated owing to blood clot. As seen from Table III the collapse created by means of pneumolysis has been completed either by thoracoplasty or by phren. exhairesis in 12.2 per cent. of our cases on account of the obliteration of the space. An additional pneumolysis of this kind appears to be a more reliable and, at least compared with thoracoplasty, a less dangerous measure. As it must be carried out at an early postoperative stage before the lung has had time to become too adherent owing to the formation of the pneumolysis capsule, the procedure may be considered only in clear cases where coagulations are abundant and the danger of obliteration is evident. In border cases it is advisable to refrain from this measure and perform phren. exhairesis or later on a thoracoplasty, if required. The most suitable time for additional pneumolysis seems to be about a fortnight after the first operation, at which date lung reactions have usually disappeared. The

blood clot has not yet had time to become fully organized and is still removable and specific infections have not yet arisen in the space, where they — in case of blood clot — develop into severe extrapleural empyemas. So far we have tried to complete the pneumolysis in this way in one case which was successful. We have not observed any reference in the literature as regards the possibility of employing a 2-stage pneumolysis. As mentioned earlier, we have unfortunately not had the opportunity of obtaining Anglo-American papers during the past 2—3 years.

As regards the cases in which a sterile exudate persists week after week, pneumothorax must be converted into oleothorax at an early date.

Specific infections, although very numerous, cause extrapleural tuberculous empyemas only in 10—15 per cent of these cases of infection. For their treatment we have employed gomenol-paraffin oil either alone or together with azochloramide rinses. In very severe cases a removal of air from above the oleothorax is recommended with a view to relaxing the lung and diminishing the purulent surfaces of the space. Usually the treatment of these empyemas is much easier than that of intrapleural empyemas. Only if extensive blood clot is present or the disease has been very exudative these empyemas also are very stubborn.

The most dangerous complication is a *bronchial fistula*, for which no reliable remedy has so far been found. Therefore it must be attempted in these cases to state the indications with a view to limiting the occurrence of fistulas as much as possible.

Finally, speaking of the postoperative treatment, we wish to *call attention to the time at which the use of oil should begin*. It may take place too late, when the obliteration of the space is far advanced, or too early, in which case superpressure in the space may arise owing to exudation. We have noticed that obliteration of the space occurs only in certain cases. A space which has dried up and remains dry is healed and no obliterations will occur. *If, on the other hand, fluoroscopy reveals even a small amount of fluid in the space, it is a sign of a state of irritation, due to various causes, and indicates that obliteration is in progress.* The use of oil must not be delayed in a case like this. The drying up and the healing of the space seems to take on an average four weeks, and we consider this period a kind of time limit for converting pneumothorax into oleothorax.

Summary.

The authors present experience gained by the pneumolysis method based on a connected series treated in the years 1939—1944. The material comprises a total of 118 pneumolyses on 115 patients. In the greater number of the patients the disease was far advanced and a thoracoplasty could not be performed. About 50 per cent had bilateral disease. 71.1 per cent of the patients survived and 74.3 per cent of them have no bacilli and are able to work.

The authors stress the importance of preoperative treatment on conservative lines. It is, however, less important in pneumolysis than in thoracoplasty, as the former may be applied also in comparatively fresh cases urgently requiring quick active collapse therapy. Fresh thin-walled secondary cavities are more suitable for treatment by pneumolysis than thick-walled tertiary cavities. In connection with the latter extrapleural adhesions of inelastic fibrous tissue develop, which are separable with difficulty. There is great danger attached to the treatment by pneumolysis of large cavities extending to the surface layers of the lung and extensively adhering to the thorax wall. Various kinds of severe pleural affections cause such compromising adhesions as to render pneumolysis impossible.

As a tissue-preserving procedure the pneumolysis method has extended our therapeutical possibilities in bilateral cases.

Pneumolysis causes very little disturbance in the function of the circulatory system and may thus be employed in the treatment of older persons and also in other cases in which circulatory function is not quite normal.

In the technique three things must be observed in particular: the stripping is to be extended as far as possible in all directions, with the exception of the loosening of the lung from the mediastinum, which should be stopped some distance above the hilus. Operation hemorrhages should be checked with care. Extreme sterility is necessary during the whole procedure.

Postoperative treatment is simple in normal cases. Complications arise often but they are generally fairly easily treated, excepting the perforations of the cavity. The frequency of these perforations may be greatly reduced by stating the indications correctly. — Extrapleural pneumothorax should, in most cases, be converted into oleothorax.

The very small primary mortality (no deaths during the observation period of 3 months) is an encouragement to develop the procedure further.

The authors have also studied the possibilities of carrying out pneumolysis in two stages. The second operative stage may be either planned beforehand or a completion of the first operation in certain cases in order to eliminate the danger of the space becoming obliterated.

Zusammenfassung.

Verff. berichten an Hand einer in den Jahren 1939—44 behandelten, fortlaufenden Serie über ihre Erfahrungen mit der extrapleuralen Pneumolyse. Das Material umfasst 118 Pneumolysefälle an 115 Patienten. Die Mehrzahl der Kranken litt an einem tuberkulösen Prozess in einem Stadium, wo eine Thorakoplastik nicht infragekommen konnte. Etwa 50 % hatten Veränderungen in beiden Lungen. Von den Kranken sind 79.1 % am Leben, darunter 74.3 % bazillenfrei und arbeitsfähig.

Verff. betonen die Wichtigkeit der konservativen Behandlung. Diese ist bei der Pneumolysebehandlung jedoch nicht von ebenso grosser Bedeutung wie bei der Thorakoplastik, und erstere Methode kann auch bei verhältnismässig frischen Fällen Verwendung finden, die einer baldigen aktiven Kollapsbehandlung durchaus bedürfen. Frische, dünnwandige sog. Sekundärkavernen eignen sich besser für die Pneumolyse als dickwandige Tertiärkavernen. Bei letzteren sind oft schon extrapleurale Verwachsungsschwarten entstanden, die schwer zu lösen sind. Besonders gefährlich mit Pneumolyse zu behandeln sind grosse Kavernen, die sich bis an die oberflächliche Schicht der Lunge erstrecken und mit der Wandung der Brusthöhle breit verwachsen sind. Alle Arten von schweren Pleuraaffektionen geben so feste Verwachsungen, dass sie die Pneumolyse unmöglich machen.

Als eine das Lungengewebe schonende Methode hat das Pneumolyseverfahren unsere Möglichkeiten, doppelseitige Fälle zu behandeln, erweitert.

Da die Pneumolysemethode die Kreislaufsorgane nur in sehr geringem Masse anstrengt, kann sie bei der Behandlung älterer Leute infragekommen, sowie ferner wenn die Funktion der Kreislaufsorgane sonstwie nicht völlig normal ist.

Was die Technik anbelangt, sind in erster Linie drei Faktoren zu beachten: Die Ablösung muss möglichst radikal in allen Richtungen stattfinden. Doch wird die Lunge in dem unmittelbar oberhalb Lungenhilus gelegenen Gebiet gewöhnlich nicht vom Mediastinum abgelöst. Die Blutstillung muss eine sorgfältige sein. Bei der Ausführung ist die sorgfältigste Sterilität zu wahren. Die Nachbehandlung ist in Normalfällen einfach. Oft treten trotzdem Komplikationen auf. Diese sind, mit Ausnahme der Kavernenperforationen, verhältnismässig leicht zu behandeln. Das Vorkommen von Komplikationen lässt sich jedoch mit Hilfe der Indikationsstellung wesentlich einschränken. Der extrapleurale Pneumothorax muss später oft in einen Oleothorax verwandelt werden.

Die äusserst geringe Primärmortalität der Pneumolysemethode (bei den Verff. in 3 Monaten 0.0 %) scheint zu fortgesetzter Entwicklung der Methode zu mahnen, so dass die Indikationen derselben genauer festgestellt und spätere Komplikationen vermieden werden können.

Die Verff. besprechen auch die Möglichkeit einer zweizeitigen Pneumolyse. Der zweite Eingriff könnte hierbei entweder im Voraus geplant sein, oder in gewissen Fällen eine vervollständigende Operation darstellen, um der Gefahr einer Obliteration der Höhle zu begegnen.

Résumé.

Les auteurs exposent leurs expériences concernant la pneumolyse extra-pleurale, faites sur une série de cas traités pendant les années 1939—44. Leur matériel comprend 118 cas de pneumolyse chez 115 malades. La majeure partie des malades étaient affectés de processus tuberculeux à un stade contre-indiquant la thoracoplastie. Chez 50 % environ des malades, les deux poumons étaient atteints. Des 79.1 % qui ont survécu, 74.3 % sont bactériologiquement stériles et aptes au travail.

Les auteurs soulignent l'importance d'un traitement préparatoire conservateur. Il n'a cependant pas une aussi grande importance dans le traitement par pneumolyse que dans la thoracoplastie et le procédé peut être appliqué dans des cas relativement récents chez lesquels la collapsothérapie s'impose de façon urgente. Des cavernes fraîches à parois minces se prêtent mieux à la pneumolyse que les cavernes tertiaires à parois épaisses. Il arrive souvent que ces dernières ont donné lieu à la formation d'adhérences

extra-pleurales couenneuses qui sont difficiles à détacher. Mais ce sont les grandes cavernes s'étendant aux couches superficielles du poumon et largement adhérentes à la paroi thoracique dont le traitement par pneumolyse est le plus dangereux. Les adhérences épaisses que laissent toutes les affections pleurales graves sont une contre-indication absolue à la pneumolyse.

La pneumolyse est un procédé ménager du tissu pulmonaire qui nous a fourni une nouvelle possibilité de traitement des affections bilatérales. Comme il ne surmène pas la circulation, on peut l'utiliser chez les vieilles personnes et dans les cas de méiopragie circulatoire modérée.

En ce qui concerne la technique, trois facteurs sont spécialement importants: détacher les adhérences complètement dans toutes les directions. Cependant on évite de libérer le poumon du médiastin dans la section située immédiatement au-dessus du hile. L'hémostase doit être soignée. Et la stérilité doit être parfaite.

Dans les cas normaux, le traitement postopératoire est simple. Cependant il se produit souvent des complications. Sauf la perforation de cavernes, elles sont faciles à traiter. Mais on évite nombre de complications par des indications bien fondées. Il faut souvent postérieurement transformer un pneumothorax en oléothorax.

La mortalité primaire très réduite (0.0 % pendant trois mois chez les auteurs) semble encourager un développement de la méthode visant à préciser davantage ses indications de façon à éviter des complications ultérieures.

Les auteurs discutent également la possibilité d'une pneumolyse en deux étapes. La seconde étape serait soit une opération prévue d'emblée, soit surtout une opération complémentaire réservée aux cas où il s'agit d'écarter le danger d'une obturation de la cavité.

References.

Adelberger, L.: Beitr. Klin. Tbk. usw. 1939: 93: 413. — Adelberger, L.: Beitr. Klin. Tbk. usw. 1941: 93: 413. — Brunner, A.: Acta Soc. Med. Fenn. Duod. 1941: 31: 52. — Brunner, A.: Beitr. Klin. Tbk. usw. 1941: 97: 34. — Churchill, E. D.: J. Thorac. Surg. 1938: 7: 586. — Denk, W. & Domanig, E.: Beitr. Klin. Tbk. usw. 1931: 77: 320. — Graf, W.: Beitr. Klin. Tbk. usw. 1936: 88: 324. — Graf, W.: Chirurg. 1938: 9: 297. — Graf, W.: Beitr. Klin. Tbk. usw.

1941: 97: 479. — GRAVESEN, J.: Nordisk Medicin 1940: 15: 723. — GULLBRING, A.: Hygiea. 1942: 104: 665. — HOLST, J.: Forhandl. ved nordisk kirurgisk forenings mode i Oslo 1939. — HOYT, W. FENN and TATE, J. C.: J. Thorac. Surg. 1941: 10: 551. — KIVIKANERVO, K.: Wien. med. Wschr. 1941: 48: 957. — KIVIKANERVO, K.: Acta tbc. scand. 1942 Suppl. VIII. — KIVIKANERVO, K.: Acta tbc. scand. 1944: 2—4: 262. — KJAER, TAGE: Nordisk Medicin 1940: 15: 717. — KLEESATTEL, H.: Erg. Tbk. forsch. 1939: 9: 453. — KLEESATTEL, H.: Z. Tbk. 1941: 86: 280. — KREMER, W.: Beitr. Klin. Tbk. usw. 1933: 83: 675. — MONOD, O.: J. Thorac. Surg. 1939: 8: 150. — MUTSCHLER, S.: Arch. klin. Chir. 1938: 193: 107. — OVERHOLT, R. and O. TUBBS: J. Thorac. Surg. 1938: 7: 591. — SAUERBRUCH, F.: Arch. klin. Chir. 1938: 193: 456. — SCHMIDT, W.: Beitr. Klin. Tbk. usw. 1936: 88: 689. — SCHMIDT, W.: Beitr. Klin. Tbk. usw. 1938: 91: 121. — TÖRNING: Nordisk Medicin 1940: 15: 723. — TUFFIER, TH.: According to other authors.

From the County Hospital at Kuopio.
(Chief: Professor M. HÄMÄLÄINEN, M. D.)

On the Treatment of Periappendicular Abscesses, Particularly with Regard to their X-Ray Therapy.

By

T. GUNNAR NYSTRÖM.

Definition, Introduction.

A definition of ideas is given to begin with. The author purposely has chosen the older denomination periappendicular abscess to denote a disease condition, where a sharply defined, palpable resistance border was stated over or close to the appendix region. In a few cases the tumour was not detected until at an examination per rectum or at palpation under narcosis. The abdomen for the rest was soft, no tenderness, and no signs of peritoneal irritation. The patient's general state was satisfactory. Consequently cases of acute appendicitis with circumscript peritonitis without a clinically clearly defined resistance border are not included in this paper.

The treatment of periappendicular abscesses has run along three main lines: a purely conservative, expecting, an operative, where the interference consisted in opening and draining the suppurative focus and a radical operative one, whereat the pus was removed and the appendix extirpated. Different opinions were previously propounded, which one of these methods of treatment was best. The development, however, seems to have taken such a trend, that conservative measures are nowadays chosen as a rule and operative interferences taken recourse to only in case the abdominal symptoms are growing worse or the general state points towards a stronger peritoneal irritation. Some surgeons anyway still recommend more radical primary measures.

In the years 1936 and 1937 a method of treatment was introduced in the County Hospital at Kuopio, which according to the literature and verbal inquiries seems to be but little known, wherefor a brief report may be considered justified. In cases of periappendicular abscess, where the conservative line was selected besides keeping the patient in bed and application of ice-bag, the abscess was radiated with X-rays once or twice, seldom more often. The dosis was 150—200 r (Distance 30 cm, ma 4 KV 140). Copper-aluminiumfilter was generally used. In case two or more treatments were given the interval between them varied between one or two days to one, at most two weeks, depending upon the local and general state of health. This method of treatment has been applied upon adults as well as children, men as well as women.

Material.

320 cases of periappendicular abscess were treated in the County Hospital at Kuopio during a period of 15 years, from 1930 to 1944. The distribution of the cases upon different years as well as sex is shown by Table 1. As appears by the table the cases are very evenly grouped with regard to sex. The frequency during the various years is also comparatively even. The low figure for the year 1941, probably is due to the outbreak of the war. The size of the abscess was stated in 236 cases (Table 2). As seen by the table the small abscesses are represented in 103 cases or in 43.7 per cent, the medium sized in 91 cases or 38.5 per cent and the big ones in 42 cases or in 17.7 per cent. Table 3 shows the methods of treatment. These figures do not fully correspond with those found in Table 1, owing to the circumstance that the conservative line was used to begin with, but operations anyway later on became necessary. One and the same case may thus occur in different groups.

One notices how the combined method, conservative treatment — radiation with X-rays, after a cautious commencement in 1936 and 1937 gradually becomes predominant in the statistics. By reason of the good results attained, the method has fortified its position and is nowadays prevailing in most cases of periappendicular abscess formation.

Some words on the lethal cases in the course of the years. Three of the purely conservatively treated cases terminated in death,

Table 1.

Distribution of cases.

	1930	1931	1932	1933	1934	1935	1936	1937	1938	1939	1940	1941	1942	1943	1944	Total
Men	8	9	12	8	20	14	10	14	8	7	18	6	10	8	14	166
Women	10	14	14	9	7	13	8	3	6	13	13	5	18	9	12	154
Total	18	23	26	17	27	27	18	17	14	20	31	11	28	17	26	320

Table 2.

Size of abscess.

Size	1930	1931	1932	1933	1934	1935	1936	1937	1938	1939	1940	1941	1942	1943	1944	Total
Hen's egg or smaller ...	5	2	7	2	4	5	10	10	5	9	18	6	11	6	3	103
Fist	7	3	6	5	8	9	4	4	6	8	5	2	10	6	8	91
Bigger than a fist	1	1	1	4	8	4	1	1	3	3	3	2	3	5	2	42
Total	13	6	14	11	20	18	15	15	14	20	26	10	24	17	13	236

Table 3.

Treatment.

	1930	1931	1932	1933	1934	1935	1936	1937	1938	1939	1940	1941	1942	1943	1944	Total
Conservative	14	21	22	15	18	23	16	14	3	6	2	2	3	3	4	166
Incisio + canalisatio ..	3	2	4	2	7	3	1	1	1	—	—	4	3	3	3	37
Incisio + canalisatio + app.ectomia	1	—	—	—	2	1	1	—	—	1	—	—	—	1	4	11
Conservative + X-ray treatment .	—	—	—	—	—	—	1	3	10	13	29	7	23	11	16	113
Total	18	23	26	17	27	27	19	18	14	20	31	13	29	18	27	327

one of them in 1935 and two in 1936. A man aged 18 was admitted to hospital in 1935, highly septic, and very feverish. He was treated with ice-bag but died after having been 22 days at hospital. In the first case in 1936 it was the question of a boy

aged 14 with an abscess the size of a fist. He was treated for 25 days with ice-bag, at times afebrile, the abscess slowly subsided. After having been at home in bed for some time he was again admitted in a considerably worse state. Appendicectomy was performed. He was subfebrile the whole time after the operation, with a pulse of 120/min. and died after having been 46 days in hospital. Septic endocarditis was considered to be the cause of death. In the second case it was the question of a woman aged 74, with cardiac insufficiency and bronchopneumonia and a small resistance in the region of the appendix. She was treated with ice-bag and died on the 8th day from cardiac insufficiency. In all these cases the result probably had been the same irrespective of the treatment. The conservative therapy cannot be considered the cause of the lethal termination.

Seven out of the 41 cases primarily operated upon led to exitus. In four cases death was due to peritonitis, in one case to emboli, in one to coma diabeticum and in one case to thrombophlebitis with pneumonia. No comments are needed in these cases. Three of the cases, treated conservatively and radiated with X-rays besides, terminated in exitus. They are going to be discussed in detail later on. Thus 13 cases out of the 320 terminated in exitus, equal to a mortality of 4 per cent, which must be considered low.

Discussion.

By using X-ray treatment in inflammatory processes we strive to attain a limitation of the disease focus. Our intention is, to excite the surrounding tissue to an increased barrier formation. The speed at which the blood corpuscles wander towards the affected place is more rapid by reason of the vessel dilatation and newformation. Such is the case also when a periappendicular abscess is radiated. The limitation, the formation of adherences towards a free abdominal cavity is rendered more secure thereby. It may be stated that the peritoneal symptoms at a periappendicular abscess surrounded by slight peritoneal irritation, subside one or two days after X-ray treatment, until they disappear gradually altogether. A resorptive effect of the X-ray radiation on the abscess is also observed as a rule. The suppurative focus rapidly vanishes in most cases, it melts away like snow in the spring sun. The temperature generally remains elevated for some

days after the first treatment to fall then suddenly in conformity with the resorption of the abscess. It sometimes even happens that the fever increases somewhat in the beginning as a sign of the irritating effect of the X-ray treatment. The red-cell sedimentation reaction and the leucocyte number follow the temperature curve. X-ray treatment also plays a rôle in cases, where signs of an ensuing intra-abdominal abscess are met with subsequent to an operative interference. It is often possible to stop the process without a new operation. X-ray radiation besides is an asset when we attempt to make a deeper periappendicular abscess "ripe" for incision, if one may use the expression.

As a general rule may be said, that a cautious X-ray treatment in periappendicular abscesses contributes to a more rapid resorption of the abscess thus sparing the patients from hospital stay of often long duration, thereby lessening their expenses as well as those of the hospital.

The question naturally arises as to which are the disadvantages, the dangers of X-ray treatment of periappendicular abscesses. In women the radiation — inspite of the cautious dosage — may of course exercise an unfavourable influence on the ovarian function. Menstruation disturbances, neither by way of hemorrhages nor amenorrhea, however, have not been met with. Anyway, a certain caution is naturally justified when it is the question of women. Neither eczema nor any other skin affections have been observed. According to the author the greatest danger of this method lies therein that a necessary operation may be omitted or taken recourse to too late because of the X-ray treatment used. The increase in temperature, which sometimes accompanies the X-ray radiation, may induce the belief, that it rises in consequence of the treatment, whereas the inflammatory process is de facto spreading. Such a case occurs among my 113 cases of periappendicular abscess, treated with X-rays. I would emphasize in this connection, that the patients must be kept under very careful observation, perhaps under a more careful still than otherwise, in case X-ray radiation is made use of at periappendicular abscess formation.

Finally some remarks on the ad mortem cases, that had been treated with X-rays.

In the first case it was the question of a woman aged 21, who during five to six days had suffered from abdominal pains especially in the lower part of the abdomen, as well as from fever and diarrhoea. Strong

vomitings. Menses had been regular, now two weeks too early in connection with the pains. Status praesens on admittance: The patient was somewhat exhausted, pale, the temperature 38.4—38.6° C, the pulse even, regular 120/min. Red-cell sedimentation reaction 95/115 mm. The lower part of the abdomen somewhat tender, just a little tense, a resistance palpable to the right. The upper part of the abdomen: no remarks. Conservative treatment with ice-bag was applied in this case. The state grew worse on the fourth day wherefore the abscess was radiated with 200 r. An internal examination was made the same day, whereupon severe abdominal pains immediately set in. The pulse grew weak and she died in the evening with symptoms of peritonitis. A perforated periappendicular abscess with peritonitis was considered to be the cause of death. No autopsy. In this case the sole X-ray radiation, given the day when the patient died, hardly can have played any rôle, whereas it may be subject to dispute whether an operative interference at an earlier stage might possibly have saved her life.

In the second case it was the question of a man aged 54 with severe cardiac insufficiency, admitted to hospital with a periappendicular abscess the size of a fist. Conservative treatment was taken recourse to and he was radiated besides three times with X-rays at 200 r with an interval of nine days between the radiations. The patient died on the 45th day from cardiac insufficiency. Resorption of the abscess then had taken place long ago.

In the third case it was the question of a woman aged 23, admitted to hospital subsequent to a case history of typical appendicitis of two days duration, with 40° C fever and a tender and sharply defined resistance the size of a usual hen's egg above the appendix region. For the rest nothing particular to be said about the abdomen and the general state of health. She was treated with ice-bag and radiated with X-rays at 200 r in the direction towards the abscess. Fits of ague after two days, the temperature was 40.3° C. Four days later on she became icteric, the liver seemed enlarged on palpation, tender. Severe abdominal pains. When she had been two weeks in hospital she was radiated anew with X-rays at 200 r, and enterostomy ad modum Witzel was performed owing to intestinal paresis. Incision of the abscess. Exitus lethalis the next day. The cause of death was: Abscessus periappendicularis. Peritonitis. Pylephlebitis cum abscessu hepatis. In this case it is possible that the X-ray treatment obscured the disease picture, that the radiation but increased the virulence of the bacteria and opened the venous tracks towards vena portae. An operative interference immediately on admittance might eventually have saved the patient's life. But it may not by any means be taken for granted. The fits of ague and the high fever already on admittance to hospital indicate that the pylephlebitic process was already ensuing at that time. It is a well known fact that the prognosis is exceedingly unfavourable in conditions of this kind.

Summary.

On the basis of 320 cases of periappendicular abscess-formation, treated during the years 1930—1944 in the County Hospital at Kuopio the author in cases with a sharply defined abscess without any other abdominal symptoms or with regard to the general state, recommends a combined method of treatment, viz.: conservative measures together with X-ray radiation of the abscess. This method has yielded good results in 113 cases.

The advantages of this method of treatment as compared with the purely conservative one are, that a more rapid resorption of the abscess, a more reliable barrier formation towards a free abdominal cavity, in more favourable cases shorter hospital stay and consequently less expenses for patients as well as hospital, are attained. The author anyway emphasizes, that this kind of treatment requires a careful observation of the patient. This method of treatment has been applied upon adults as well as children, men as well as women. Disturbances in the ovarian function, eczema formation or other complications have not been observed.

Zusammenfassung.

Auf Basis von 320 Fälle von periappendiculärer Abscessbildung die während der Jahre 1930—44 im Distriktskrankenhaus zu Kuopio behandelt sind, empfiehlt der Verfasser bei wohlbegrenztem Abscess ohne Symptome im übrigen vom Bauch oder Allgemeinzustand eine kombinierte Behandlungsmethode: konservatives Vorgehen und Röntgenbestrahlung des Abscesses. Diese Methode ist mit gutem Erfolg bei 113 Fälle angewandt.

Die Vorteile dieser Behandlung vor der reinen konservativen sind, dass wir eine schnellere Resorption des Abscesses und eine sichere Barriärbildung gegen freie Bauchhöhle erhalten. In günstigen Fällen finden wir einen kürzeren Aufenthalt im Hospital und dadurch verminderte Aufwände für sowohl Patient als Krankenhaus. Der Verfasser betont doch, dass diese Behandlung ein sorgfältiges Überwachen des Kranken erfordert. Die Behandlung ist bei sowohl Erwachsenen als Kindern, Männern und Weibern angewandt. Störungen in der Ovarialfunktion, Eczembildung oder andere Komplikationen sind nicht beobachtet.

Résumé.

Sur la base de 320 cas de formation d'abscès périappendiculaire traités durant les années 1930—44 à l'hôpital départemental de Kuopio l'auteur recommande une méthode de traitement combinée, lorsqu'il s'agit d'un abscès bien limité sans autres symptômes abdominaux ou autre altération de la santé: procédé conservateur accompagné du traitement par les rayons X. Cette méthode a donné des résultats satisfaisants dans 113 cas.

Les avantages de ce traitement sur le traitement purement conservateur sont les suivants: résorption plus rapide de l'abscès, formation de barrière plus sûre contre une cavité abdominale libre, dans des cas favorables séjour hospitalier plus court et, par conséquent, frais réduits tant pour les malades que pour les hôpitaux. L'auteur souligne néanmoins que cette forme de thérapeutique impose une surveillance rigoureuse du malade. Le traitement a été appliqué aux adultes aussi bien qu'aux enfants, tant aux hommes qu'aux femmes. Des troubles de la fonction ovarienne, eczémas ou d'autres complications n'ont pas été observés.

Aus einem Kriegslazarett.
(Chefarzt San. Maj.: AARNE PELKONEN.)

Über die Prostatamyome.[1]

Von

AARNE PELKONEN.

Die benignen Prostatatumoren Fibrom, Fibromyom und Leiomyom sind sehr selten. RUBRITIUS erwähnt in seiner Veröffentlichung 4, DEUTICKE wiederum 6 frühere Fälle, und sein eigener Fall ist der siebte. KEEN hat in der Weltliteratur unter Einbeziehung seines eigenen Falles 21 Leiomyome angetroffen, von welchen jedoch zwei deutliche sarkomatöse Degeneration hatten, so dass sie nicht mehr gutartig waren. Grössere persönliche Serien von Fällen hat niemand aufzuweisen. Da ich in der nordischen Literatur keine Angaben über die in Frage stehenden Fälle gefunden habe, dürfte es angebracht sein, einen solchen zu beschreiben, den ich während des Krieges zu behandeln hatte.

Der Patient E. N., ein 69-jähriger Kaufmann, wurde mir von einem Kollegen zur Behandlung geschickt, weil der Patient *schwere Defäkationsbeschwerden* hatte. Der Darm hatte sich nur alle drei Tage entleert, und die Stuhlgangbeschwerden waren immer stärker geworden. Der Patient hatte in den letzten 3 Wochen 10 kg abgenommen. Beim Urinieren hatte der Patient keine Beschwerden gehabt. St. pr.: Patient mager, Subcutis stark reduziert, Herztöne klanglos, bei Röntgendurchleuchtung Herz nicht erweitert, Schläge ziemlich schlaff, Aorta rauh und rigid. In den Lungen bei der Auskultation keine Veränderungen festzustellen, bei Röntgenuntersuchung in den Hilusgegenden kleine Kalkflecken. Lungen und Pleura sonst o. B. Keinerlei Zeichen von Metastasen. Im Bauch keine Resistenz zu fühlen, das Perineum ist nicht vorgewölbt.

Per rectum: Schleimhaut glatt, nicht infiltriert, an der Prostata ein grosser, verhältnismässig glatter, unempfindlicher Tumor von der Grösse zweier Männerfäuste, der das Rektum ausfüllt und verstopft. Der Katheter lässt sich mühelos einführen, kein Rezidualharn. Harn: Alb.—,

---

[1] In der Versammlung der Finnischen Chirurgenvereinigung am 3. 3. 45 gehaltener Vortrag.

Nyl.—, Sed: Leukoz.—, Erytroz.—, Bakt.—, Kult.—. Das Cystoskop kann ohne Schwierigkeiten eingeführt werden, Schleimhaut normal, Boden der Blase gewaltig vorgewölbt, Ureteröffnungen nicht zu sehen. Reststickstoff 31 mg %. Wasserbelastungsprobe gut (V I 1,270, V II 490, Konz. 20, Elfving'scher Index 32). Hgb. 80/93 Sahli, Erytroz. 4.80 Mill., Leukoz. 9,000, Senkungswert 3/7 mm. Der Patient wurde auf die Operation vorbereitet, indem ihm fünf Tage vor der Operation täglich 3 Amp. (1/4 mg) Strophantin, 10 cem 30 % Glykose und 1 Amp. Ascorbin intravenös verabreicht wurde. Am 9. 6. 44 Prostatectomia suprapubica (Novoc. evipannatr.) Die Blase wird geöffnet und dabei festgestellt, dass ein grosser Tumor auf ihre Wand drückt. Nach JUDD wird eine Prostatectomie ausgeführt. Die Prostata löst sich verhältnismässig leicht, sie ist etwas vergrössert, aber unmittelbar an ihren Seiten hat sich ein zweiteiliger, grosser, gut abgegrenzter Tumor gebildet, wovon der eine, ungefähr faustgrosse, Teil ganz entfernt wird und die andere Hälfte in kleinen Stücken. Die Wände des Hohlraums sind glatt, keine nennenswerte Blutung. Ein fortlaufender Schlauch wird durch die Urethra und die Harnblase geführt, an der Blase zwei Offnungen. Nach der Operation 1 Flasche Blut und 1 Flasche Kochsalzlösung. Der Patient übersteht die Operation verhältnismässig gut, erhält zur Verhütung von Blutungen Manetol und Coagulen sowie Calciumchlorid. Am Abend des gleichen Tages ist das Allgemeinbefinden des Patienten relativ gut, der Puls etwas weich, Spülungsflüssigkeit ziemlich blutig. In den ersten Morgenstunden am 10. 6. 44. Allgemeinbefinden verschlechtert, Puls weich und klein, ziemlich starke Blutungen. Der Patient erhielt 2 Flaschen Blut und Kochsalzlösung, wonach sich das Befinden bedeutend besserte. Am Abend stieg die Temperatur auf 39°, der Patient erhielt eine M + B Kur. Nach zwei Tagen war er fieberfrei und der Harn klar, Befinden gut. Am 12. 6. 44 Hgb 80/93 Sahli, Erytrozyten 4.80 Mill. Am zehnten Tag nach der Operation wird ein Dauerkatheter eingesetzt, das Befinden des Patienten bessert sich ständig, zwei pyelonephritische Anfälle, die sich mit Neosalvarsan- und Cylorion-Injektionen beheben lassen. Der Senkungswert war am 7. 7. 44 55/91 mm. Der Patient erholt sich ausserordentlich gut. Bei der Entlassung aus dem Krankenhaus am 29. 7. 44 war der Senkungswert 8/22 mm, Reststickstoff 40 mg %, Allgemeinbefinden gut, Wunde geschlossen, per Rectum eine leichte gleichmässige Narbenbildung an der Stelle der Prostata, weder Defäkations- noch Harnbeschwerden. St. Harn: Im Sediment reichlich Gram-Bazillen, einige Gram + Kokken und in Massen Leukozyten. Dr. KURTZE hat freundlicherweise die Nachuntersuchung des Patienten im Februar 1945 vorgenommen, wobei er folgendes feststellte: Allgemeinbefinden gut, per rectum Stelle der Prostata unempfindlich, Rektum frei, 50 cem Rezidualharn, Harn etwas trübe, Alb.—, aber im Sediment Leukozyten und Gram-Stäbchen.

Präparat: Von der Geschwulst entfernte ich zuerst den ungefähr faustgrossen linken Lobus 9.7 × 6.8 × 3.9 cm (a, Abb. 1) und dann den rechten Lobus in kleineren Stücken, Gesamtgewicht 350 g.

Die Geschwulst war scharf abgegrenzt, liess sich leicht abtrennen, und die Fläche zu dem anderen Lobus war glatt und breit. In Abb. 1 sehen wir die Aussenfläche des Lobus, welcher auf der Verbindungsfläche liegt, und in Abb. 2 sehen wir wiederum einen Querschnitt des Tumors, wo deutlich die Verbindungsfläche zu sehen ist (c). Die Geschwulst war hellgelb, ziemlich glatt, ihre Schnittfläche gleichmässig hellgelb, vgl. Abb. 2.

Zwei von den kleineren Stücken, die unmittelbar an die Schleimhaut anschlossen, und die seitlich und von hinten durch den Tumor begrenzt wurden, sahen heller aus, und die Schnittfläche entsprach dem Bild der Prostatahypertrophien (vgl. b, Abb. 2).

Mikroskopische Untersuchung.

Die mikroskopischen Präparate wurden hergestellt und gefärbt im Pathologisch-Anatomischen Institut der Universität Helsinki. und ich möchte an dieser Stelle dem Vorstand dieses Instituts, Herrn Prof. Arno Saxén, bestens danken. Die Lichtbilder hat Herr Prof. A. R. Klossner aufgenommen, dem ich ebenfalls für seine Bemühungen danke. Ausser der Hämatoxylin-Eosin-Färbung wurde von allen Präparaten auch die Elastinfärbung ausgeführt.

Bei der mikroskopischen Untersuchung, die ich von dem ganzen Gebiet des Tumors durchgeführt habe, auch von den allerkleinsten Stücken, konnte ich feststellen, dass in zwei Stücken, in der Abb. 1 mit b bezeichnet, Prostatadrüsengewebe anzutreffen war. Diese Stücke waren im Verhältnis zu dem übrigen Tumor sehr klein.

Das mikroskopische Bild aller anderen ausser den mit b bezeichneten zu untersuchenden Stücke wird vom *Muskelgewebe* beherrscht (vgl. Abb. 3 und 4).

Die glatten Muskelfasern kamen sowohl in Längs- als auch Querschnitten vor, irgendwelche besonders abgegrenzte Knollen sind nicht festzustellen, sondern überall ist die gleiche ebenmässige Geschwulst anzutreffen. Die Muskelfasern sehen stellenweise ganz normal aus, stellenweise wiederum ist ihr Zellplasma spärlicher, und das Gewebe erscheint kernreicher als normal. Die Zellstruktur ist jedoch verhältnismässig regelmässig, Mitosen sind nicht wahrzunehmen. Ausser dem Muskelgewebe ist *reichlich Bindegewebe* herrschend, zu einem beträchtlichen Teil hyalinisiert, im allgemeinen wird es jedoch in relativ beschränktem Umfange angetroffen. In der Geschwulst sind zahlreiche, dünnwandige, dilatierte,

bezüglich des Lumens unregelmässige *Blutgefässe*, aber *keinerlei Zeichen von Drüsengewebe. Elastische Fasern* kommen vor, aber in sehr viel geringerem Masse als in den Stücken, welche Drüsengewebe enthalten, und an vielen Stellen sind sie überhaupt nicht anzutreffen.

Die mikroskopische Struktur der zwei kleineren mit b bezeichneten Stücke ist aus Abb. 5 ersichtlich. Das Bild wird besonders von verschieden grossen Drüsenschläuchen beherrscht, die entweder ganz leer sind, oder feinkörnigen Inhalt, eine nekrotische Masse, und hier und da ein einzelnes Konkrement haben. Das Epithel der Schläuche ist verschieden: stellenweise ist es hoch, klar, die Kerne basal angeordnet, stellenweise wiederum würfel- oder zylinderförmig, an manchen Stellen mehrschichtig, in manchen Schläuchen ist das Epithel ganz flach und einreihig, und stellenweise fehlt es ganz. An den letztgenannten Stellen sind die Drüsenschläuche stark dilatiert. An zwei Stellen ist in der Umgebung der Schläuche *Rundzelleninfiltration* wahrzunehmen, sonst sind keinerlei entzündliche Veränderungen festzustellen. *Muskelgewebe* und *Bindegewebe* kommt wie bei gewöhnlicher Prostatahypertrophie vor. Blutgefässe sind verhältnismässig reichlich anzutreffen. *Elastische Fasern* sind reichlich rings um die Schläuche und in deren Interstitium vorhanden. Es bietet sich das typische Bild einer Prostatahypertrophie.

Pathologisch-anatomische Diagnose: Leiomyoma prostatae. Hypertrophia prostatae.

Epikrisis: Bei einem 69-jährigen Mann ist eine grosse, das Rektum stark verengernde Prostatageschwulst festzustellen, welche glatt ist, Schwierigkeiten bei der Defäkation aber keine Harnbeschwerden bereitet. Der Patient hat nach eigener Angabe in den letzten 3 Wochen ungefähr 10 kg abgenommen, weshalb ich Verdacht auf Prostatasarkom hatte. Bei der Operation bereitete die Entfernung der grossen Tumoren die meisten Schwierigkeiten. Nur ein einziger Lobus konnte in toto entfernt werden, die anderen Teile kamen in kleineren Stücken, obwohl sie sich ziemlich leicht lösten. Nach der Exstirpation war schwere Blutung zu erwarten, da der Hohlraum sich sehr gross, wenn auch glattwandig gestaltete. Wiederholte Bluttransfusionen wirkten ganz entscheidend auf die Genesung und das Wohlbefinden des Patienten. Auch die prophylaktisch verabreichte Strophantinbehandlung kann nicht ganz ohne Wirkung gewesen sein, denn der Patient überstand bezüglich des Herzens die Operation ausgezeichnet. Der Patient erholte sich

gut, irgendwelche Zeichen von Rezidiv sind nicht festzustellen. Der Reststickstoff ist normal und ebenso der Senkungswert. Zu bemerken ist, dass der Patient weder vorher noch nachher Harnbeschwerden gehabt hat. Harn früher steril, jetzt noch etwas trübe und enthält Gram-Stäbchen und Leukozyten.

In meinem Fall stellte ich ein reines, gesondertes Leiomyom fest, in welchem verhältnismässig reichlich Bindegewebe und Blutgefässe waren, spärlich elastische Fasern, Drüsengewebe aber überhaupt nicht und ebensowenig Reste davon. In zwei kleinen Stücken war gewöhnliches hypertrophisches Prostatagewebe vorhanden. Hinsichtlich seiner Lage und seiner Form entspricht der von mir dargestellte Fall einem Leiomyom, das aus den Seiten der Prostata und dem dahinter befindlichen Muskelgewebe hervorgegangen ist, aber so gross ist, dass es den Boden der Harnblase nach oben hebt.

In der Prostata unterscheiden wir drei Teile, die in verschiedenem Masse an der Bildung der gewöhnlichen Prostatahypertrophie teilnehmen: Das Drüsengewebe in 50 %, das Binde- und Muskelgewebe jeweils in 25 %. Jeder von diesen Faktoren kann entscheidend die Machtstellung einnehmen. Kornitzer und Zanger haben besonders die Entwicklung und das Vorkommen der myomatösen und adenomyomatösen Prostatahypertrophie untersucht und stellen fest: »Es finden sich aber auch — und nicht allzu selten — (nach Albarran-Hallé bei 3 % der beobachteten Fälle) Fälle, bei denen für die mikroskopische Betrachtung Bindegewebe und glatte Muskulatur in wechselndem gegenseitigem Verhältnis neben dem Drüsengewebe deutlicher in Erscheinung treten oder auch als hauptsächlichster oder alleiniger Gewebsbestandteil das Bild beherrschen.« Hinman hat festgestellt, dass die gutartigen mesodermalen (mesothelialen) Tumoren, die Leiomyome, Fibrome usw., 5 % der Fälle ausmachen. Kornitzer und Zanger hatten im Verlauf relativ kurzer Zeit 6 Fälle mitzuteilen, und hinsichtlich deren Ätiologie legen sie auf Grund ihrer Untersuchungen folgende Schlussfolgerungen dar:

»Im Zustande präseniler Atrophie der Prostatadrüse kann es unter hormonaler Beeinflussung von seiten des noch gut funktionierenden Hodens zu einer Art Ersatzbildung kommen, die sich als drüsige Prostatahypertrophie darstellt. Diese Bildung ist durch ihre relative Autonomie befähigt, bei Aufhören des innersekretorischen Reizes eine Proliferation auch anderer sie zusammensetzender Gewebsbestandteile in Erscheinung treten zu lassen, so

Abb. 1. Abbildung des Tumors, worin der linke Lobus mit *a* bezeichnet ist. In den mit *b* bezeichneten Stücken ist nur leicht hypertrophiertes Prostatagewebe. Dazwischen ist der rechte Lobus in mehreren Stücken.

Abb. 2. Querschnitt des grösseren linken Lobus und der grösseren Stucke des rechten Lobus. Die Verbindungsseite des linken Lobus gut sichtbar, *c*.

Abb. 3. Typisches Leiomyom, das in allen Stücken ausser in den mit *b* bezeichneten vorkommt. Geringere Vergrösserung. Hämatoxylin-Eosin-Färbung.

Abb. 4. Das Gleiche mit stärkerer Vergrösserung.

Abb. 5. In den mit *b* bezeichneten Stucken sah man nur typisches, wenig hypertrophiertes Prostatagewebe.

dass in einem späteren Stadium sowohl die Drüsensubstanz adenomartige Bildungen wie auch glatte Muskulatur — ebenso das Bindegewebe — diffuse oder umschriebene Proliferationszonen aufweisen können.« Alle ihre Fälle waren auch alte Männer, die schwere Harnbeschwerden mit Urinretentionen und langwieriger Katheterbehandlung hatten. Bei der Untersuchung ergab sich, dass alle ausser den starken Blasenbeschwerden eine harte, kaum vergrösserte Prostata hatten, von welcher nicht ohne weiteres von vornherein myomatöser Wuchs vermutet werden konnte, eher wirkten die Fälle wie Karzinom. Die Prostata war bei der Operation auch schwer zu entfernen, in den meisten Fällen nur scharf. Die Entwicklungsstelle war der Raum zwischen der Urethra, dem Ductus ejaculatorius und dem Blasenboden. Im mikroskopischen Bild war in allen Drüsengewebe festzustellen, aber besonders das Muskel- und Bindegewebe hatte zugenommen. Das Muskelgewebe trat in schmaleren und breiteren Streifen, bisweilen als eine grössere, zusammenhängende Masse, aber seltener trat es als umschriebener Knoten auf. OPPENDORFER seinerseits sagt: »Entstehen die Adenomyome der Prostata primär als kleine Muskelwucherungen, dann wird die Analogie der Prostataknoten zu den Myomen des Uterus, die ebenfalls grösstenteils erst im alternden Organ auftreten, noch grösser.«

KORNITZERS und ZANGERS Erklärung passt gut für die meisten Prostatamyomfälle, denn den grössten Teil machen bejahrte Männer aus, wobei das durchschnittliche Alter ungefähr 60 Jahre beträgt. Sie kann jedoch nicht erklären, warum sich bei einem 4-jährigen Kinde oder einem 36-jährigen Manne ein Prostatamyom entwickelt. Haben KEENS entwicklungsgeschichtliche Faktoren Bedeutung in der Ätiologie dieser Geschwülste? Die Entwicklung und Tätigkeit des Ductus Mülleri scheint bei der Entstehung der Uterusmyome Bedeutung zu haben. Es wirkt glaubhaft, dass der gleiche endokrine Faktor, der die Entstehung der Uterusmyome bewirkt, auch das aus dem rudimentären Muskel der hinteren Urethra ausgehende Wachstum verursachen könnte. Diese Annahme würde gestützt durch den Fall von TOVARU und VASILESCU, wo ein 4-jähriger Knabe ein Leiomyom im hinteren Teil der Prostata hatte, das mit sarkomatöser Degeneration verbunden war, und die Geschwulst den Boden der Blase und den inneren Mund der Urethra infiltrierte. REINHARDT führt einen Fall an, welcher ein kindkopfgrosses Myom bei einem 19-jährigen Manne schildert, das als kongenital angesprochen wird.

Auch die Ausgangsstelle des Myoms ist nicht bei allen gleich. In solchen Fällen, wo der glandulare Teil der Prostata beteiligt ist, stammt es offensichtlich aus der von KORNITZER und ZANGER angegebenen Stelle. Hierfür spricht der Fall von RUBRITIUS, wo auch der Drüsenteil beteiligt war. Seinen Fall halten alle ausser KORNITZER für ein Prostatamyom. Der Letztere hält ihn für ein Blasenmyom. DEUTICKE bestimmt den Ausgangspunkt folgendermassen: »dass diese Tumoren in weitgehender Unabhängigkeit von der prostatischen Harnröhre, etwa in der Gegend der hinteren Kapsel, ihren Ausgang nehmen«. Was DEUTICKE mit der hinteren Kapsel meint, ist nicht ganz klar, da aber in der Kapsel kein Muskelgewebe ist, wirkt es glaubhaft, dass das Myom in meinem Falle, welcher vollständig dem Fall von DEUTICKE gleicht, vom Prostatamuskel, und zwar von dessen hinterem Teil und den Seiten ausgegangen ist.

Beachtung verdient OPPENDORFS Erwähnung, »dass für die Entstehung der Uterusmyome vielfach auch die perivaskuläre Entstehung vertreten worden ist, die nach dem häufigen Fund von zentralen Gefässen in den jugendlichen Myomen der Prostata auch hier die wahrscheinlichste ist».

Die eigentlichen und reinen Leiomyome sind selten. MACCALLUM stellte bei 14,000 Obduktionen 8 fest, KEEN hat in der Weltliteratur Prostataleiomyome in 21 Fällen gefunden, wobei sein eigener Fall mitgerechnet ist. Die Grösse des Tumors ist sehr verschieden: Den grössten hat NEUPERT 3,600 g, BUKBEE 340 g, VIGNOLO 250 g und DAMSKI 180 g, um nur einige zu erwähnen. Das Gewicht meines eigenen Tumors betrug, wie ich schon oben erwähnt habe, 350 g, so dass er also die zweite Stelle einnimmt. In der pathologisch-anatomischen Struktur dieser Geschwülste gibt es beträchtliche Unterschiede. Manche haben mehr Drüsengewebe, eine andere ist ein deutlicher fibromyomer Typ, bei einer anderen wiederum fehlt das Drüsengewebe ganz, in zwei Fällen ist sarkomatöse Degeneration festzustellen.

Ein Umstand fiel mir auf, nämlich dass in den Fällen von KEEN, DAMSKI und DEUTICKE nichts über das eigentliche Prostatagewebe erwähnt wird, das natürlich an manchen Stellen anzutreffen sein muss, entweder deutlich gesondert wie in meinem Fall, oder dann im Zusammenhang mit dem Tumor. Auch in den von KEEN beschriebenen Fällen wird nur erwähnt, dass kein Drüsengewebe im Tumor vorkommt, es geht aber nicht hervor, welches Verhältnis die Geschwulst zu der eigentlichen ursprünglichen Prostata hat.

Symptome: Die Symptome der Prostatamyome werden beherrscht entweder von *starken Harnbeschwerden* oder aber von *grösseren oder geringeren Beschwerden bei der Defäkation*, in seltenen Fällen gibt es gleichzeitig Mastdarm- und auch Harnbeschwerden. Nach DAMSKI beruhten die Harnbeschwerden darauf, dass dann auch das Drüsengewebe am Tumor beteiligt ist, und der Tumor an Prostatahypertrophie erinnernde Symptome erzeugt. In solchen Fällen, wo es sich um einen gesonderten Tumor handelt, der frei von Drüsengewebe ist, fehlen die Harnbeschwerden. DAMSKIS, DEUTICKES und mein eigener Fall sprechen stark für diese Auffassung. Bezüglich meines eigenen Falls ist zu erwähnen, dass ich zwei Stücke feststellte, die nahe bei der Schleimhaut waren, und in welchen reguläres, etwas hypertrophiertes Prostatagewebe vorkam, nach welchen für den Patienten auch noch gar keine Prostatabeschwerden zu erwarten sind. Der umgebende Tumor war fest und verengerte in keiner Weise die Urethra, weshalb die Urinierung beschwerdefrei war. In KEENS eigenem Fall und auch in den anderen von ihm beschriebenen Fällen bemerkt man, dass das Vorkommen des Drüsenteils eine sehr seltene Erscheinung war. Er war nur in zwei Fällen wahrzunehmen, welche beide Harnbeschwerden hatten. Von seinen Fällen waren bei 14 die Harnbeschwerden vorherrschend, und bei 12 von diesen befand sich in dem Tumor kein Drüsengewebe, ein Fall hatte sowohl Mastdarm- als auch Harnbeschwerden, und 6 Fälle hatten nur Mastdarmbeschwerden. Im Licht dieser Ziffern stimmt DAMSKIS Theorie nicht, sondern auf das Vorkommen von Harnbeschwerden wirken entscheidend andere Faktoren. Offensichtlich muss die *Geschwulst die Urethra drücken* oder *ihre Richtung verändern oder ein direktes Hindernis für ihre Entleerung* bilden. Die Grösse des Tumors beeinflusst nicht entscheidend die Harnbeschwerden, man könnte vielmehr fast das Umgekehrte behaupten, denn in den Fällen von DAMSKI, VIGNOLO, DEUTICKE und KOENIG sowie in meinem eigenen Fall war der Tumor gross, und es konnten keine Harnbeschwerden festgestellt werden, obwohl die Patienten alle alte Männer waren. In einigen Fällen drückt der Tumor auf das Perineum, und in einem Fall war er durch die Bauchdecken hindurch zu fühlen (NEUPERT). Bei der Untersuchung per rectum war eine sehr eigenartige Geschwulst wahrzunehmen, die in allen Fällen von nicht infiltrierter Schleimhaut bedeckt war. Die Grenzen des Tumors zu seiner Umgebung waren oft deutlich, in manchen Fällen wirkte die Prostata nur wenig vergrössert und hart.

Diagnose: Die Diagnose dieser Fälle vor der Operation ist äusserst schwierig, und sie konnte in keinem einzigen Fall genau im Voraus gestellt werden. Da das Alter, in welchem die Krankheit auftrat, zwischen 4—81 Jahren schwankte, wobei sie jedoch meistens bei alten Leuten vorkam bei einem durchschnittlichen Alter von ca. 60 Jahren, kann man nicht umhin, an einen malignen Tumor zu denken, und zwar am ehesten an Sarkom. Hierfür spricht auch die oft mit der Krankheit verbundene Abmagerung, die nur indirekt durch die Geschwulst erzeugt ist. Das Sarkom ist jedoch in beträchtlichem Masse eine Krankheit der jüngeren Jahre, denn 34 % der Sarkome kommen bei Personen im Alter von unter 10 Jahren vor, 69 % unter 40 Jahren und über 50 Jahre nur 17 % der Fälle. Die Kinder kommen gewöhnlich in weit vorgeschrittenem Stadium zur Untersuchung, und die Häufigkeit der Krankheit bei ihnen lässt uns ohne weiteres an Sarkom denken, aber bei den älteren Personen ist die Stellung der Diagnose schwierig. Der Tumor ist meistens hart, knollig, die Mitte ist bisweilen erweicht. Infolge des schnellen Wachstums des Tumors werden die benachbarten Organe verhältnismässig schnell in Mitleidenschaft gezogen. Die Passage der Urethra wird erschwert und gewunden oder sie wird ganz zusammengedrückt. Die Harnblase infiltriert der Tumor relativ schnell, z. B. in dem Fall von Tovaru und Vasilescu im Verlauf von 5 Monaten, wobei er sich stark an Karzinom annäherte. Die zur Blase hin wachsenden Knollen haben keine Neigung zu Ulzeration. In diesen Fällen steht das Bild einer malignen Geschwulst bedeutend mehr im Vordergrund als bei den Myomen, wo das trotzdem verhältnismässig gute Befinden des Patienten auffällt, obwohl die Geschwulst oft recht gross ist. Die Fälle von Kornitzer und Zanger lassen einem wiederum eher an Karzinom denken, die Prostata ist gewöhnlich nur wenig vergrössert aber ziemlich hart, infiltrierend, in allen Operationen nur scharf abtrennbar, und in diesen Fällen kann nur die mikroskopische Untersuchung Antwort geben. Von den Prostatamyomen sind die Myome am Blasenhals klinisch unmöglich nur unterscheiden, z. B. Rubritius hält den Fall für ein Prostatamyom, aber Kornitzer dagegen für ein Blasenmyom.

Was die *Operationsmethoden* betrifft, so wurden bei den von Keen aufgezählten Fällen bei 6 eine suprapubische Prostatectomie ausgeführt, 6 wurden perineal operiert, und bei einem Fall wurden beide Methoden kombiniert. In einem Fall wurde eine trans-

uretrale Resektion ausgeführt. Bei den übrigen konnte eine Radikaloperation nicht ausgeführt werden.

Resultat der Therapie: Die Patienten der Fälle von KEEN sind alt, mit schlechtem Allgemeinbefinden, und zwei haben Sarkom. Unter ihnen befanden sich drei, denen nicht geholfen werden konnte, vier, bei welchen nur eine palliative Operation ausgeführt werden konnte, aber einer starb unter der Radikaloperation. Von 21 Fällen also starben 8, und die übrigen erholten sich gut. In den Fällen, wo eine radikale Operation ausgeführt werden kann, ist das Resultat ziemlich gut.

Schlussfolgerungen.

1. Es wurde ein wahrscheinlich von der Seite und hinter der Prostata aus dem Muskelgewebe ausgehendes Leiomyom festgestellt, in den Inneren sich zwei Stücke leicht hypertrophiertes Prostatagewebe befanden.

2. In der mikroskopischen Untersuchung wurde ein typisches Leiomyom festgestellt, keine Zeichen von Drüsengewebe, in zwei kleinen gesonderten Stücken leicht hypertrophiertes Prostatagewebe.

3. Der Patient hatte keinerlei Harnbeschwerden. Auch das Cystoskop ging mühelos in die Blase, die Nierenfunktion war gut, aber ein ca. 2 Fäuste grosser, glatter, scharf umschriebener Tumor verstopfte das Rektum fast vollständig.

4. Die Ursache für die Harnbeschwerden kann die Zunahme des glandularen Teils sein, aber bedeutend häufiger drückt die Geschwulst auf die hintere Urethra oder erschwert sonst ihre Passage oder verstopft sie.

5. Durch eine suprapubische Prostatectomie lässt sich die Geschwulst trotz ihrer Grösse im allgemeinen relativ leicht entfernen. Auch in denjenigen Fällen, wo der perineale Weg benutzt wurde, ging die Exstirpation relativ mühelos vor sich.

Zusammenfassung.

Der Verfasser hat bei einem 67-jährigen Mann eine Prostatageschwulst von 350 g Gewicht entfernt, welche sich in der mikroskopischen Untersuchung als Leiomyom erwies. Der Patient hatte keine Harn- sondern Defäkationsbeschwerden. Der Verfasser be-

handelt dann die Ätiologie, die Differentialdiagnose, die Therapie sowie die therapeutischen Resultate der Leiomyome.

Summary.

The author has removed a prostatic swelling weighing 350 g from a 67-year-old man which, on being microscopically examined, proved to be a leiomyoma. The patient had no urinary trouble but had defecation troubles. The author deals with the etiology, differential diagnosis, therapy and the therapeutic result of the leiomyoma.

Résumé.

L'auteur a opéré, chez un homme de 67 ans, une tumeur de la prostate pesant 350 g. L'examen microscopique a révélé qu'il s'agissait d'un liomyome. Le malade accusait non pas des troubles de la miction mais de la défécation. L'auteur traite pour finir de l'étiologie, du diagnostic différentiel et de la thérapeutique des liomyomes ainsi que des résultats thérapeutiques.

Literaturverzeichnis.

Damski, A.: Ztschr. f. Urol. Chir. 16: 47: 1924. — Deuticke, P.: Deutsche Ztschr. f. Chir. 236: 475: 1932. — Keen Morris Robert: J. of Urol. 42: 158: 1939. — Kornitzer, E.: Ztschr. f. Urol. Chir. 40: 367: 1935. — Kornitzer Ernst, und Zanger, Carl: Ztschr. f. Urol. Chir. 11: 137: 1923. — Neupert: Ztt. f. Chir. 58: 1071: 1931. — Obendorfer, S., F. Henke und O. Lubarsch: Handbuch der speziellen pathologischen Anatomie und Histologie s. 471: 1931. — Rubritius: Ztschr. f. Urol. Chir. 24: 418: 1928. — Tovaru, S. und Vasilescu, C.: Frankfurter Ztschr. f. Path. 52: 41: 1938.

On Clostridia Infections in War Wounds on the Carelian Isthmus.

By

ERKKI SAARENMAA, M. D. (Helsinki).

Introduction.

The German Medical Department of the Ministry of War (die deutsche Medizinalabteilung des Kriegsministeriums) in 1918 while the war was still on — on the western front — prohibited all publication of investigations on the so called gas oedema. It proves that this war plague, "die Geissel des Krieges", as COENEN terms it, was a question of vital importance. We do not know whether the causes ("die prinzipiellen Erwägungen") on which the census founded the prohibition were purely military, or whether it was a criticism against the literature on gas oedema which had grown immensely after 1914. In any case the flood of this kind of literature proved that the physicians at the front and in the hospitals were struggling with a complicated problem. Also in the western powers the question was discussed with interest. In 1921, HABERLAND published a report on "Die anaerobe Wundinfektion". His list of references comprised 1,293 publications. The gas oedema infections were given 71 definitions. 52 microbes causing infection were discovered. 8 synonyms were used for clostridium welchii, the most common causative agent of gas oedema. The present war, now of close to 6 years duration, has again proved gas oedema to be one of the commonest subjects in medical literature. In the present era of sulphonamide drugs and penicillin the therapeutical side is of great interest.

Was the gas oedema an important question on our fronts in East Carelia and on the Carelian Isthmus? What was the nature

of this disastrous wound infection in our battle-fields? It may be difficult to answer these questions on the basis of clinical reports from field-, evacuation- and war-hospitals. The diagnoses are founded upon clinical observations. Our field laboratories were not equipped with the necessary appliances for the purpose of making bacteriological diagnoses of anaerobe bacteria. Bacteriological diagnoses are not important theoretically only. WEINBERG and SÉGUIN made a diagnosis in 24 hours by using microscopical examinations of the wound exudate, agglutination tests, inoculations in test-animals and pure cultivation. In Finland RAIVIO has treated the question and published a report on 30 cases in the Finnish medical journal "Duodecim". The reason for gas oedema not having been much investigated in this country is the lack of possibilities for carrying out bacteriological diagnoses on anaerobes in the field laboratories. It is no easy task to add anything positive to the chaos of opinions in the literature if the cases are not clearly described. A conception of the gas oedema may only be reached by bacteriological investigations.

General Survey of the Clostridium Family.

In systematic bacteriology the bacteria are grouped according to the botanic system in families and the families in species. The grouping is natural and based upon morphological and biological similarity. The family of bacteria constitutes a biological entity. The infections which the pathogenic species of the family cause in the body of animals and man may be investigated as a whole in pathology. The grouping of the clostridium family has been a labourious research work. *The Anaerobic Committee of the Medical Research Council* quotes 22 different species (TOPLEY-WILSON).

The pathogenic species of the clostridium family bring about infection o n l y in local tissue injuries, wounds, and differ in this respect from aerobic pyogenic, anaerobe pyogenic (putrid) bacteria, and diphtheria. Lacking strong exotoxins they would be saprophytic. As cl. tetani and cl. botulinum exotoxins affect particularly the nerve tissues specifically the gas oedema toxins have a specific effect on the *muscular tissue*. The remarkable and violent pictures of the disease caused by clostridia, tetanus, botulism, and gas oedema are biologically so much similar that

it may be said that they are intoxications rather than infections. The picture of the gas oedema thus becomes more comprehensible. We understand the violent rapidness of the inflammatory process as the spreading of the toxins cannot be limited by demarcation lines formed by the leucocytes as in pyogenic infections.

Gas Formation Due to the Causative Agents of Gas Oedema and "Other Gas Forming" Bacteria.

When are we entitled to use the term gas oedema of an infection in a wound, or in other traumatic lesions (haemarthron, haemothorax)? The answer is simple: when the pathogenic exotoxin-forming clostridium bacterium has caused the manifest picture of the disease. In practise, the following facts particularly, complicate the question: 1) Pathogenic clostridium bacteria are found in war wounds in a proportion almost equal to those found in soil although they do not produce the disease in its typical form (ZEISSLER, GAY). 2) The gas oedema is not a bacteriological entity, there are various causes giving rise to it, and the power of their exotoxins are varied; some of them lack, besides, a natural pathogenicity but form, however, exotoxin, 3) there are other bacteria causing wound inflammations in which gas formation is noticed, 4) in the so called traumatic ischemia (or in general in ischemic necrosis) although it may be only contaminated by saprophytes, processes of putrefaction with alterations in the skin take place which deceivingly resemble gas oedema. Putrescent ischemic necrosis, even a mummification remaining sterile, has a toxic effect also on the general condition. As, on the other hand, traumatic ischemia seems to be perhaps the most important predisposing factor of true gas oedema, the question between traumatic ischemia and gas oedema will be more thoroughly discussed when I have put forward my own cases. Of 22 clostridium bacteria, cl. butyricum and cl. sporogenes and 12 less important species are pure saprophytes. This is the so called *atoxic* group of clostridia. Cl. botulinum is an exotoxin forming saprophyte growing outside the organism. Cl. tetani possesses a natural pathogenicity but its exotoxin is strictly specific to the nerve tissue. These two kinds form the so called n e u r o t o x i c group. *There are thus 6 kinds of clostridia causing a picture of disease similar to gas oedema which should be observed.* They form the so

called *histiotoxic* group. Three kinds of this group, cl. welchii, cl. septique and cl. oedematiens, have a natural pathogenicity and specially strong histiolytic toxins. The natural pathogenicity of three others, cl. histiolyticum, cl. fallax and cl. chauvoei, is uncertain but they form, however, exotoxins which have a histiolytic effect. They are important with regard to the rise of mixed infection together with the former and also independently when they come into nutritive substance in necrotic and ischemic tissue. As the exotoxins of the agents causing toxin-forming gas oedema are variable in strength, it is evident that both malignant and mild forms of disease may arise. It is logical to use the term gas oedema also of mild cases if they show clinically typically inflammatory symptoms, oedema and gas, and a stated pathogenic clostridium. Certain streptococcal infections are called erysipelas in spite of the various degrees and prognosis of the disease. I should like to stress this fact as many authors do not approve of the term "gas oedema" excepting in severe cases. Also in mild cases the symptoms may be characteristic of gas oedema, for instance the manner of spreading in the muscular tissues, oedema, and necrosis of the tissue lacking agglomerations of leucocytes. In these symptoms appear the pathogenicity of the histiotoxic group of clostridia (the gas oedema group) which differentiates them from the saprophytes. It is often said: this is not a question of gas oedema but of some "other gas forming" infection. But which are the "other gas forming" infections? There are numerous bacteria that form gas resulting from the metabolism of carbohydrates and proteins. Such bacteria are bacterium coli, proteus vulgaris, anaerobic streptococci and staphylococci, and apathogenic clostridia. Is there any difference in the quality of this characteristic symptom in the case of gas oedema and the other gas forming bacteria? Is this difference diagnostically important? The difference appears in the first place in the quantity of gas and secondly in the composition thereof. The characteristic gas forming capacity of the gas oedema bacteria is exceptionally great in comparison with the others. The gas in gas oedema has been formed from hydrogen and carbonic acid; it contains a small amount of sulphuretted hydrogen. On this account there is no putrid and feculent smell which is typical of other anaerobic infections. The smell is caused by indol and scatol, sulphuretted hydrogen and merkaptan. The gas produced by the other gas forming bacteria arises from the

local focus in which the bacteria live and from which they spread as the focus expands. The quantity of gas does not obtain the same proportions as in the gas oedema. This is understandable as the destruction of the tissue in gas oedema takes place with great rapidity owing to the spreading exotoxin. In mild gas oedema cases in which the quantitative difference is not remarkable there is, however, a characteristic difference in the mode of spreading of gas oedema. On the basis hereof we have a possibility of using *X-ray diagnostics* for the purpose of differential diagnosis. The "*malignant*" infiltrative gas of the gas oedema has penetrated characteristically between the muscular fibres into the muscular tissue. A "*benign*" expansive gas produced by other bacteria is observed in well demarcated bubbles of gas in the tissues. Compare the spreading of the gas in the X-ray pictures given in Fig. 2—4. The records have been taken of gas oedema cases diagnosed bacteriologically. Although we have important symptoms when differentiating between the true but mild gas oedema cases and other gas containing phlegmons and abscesses, such as the smell and the mode of spreading of the gas, which may be observed from the X-ray pictures, too, a possibility of errors is however present. The smell may be putrid in true gas oedema if there is a question of mixed infection. It is often difficult to reveal the presence of gas in the trunk for instance, in an X-ray picture. Although the putrification process of the saprophytes in traumatic ischemia starts in the perifery and does not generally spread rapidly beyond the ischemic areas, the changes in the skin and the reduced toxic general condition may cause an incorrect gas oedema diagnosis. Thus the only remaining exact means of deciding whether the clinical picture is a gas oedema is to state the pathogenic clostridium in the gas containing tissue. As pathogenic clostridia in the actual wound may be found more often than they cause a clinical picture, I wish to emphasize that the bacteria must be cultivated from specimens which are not taken from the actual wound but through undamaged skin. If we take the clinical picture of the disease only as a basis for valuing and leave the bacteriological facts aside we easily arrive at two opposed views of which the one emphasizes the saprophytic nature of the clostridia alone. BIER supports this idea. He is of the opinion that there is no absolutely pathogenic gas oedema bacteria causing the disease by its own power. In necrotic or severely injured muscular tissue the rise of gas

oedema is possible. This conception is strongly supported by important facts. They are: almost in all war wounds investigators have found pathogenic gas oedema bacteria. It is a natural consequence of the fact that gas oedema bacteria are very common in nature. The well-known anaerobe investigator ZEISSLER says of cl. welchii: "Der Fraenkelsche Gasbacillus (Bac. Welchii) ist ubiquitär, wahrscheinlich der verbreiteste Keim, der es überhaupt gibt." Not one single case of the surgeon or the nurse having been infected with gas oedema has been noted. Neither are there any reports on the post mortem examiner having been infected, to my knowledge. But numerous gas oedema cases have been reported in consequence of very insignificant tissue damages, among others after subcutaneous and saline injections. In addition gas oedema is known in puerperal infections. The second opinion does not anyhow make a great difference between the true gas oedema and other gas containing infections. In the true gas oedema the tissues are always affected, histiotoxically especially the muscular tissues. The original focus of infection does not, however, have to be in the muscular tissue, it may be for instance in a foreign body or a thrombus completely isolated in a blood vessel which will be described later on. Even if there is no muscular tissue the agent of gas oedema may of course cause infection in large haematomas and blood collections (haemarthron, haemothorax). Infections caused by clostridia in chest injuries will be further described in connection with a case of "clostridium empyema". The picture of the disease is not typical here. But the so called epifascial gas oedema forms, which PAYR has described, do not fit in with the conception of bacteriologic gas oedema. FRANZ says: "Die sogenannten epifascialen Gasphlegmonen (PAYR), die mir gezeigt wurden, waren nichts anders als Phlegmonen mit Gas."

Personal Observations and Cases.

While working in a field hospital during the war 1939—40 and during the recently ended war, from June 1941—June 1944, on the Carelian Isthmus, I formed the opinion that gas oedema was uncommon in these districts. BROFELDT says that gas oedema in the war 1939—40 was "exceptionally rare". My opinion was based upon the following observations.

1) I did not notice any gas containing infections in the head, the throat, the arms and the trunk. Anaerobe empyemas in penetrating chest wounds were observed; the general course of such empyemas was similar to that of the ordinary ones. I observed one case only in which the course of the disease was violent and which might have been caused by a "pressure pneumothorax". The patient was treated in F. H. A /23. The course of the disease was as follows: a young officer was wounded in the chest by a small splinter. General condition when brought to the hospital exceptionally good. No sign of pneumothorax or haemothorax. A small closed opening in the thorax. Cough discharge slightly mixed with blood on account of the splinter having entered the lung. In a fortnight the general condition rapidly weakened and the patient became dyspnoic. "Pressure pneumothorax" was stated, gas emptied with high pressure. The patient died within 12 hours after the appearance of the first symptoms. The patients were quickly evacuated from the field hospitals during battle and on that account the previously mentioned negative observations may be explained to be due to the incubation time not having expired. But I did not either observe gas containing infections in the mentioned parts of the body during the long period of stationary warfare.

2) The only gas containing infections that I observed were in wounds in the lower limbs in which there was a vascular lesion and in consequence thereof an ischemic area. Amputation being necessary, as in such cases in general, the infection did not become so violent as to attract notice to the developing bacteriological process in the ischemic limb. From a therapeutical point of view it makes no difference whether gas oedema or saprophytic putrification develops fully in the ischemic limb. If the amputation is carried out in time there is no divergence in the prognosis. Neither limb nor life can be saved by incision or medicinal treatment if there is ischemia in the limb. I did not either observe any gas forming infections in border cases. Those are as a rule wounds caused by mine explosions in which the degree of the ischemia is more difficult to state as the blocking of the circulation of the blood may be a temporary compression of the artery caused by haematome or sudden contusion. On the other hand, wounds, due to numerous small showers of splinters striking the calf in which there is a possibility of injuring the main arterial trunks and cause an ischemic area, were such, that gas con-

taining infection could be expected with certainty. FRANZ's statement that gas oedema never starts in the toes or the fingers holds good in my observations too. RAIVIO says that he has observed one such case. His description makes it clear that here, too, was a case of ischemia. FRANZ probably wishes to point out by this that gas oedema does not begin in the toes or the fingers if pulsation is felt in the hands and the feet.

3) I did not observe a division of gas oedema into "brown" and "blue" forms.

When in July 1944 I was transferred to work in the great evacuation hospital on the Carelian Isthmus front I had the opportunity of seeing patients arriving in hospital just at the stage when gas oedema generally breaks out. My attention was attracted to numerous advanced gas oedema cases which I had not seen before in field hospitals. But, again, all far advanced infections appeared in the lower limbs. High thigh amputations had to be performed. The patients' general condition was low and the prognosis correspondingly. By examining the amputated limbs a vascular lesion on account of which thrombosis had developed in the artery was regularly stated. The gas containing area had, however, spread above the thrombosis. This fact justified diagnosing the cases as true gas oedema. The microscopical examination of specimens of gas containing muscular tissue proved that in some cases few bacteria appeared in the field of vision (grampositive granulated rods), in others they were not visible at all. In old cases the bacterial flora was abundant. Fig. 1: A preparation of the liquid of gas containing muscular tissue in which there are quantities of grampositive rods. The specimen was taken from Case 4 (cl. welchii). If the blood vessels were not injured no gas containing infections which would have led to death were found, excepting in one case in which a clinical gas oedema developed in the abdominal wall of a patient wounded in the abdomen and operated at the field hospital. Bacteriological diagnosis was not made. At the same time I stated some gas containing infections in the gluteal region, the back and the thighs, in which the gas containing area did not spread but was demarcated. None of these led to death but in them there was nowhere such an ischemic area which might have been caused by damage in a large or fairly large arterial trunk. The infected foci were situated in skin-covered muscular tissue contusions caused by small splinters. As known, even a small splinter may, on account of initial veloc-

ity, cause large wound cavities under the skin. As in these demarcated gas infections grampositive rods appeared, morphologically similar to those in severe cases, I decided to take specimens for cultivation of all such wound infections in which gas formation appeared. The specimens were to be taken through the whole skin from gas containing tissue and not from the wound itself, as far as possible. I sent the specimens to the Bacteriological Laboratory I, where Dr R. KOULUMIES carried out the cultivation tests on animals and made the bacteriological diagnosis.[1]

There was time for taking specimens during one month only before peace came. The number of wounded was much less than in June—July 1944. During this time 5 cases in which gas containing infection was developing, or, more correctly, was already developed were brought to the hospital. As these 5 wound infections were clinically, bacteriologically, and 3 of them also pathologic-anatomically diagnosed gas oedema cases, there is reason to report them as bacteriological diagnostics has not been used in this connection in Finland as a rule. The cases represent, besides, 3 different types: 1) clostridium infection in the pleural cavity (1 case), 2) clostridium infection in the muscular tissue in which there was no vascular lesion (2 cases), 3) clostridium infection in traumatic ischemia (2 cases).

Case 1. B. S. 39 years, sergeant-major. Wounded 5.7.44 by shell splinter in right side of chest. Haemopneumothorax l. dx. followed. Attended first from 5.7—15.7.44 in Field-Hospital A/15. Given tetanus antitoxin 3000 units. "Revisio et suturatio vulneris" performed in FH. Transferred 15.7.44 to War-Hospital 13, on admittance general condition rather weak after journey. Temperature 38.4. On 16.7.44 quick fluoroscopy (the patient was not able to sit nor stand for any time). A compact shadow as far as the apex of the lung, above it a certain amount of air. 18.7.45 severe attack of shortness of breath. Puncture performed "foul smelling air" discharged with great pressure through the cannula, no fluid. 24.7.44 650 ccm. of plum-coloured repugnant smelling liquid was emptied. 28.7.44 the puncture was repeated giving the same kind of fluid with repugnant smell. Each time specimens were sent to the bacteriological laboratory. In the aerobic cultivation no growth. I saw the patient the first time 30.7.44 and removed 700 ccm. of chocolate coloured fluid unpleasant, but not putrid smelling. In the fluid there were only a few leucocytes and grampositive granulated rods. Only grampositive rods grew in the anaerobe cultivation. Bacteriological diagnosis: clostrium septique. There was thus a question of *monomicrobial* infection in the pleural cavity which had

[1] In this connection I wish to thank Dr KOULUMIES for his kind assistance.

been caused by one of the three most important gas oedema-agents. Pneumothorax had developed fully. The pleural cavity was canalized. The patient recovered but is still being treated on account of a residual cavity. The clostridium in the cavity has disappeared and has been replaced by saprophytic mixed infection.

When observing the frequency of chest wounds it is remarkable that the agents of gas oedema very rarely seem to lead to typical malign infection in the lung tissue or the pleural cavity. It also seems probable that the clostridia are not capable of infecting the lung tissue. When the infection arises in the blood leaking into the pleural cavity, we may speak of "gas oedema empyema" even if the name "empyema" is inconsistent in this connection. The exotoxins of the gas oedema do not destroy the pleural and lung tissues in the same special way as it does the muscular tissues. This agrees with what we in general know of the histiolytic specificity of gas oedema toxins. According to ELLIOT and HENRY 10 per cent of all haemothorax are cases caused by shot-wounds infected with anaerobe bacteria. In 80 per cent of these cases the patients recover. The prognosis of gas oedema empyemas do not seem less favourable than those of other anaerobes. Clostridium empyemas are uncommon. In the literature they are described as isolated cases. MARWEDEL, among others, gives a report on them. In his case a "pressure pneumothorax" arose. 5 liters in all, of chocolate-coloured fluid with a strong smell of sulphuretted hydrogen were emptied out of the pleural cavity. The bacterium was clostridium welchii. The patient recovered after an operation. MARWEDEL points out that the favourable prognosis is due to the strong resistive power of the lung tissues against anaerobe gas bacteria. MARWEDEL's case resembles greatly my clostridium empyema case, reported above. which also recovered notwithstanding, "pressure pneumothorax". This was the only case of clostridium empyema of all anaerobe empyemas treated in war-hospital 13, although a very great material was closely examined bacteriologically.

Case 2. V. D. 38 years, private. Wounded by shell splinter 25.7.44 in the right thigh. The splinter was small and pierced the thigh. The openings caused by the entry and exit of the splinter were small and closed. Treated first 25.7—26.7.44 at FH 38. 3000 units of tetanus antitoxin was administered. Transferred 26.7.44 to WH 13. The initial velocity of the splinter was no doubt very great as the splinter had passed through the bone making a small hole at the same time as a line-like crevice arose in the bone. The bruise in the muscular

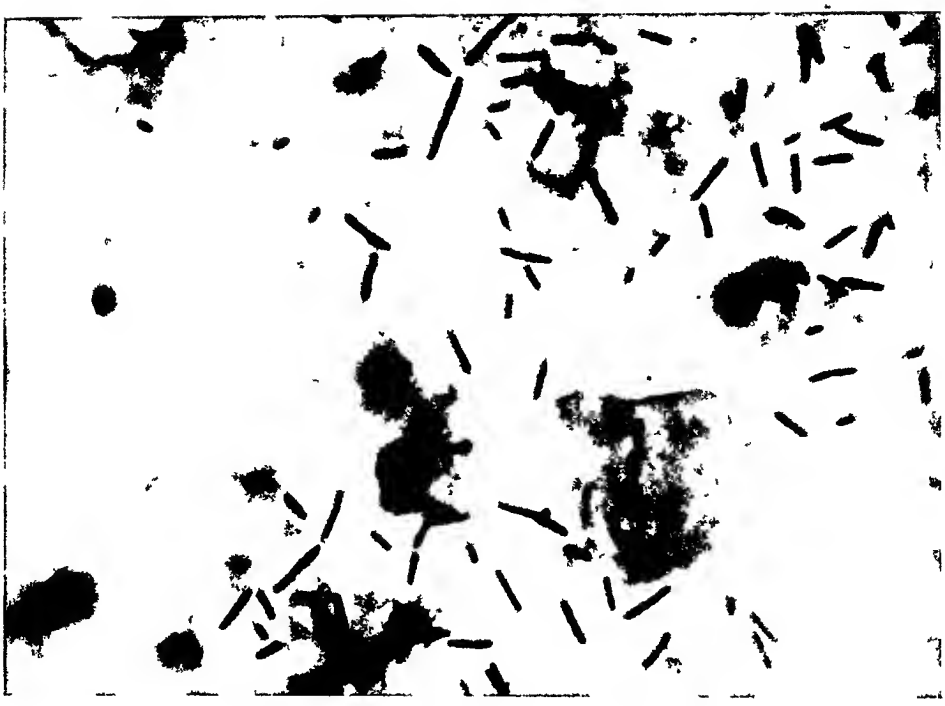

Fig. 1.



Fig. 2.

SAARENMAA: Clostridia Infections in War Wounds.



Fig 3.



Fig. 4.

thigh of the same limb. There were no other wounds. First treated 5.8—11.8.44 in FH B/27. 3000 units of tetanus antitoxin administered. Transferred to WH 13 on 11.8.44. General condition exceedingly poor. Temperature 36.9. Blood pressure 100 mm Hg. Pulse 140—160 beats/min., consciousness quite clear. He gave his anamnesis in detail. After being wounded he had walked a long distance. In the FH the blade of the foot and the leg ached all the time, the pain increasing day by day. A small incision of about 2 cm was made in the bend of the knee and an unsuccessful attempt to locate the splinter with a probe was made. The temperature was low all the time. The pulsation in the lower limb was not recorded. 6 days after being wounded the leg began to swell considerably. Then the patient was transferred to WH 13. Stat. loc.: the lower left limb as far as the inguinal region very much swollen, the swelling reaching the width of a hand above the inguinal region. There was no clear demarcation line. The swollen area was completely insensitive. Cuts could be made in the skin without the patient reacting in any way. The line of the insensitive part was not demarcated and did not reach as far as the swelling. The skin was wax coloured excepting around the incision in the bend of the knee where there was a brownish-purple circle of about 20 cm. Some blisters in the skin in this part with thin blood containing serous fluid. The pulse could not be felt in the inguinal region but in the bend of the knee it was clearly descernible. The percussion sound was tympanitic and a strong gas crepitus was observed in the whole of the swollen area. The X-ray picture revealed a splinter in the bend of the knee and another smaller one on the inside of the thigh. *Very strong gas formation everywhere in the muscular tissue. The gas had spread from the area of the splinter in the bend of the knee in both directions.* Fig. 2 and 3. An attempt was made to improve the general condition of the patient by blood transfusions and stimulants. Bacteria samples were taken from incisions in the skin, and tissue samples for the purpose of histological tests. About two hours after admission into the hospital an upper thigh amputation was undertaken. There was a strong pulsation in the stump and the muscular tissue changed rapidly into a vivid red. Between the fascias there was jelly-like oedema which continued upwards into the stump. The infection could no more be eliminated radically. I examined the amputated limb and stated that the splinter was situated in the border between the femoral artery and the popliteal artery. It was located in the lumen of the vessel, the vessel was torn almost in two in this place. In the proximal direction a thrombosis completely blocking the artery had developed. In the walls of the artery the cell nuclei had been preserved only in the inner parts, those on the outside were completely necrotic. Cross-sections of the blood vessel cut distally from the splinter showed that the lumen of the artery was open and that the cell nuclei in the walls were better preserved. The histological picture of the muscular tissue, the fatty tissue, and the skin, was typical of gas oedema with advanced gangrene. Bacteria were observed also in the tissues. Pathologic-anatomical diagnosis: gangraena aerogenes. In the bacteriological investigation only gram-

positive granulated rods were stated and appeared numerously in the tissue fluid. Fig. 1. In the anaerobic cultivation grew one bacterium only, the diagnosis of species was cl. welchii. The infection was monomicrobial. The general condition of the patient did not improve after the operation and 6 hours later he died.

Case 5. E. K., 27 years, corporal. (As this case is a gas oedema as well as an interesting embolia caused by shot wounds (splinter embolia) of which at present one case only has been reported from the war in Finland I shall describe it in detail.) Earlier PERÄSALO has published a case of bullet-embolia in which a bullet loosened from the heart had been arrested in the a. hypogastrica sinistra. My case is a splinter embolia: The splinter had travelled with the blood stream from the left ventricle as far as a. tibialis posterior. The patient was wounded 5.8.44 at 19.30 hours by a small shell splinter in the left side under the pit of the arm. The air pressure caused the patient to become temporarily unconscious. The patient had no other wounds excepting the mentioned entry of the splinter which was only 3 mm in diameter and closed. The patient became conscious a few minutes after being wounded and was transported to the field-hospital (A/29 FH) where he arrived after 3 hours or at 22.30. He was given 3000 units of tetanus antitoxin. There is no record of his general condition. Stat. loc. in FH: "In left pit of arm small opening made by splinter. Fluoroscopy did not reveal splinter. Abdominal wall soft, blood expectorations". The next day, 6.8.44, there is the following record: "complains of insupportable pains in left leg. The leg insensitive up to the knee, colder than the right leg and the muscles rather slack. To be sent to war-hospital for laminectomy. Diagnosis: Vuln. bomb. penetr. thoracis l. sin. Corpus alien. medullae spinalis. Commotio cerebri levis." Arrived at WH 13 7.8.44 at 0.45 hours. The physician in charge sent the patient to the ward to await morning, giving him morphia. Status praesens 7.8.44 at 8 o'clock: high temperature, 39,3, seemed calm, pulse rapid, soft, regular, 110 beats/min. Not orientated. He answered questions slowly but to the point. The colour of the skin palish, lips not cyanotic, breathing calm. Blood pressure 100 mm Hg. The pupils widened, reacting. Local symptoms: in left pit of arm a closed opening at entry of splinter surrounded by slight sugillation, no inflammatory reaction in the wound. An X-ray picture of the lungs was taken, nothing special noticable, no shadow of the splinter. No other wounds in the body. The upper limbs and the right lower limb intact. The abdominal wall soft. No symptoms in the urine. Flexion of left knee about 90°. Trying to stretch it out the patient suffered unbearable pain. The upper part of the thigh normal in colouring, warm. From the knee downwards the whole left limb thick, swollen like a log, colour of skin pale, like wax, excepting on the lateral side of the leg where there was a brownish-violet area as large as a hand. No feeling from knee downwards. No pulsation in a. dorsalis pedis and a. poplitea. He could move his knee to some extent, ankle movements uncertain. In the whole leg, and the width of a hand above the knee, gas crepitus observed.

Percussion sound tympanitic. *Small splinter in neighbourhood of capitulum fibulae and also strong gas formation observed in X-ray picture. Gas spread in both directions from the splinter.* Fig. 4. On the basis of the investigation the following diagnosis was made: vuln. bomb. penetr. thoracis l. sin. penetr. aortae seu cordis. Corpus alien. intra-arterialis reg. fossae popliteae l. sin. Infectio aerogenes. As the patient's general condition was good a decision was made to try a conservative operation. The result of the operation was doubtful, however, on account of such a long time having elapsed since the patient was wounded. The case would have been most interesting to obtain quite fresh. Ether narcosis was administered and the operation performed at 10 o'clock: arteriotomia a. tibialis post., extractio corporis alieni, arteriotomia a. tibialis ant. et fibularis. The patient was given heparin intravenously. A longitudinal cut in the fossa poplitea. A. poplitea was laid bare, it throbbed clearly almost in its entire extent. Following the trunk of the artery the splinter was felt in a. tibialis posterior. About 2.5 cm from the splinter, proximally, the artery was blocked by a thrombosis at which place the pulsation of the artery ceased. Starting here the wall of the artery was slack and the colour dark. Branching out from this spot, somewhat distally a. tibialis and fibularis were blocked with thrombs and there was no pulsation. Between the fatty tissue and the fascia there was a jelly-like oedema and the muscular tissue was dirty-brown and gas containing. The splinter was removed from a small incision opening which did not bleed. When the artery was probed with a ureteric catheter in the proximal direction it was opened and strong arterial bleeding was obtained. Distally the probe entered easily about 10 cm. A. tibialis post. pulsated well in the whole area of the cut after the incision had been closed by vascular suture. The arterial walls soon recovered their normal colour and firmness. Incisions were also made in the wall of a. tibialis ant. and a. fibularis; the lumens were probed and cleared. The arterial walls did not recover their normal colour as clearly and the pulsation did not become as powerful as in a. tibialis posterior. Then a great incision was made in m. gastrocnemius and the gas containing muscular tissue was rinsed with warm salt solution and hydrogenperoxide. The colour was observed to become more reddish in the muscular tissue and local arterial haemorrhage appeared. The patient was taken to the ward. The blood pressure was now 100 mg Hg. Blood transfusions and stimulants. The patient awoke from the narcosis and did not complain of pains in his leg. As the blood pressure did not rise during the following hours and the blade of the foot did not become warm an amputation in the upper thigh was performed in healthy tissue at 22 hours. The gas containing area had spread somewhat above the knee. After the operation the blood pressure was 90 mm Hg. At 23.55 the patient suddenly had a fit of restlessness and became delirious. Immediately afterwards the patient died. Bacteria samples were taken of the gas containing tissue, the test showed sprinkled grampositive granulated rods. In the anaerobe culture only grampositive rod bacteria grew. This was thus a case of *monomicrobial infection*. Diagnosis of species:

cl. welchii. I requested the military pathologist to open the body principally for the purpose of finding out in which way the splinter had come into a. tibialis posterior via the thorax from the left armpit. Prof. JÄRVI performed the autopsy. As it was carried out almost 24 hours after death the histological examination of the various organs was not of any great importance. Vital reactions, caused by the gas oedema, were not, however, stated in the histologic specimens taken from the various organs. Macroscopically the post mortem examination revealed that there was about 600 ccm liquid blood in the left pleura (the patient had been given heparine). An opening of 4 mm in diameter was observed in the 4th interspace of the ribs in the parietal pleura. In the lower part of the upper lobe of the lung a solid area of the size of a plum was felt. The entry opening of the splinter was felt on the outside and on the inner surface of this area. The cut surface was dark purple and void of air. No fluid in right pleura. The lungs clear. On the left border of the pericardium, in the outer lobe close to the base of penetration opening, a splinter (about 5 mm). In the inner lobe a corresponding opening was found on the outside border of the back wall of the left ventricle about $1^1/_2$ cm distally from sulcus coronarius. The pericardium contained only about 2 spoon-fuls of liquid blood. The lobes pale and smooth. The size of the heart usual, slack consistency. The heart cavities almost void of blood. The above mentioned penetration opening of the splinter continued through the heart muscle in about a 2 cm long channel slanting cranially and opening out into the left ventricle directly above the outer border of the farthest mitral sail. Sugillation around the channel but no pus. The left auricle muscle slack. The inner surface of the heart smooth. The coronary arteries smooth. Aorta smooth, the inner surface of the wall inbibed red. *No vital reactions were observed in the histological samples taken from the various tissues, neither around the wound channel in the lung tissue, nor in the heart muscle.* Post mortem diagnosis: vuln. bomb. penetr. parietis thoracis l. sin., lobi sup. pulm. sin., pericardii et parietis cordis l. sin. Haemothorax l. sin. St. post amputationem extr. pelvin. l. sin. (Transparitio corporis alieni c. sanguine e corde in a. tibialem post. sin. Thrombosis a. tibialis post., ant. et fibularis. Gangraena aerogenes.)

3 of these 5 cases thus appeared with monomicrobial infection, which is not common, if the samples are taken from war wounds. They generally contain mixed infection. Only 10 of WEINBERG's and SEGUIN's 91 cases contained monomicrobial infection. My cases were, however, exceptional, as the agent of the infection in two of them was situated in a foreign body completely blocked by a vessel, and the samples were taken from gas containing tissue though undamaged skin and not from the wounds. The third monomicrobial infection arose in the haemothorax. From the point of view of the pathogenesis of gas oedema it is

interesting to notice that in case 5 no vital reaction had developed within two days in the lung tissue nor in the heart muscle through which the foreign body infected by the gas oedema bacterium had travelled but within the same time a strong gas oedema had arisen in the ischemic muscle tissue of the leg.

Traumatic Ischemia and Gas Oedema.

Many investigators have always considered disturbances of the blood circulation a primary agent of gas oedema. According to FRANZ one third of all the gas oedema cases in the Great War were connected with artery injuries. RICKER's and HARZ's experiments are most interesting, too. They were able to bring out gas oedema by means of a certain quantity of oedema bacteria only after having tied the test animal's artery in the limb which had been inoculated. There are, however, investigators who wish to separate the gas oedemas originating in connection with traumatic ischemia into a group of their own. If a bacteriological diagnosis has not been made we are not entitled to do so because true gas oedema develops most easily just in the area of ischemic tissue. In this connection I should like to stress that the gas oedema in our hospitals seemed to develop into a malignant form in combination with traumatic ischemia only. Unless there is an infection of this kind, a blood vessel lesion alone does not prove to be so fatal to the patient even if a radical treatment, generally amputation, is delayed. This is important when applying plaster dressings and tourniquets.

The Pathogenesis of Clostridia Infections.

It is evident that pathogenic clostridia and saprophytic putrefaction bacteria, in severely damaged tissue, in large contusions, and in such parts of the body in which the arterial blood circulation has been disturbed, find suitable nutrition and anaerobic conditions for themselves. But it is a mysterious phenomenon, on the other hand, that pathogenic clostridium infection is present in most of the other war wounds but the manifest disease develops in a fractional part of them only. This fact has been closely studied in respect of tetanus as well as of gas oedema. They possess pathogenic similarities. Gas oedema bacteria containing

broth culture have been injected into test-animals and gas oedema produced. But if the bacteria have been injected rinsed free of broth they have grown in, no infection has arisen. If, again these rinsed bacteria and a dose of subletal toxin, obtained from the broth, have been injected together a mortal infection has developed. Bacteria, lacking toxins, are rapidly destroyed by the phagocytosis in the tissue, the bacteria injected with toxin begin, on the contrary, to split up and form new toxins. The toxins are not, however, the only bodies possessing this cataphylactic effect. Some salts of calcium have displayed such qualities, for instance calcium chloride and colloidal silica. It has further been stated that mixed infection caused by proteolytic saprophytes, cl. sporogenes and proteus vulgaris, cause the avirulent pathogenic clostridia, cl. tetani and the agents of gas oedema to be exceedingly virulent. It is not quite clear what causative factors should be present to produce gas oedema but the investigators agree that some such factor is required. I quote from the "Report of the Anaerobic Committee" as follows: "The disease begins, not when a wound has become infected with the pathogenic anaerobes, but from the moment when a group of these bacteria have been enabled to surround themselves with a toxin sufficiently concentrated to abolish the local defences of the tissues." As regards tetanus, general practice shows that administration of prophylactic antitoxin is an effective means of eliminating the agents developing tetanus infection. Would a systematic administration of tetanus antitoxin have caused also gas oedema to appear more infrequently and not so severely on the Finnish fronts? The fact that the gas oedema cases developed into malignant forms only in combination with traumatic ischemia could perhaps be understood on this account. This possibility is not quite excluded if we consider the relationship of the tetanus and gas oedema bacteria. The infrequency of gas oedema cannot be attributed to surgical treatment as it is impossible to obtain such radical results as to exclude anaerobe infections by means of wound revisions. In the modern material-wasting warfare, due to the enormous use of all sorts of artillery shots and air bombs and due to their immense splinter effect, the number of multiple wounds caused by small splinters has grown to such a degree that the much emphasized wound revision is a pure theory. It is questionable whether even in the first Great War the decrease in the number of gas oedema cases occurring simultaneously

with the decrease of tetanus, was due to surgical treatment of wounds. In the British Expeditionary force, for instance, the rate of gas oedema cases dropped from 12 per cent to less than 1 per cent.

Summary.

In the above I have not presented a general survey of gas oedema cases but personal observations on the appearance of this wound infection in war wounds on the Carelian Isthmus during the wars 1940—44. Observations are based upon experiences in field- and evacuation-hospitals.

1. No clinical gas oedema cases in the head, the throat, the walls of the chest and the arms were observed.

2. Two cases only were stated in which the infection was violent and appeared in other parts than in the lower limbs. One of them was a splinter penetrating the lung tissue and causing gas infection and on account thereof "pressure pneumothorax". The second case was a patient operated upon on account of a wound in the abdomen. Gas oedema developed in the abdominal wall. Both cases led rapidly to death. The cases were not examined bacteriologically.

3. In the lower limbs numerous gas containing infections appeared in connection with traumatic ischemia.

4. A division of gas oedema into "brown" and "blue" forms was not observed.

On account of these observations I proceeded, in August 1944, to examine gas containing wound infections bacteriologically. There was time to examine 5 cases only of wound infections, in which gas appeared clinically, before the armistice. Clostridium was found in all of them. The investigated clostridia were pathogenic. Specimens were taken through undamaged skin from gas containing tissue. Monomicrobial infection was present in three cases. The cases described are examples of three different types of disease: 1) 1 "clostridium empyema" in which "pressure pneumothorax" developed. The patient recovered by surgical operation. This was the only "clostridium empyema" appearing among numerous empyemas caused by other anareobes, in one big evacuation hospital. The bacterium was cl. septique. 2) 2 gas oedema infections in contusions of muscular tissue, caused by pathogenic clostridia (cl. welchii and a strain not closer diagnosed).

3) 2 far advanced gas oedemas in the lower limbs in which traumatic ischemia was simultaneously present. The bacterium in each of them was cl. welchii. One of the cases was an interesting splinter embolia in a. tibialis posterior. The patient lived about 48 hours after being wounded. During this time no vital inflammatory reaction was observed in the wound channel made by the splinter and leading from the left armpit through the lung tissue to the left ventricle of the heart but an immense gas oedema developed in the ischemic muscular tissue of the left leg. The patient died on account of the gas oedema and not on account of the heart injury.

Malignant gas oedema was very uncommon on the Carelian Isthmus excepting in combination with traumatic ischemia which must be considered the most important factor in the pathogenesis of gas oedema and should be particularly observed when applying plaster dressings and tourniquets. They may cause the gas oedema to break out even when the virulence of the clostridia is slight which it was without doubt in the terrain on the Carelian Isthmus. Did the systematically administered tetanus antitoxin contribute to the weakness of the virulence — that is a question that cannot completely be left aside. Gas oedema also appears in mild forms in which, however, histiolysis of the muscle tissue and pathogenic clostridium can be stated. In the differential diagnosis in the X-ray pictures the gas oedema gas may be distinguished from the gas of gas abscesses and of gas containing phlegmons.

Zusammenfassung.

Verf. bringt kein einheitliches Material von Fällen von Gasphlegmone, sondern nur persönliche Erfahrungen von dem Vorkommen dieser Wundinfektion bei Kriegsverletzungen auf der Karelischen Landenge in den Kriegen 1940—1944. Die Erfahrungen fussen auf der Tätigkeit in Feld- und Evakuierungslazaretten.

1. Verf. hat bei Verletzungen an Kopf, Hals, Brustwand und oberen Extremitäten keine Fälle von Gasphlegmone beobachtet.

2. Verf. beobachtete nur 2 Fälle von schwerer Infektion bei anderer Lokalisation als an den unteren Extremitäten. Der eine war ein Fall, wo ein Granatensplitter in die Lunge eingedrungen

war und ein Gasphlegmone mit ausgesprochenem Spannungspneumothorax erzeugt hatte, der andere eine Bauchverletzung mit Gasphlegmone in der Bauchwand. Beide Fälle verliefen rasch zum Tode. Die Fälle wurden nicht bakteriologisch untersucht.

3. Zahlreiche Fälle von gasbildender Infektion bei traumatischer Ischämie kamen an den unteren Extremitäten vor.

4. Eine Verteilung auf „braune" und „blaue" Typen hat Verf. nicht beobachtet.

Auf Grund dieser Fälle begann Verf. im August 1944 eine Untersuchung der Bakteriologie gasbildender Wundifenktionen. Nur 5 Fälle, bei denen sich klinisch Gasbildung nachweisen liess, konnten vor dem Waffenstillstand untersucht werden. In allen diesen Fällen wurden Klostridien pathogener Natur nachgewiesen. Die Proben wurden aus gashaltigem Muskelgewebe durch unbeschädigte Haut entnommen. In 3 Fällen lag eine monomikrobe Infektion vor. Die Fälle stellen Beispiele für 3 verschiedene Infektionstypen dar:

1. „Klostridiumempyem", ein Fall, bei dem ein Spannungspneumothorax auftrat. Der Verletzte wurde nach Operation geheilt. Dies war in einem grossen Evakuierungskrankenhause unter unzähligen Fällen von durch Anaerobier erzeugten Empyemen der einzige Fall von Klostridiumempyem. Der Erreger war in diesem Falle Clostridium septique.

2. 2 Fälle von Gasphlegmone, erzeugt durch pathogene Klostridien (Cl. Welchii und eine nicht näher festgestellte Art) bei zerfetzten Muskelverletzungen. Das Gasphlegmone begrenzte sich, und die Kranken wurden geheilt. Die Behandlung bestand in Inzisionen, Gasbrandserum und Sulfonamiden.

3. 2 Fälle von weit vorgeschrittenem Gasphlegmone der unteren Extremitäten, verbunden mit traumatischer Ischemie. Erreger: Clostridium Welchii. Der eine war ein interessanter Fall von Granatensplitterembolie in der A. tibialis posterior. Der Patient lebte 48 Stunden nach der Verletzung. Während dieser Zeit wurde keine vitale Entzündung des von der linken Armhöhle durch die Lunge in den linken Herzvorhof verlaufenden Wundkanals beobachtet. Dagegen kam in dem ischämischen Muskelgewebe des linken Unterschenkels ein überaus heftiges Gasphlegmone zur Entwicklung. Der Kranke starb nicht an der Herzverletzung, sondern an dem Gasphlegmone.

Schwere Gasphlegmonen kamen auf der Karelischen Landenge

überaus selten vor, ausser in Verbindung mit traumatischer Ischämie, die deshalb als der wichtigste pathogenetische Faktor des Gasphlegmones anzusehen ist. Dieser Umstand muss beim Eingipsen und bei Verwendung eng sitzender Verbände Beachtung finden. Ein Gasphlegmone lässt sich auch in Fällen hervorprovozieren, wo die Virulenz der Klostridien gering ist, wie sie es auf der Karelischen Landenge zweifelsohne war. Eine Aufmerksamkeit verdienende Frage ist, ob die systematisch gegebene Administration von Tetanusantitoxin für die geringe Virulenz der Bakterien eine Rolle spielt.

Das Gasphlegmone kommt auch in einer leichten Form vor, wobei immerhin Histolyse von Muskelgewebe und irgend eine pathogene Klostridiumart gefunden wird. Im Röntgenbilde unterscheidet sich das bei dem echten Gasphlegmone zu sehende Gas von dem bei anderen Abszessen und Phlegmonen vorkommenden.

Résumé.

L'auteur ne présente pas un matériel uniforme de cas de phlegmons gazeux, mais seulement des expériences personnelles de cette forme d'infection des blessures de guerre sur l'Isthme carélien pendant les guerres 1940—1944. Ses expériences ont été faites dans les lazarets de campagne et d'evacuation.

1. L'auteur n'a pas observé de phlegmons gazeux dans les cas de blessure de la tête, du cou, de la paroi thoracique et des extrémités supérieures.

2. Il n'a observé que deux cas avec localisation autre que les extrémités inférieures. Dans le premier cas, un fragment de grenade avait pénétré dans le poumon et donné lieu à un phlegmon gazeux avec pneumothorax à tension élevée; dans le second cas, il s'agissait d'une plaie abdominale avec phlegmon gazeux de la paroi abdominale. La mort fut rapide. On ne procéda pas à l'examen bactériologique.

3. De nombreux cas d'infection gazogène se produisirent dans les cas de traumatisme avec ischémie des extrémités inférieures.

4. L'auteur n'a pas observé une division des cas en phlegmons «bruns» et phlegmons «bleus».

Se basant sur ces expériences, l'auteur entreprit en août 1944 une étude bactériologique des infections chirurgicales gazogènes. Lors de l'armistice, il n'avait réuni que 5 cas dans lesquels l'exa-

l'autre clostridium pathogène. L'image radiographique permet de distinguer le gaz du vrai phlegmon gazeux de celui qui se produit dans d'autres formes d'abcès et de phlegmons.

References.

BIER, A.: Gasphlegmone im wesentlichen eine Muskelerkrankung, Med. Klinik. 1916: 14: 355. — BROFELDT, S. A.: Lyhyt kenttäkirurgian opas, Helsinki 1942. — COENEN, H.: Die Bösartigkeit des Gasbrandes in manchen Kampfgebieten, Berliner klin. Wochenschr., 1917: 15: 354. — ELLIOT and HENRY: Ref. according to HABERLAND. — FRANZ, C.: Lehrbuch der Kriegschirurgie, Berlin, 1942. — GAY, FREDRICK P.: Agents of Disease and Host Resistance, Baltimore, 1935. — HABERLAND, H. F. O.: Die anaerobe Wundinfektion (N. D. Chir. 27), Stuttgart, 1921. — MARWEDEL, G.: Über offene und ruhende Gasinfektion, Deutsche med. Wochenschr., 1917: 26: 803. — PAYR, E.: Über Gasphlegmone im Kriege, Münch. med. Wochenschr. 1915: 2: 57. — PAYR, E.: Über Gasphlegmone, Med. Klinik, 1916: 17: 442. — PERÄSALO, O.: Sotilaslääketieteellinen Aikakauslehti, 1944: 101. — RAIVIO, EERO V. L.: Duodecim, 1942: 539. — "Report of the Anaerobic Committee", Ref. according to TOPLEY-WILSON. — RICKER, G. und HARZER, A.: Beitrag zur Kenntnis der ödem- und gasgangränerzeugenden Wirkung anaeroben Bazillen bei Versuchstieren und beim Menschen, Brun's Beitr., 1918: 112: 289. — TOPLEY, W. W. C.—WILSON, G. S.: The Principles of Bacteriology and Immunity I—II, London, 1931. — WEINBERG et SÉGUIN: Ref. according to TOPLEY-WILSON. — ZEISSLER, J.: KOLLE, W. KRAUS, R.—UHLENHUTH, P.: Handbuch d. Mikro, Bd. IV:2, S. 1097, Jena, 1928. — ZEISSLER, J. und NELLER, K.: Arch. f. klin. Chir., 1927: 149: 153.

Processus Pyramidalis in Struma Operations.

By

TORSTEN SANDELIN.

As is known, glandula thyreoidea is divided in two sidelobes which are located on each side of the upper part of the trachea. The lobes are connected with each other by a gland bridge called isthmus. From this or from the sidelobes there often starts a glandular growth which spreads itself over the larynx, sometimes extending all the way up to the tongue bone. This growth is called processus pyramidalis.

In regard to form as well as size glandula thyreoidea is greatly variable in different individuals. The situation gets even more confusing if the gland is pathologically transformed and a struma has developed. The sidelobes as well as the isthmus also vary to a great degree in each case. Sometimes the isthmus is strongly developed, sometimes it can be almost entirely missing. In such cases only a capsule and small singular gland particles are left. Even the processus pyramidalis varies in its appearance and form.

As in the thyreoidea gland, struma may also appear in processus pyramidalis. Sometimes it is diffusely enlarged, sometimes larger or smaller adenoms appear in it. When these adenoms are located at the tip of the processus pyramidalis and the base is indistinctly developed, it may seem as if an isolated struma growth was lying on the tongue bone. In case the adenoms are small they may easily be overlooked in an operation and a recidive may occur. As recidives are usual in this processus I have in struma operations taken notice of this. Thus I always prepare the processus pyramidalis in its whole width and can often discover adenoms which otherwise would not have been observed. In 67 % of the latest of my 200 struma operations the processus

has been so big that I have considered it right to remove it. In the rest of the cases it has been either very small or entirely missing. In 70 % of the cases it has started from the isthmus and in the rest as often from the right as from the left lobe. The size of the processus pyramidalis has varied from a half to two centimetres in breadth and has nearly always been spread over the larynx up against the tongue bone where it gradually diminishes in breadth. Only when there are adenoms at the tip it has had a distinct border line upwards. In 20 % adenoms have been found, the biggest weighing 20 grs. It is clear, that if processus pyramidalis is ignored in an operation, a recidive may easily occur, especially if there are ready developed adenoms to be found. Even in diffuse struma the remaining gland particles are inclined to grow. I am convinced that recidive cases would diminish to a notable degree if more attention would be paid to processus pyramidalis when operating. My own material, covering over 1,300 cases, shows that 39 cases have suffered a recidive (3 %). Of these a little over a half had recidive only in processus pyramidalis. These recidives seldom cause thyreotoxical symptoms or pressure on the throat but from a cosmetical point of view they are annoying because even the smallest growth in front of the trachea or larynx will immediately be noticeable.

My material consequently shows that recidives in processus pyramidalis are usual and even more usual than other recidives. Technically the removal of processus pyramidalis in a primary struma operation is generally easy. Only when the growth extends very high above the tongue bone there may appear difficulties in exposing it. In such cases the incision often must be made longer. There are no arteries, only some smaller ones at the tip. On each side of the base there are almost constantly two veins. The operation of the recidive is simple. A traverse cut is made across the recidive. The operation can often be made policlinically. There are no adherence difficulties which so complicate struma recidive operations.

In 80 % of the cases examined by me the tissue of the processus pyramidalis has macroscopically seen been normal. One now questions whether this growth should always be removed when observed in struma operations. I have generally proceeded so that I have first removed both of the side lobes. If there now remains a sufficient amount of normal tissue I have also removed the processus pyramidalis. In case, however, that the side lobes

have been adenoidly transformed to such an extent that no normal tissue can be discovered I have left the pyramid as a thyreoidea reserve. Rather an enlarged processus pyramidalis than a hypothyros!

Summary.

The author has found that the recidives after his struma operations occur in one-half of the cases in the processus pyramidalis and he therefore prepares and removes this growth at every struma operation. The processus pyramidalis is well developed in 67 % of the struma cases and usually starts from the isthmus and seldom from either of the lobes.

Zusammenfassung.

Verf. hat gefunden, dass die Rezidive nach seinen Kropfoperationen in der Hälfte der Fälle im Processus pyramidalis zur Entwicklung kommen, weshalb er bei jeder Kropfoperation dieses Gebilde freilegt und entfernt. Der Processus pyramidalis ist bei 67 % der Kropffälle gut entwickelt und entspringt gewöhnlich vom Isthmus, selten von einem der Seitenlappen.

Résumé.

L'auteur a constaté que les récidives suivant ses opérations de goitre proviennent dans 50 % des cas du lobule pyramidal. C'est pourquoi il le prépare et l'enlève dans toutes ses opérations. Le lobule pyramidal est bien développé dans 67 % des cas. Il part généralement de l'isthme, plus rarement de l'un des deux lobes.

From the Orthopaedic Clinic of the Karolinska Institutet,
Vanföreanstalten, Stockholm.
(Chief: Professor S. FRIBERG.)

Arthrography in Sequelae to Acute Infectious Arthritis of the Hips of Young Children.

By

ERIK SEVERIN, M. D.

As both the head of the femur and the acetabulum are more or less completely cartilaginous in the early years of life, ordinary Roentgen photographs of infants can give no exact conception of the shape and relative position of the elements of their hip joints. This is especially the case when no bony structure has yet begun to form in the capital epiphysis to make this directly observable in the Roentgen picture. In high grade malformations, *e. g.* in high dislocations of the hip, it is of course possible to see that the cranial end of the femoral diaphysis is latero-cranially displaced in relation to the pelvis, but even that gives no exact information on the appearance of the femoral head and acetabulum. In cases of minor changes like subluxations, it may be difficult to spot the misplacement by means of ordinary Roentgen technique, more especially if it is bilateral. The *arthrographic method of examination*, however, has provided a means of mastering these difficulties.

The utility of arthrography in cases of congenital dislocations of the hip has been demonstrated before (FABER and SEVERIN). The arthrographic Roentgen picture and its anatomical basis in children's normal and dislocated hips have been fully described by FABER, WIBERG, and SEVERIN. In 1941 SEVERIN described the technique as follows: "The needle is inserted about two centimetres below Poupart's ligament and one centimetre lateral to the femoral artery. The tip of the needle is then pushed in dorsal to the artery, towards the calculated site of the acetabulum in the case of dislocation, and towards the head if it is still in the

acetabulum. In the latter case, it is easy to tell when the needle point has entered the joint if the leg is slowly rotated outwards and inwards during the puncture. As soon as the needle has reached the head, great care must be taken not to injure the cartilage. It is best to use a short-bevelled lumbar needle. A long-bevelled needle is more apt to scratch the cartilage, and with a long needle opening there is more chance of some of the contrast medium being injected outside the joint. — If the puncture is successful, the contrast fluid[1] is easily injected at first, but after a few cubic centimetres a fluctuating resistance is met. This shows that the capsule is filled, and the injection is stopped. Different quantities of contrast medium are needed, according to the age. We generally inject 1.5 to 3 cc. into the healthy joint of a child two to three years of age. More can be taken by a dislocated joint, but we usually do not inject more than 3.5 cc., to avoid too much of the medium being pressed out around the joint when the reduction is done. — Before exposing the Roentgen plate, the leg is moved about a little to distribute the fluid over the whole joint."

The arthrogram of a child's normal hip joint (Fig. 1, right hip) shows a spherical head fitting into a cartilaginous acetabulum, the latero-cranial lip of which is marked by a small amount of contrast medium collected at the edge of the fibro-cartilaginous limbus, and medially-caudally by a defect in the contrast, which corresponds to the transverse ligament. The fibro-cartilaginous limbus is a sensitive indicator of the position of the head. Normally, the edge of the limbus should be on the horizontal line through the Y-cartilage. The least latero-cranial displacement of the femoral head will be disclosed in the arthrogram by the edge of the limbus, which then leaves the Y-line for a more cranial position. The normal arthrogram also shows the outline of the zona orbicularis between the two contrast rings, one round the border of the acetabulum, the other round the femoral neck near the insertion of the capsule.

In congenital dislocations of the hip the arthrogram (Fig. 1, left joint) shows among other things a small and deformed femoral head, the capsular isthmus with the ligamentum teres, and the deformed cartilaginous acetabular roof pinned in with the limbus medially-caudally to the femoral head.

A healing acute infectious arthritis of the hip in an infant

[1] BAYER's "Perabrodil zur Gelenkdarstellung" with normal saline diluted to a 17.5 per cent solution.

will as a rule cause deformation of the cranial end of the femur. In the literature it is also pointed out that dislocations through distention are common sequelae to arthritis of the hip in infants. My two cases permit no discussion of this question, but judging by them it does not seem unlikely that some of the residuary conditions, which in the Roentgen picture were interpreted as dislocations, were actually of the same type as in my cases, *i. e.* the dislocations were only simulated. Post-arthritic changes in the hip make it even more difficult than usual to obtain any clear idea by means of the ordinary Roentgen technique of what the hip joint is like. If the capital epiphysis is not ossified there is always some doubt as to where to look for the head of the femur. In that case the position of the femoral shaft is the only guide, and — as will be shown below — this gives only vague and unreliable indications of the conditions in the joint. In trying to estimate correctly the form and relative position of the elements of the joint in a suspected case of distentional dislocation, valuable and interesting information might *a priori* be expected from an arthrographic examination, but as far as I am aware this field has as yet hardly been touched.

The residuary conditions following infectious arthritis of the hip joint are as a rule difficult to interpret in the arthrograms. The shrivelling of the capsule and deformations of the articular surfaces blur the outlines, and the anatomical details are not as easily identified as in normal, dysplastic, or congenitally dislocated joints. In studying the pictures it is in the first place necessary to determine the shape of the articular surfaces, the relative positions of the different parts of the joint, and the position of the head and neck of the femur in relation to its shaft. A good idea may then be obtained of the general appearance of the joint, even though its finer anatomical details may escape us. The arthrographic pictures of these residuary conditions provide better grounds for the diagnosis, and may at times be of quite decisive importance to the proposed therapeutic action.

Case 1. J. 2908/45. H. F., ♀, 1 year and 10 months.

At the age of 3 weeks the child had an attack of bilateral acute infectious arthritis of the hips, which was clinically healed after 4 weeks. She began to walk at the age of $1^1/_2$ year, but limped from the first. A Roentgen examination in the local hospital resulted in a diagnosis of "pronounced latero-cranial subluxation of both hip joints", and the patient was sent to our clinic.

When examined by me on 1/6 1945, the child — then 1 year and ten months old — gave the clinical impression of a bilateral dislocation of her hips. She walked with a waddle and showed a strongly developed Trendelenburg phenomenon on both sides. Palpation indicated that the large trochanters on both sides were greatly displaced cranially. Hip abduction was limited to 15°, with otherwise normal mobility. The Roentgen examination (Fig. 2) showed that the slightly shortened, clumsily rounded end of the femoral neck was displaced cranially and laterally in relation to the acetabulum, approximately equally much on both sides. The acetabula had not the appearance usual in congenital subluxations or dislocations, their borders projecting out fairly well. No capital epiphysis was visible. The Roentgen examination thus indicated complete dislocation or severe subluxation of non-congenital origin. In view of this find, our first thought was to attempt a reduction of the dislocations, or at any rate to put them into plaster for a time in the abducted position. In deformed joints the diagnosis whether there is a dislocation or not depends mainly on the position of the head of the femur. If — as in cases like these — the head cannot be localized in the Roentgen photograph owing to there being as yet no epiphysis, the diagnosis will necessarily be uncertain. As the position of the head had been clearly demonstrated in my arthrographic examinations of other hip joints, arthrography was done in this case, too, with a view to determining the position of the femoral head before any treatment was initiated. The arthrography gave the following results:

On the right side (Fig. 3) the contour of the head was very irregular. It was of roller shape, and in lateral pictures (Lauenstein's position) showed a pronounced mushroom shape. In that position the maximum width was 3.8 cm., and in pictures taken with the joint extended it was 2.7 cm. The femoral head was directed towards the cranial acetabular border, but was not completely outside the acetabulum, which was filled by a pool of contrast medium. The case is one of severe subluxation of a mushroom-shaped, enlarged femoral head.

On the left side (Fig. 3) the arthrogram shows a very small conically pointed but fairly well rounded cartilaginous head directed towards the acetabulum, in which — as on the right side — a considerable pool of contrast medium indicates that the cavity of the joint has not been obliterated, although it is not filled by the femoral head. The neck seems very short. The femoral head and neck are in a right-angled varus position. There is accordingly neither dislocation nor subluxation on the left side, and any attempt at reduction would be meaningless.

In the absence of an arthrogram, the Roentgen picture would probably have led to the child's being subjected to reducing treatment of both hips. The arthrogram showed that no such treatment was indicated.

Another case is illuminating:

Case 2. J. 4780/43, H. J., ♂, 3 years and 2 months.

At the age of 7 months the left hip of the child was attacked by acute infectious arthritis, the residuary conditions of which were interpreted as a severe subluxation (Fig. 4).

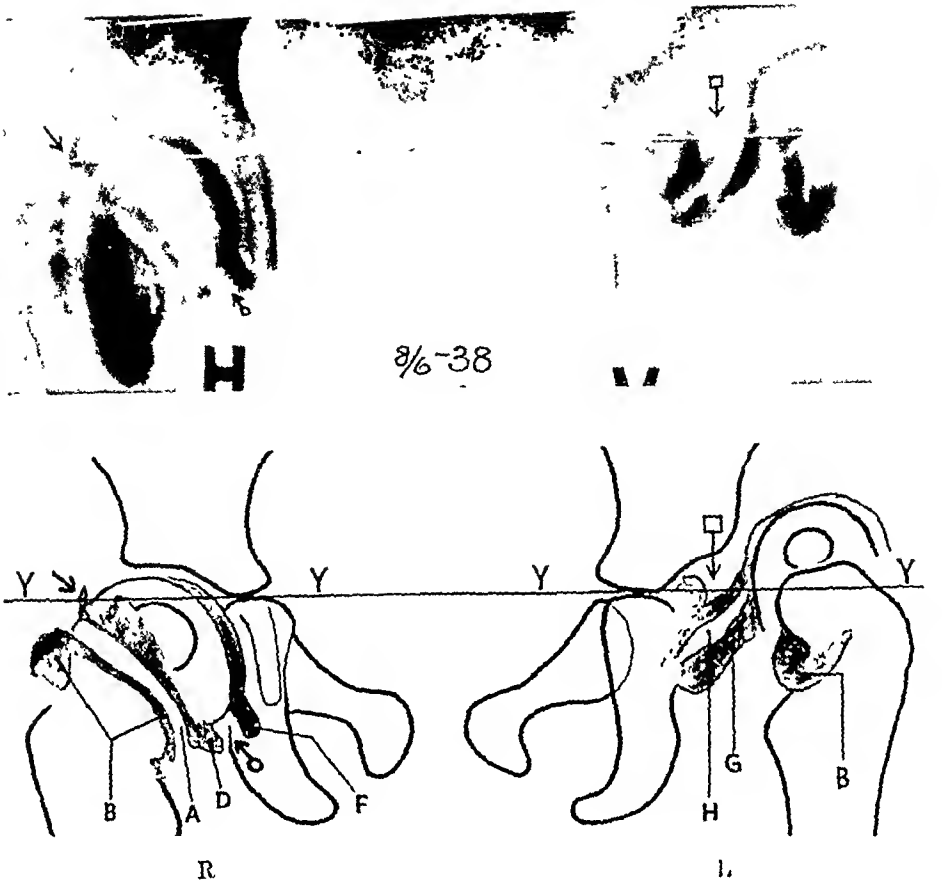

Fig. 1.
Arthrogram of the hip joints of a ♂ aged one year and ten months. The right hip is normal. Congenital dislocation of left hip.

A, zona orbicularis;
B, contrast ring around the femoral neck;
D, contrast shadow lateral to the transverse ligament;
F, contrast medium in the lowermost part of the acetabular fossa medial to the transverse ligament;
G, capsular isthmus;
H, ligamentum teres;
Y—Y, horizontal line through the Y cartilage;
⟶, edge of the limbus fibro-cartilagineus;
□→, limbus fibro-cartilagineus bent back into the joint;
○→, transverse ligament.



R L

Fig. 2.
Case 1. J. 2908/45. H. F., ♀, 1 year and 10 months. Residuary condition following bilateral acute infectious arthritis of the hip. This picture favours a diagnosis of dislocation or severe subluxation of similar degree on both sides.

Fig. 3.
Arthrogram of the case shown in Fig. 2.
The right hip joint shows a severe subluxation, bordering on a dislocation. Great deformation of the femoral head and neck. In the left hip joint the head of the femur is small and conical, and has a short neck. Pronounced varus deformity. No dislocation or subluxation.

R L

Fig. 4.

Case 2. J. 4780/45, H. J. ♂. 1 year and 4 months.

Residuary condition following acute infectious arthritis of left hip. The Roentgen picture was interpreted as a severe subluxation. Reduction treatment was given.

R L

Fig. 5.
The same case as in Fig. 4, 1 and $^{3}/_{4}$ year later, at the age of 3 years and 2 months. The left hip is practically unchanged since the beginning of the treatment.

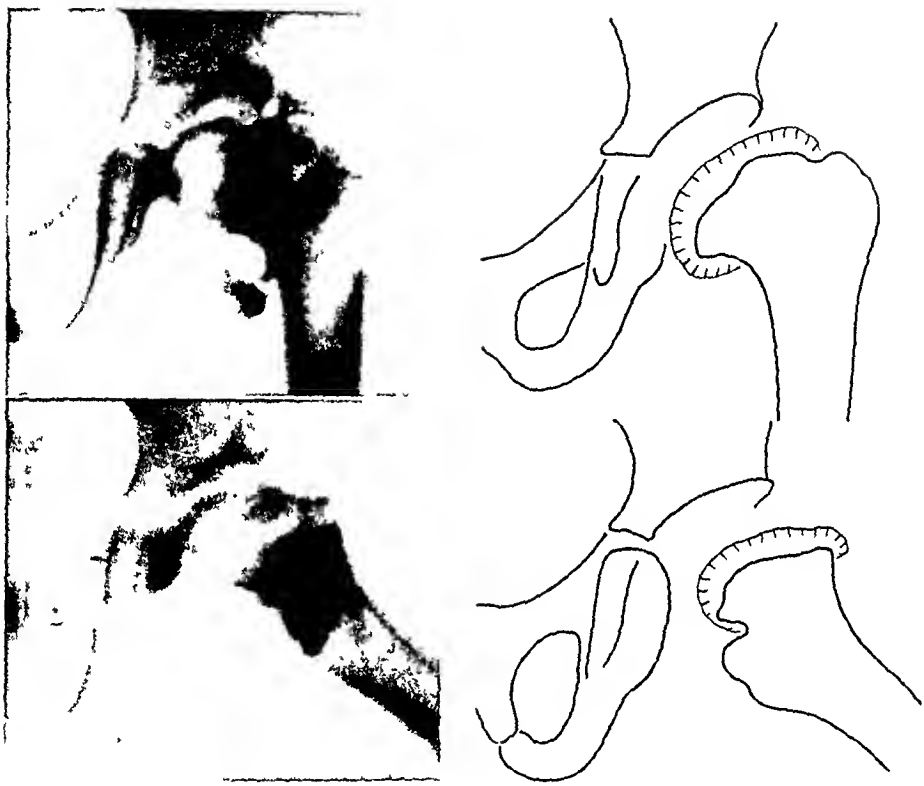

L L

Fig. 6.
The same case as in Figs. 4 and 5. Arthrogram on completion of treatment, showing that the greatly deformed head of the femur lies inside the acetabulum. The position was most likely the same from the first.

An attempt to reduce this was begun in our clinic 9 months after the onset of the disease, at the age of 1 year and 4 months. The entry in the Journal reads: "Reduction by placing the leg in the abducted position", from which we may infer that the operator did not need to give any real reducing movements, nor did he have any feeling of the head slipping back into the acetabulum. After 12 weeks' fixation of the trunk and both legs in plaster, with the hip joints flexed to 90° and abducted to 80°, the patient was allowed to resume careful walking practice. At night and during his midday rest his hips were kept in the abducted-flexed position in the usual way of routine post-operative treatment of congenital hip dislocations in our clinic. The situation in the hip joint was checked by Roentgen every second or third month. A year and nine months after the reduction the hip joint was still practically unaffected by the treatment (Fig. 5). The femoral diaphysis was displaced latero-cranially, as in a subluxation, while the neck was short and thick. Although fairly well developed, the acetabulum was not as vaulted as on the right side. The femoral head did not seem to be sufficiently supported by it, and a plastic shelf operation was contemplated. In order to ascertain the extension of the acetabular roof, an arthrogram was first taken.

Arthrography on 22/6, 1945, $1^3/_4$ year after the beginning of the treatment (Fig. 6), showed a flattened left femoral head, splayed like a mushroom and with deformed surface contours. The deformation of the head was particularly distinct in the Lauenstein position. The cartilaginous head was considerably lower than the head on the right side (0.6 and 1.3 cm respectively). The neck was short. Head and neck were at almost right angles to the shaft of the femur. The acetabulum was preserved, but the head bottomed badly, probably because of incongruence of the articular surfaces. In Lauenstein's position a broad pool of contrast medium could be seen, a sign that the contact between the head and the acetabulum is bad. The articular surfaces in the cranial part of the joint met distinctly. There was no marked border of the limbus fibro-cartilagineus. Although this is a partial subluxation, in that the head is displaced laterally, there is no great cranial displacement. The acetabular roof is well developed and supports the cartilaginous head satisfactorily. A plastic shelf operation is obviously not indicated.

That was one side of the problem. If we go back in time, however, and compare the recent picture with those taken at the beginning of the "reduction", the arthrogram puts the case in quite a different light (Figs. 4, 5, and 6).

Judging by the ordinary Roentgen photos, the cranial part of the femoral diaphysis was on the whole in the same position in relation to the pelvis at the end of the treatment as at the beginning. The arthrogram shows that its displacement has not been due to any subluxation or dislocation, but to a varus de-

formity and a deformed femoral head. In all probability the condition was the same already at the time of the "reduction", and the treatment has thus been not only without result, but meaningless.

Before any attempt at reduction is made in a case of suspected subluxation or dislocation following an attack of acute infectious arthritis of the hip, the position in the joint must be clearly diagnosed. This offers no difficulties in older children, but in *infants*, in whom the capital epiphysis of the affected hip is not yet observable by Roentgen, an arthrogram should be taken.

The point then arises, however, how soon after the acute attack an arthrogram can be taken without risking exacerbation of the inflammatory process. Our cases have come to us for orthopaedic treatment so late that that question has not been of immediate interest to us, and we have accordingly no experience of it. We would suggest, however, that at least six months should elapse between the end of the infection and the arthrography. Should a suspected distentional displacement be brought for an orthopaedic diagnosis earlier than that, a provisional "reducing" treatment in the meantime is suggested. The lines of any subsequent therapy can then be determined later on by means of arthrograms.

Summary.

The author shows that residuary conditions left by acute infectious arthritis of the hip joint in infants may easily be misinterpreted roentgenologically. As long as the epiphysis is not ossified, the shape and relative position of each joint element can only be definitely settled with the aid of arthrography, which must accordingly be resorted to before deciding the treatment.

Zusammenfassung.

Verf. zeigt, dass Restzustände nach septischer Koxitis bei Kleinkindern leicht röntgenologisch fehlgedeutet werden können. Die Form der Gelenkteile und ihre Lage zueinander lässt sich, so lange der Epiphysenkern fehlt, nur mit Hilfe der Arthrographie feststellen. Arthrographie muss deshalb vorgenommen werden, ehe die definitiven Richtlinien für die Behandlung bestimmt werden.

Résumé.

L'auteur démontre que les séquelles de coxite septique chez les petits enfants peuvent facilement donner lieu à des interprétations radiographiques erronées. La forme et la situation interne des éléments du membre ne peuvent être déterminées que par arthrographie aussi longtemps que manquent les noyaux épiphysaires. C'est pourquoi il faut pratiquer l'arthrographie avant de fixer les lignes définitives de traitement.

References.

Faber, A.: Untersuchungen über die Ätiologie und Pathogenese der angeborenen Hüftverrenkung. Leipzig 1938. — Severin, E.: J. of Bone & Joint Surg. 1939. — Severin, E.: Surg., Gyn. & Obst. 1940. — Severin, E.: Acta Chir. Scand. 1941. — Waldenström, H.: Nord. Lärobok i Kirurgi. Köpenhamn 1934. — Wiberg, G.: Ztschr. f. Orthop. 1941.

From the II. Surgical Clinic, University, Helsinki.
(Chief: Prof. P. E. A. NYLANDER, M. D) The Roentgen Department.
(Assistant Prof. GÖSTA JANSSON, M. D.)

Vertebra Plana Osteonecrotica (Calvé).

By

E. TIITINEN and K. WAHLFORS.

In 1925 CALVÉ published two cases of spinal disease clinically resembling tuberculous spondylitis but differing roentgenologically from the picture generally obtained in spondylitis. In 1924, 11 months before CALVÉ, the Norwegian BÜLOW-HANSEN, of the Surgical Society at Oslo, reported a similar case which he calls KÖHLER's disease of the spine. The disease bears CALVÉ's name, however, as he was the first author to report the disease both clinically and roentgenologically. In 1927 HARRENSTEIN suggested the denomination Vertebra plana osteonecrotica (V.pl.) which is now commonly used in the literature.

According to MARQUARDT 27 cases of V.pl. were published up to 1937. Some of these cases must, however, be considered doubtful. After 1937 16 new cases have appeared in the literature. 43 cases in all have thus been published. A few more boys than girls have been affected by the disease but as the total number of cases is so very small no statistical conclusions can be drawn. Judging by the very small number of cases the disease must be considered uncommon. FEDERSCHMIDT has, it is true, discovered 50 cases of tuberculous spondylitis and two cases of V.pl. in 3 years, but SUNDT discovered 430 cases of spondylitis in 23 years and only one case of V.pl.

Even if the clinical symptoms strongly resemble those of the tuberculous spondylitis, the earlier published cases, as well as the one reported in this paper, differ, however, from the common tub. spondylitis. It is evident that the final diagnosis can be made only roentgenologically.

As there has been no possibility of following the earlier published cases from the onset of the symptoms of the disease, the initial stage and the first roentgenological findings are somewhat obscure. As the case histories and the roentgenograms in our case have been obtained from various hospitals, *it was possible to reconstruct the course of the disease both clinically and roentgenologically from the very onset when the patient was admitted into hospital with acute symptoms.*[1]

This case concerns a boy, born 15th Dec. 1939, who has been treated in various hospitals for tuberculous spondylitis. He was transferred to the Roentgen Department of the Surgical Clinic at Helsinki on January 31st 1945, where the diagnosis *Vertebra plana osteonecrotica* was made. The patient was then placed in II Surgical Clinic on February 8th 1945 for further observation.

Anamnesis: No tuberculosis in family. Child normally developed. Earlier water-pox, otherwise healthy. On 2. IV. 1943 the patient began to complain of pains in the lower part of the abdomen. Appetite poor, but no vomiting and no diarrhoea. The next two days the abdominal pains were intense and the patient had to be kept in bed. 4. IV. 1943 rectal temperature 37.5 C. 5. IV. 1943 a physician was called in who sent the patient to hospital suspecting acute appendicitis. At the hospital the general condition was stated to be good. The pharynx slightly reddish. Nothing noticeable in lungs or heart during the whole stay in hospital. Blood picture 5. IV. 1943: hb 88 per cent, erythr. 4,880,000, ind. 1.04, leuc. 5,600 (eos. 0.5 per cent, staff forms 6.5 per cent, segm. forms 54 per cent, lymph. 31 per cent, monoc. 8 per cent). 10 days later the number of leucocytes was 3,100. Sedimentation rate 5. IV. 1943 27 mm, 21. IV. also 27 mm, 30. IV 14 mm. During the first days in hospital abdomen somewhat tender when pressed but no reason for operation seemed present. The abdominal symptoms disappeared, however, very soon but the patient was rather irritable and would neither sit nor stand. No tenderness in spine when tapped. Reflexes normal. Temperature 8—9. IV. 1943 39.0 C., on other days varying between 37 and 38 C. Pirquet —, Mantoux —, Mantoux 1 mg —. 30. IV. 1943 the patient was allowed to return home. The hospital diagnosis was Osteomyelitis vertebr. lumb. II? 10. 5. 1943 a renewed examination of the spine was undertaken and the diagnosis Spondylitis tub. vertebr. lumb. II was made. The patient was then treated for half a year in a sanatorium in plaster bed. General condition, here too, all the time good, with the exception of a slight bronchitis. In the autumn of 1943 the patient was discharged from sanatorium and was then kept in plaster bed at home.

Status praesens on admission to the Surgical Clinic 8. II. 1945: General condition good, structure ordinary, thyreoidea of usual size and

[1] Our thanks are offered to Prof. A. J. Palmén and Assistant Prof. Viljo Rantasalo, who have kindly lent us the case histories and the roentgenograms from their hospitals.

consistency. No enlarged lymphglands. Temp. 36.9 C. Urine 0. Nothing pathologic in lungs and heart. Blood picture normal. Pirquet —. The patient's walk normal. Spine straight with normal lumbal lordosis. No tenderness in spine when tapped. Turning and bending back normal and the patient does not mention any pains when doing so. Reflexes normal. Kernig —. The patient was discharged on 10. II. 1915 and allowed to move about without supporting bandages.

The roentgen findings are characteristic of this disease and the typical symptoms may be mentioned in short as follows:

1) A strong plane-parallel flattening down to a disc, generally of one vertebra only.

2) The intervertebral cartilages adjacent to the affected vertebra remain unaffected and retain their normal height.

3) The flattened vertebra is regenerated, at least partly, into a vertebra with increased calcium content and often with distinct spongiosa and corticalis.

In our case we have a series of roentgenograms of the affected vertebra; the first picture is taken 12 days after the first symptoms have set in, the last picture almost two years later. This series allows us to follow the development of the process from the onset right up to the phase of regeneration.

Our first picture (Fig. 1) of the case photographed 14. IV. 1943 *i. e.* 12 days after sickening, shows already changes in the 2nd lumbal vertebra. The affected vertebral body shows a clear decalcification. We see that the height of the vertebral body has diminished and that the flattening down has taken place plane-parallelly. We also notice that it has become somewhat broader and that the ventral contour is somewhat protruding in comparison with the adjacent vertebra. The intervertebral cartilage is of normal height, even an increase of the closest ones seems noticeable. No gibbosity can be observed. It is remarkable that the contours of the vertebral body are intact and may be clearly demarcated, notwithstanding their lower calcium content. No pathologic changes in the adjoining vertebra can be noticed.

The next picture (Fig. 2), 10. V. 1943, 38 days after sickening, shows great changes. The vertebra which has been slightly narrowed up to the present, and especially its ventral part, has now collapsed almost completely and has become wedge-shaped. We are now able to observe a slight sclerozing of an almost disc-shaped nucleus surrounded by a decalcified stratum. The affected vertebra protrudes above the adjacent one. The intervertebral

Fig. 1.

Fig. 2.

Fig. 3.

Fig. 4.

TIITINEN and WAHLFORS: Vertebra Plana Osteonecrotica (Calvé).

Fig. 5.

Fig. 6.

Fig. 7.

Fig. 8.

cartilage is still of the same thickness and does not show any signs of destruction. A suggestion of gibbosity or at least a straightening of the lordosis is now discernible.

In the picture of the 14. XI. 1943 (Fig. 3) a further flattening of the second lumbal vertebra is noticed and a more clearly sclerozed nucleus has narrowed down further.

The following pictures (Fig. 4 and 5), 23. IV. 1944, taken about a year after sickening, show signs of regeneration. The dorsal part of the vertebral body has increased somewhat in height and in the nuclear formation a suggestion of spongiosa and corticalis is noticed. This growth has taken place at the expense of the partly decalcified layer which has now narrowed down while the intervertebral cartilage has remained intact. The gibbosity has been straightened out. In the ventro-dorsal picture it may also be seen that the narrowed vertebra protrudes somewhat beyond the adjacent ones.

Half a year later, 4. IX. 1944 (Fig. 6) all these signs of regeneration appear still more distinctly. The intervertebral cartilages now seem somewhat higher than the rest, perhaps as a result of the treatment in plaster bed.

In the last pictures of our series (Fig. 7 and 8), taken on 31. I. 1945 we notice, that the vertebra has increased still further in height and now in its full breadth. The differentiation in spongiosa and corticalis has become more distinct. The regenerating vertebra still protrudes beyond the adjacent ones in all directions. The sclerozed and thickened vertebra is still surrounded by a decalcified layer, which may suggest that the regeneration process has not ceased yet.

The etiology of the disease still seems obscure. Tuberculosis and syphilis may be excluded with all certainty (SUNDT). The tuberculin test was negative in almost every case — in the case described in this paper as well. LÖHR stresses besides that the tuberculin test is of no diagnostic value as the diagnosis may be made even if the test is positive. The disease has been observed only in children, most of them under the age of 5 — a few children of more than 10 years of age have sickened. It is evident that only one vertebra becomes affected. The very few cases in which changes have been observed in more than one vertebra are considered doubtful Vertebra plana cases by many investigators. The disease is as a rule said to belong to the same group as the juvenile osteochondrites (Morbus Calvé-Legg-Perthes in the hip-

joint, Morbus Köhler in os naviculare pedis), in which aseptic osteonecrosis in the shape of an embolic infarct is considered present.

In many cases the onset of the disease is acute. SUNDT has found 15 cases with detailed case histories in the literature of which 6 have started with acute symptoms while 9 cases have had a more chronic course. 4 of the acute cases began with abdominal pains like our case. The patient had a temperature during the first days, up to 39 C. No other reason for the rise of temperature could be detected. As soon as 12 days after sickening distinct roentgenologic changes in the vertebra were stated; they had developed further when the second roentgenogram was taken, 38 days after sickening. There was then only a disc of the thickness of a few millimetres left of the affected vertebral body.

The disease never causes abscesses or fistulae. *We have thus an aseptic bone necrosis which develops very quickly, at least in some cases.* Bone changes arise more rapidly than in osteomyelitis, for instance. Sequester formations have not been observed. *The calcification increases and a regeneration of the vertebral body takes place gradually.* In one case (DENKS) the vertebra has regained its former height, in an other case (LÖHR and TÖRSTE) the former height has been almost regained. The vertebra generally remains somewhat lower than the adjacent ones but its calcium content is somewhat increased and its spongy structure is at least partly reformed. The cause of the reactive sclerozing which seems to set in very soon after the acute stage is unknown. Permanent gibbosity does not either develop in this disease. The slight kyphosis appearing in the beginning of the disease disappears later — in those cases, too, which have not been treated in plaster bed.

Changes in the blood picture have been examined and considered in a few cases only. SUNDT says that the sedimentation rate is never increased, probably due to the fact that there has never been an opportunity of observing the disease from the very onset. In the case we have observed, the sedimentation rate was 27 millimetres on the 3rd day after the patient sickened, a fortnight later still 27 mm and 11 days thereafter 14 mm. Leucocytosis was not stated, leucopenia was contrarywise observed on the 12th day — it may, however, have appeared in connection with the sulfonamid-therapeutics. A shift to the left was not observed. Blood findings, in this case, thus speak against a bacterial infection, not even a focal infection may be considered probable.

Injuries, even slight ones, may be considered an etiologic factor by crushing of the nutritive vessels. The disease may thus be of the same origin as lunatum malacia. In our case the mother tells us that the child had fallen some time before the symptoms were observed but she did not mention the fall when the child was in hospital the first time, which indicates that the injury was slight.

The greater number of the published cases — as also the present case — have first been treated as tuberculous spondylitis. But the roentgenogram of Vertebra plana is very characteristic and there should be no difficulty in making a differential diagnosis if the physician is acquainted with the symptoms of this very uncommon disease and has, perhaps, had the opportunity of observing the case for some time. In tuberculous spondylitis two or more adjacent vertebra are often affected and the intervertebral spaces narrowed whereas only one vertebra is affected in V.pl. and the intervertebral cartilages retain their normal height. In V.pl. regeneration starts at an early stage and the flattened down or only disc-shaped vertebra begins to increase in height. *In the increasing vertebra differentiated structure with corticalis and spongiosa may be discerned.* This phenomenon never occurs in tuberculous spondylitis, in which during the stage of healing a sclerozing of the collapsed vertebra only is noticed. Finally a healing into one stiff block consisting of several vertebrae takes place in the tubercrulous spondylitis.

The healing tendency seems to be good in V.pl. but the case should be treated in plaster bed for some time. Even if this kind of treatment has been given in the initial stages it cannot interrupt the development of the process (SUNDT, HANSON) but it affords improved healing possibilities. The duration of treatment is shorter than in spondylitis and is determined by the regeneration of the vertebral body observable roentgenologically.

Summary.

The authors give an account of a case of Vertebra plana osteonecrotica, a three and a half year old boy, who was taken ill with acute abdominal symptoms and a rising temperature. Already twelve days after the beginning of the acute symptoms, decided changes in the corpus vertebrae L II were noticed during the X-ray examination. The changes increased very rapidly until only one a

few millimeter thick lamella of the affected vertebra remained. The patient was afterwards treated for about two years for tuberculous spondylitis, but was referred to the roentgen department of the University Surgical Clinic for control examination where the case was diagnosed as vertebra plana osteonecrotica. The progressive and regressive phases of the disease are illustrated by a series of roentgenograms. About two years after the time when the patient fell ill the flattened vertebra has increased in height to one with a clearly differentiated corticalis and spongiosa.

Zusammenfassung.

Verff. berichten über einen Fall von Vertebra plana osteonecrotica bei einem $3^1/_2$-jährigen Knaben, der an akuten Bauchsymptomen mit Temperatursteigerung erkrankt war. Schon 12 Tage nach dem akuten Einsetzen der Symptome wurden bei der Röntgenuntersuchung deutliche Veränderungen im Corpus vertebrae L II beobachtet. Die Veränderungen nahmen sehr rasch zu, bis von dem angegriffenen Wirbel nur noch eine einige mm dicke Scheibe vorhanden war. Der Kranke wurde darauf etwa 2 Jahre lang als tuberkulöse Spondylitis behandelt, wurde aber zur Kontrolluntersuchung der Röntgenabteilung der Chirurgischen Universitätsklinik überwiesen, wo die Diagnose Vertebra plana osteonecrotica gestellt wurde. Die progressive und die regressive Phase im Krankheitsverlauf werden durch eine Serie Röntgenaufnahmen veranschaulicht. Etwa 2 Jahre nach Einsetzen der Erkrankung hat der flachgedrückte Wirbel wieder an Höhe zugenommen und stellt einen Wirbel mit deutlich ausgebildeter Kortikalis und Spongiosa dar.

Résumé.

Les auteurs exposent un cas de vertèbre plane ostéonécrotique chez un garçon de 3 ans $^1/_2$, qui débuta par des symptômes péritonéaux accompagnés d'élévation de température. 12 jours seulement après le début des symptômes aigus, on observa à la radiographie des altérations visibles dans le corps de la deuxième vertèbre lombaire. Ces altérations se développèrent rapidement, jusqu'à réduire la vertèbre malade à un disque épais de quelques millimètres. Le malade fut alors traité deux ans durant pour

spondylite tuberculeuse mais fut remis à la division de radiographie de la clinique chirurgicale de l'Université pour contrôle; on y diagnostiqua une vertèbre plane ostéonécrotique. Les phases progressive et régressive de la maladie sont illustrées au moyen d'une série d'images radiographiques. Deux ans après le début de la maladie, la hauteur de la vertèbre atrophiée a crû et présente une démarcation nette entre le tissu spongieux et la partie corticale.

Literature.

Bülow-Hansen: Forhandl. i Oslo Kirurg. Foren. 1924, p. 14. — Calvé: J. Bone Surg. 1925, 7, p. 41. — Denks: Zbl. Chir. 1938, p. 338. — Federschmidt: Roentgenpraxis 1935, 5, p. 801. — Hanson, Acta Chir. Scand. 1930, 67, p. 461. — Harrenstein: Zschr. orthop. Chir. 1927, 48, p. 70. — Löhr: Chirurg 1933, p. 569. — Marquardt: Z. Orthop. 1937, 66, p. 343. — Sundt: Acta Chir. Scand. 1935, 76, p. 501. — Törste: Zbl. Chir. 1939, p. 635.

From the Children's Hospital at the University of Helsinki.
(Chief: Prof. A. YLPPÖ, M. D.)

Splanchnectomy by Megacolon Congenitum.

By

P. I. TUOVINEN.

Since HIRSCHSPRUNG in 1886 described a picture of Megacolon congenitum many attempts have been made to classify the etiology and therapeutics of this illness. HIRSCHSPRUNG supposed the dilatation and hypertrophy of the large intestine to be some sort of congenital giant growth in this part of the intestines. It appears that the illness cannot be entirely explained as being a giant growth, as it is characterized by both functional derangements and by anatomical changes. The anatomical changes indicate derangements in the functions of the bowels, while the functional changes indicate neurogenic etiology. Discussion has arisen on account of these two theories (HÄMÄLÄINEN 1939). EHRENPREIS (1945) observes that the primary factor in the genesis of the illness is a derangement in the discharging mechanism of the bowels. The anatomical picture of the illness develops secondarily, for instance between the ages of 3 weeks to 3 months.

If we disregard the symptomatic megacolon, which, for instance, is found in spina bifida occulta or in anal restriction the therapeutics based on etiology have shown poor results. Because the etiology of the illness has been unclear it has been impossible to arrive at appropriate therapeutic measures. The operations have been palliative, such as the splitting of the rectal valves, dilatation of the anal opening or incisions performed directly on the bowel, such as resection of the intestine. The most advantageous method of the last mentioned operation is the drawing forward of the intestine, "Vorlagerung", after which resection is performed. In this way it has been possible to remove the dilated part and to

fix the intestine in the front, thereby preventing it from sinking towards the bottom of the pelvis. This method has been charged with comparatively great mortality, which, however, has varied much in the different statistics.

It seems as if great progress has been made in therapeutics through the sympathicus surgery. Although it cannot be indisputably proved that the illness has a permanent sympathicus tonus, the disruption of the sympathicus bundle has been shown to have a favourable influence on the peristalsis of the intestines to such an extent that the intestine wall has contracted for a long time, possibly even permanently. Chance has probably played a part in the arrival at this solution of the problem, because the Australians ROYLE and WADE observed that the peristalsis of the intestine was more lively after lumbal sympathectomia. For this reason they suggested in 1927 sympathectomy as a therapeutic measure also in megacolon.

Lumbal sympathectomy was actually adopted in various places as therapeutics in this illness and this method was also introduced in Scandinavia. The incision is, however, comparatively hazardous in small children, especially as the general condition owing to the illness, is much weakened.

A couple of years before the beginning of the Second Great War resection of the splanchnicus was taken into use as therapeutics. This idea was brought forward by ADSON and the master of the sympathicus surgery, LERICHE. The first cases were published by them in 1937. Through them the method was brought to Finland, where HÄMÄLÄINEN performed the first operations in 1938. During the spring term of 1945 some cases have been treated with splanchnicus-resection at the Children's Hospital at the University of Helsinki.

The cases are of a late date but the results show that this method may possibly be better than those formerly tried, and it may consequently be of interest to explain the method on the basis of these cases.

The advantage of this operation is that like lumbal sympathectomia it is performed extra-peritoneally, but is less exhausting to the patient than the latter.

I shall below relate in short the five cases operated by me. In the histological examination we have in all cases been able to state sympathicus tissue. The operations have been made under aether anaesthetic.

Case 1. A boy, age 3 years 10 months, received into the Children's Hospital 23. 4. 45.

Function of stomach and bowels good until Christmas 1944, when appetite grew bad. The movements irregular, small, hard, no rheum or blood. Movements even during the night, involuntarily. The patient has lately not had strength to join in other children's games. The appetite has grown continually worse. Decreased alarmingly in weight, on account of which a visit was paid to the doctor, who sent the patient to hospital. The doctor who sent the patient felt a tumour in the abdomen in the centre line between the navel and proc. xiphoideus.

St. pr. Pale, somewhat weak. Weight 12,100 grams. Reduced subcutis. Reduced turgor. "Rosenkranz".

The muscular walls were soft. In the centre line somewhat to the right and reaching from the epigastrium to a couple of cms. under the navel, was a 10—12 cms. long, hard, knotty resistance, not tender. The liver perentiently not enlarged.

Per rectum: In rectum considerable quantities of medium hard scybala the size of a thumb-end. Ampulla recti great.

Decursus: The bowels discharged only with enema given every other day. Spontaneous movement 30. 4. (7 days after entering hospital.) After that again enema. No increase in weight.

Operation 8. 5. 1945. *Splanchnectomia l. sin.* The incision 8 cms. long. The nerve bundle was found to be 1 mm. thick and 2 cms. of same were removed, this being n. splanchnicus major, while minor was not distinctly separable. Further a great part of ganglion coeliacum was removed. After this the sympathicus bundle was prepared near the kidney and 1 cm. was removed. Catgut sutures and a couple of silk sutures in the muscles.

The day after operation the bowels discharged by enema. Sixth day after operation spontaneous movement. After ninth day spontaneous movements, first 2 consecutive days, then every other day.

The patient was discharged 22nd day after operation.

Case 2. A boy, age 10 months.

Weight at birth 3,780 grams. Function of bowels generally sluggish. Was received into the Children's Hospital for weakness (Dystrophia) 2 months previously. After return from hospital movement every 4th day.

St. pr. Pale and weak. Weight 5,550 grams. Elasticity and turgor reduced. Abdomen swollen, not visible peristalsis. By palpation resistance felt to left between navel and sp. iliaca ventralis.

Per rectum: Ampulla great, hard lumps of evacuation.

Decursus: Vomiting slight, almost every other day. Often enema and some spontaneous movement.

Operation 22. 5. *Splanchectomia l. sin.* Cross incision. At aorta several lymph glands, which hampered detection of nerve bundle. Splanchnicus thin, of which 3 parts removed, together 2 cms.

After sixth day daily movement. 2. 6. Small pneumonial focus at right top.

Fig. 1. Case 1. A boy, 3 years 10 months. Irrigoscopy before splanchnectomy.

Fig. 2. Same case, 5 weeks after operation.

Fig. 3. Case 2. A boy, 10 months. Irrigoscopy before operation.

Fig. 4. Case 2. 8 days after operation.

Fig. 5. Case 3. A boy, 9 months. Irrigoscopy 8 days after splanchnectomy.

Fig. 6. Case 3. 16 days after operation.

Case 3. A boy, age 9 months. Entered 18. 5. 1945.

Weight at birth 3,700 grams. While patient received mother's milk movements several times a day. After that irregular movements with increasingly longer intervals, at the same time much evacuation intermixed with hard lumps. Abdomen much swollen, after movement normal. Appetite and development good in spite of suffering. Arrived at hospital on account of no movement in 18 days.

St. pr. Weight 8,000 grams. Lively. Elasticity and turgor normal. Abdomen and muscular walls normal.

Per rectum: Ampulla great, hard lumps palpated in rectum.

Operation 23. 5. 1945. *Splanchnectomia l. sin.* Cross incision as in previous cases. Splanchnicus in the usual place, 2 very thin and 1 thick, of 1 mm. thickness. Of these all were recceded.

2 days after operation movement spontaneous. Fifth day after operation yellow and normal evacuation. 4. 6. condition good, daily movement. Some rheum in the evacuation.

Case 4. A boy, age 7 years. Entered 16. 6. 1945.

Stomach and bowels function normally until 2 years of age, when patient began to defecate involuntarily. The attempts of the mother to make movements of the child regular unsuccessful. At movements the patient complains of pains in the anal opening. The consistency of evacuation has been of medium firmness.

St. pr. Weight 21 kgs. Looks healthy. Nutr. condition good.

Abdomen somewhat swollen, muscular walls soft. Small fissure in anus, only very little tender.

Per rectum: Ampulla great, hard lumps palpated in rectum.

26. 6. *Splanchnectomia l. sin.* N. splanchnicus branches immediately after passing through the diaphragma, which makes it somewhat difficult to detect. The nerve (both spl. major and minor) recceded in lengths of 1 cm.

Spontaneous movement only 11th day after operation. Then spontaneous movements every second day. Patient sent home 18th day after operation. At discharge the abdomen swollen as before. Roentgen-examination 17 days after operation showed no change in lumen of intestine.

Case 5. A case of relapse. A boy, 3 years. Entered 20. 6. 1945.

Abdomen has always been swollen. The child has always had difficulties of evacuation. At age of 3 months deformity of intestine was stated in a hospital in Viipuri. At age of 2 years 21. 8. 44 splanchnectomy was performed in the district hospital at Mikkeli. After the operation the patient had proper spontaneous movement during one month, after which the mother had to recommence with enema. The abdomen has become still more swollen.

St. pr. Weight 13 kgs. Nutr. condition somewhat weakened. Complexion a little pale, elasticity reduced, turgor normal. A scar after leftsided splanchnectomia.

Abdomen much swollen, muscular walls soft, thin, receding. By left

hypogastrium is felt a 15 cms. long resistance the thickness of a fist, which disappeared after enemas.

26. 6. *Splanchnectomia l. dx.* N. spl. major 2 mms. thick, easily detected, 1 cm. length receded.

Spontaneous movement 12 days after operation, then enema and some spontaneous movements. 18 days after operation the abdomen was as swollen as before operation. 4 weeks after operation quantities of scybala in ampulla felt per rectum. Roentgen-examination 3 weeks after operation shows no changes in the lumen of intestine.

The patient has not been helped by second operation either.

From the above described 5 cases it appears that no complications occurred, except the small pneumonial nest in the child with dystrophia (Case 2) 11 days after operation.

I wish to mention that I have left out of the therapeutic measures the obvious method of teaching the child to defecate regularly. With the children in question this would have met with no success and could have been tested only in one case. Formerly, a few years ago, I caused sympathicus blockades by injecting solution of novocain near the spot where at the operation the nerve was to be receded. As these blockades have a passing effect and splanchnectomy has gained greater support, I have in the above cases performed the operation immediately without previous blockades.

3 cases out of the five have profited by the operation. Those which have not were of the ages 7 and 3 (Cases 4 and 5). It seems as if the operation has better effect at a younger age, especially in infants, in which the anatomical changes in the intestine (dilatation and hypertrophy of the wall of the bowel) have not yet become too great. It appears to indicate that the treatment of older children (over 3 years) should be begun by blockading the splanchnicus, and if the effect of the blockade is favourable, continued by the treatment with splanchnectomy.

Summary.

In Finland HÄMÄLÄINEN began in 1938 to use splanchnectomy by Megacolon congenitum. The author has during 1945 performed the operation on 5 cases between the ages of 9 months—7 years. In three cases the peristalsis has begun to function after splanchnectomia and roentgenologically the dilatation of the intestine has receded. The two cases which did not react were of the ages 7 and 3, the latter a case of relapse after splanchnectomia a year

previously. The author suggests that splanchnectomy should not be performed on children over 3 years before several splanchnicus blockades with favourable effect have been made.

Zusammenfassung.

In Finnland verwendete HÄMÄLÄINEN als erster die Splanchnektomie bei Megacolon congenitum. Verf. hat im Jahre 1945 in 5 Fällen bei Patienten im Alter von 9 Monaten bis 7 Jahren die Splanchnektomie vorgenommen. In 3 Fällen begann die Peristaltik nach der Operation zu funktionieren, und röntgenologisch liess sich ein Zurückgehen der Darmdilatation nachweisen. Die nicht ansprechenden Fälle waren ein 7jähriges und ein 3jähriges Kind, und zwar lag bei letzterem ein Rückfall nach einer 1 Jahr früher vorgenommenen Splanchnektomie vor. Verf. ist der Ansicht, dass die Splanchnektomie im Alter von über 3 Jahren nicht zur Verwendung kommen soll, ohne dass eine oder mehrere vorausgehende Splanchnikusblockaden günstige Wirkung gegeben haben.

Résumé.

C'est HÄMÄLÄINEN qui utilisa le premier en Finlande la splanchnectomie dans le mégacolon congénital. En 1945, l'auteur a exécuté la splanchnectomie dans 5 cas chez des malades âgés de 9 mois à 7 ans. Dans 3 cas, la péristaltique a commencé à fonctionner après l'opération et la radiographie a permis de constater que la dilatation avait rétrocédé. Un enfant de 7 ans et un de 3 ans ne réagirent pas; le second cas était une récidive postérieure d'un an à une splanchnectomie. L'auteur est d'avis qu'au-dessus de 3 ans il ne faut pas recourir à la splanchnectomie avant d'avoir procédé à un ou plusieurs blocages du splanchnique dont les résultats ont été favorables.

Bibliography.

ADSON, cit. HÄMÄLÄINEN. — EHRENPREIS, TH.: Nord. med. *27*, 1419, 1945. — HIRSCHSPRUNG, cit. DRACHTER-GOSSMAN, Chirurgie des Kindesalters. — PFAUNDLER-SCHLOSSMAN, Handbuch der Kinderheilkunde. Bd. 9. Leipzig 1930. — HÄMÄLÄINEN, MARTTI: Duodecim *55*, 945, 1939, and Nord. Med. *10*, 1312, 1941. — LERICHE, cit. HÄMÄLÄINEN. — ROYLE and WADE, cit. HÄMÄLÄINEN.

On the Practical Importance of the Clinical Determination of the Basal Metabolic Rate in Thyrotoxicosis.

By

JOHANNES WAHLBERG.

As I have emphasized in my monography on the diseases of the thyroid gland in Finland[1], the goiter endemic in Finland is characterized in the first place — next to the high frequency of adenomas — by an abundant occurrence of thyrotoxicosis. As a consequence thereof, it is of a relatively great practical importance to form a correct judgment on cases of thyrotoxicosis in a clinical material, especially with regard to the diagnosis and the therapy. This concerns in the first instance surgery and internal medicine, but to a certain degree also all other branches of medicine. It has been believed that in the clinical determination of the basal metabolic rate a method had been found, which would be specially apt to simplify some of the most difficult problems connected with the clinic of thyrotoxicoses. It is therefore not to be wondered at that it has called forth a great interest among our clinicians and that the majority of the larger hospitals in our country now have a Krogh's metabolism apparatus at their disposal.

In my thyroid monography I have paid special attention to the question of the determination of the basal metabolic rate in cases of thyrotoxicosis, its practical importance and the numerous deficiencies adhering to it. It has become evident since then that the technique as well as the judgment of the results still leave much to be desired. It therefore appears to be worth while to

---

[1] Studien über die Schilddrüsenkrankheiten in Finnland. Acta med. scand. XCIV, 1938, p. 181—195.

take up once more the question of the practical importance of the clinical determination of the basal metabolic rate.

According to the opinion now prevailing it can hardly be disputed that the tendency to a pathological increase of the activity of the organism as a whole and the symptoms pertaining to it from practically all systems of organs, can be considered as something specially characteristic for the clinical picture in thyrotoxicosis. Every manifestation of life of the organism presupposes a process of combustion with an oxygen consumption and carbon dioxide production. It is therefore evident, that a clinical test, which would render a numerical measurement of the intensity and its variations in this process of combustion possible, could be supposed to facilitate to a considerable degree the sometimes great difficulties at the diagnosis of thyrotoxicosis as well as at the estimation of the degree of the disease and of its variations. Does the clinical determination of the basal metabolic rate fulfill these claims in such a way as this seemingly so simple and in reality so very subtle method of examination is now handled here? Its practical value for the clinic of thyrotoxicosis depends on this.

Theoretically speaking one might suppose that this question could no doubt be answered in the affirmative. In practice, however, the matter is far from simple, as is often the case when a physiological test is applied to pathological material, the sick human being.

Already under *physiological conditions* the determination of the basal metabolic rate of man presents great difficulties.

By measuring the respiratory gas exchange, that is the quantity of oxygen inhaled and carbon dioxide exhaled in a unit of time (with Krogh's apparatus only oxygen absorption), we aim at getting as exact an idea as possible of the intensity of the combustion process, which is going on in the organism at the time of examination. Since, as already named, every manifestation of life presupposes such a process of combustion, it would be possible to imagine theoretically a minimum of gas exchange in a tissue, separated from the rest of the organism, which lives, but in all other respects does not fulfill any functions. This would be an *absolute basal metabolic rate.* As soon, however, as this tissue is envisaged as a component of an organ and the organ as part of a living organism, a measurement of such a process of combustion, which corresponds to such a minimum of life without function,

would be excluded a priori. Thereby the possibility of determining the absolute basal metabolic rate of a healthy individual — whose respiratory gas exchange, even in case of a maximally complete repose can only be a *relative basal metabolism* — is likewise eliminated.

We know that the combustion within the organism is influenced by all functions of the organs, such as muscle tonus, the activity of the organs of circulation and digestion, and also by psychic function. The value obtained for the relative basal metabolic rate is thus composed of the absolute basal metabolic rate plus the value which corresponds to the functions of the organs and the psychic activity, that cannot be eliminated under repose.

It has been agreed upon for practical reasons, that basal metabolism (standard metabolism) should mean the respiratory gas exchange under certain conditions, *i. e.* after 12 hours' rest and fasting, and it has been stated that it possesses under these circumstances a remarkable tendency to keep stable and to remain on the level of an average gas exchange of a great number of persons of the same sex and age and with the same weight and length.

But this is a truth with modification. In the first instance, the individual psychic and physical characteristics of every subject, which cause an increase of the gas exchange above the value corresponding to the theoretical absolute gas exchange, necessarily varies from case to case, and to a degree impossible to determine. Secondly, it is equally impossible to estimate precisely the error, which will arise just as surely as the one mentioned, when comparing the value obtained with the normal value, calculated by the aid of tables, of a person of the same sex and age and with the same weight and length. Moreover we must add to this all those unusually numerous sources of error, which characterize this method of investigation, and are caused by the investigator, the subject examined or the apparatus. The most important of these errors are dealt with in my thyroid monography. The space does not allow to discuss them here.

The above named statements elucidate the fact, that we have — when determining the basal metabolic rate of healthy persons — to take into consideration numerous sources of error, of which some occur constantly and others sporadically. Their influence on the result can certainly be affected by some factors, such as competence of the investigator, the qualities of the appliances

and a selection and training of the subjects to be examined. These pitfalls, however, can never be completely eliminated and their influence on every separate case cannot be estimated. Experience proves that this is the case, that when testing healthy individuals results are obtained, which even under most favourable conditions may vary from the calculated normal value up to 5 per cent. in the negative and 10 per cent. in the positive direction, in some cases even more.

How much more will not these sources of error make their influence felt in examinations of *pathological material* and specially of thyrotoxic patients.

As a matter of fact, just such symptoms are characteristic for thyrotoxicoses, as are related to somatic or psychic functions, which are apt to complicate the carrying out of a reliable basal metabolism determination, owing to their having a tendency to heighten the respiratory gas exchange above its basal value in different cases and under different circumstances, varying from case to case to a degree, which cannot be determined in every separate case. Among such symptoms let only some of the most important ones be named here: physical and psychic lability and lack of self-control with for this disease characteristic, more or less semipurposeful movements, hyperactivity, varying moods, exaggerated joyfulness and deep depression, tremor, muscular asthenia with a compensating hypertonus of the musculature, an increase of the respiratory frequency and of the activity of the auxiliary respiratory muscles, disturbances in the circulatory organs with tachycardia, which to a changing degree heightens the activity performed by the heart muscle itself, a tendency to myocard damage with heart failure and to hypertony, an increased intestinal peristaltic etc.

It is furthermore known to be a characteristic of the thyrotoxicosis that no symptom is pathognomonic, but that they all vary from case to case, as they occur in an extension and to a degree, infinitely varying.

Moreover we must take the fact into consideration, that in thyrotoxicosis not only the real basal metabolism, but also the dynamic effect of every increase in the physical and psychic activity upon the gas exchange is heightened to a degree, varying from case to case as to extension and intensity, which cannot either be determined.

The basal metabolism determination differs from all other

methods of clinical examination in the respect, that a reliable result presupposes an active participation on the part of the person examined and a cooperation between the latter and the examiner, which it is specially difficult to achieve just in cases of thyrotoxicosis.

Lastly we have — under the here prevailing circumstances — not enough personnel or other resources, which would make it possible that the determination of the basal metabolic rate should be effectuated always by a physician, sufficiently familiar with and experienced in the physiology of the methodics and its technical performance, either personally or under his immediate guidance or supervision.

Just in borderline cases and uncertain cases we must therefore take into consideration, that the value obtained may not show any increase or only such a small one, that this may depend upon the same factors, which cause an increase already under physiological conditions, or that an unexpectedly high value may be imagined to result from the sources of error recently named. In such cases which are diagnostically clear owing to other clinical symptoms, the determination of the basal metabolic rate naturally becomes superfluous.

This eliminates the practical diagnostic importance of the clinical determination of the basal metabolic rate in cases of thyrotoxicosis, such as it is being performed under the circumstances here, nearly exclusively by laboratory assistants without sufficient theoretical and practical training and without competent supervision.

A somewhat greater value may be ascribed to *the basal metabolism determination as a means of following the variations in the intensity of the disease.* But for this a practically speaking factory-like extent of apparatus and staff is necessary, as is the case in the big thyroid clinics in the United States, which cannot be accomplished under the here prevailing circumstances. *Even in this respect it must be owned that it is best to content oneself with the rest of the clinical symptoms.*

It can certainly be said against this point of view, that it is always best to have as many factors as possible to build one's opinion on. This argument applies as a matter of fact to all other clinical symptoms of thyrotoxicosis, but it does not, because of the above named facts, bear upon the determination of the basal metabolic rate in cases of thyrotoxicosis.

In my thyroid monography I have expressed the opinion, which

was generally adopted among specialists at the time when this work was published, that a satisfactory clinical and scientific study of the thyroid diseases could not be carried on without determination of the basal metabolic rate. The experience with about one and a half thousand cases of basal metabolic determination, performed for the most by me personally, compared with clinical observations on results of operations and with the postoperative histological investigation, have with an evidence increased throughout the years, brought me to the conviction, *that the clinical determination of the basal metabolic rate in cases of thyrotoxicosis, such as it is carried out here, is of a very doubtful value when compared with the observations of other clinical symptoms and the histophysiological picture. It is as a matter of fact so seldom of any use and so often apt only to lead astray, that it can, for the time being, practically speaking be relinquished altogether.* Scientific investigations must naturally be considered an exception. But the tests should then be made by the investigator himself, provided that he is familiar with the physiological foundations as well as with the practical methodics, which unfortunately has not always been the case until now.

Concerning the hypothyroses the circumstances are somewhat different in such a respect, that the subnormal values of the basal metabolism determination are as a rule more reliable, than the abnormally high ones. Moreover the clinical picture of some light forms and subhypothyrotic states is sometimes so difficult to interpret, that a decreased basal metabolism can play a relatively important role for the diagnosis and therapeutics. But such cases are anyhow rather rare, and one is in any case usually obliged to use thyroid preparations ex juvantibus according to all other clinical symptoms.

Summary.

The author warns of an overestimation of the value of the basal metabolism test in thyrotoxicosis. He thinks, that the experience has shown, that the method as a guide for the diagnosis and the therapy in thyrotoxicosis, especially in slight and in borderline cases, so seldom is of real value and so often is directly misleading, that it with impunity may be abandoned from practical clinical use, if it is not carried out in a laboratory filling high demands or of an experienced expert personally or under his direct supervision.

Zusammenfassung.

Verf. warnt vor einem Überschätzen der Bedeutung der Grundumsatzbestimmungen bei Thyreotoxikose. Er ist der Ansicht, dass die Erfahrung gezeigt hat, dass die Methode für die Diagnose und Therapie der Thyreotoxikose, besonders in leichten Fällen und Grenzfällen, so selten von wirklichem Nutzen und so oft direkt irreführend ist, dass sie aus dem praktisch-klinischen Gebrauch ohne weiteres gestrichen werden könnte, falls sie nicht in einem, hohen Forderungen entsprechenden, Speziallaboratorium oder von einem erfahrenen Fachmann persönlich oder unter seiner direkten Leitung zur Ausführung kommt.

Résumé.

L'auteur met en garde contre une surestimation de la valeur de la détermination du métabolisme basal dans la thyréotoxicose. Il estime que l'expérience a démontré que comme indicateur du diagnostic et de la thérapeutique de la thyréotoxicose, spécialement dans les cas légers ou dans les cas-limites, la méthode a si rarement une signification pratique et conduit si fréquemment à des conclusions erronées qu'elle peut être supprimée sans inconvénient de la pratique clinique, à moins qu'elle ne soit effectuée dans un laboratoire spécial de très haut standard ou bien par un spécialiste compétent personnellement ou sous son contrôle immédiat.

From the Surgical Children Department of the Hospital
"Diakonissanstalten" in Helsingfors.
(Surgeon in Chief: G. WALLGREN, M. D.)

Treatment of the Congenital Flat-Foot.

By

G. WALLGREN.

Pes calcaneovalgus cong., sometimes called a mallet foot, is not so scarce, as many people believe. According to KÜSTNER it was met with in 5 per cent of all the children examined by him, and SPITZY found this deformity in 1 per cent of his cases. But the author anyway considers these figures even too high, at any rate what regards the population in Finland. This deformity in its more severe form occurs about as frequently with us as the congenital club-foot, or in about 1 promille of the cases.

The deformity in question (Figure 1) is characterized by a convexity of the sole, which makes the dorsum straight or slightly concave. The foot may often be supernormally dorsoflexed, to such an extent that it touches the anterior side of the leg, whereas the plantar flexion is reduced. The lowest point is the heel, which stands in valgus. The fore-foot also is pronate and simultaneously abducted, in such a way that os naviculare and caput tali protrude on the medial side of the foot, which appears long.

Nowadays this deformity is considered due to arrested fetal development (BÖHM). Amniotic inhibition as well as faulty disposition of the hereditary plasm may also occur.

The treatment should be started as early as possible, preferably on the 10th day of life, or as soon as the mother can come regularly once a week with her child to the surgeon in charge. These measures should be taken in order to prevent the deformity from developing into irreparable flat-foot, causing the gravest trouble to the adult.

According to experience gained, the condition of such a foot can no longer be improved after the first year of life inspite of plaster bandages, operations and prolonged treatment. The critical

time with regard to the treatment is the age when the child begins to walk, as the surcharge aggravates and fixes the foot deformity in question. That is the reason why the treatment must be finished before the child takes an upright position.

Different kinds of splints for correcting this deformity are mentioned in the orthopaedic manuals. They prove, however, to be

Figure 1. Congenital flat-feet.

Figure 2. Congenital flat-feet under treatment with elastoplast bandage.

rather impossible in practice, and are unpractical even at a special hospital with its specially trained staff.

A considerable improvement was introduced by SPITZY, who pressed the foot together like that of a Chinese woman in olden times, whereupon the position was fixed with flannel bandages, fastened with a mastic solution. Everyone who has the least idea of little children's ability to wet themselves, understands how inconvenient such a treatment is in practice.

HOHMANN recommends the method used by him according to which the foot is redressed to begin with in the same way as in the treatment of club-feet, whereupon the Achilles tendon is lengthened and the foot is finally tenotomized through its posterior capsula. As the foot besides must be fixed by plaster bandages, that must be repeatedly changed, anyone can understand the difficulties this should lead to in practice. Any cleanliness is out of the question, provided the child is not lying at a special clinic.

The English authors, as *e. g.* WALTER MERCER and NORMAN C. LAKE, in their special papers strangely enough have altogether overlooked or but mentioned in passing this complaint, which causes severe invalidity, whereas the club-fot, which immediately strikes the eye but leaves a slighter degree of invalidity, is always discussed in detail.

The Author's Method.

Elastoplast has proved very suitable for correcting deformities. The advantage of elastoplast as compared with any other adhesive plaster is its elasticity permitting such a degree of movability, that it does not press or injure the skin. Even the very sensitive skin of little children endures well an elastoplast bandage. As elastoplast does not absorb fluid, it may be used with advantage, inspite of the infants being always wet.

The author began consequently to use elastoplast in the treatment of congenital flat-feet according to the following method.

The treatment is commenced with as early as possible. The foot is redressed with the hands without narcosis, and the entire foot is softened as much as possible. Os naviculare and caput tali are pressed into their correct places and the plantar arch is pressed upwards. The foot itself is transferred into drop-foot position, whereat the heel is pressed up- and backwards.

After the foot has been thus remodeled, the position is fixed with elastoplast as appears by the figures in the text.

Figure 1. Out of paste-board or thin cardboard is cut a 2 cm. wide strip, which is rolled into a compact roll, 1 cm. in diameter, and covered besides with elastoplast, which keeps the roll together and prevents it from absorbing fluid. The roll is applied under the foot at the place where the plantar arch should be.

Figure 2. The roll is fixed with a circular elastoplast strip, 10 cm. in length and 2 cm. wide = the elastoplast strip 1 in the Figures.

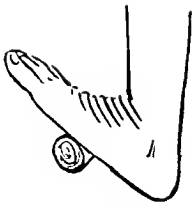

Fig. 1.

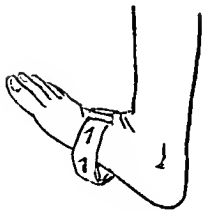

Fig. 2.

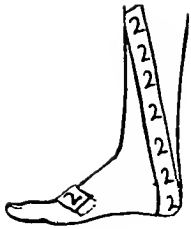

Fig. 3.

Fig. 1. a

Fig. 2. a

Fig. 3. a

Fig 4.

Fig 5

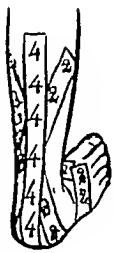

Fig. 6.

Fig 4 a.

Fig 5 a.

Fig. 7.

Sag. 38

Three more elastoplast strips from 2 to 3 cm. wide and about 15 cm. in length are cut besides.

Figure 3. One of the elastoplast strips is applied as appears by strip 2 in the Figure, whereat an attempt is made to fix the foot in club-foot position, thus in equinovarus or in other words in a position diametrically opposite to the original one.

Figure 4. Strip 3 is applied vice versa or as a mirror picture of strip 2. The foot attains thereby a median position.

Figure 5 shows how the last strip 4 is applied in order additionally to fix the foot in drop-foot position, viz. from the sole over the heel up the calf.

Figure 6 shows the completed elastoplast bandage as seen from behind.

Figure 7. In some more severe cases the aim may be sooner attained in case strip 4 is applied from the dorsum of the foot over the toes, along the sole, over the heel and up the calf. A stronger compression of the foot is thus achieved, like that attained with the flannel bandage used by SPITZY. Applied in this manner the bandage, however, causes pain, wherefore the children are restless and cry during the first day, whereas they otherwise are but surprisingly slightly troubled by their bandages.

This deformity is mostly bilateral, and both the feet can be treated at the same time.

After the elastoplast bandage has been applied, the leg is bandaged with ordinary gauze, which prevents the elastoplast strips from coming loose or get out of place, when the child is kicking. The bandage at the same time protects against soiling by excrements.

The gauze bandages are renewed each time the swaddling cloths are changed, whereas the elastoplast strips, that stand urine well, are renewed once a week by the surgeon in charge.

The child is bathed in the ordinary way, save that the feet covered with elastoplast are kept out of the water. The legs are washed with benzine or alcohol by the surgeon when changing the elastoplast bandages.

The roll under the sole may often be taken away after three weeks, whereas the remaining three elastoplast strips are still applied in the same way as previously, until the deformity is completely corrected. This takes from five to six weeks on an average. Considerably more time is however required in some cases before a satisfactory result has been obtained. This is the case

especially if the treatment is not started until the child is a few months old.

Provided irritation of the skin is observed, nothing prevents one to leave the bandage away for a few days, during which time the child, the feet as well, is bathed every day, whereupon the treatment is resumed again.

The results attained by means of this method are good, in some cases excellent even, provided the treatment was begun at the right moment, at the latest within the first month of life. The shape of the ugly, deformed foot is quite natural after the treatment, and an after-treatment similar to that used for the correction of a slight degree of flat-foot in children may be eventually required.

Summary.

The frequency of pes calcaneovalgus cong. according to the author amounts to about 1 promille in Finland. The treatment should be commenced with as early as possible, preferably from the 10th day of life. Manual redression with elastoplast fixation according to the figures in the text has proved the best method of treatment, which usually takes from five to six weeks if started in time. The results are good.

Zusammenfassung.

Pes planovalgus congenitus kommt nach Verf. in Finnland bei etwa 1 ‰ vor. Die Behandlung ist möglichst früh einzuleiten, am besten vom zehnten Lebenstage an. Die beste Behandlung besteht in manueller Redression und Reposition mit Elastoplastfixation wie auf den hier gebrachten Bildern. Die Behandlungsdauer beträgt in gewöhnlichen Fällen 5—6 Wochen, falls die Behandlung zeitig eingeleitet wird. Die Erfolge sind gut.

Résumé.

Le pied plat valgus congénital se rencontre, d'après l'auteur, chez environ un sujet sur mille en Finlande. Il faut que le traitement commence le plus tôt possible, de préference dès le dixième jour après la naissance. La meilleure thérapeutique est celle par redressement et réduction manuels, avec fixation au moyen

Tables for Calculation of Exact Measurements of Radiographed Objects.

By

CARL WEGELIUS.

As is known, the radiographs' charaeter of centrally projected shadows implies that the photographed objects are more or less magnified and, in addition, distorted as regards shape. In the following only the projective variations in respect of measurement are dealt with. With regard to shadow distortion I refer to the special literature in question (Nos. 8—9 in literary references).

To the size-relations of internal organs in the human organism which are invisible to sight and to their variations a considerable diagnostic significance in many respects is often attributed. In internal medicine the determination of the size of the heart is in this particular of main importance, in gynaecology measurements of pelvis and determination of the size of the skull of the foetus, in surgery localization and measurement of foreign bodies, fractures and so on. In orthopaedy great attention has lately been paid to the intervertebral spaees, especially with regard to diseus prolapsus and diseus degeneratio and spondylolisthesis, to mention some further instances. In all these eases there is a well grounded need of obtaining exact measurements, these being mutually eommensurable, in eontrast to the size-relations of the shadow pietures.

It is known that the magnifying phenomenon is the result of the influenee of two factors, in part the foeal distance, *i. e.* the distance between the X-ray tube and the film-plane, in part the distanee between object and film. These relations are theoretically indieated in most handbooks, elueidated with schematie sketches, see fig. 1. On the other hand, there are seldom tables, which show

the enlargement in figures, enabling the calculation of the size of a photographed object to be carried out. In medical literature I have only found such tables published by EGGERT and BAUER. Instead of a table GFRÖRER uses a nomogram, where corresponding enlargements can be graphically determined. All the tables and nomograms express in percentage the enlargement which the objects undergo with differing relations of projection; they thus start from the real size of the unknown object.

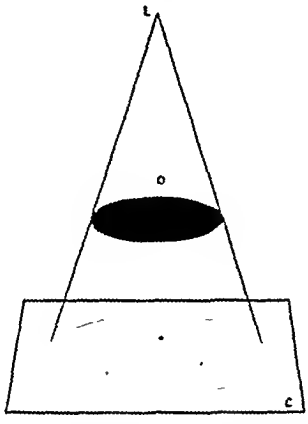

Fig. 1. Principles of shadow formation by central projection; light from a point L is falling on a film-plane C. The shadow of the interposed object O is magnified.

For the practical physician, however, a determination of the size of the object by the aid of such tables, based on indirect calculation, means a very circumstantial process of calculating. Therefore a table for direct examination has been compiled. The enlargement is here given as a coefficient of correction, whereby the distances measured on the radiographs are directly multiplied with regard to both factors, focal- and object-film-distance (we postulate that linearly measured distances run parallel with the film-plane). The advantage of using the above-mentioned table is obvious. The distances and the size-relations of the radiographs are transformed direct into accurate measurements, without unnecessary calculations. A few examples may elucidate the use of the table.

The height of the bones, intervertebral space or an eventual spondylolisthesis radiographed with 50 cm focal distance at a distance of 25 cm from the film-plane is thus actually only 0.50, *i. e.* half of the portrayed size. If the focal distance is increased to 200 cm the correction will be only 0.87 times the size of the picture, which gives us a considerably more real image of its size.

Table 1.

Coefficients for shadow-enlargement.

Focal distance \ Object-film distance	5 cm	10 cm	15 cm	20 cm	25 cm	30 cm
50 cm	0.90	0.80	0.70	0.60	0.50	0.40
60 »	0.92	0.83	0.75	0.67	0.58	0.50
70 »	0.93	0.86	0.79	0.71	0.63	0.57
80 »	0.94	0.88	0.81	0.75	0.69	0.63
90 »	0.94	0.89	0.83	0.78	0.72	0.67
100 »	0.95	0.90	0.85	0.80	0.75	0.70
120 »	0.96	0.92	0.87	0.83	0.79	0.75
150 »	0.97	0.93	0.90	0.87	0.83	0.80
200 »	0.98	0.95	0.92	0.90	0.87	0.85

The transversal diameter of a heart, photographed at a distance of 150 cm with a calculated object-film-distance of 15 cm, has to be multiplied by the corrective coefficient 0.90 in order to obtain the actual measurement. The same heart measured and radiographed at a distance of 50 cm has to be multiplied by the corrective coefficient 0.70. The difference in figures between the enlargement at various distances is seen without further from these instances.

The true conjugate in a pelvis photographed at a calculated object-film-distance of 30 cm has to be corrected by the coefficient 0.50 when photographed at a distance of 50 cm, which implies that the measurements read on one picture are to be reduced by more than half. The same pelvis opening radiographed at a distance of 150 cm has, however, to be reduced by the correction coefficient 0.80, which shows the decisive influence which the distance of the picture has with regard to the reproduction of size.

As will be seen, the table is calculated with a graduation of 5 cm variations of the object — film-distances, as well as of the usual photographic distances — from 50 to 200 cm. Through interpolation between the data in question, also the relation lying in between can naturally be calculated with satisfactory exactitude.

In addition to the above-mentioned direct projective enlargement there is in X-ray photography another factor of a certain importance as regards the exact rendering of the objects, *viz.*, the relation between core shadow and rim-shadow, which cannot always be distinctly limited. As owing to physical conditions, the radiation of X-rays from the focus in the tube cannot be limited to one point, this must always be a surface, a correct central projection cannot be obtained. The cone of light will consist of

ray lines, crossing one another, see fig. 2, with a rim-shadow as a result. This shadow diminishes in conformity with a decreasing object-film-distance and diminished focal surface. With a 2 kW tube and with modern tubes with rotating anode, the focal diameter is about 1 mm, while with the 6 kW tubes in general use nowadays, it is about 3 mm. The size of the rim-shadows is reproduced below in the form of a table arranged in conformity with Table 1.

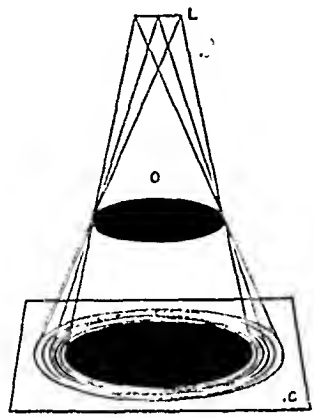

Fig. 2. Principles of the rim-shadow formation on the film-plane C by projection of an interposed object O from the focal-spot L of a X-ray tube.

As appears from these tables, by using tubes with 1 mm focal diameter, the rim-shadow is relatively small and even in the most unfavourable cases does not attain a size of more than 1.5 mm, while it is not more than 0.4 mm when radiographing the skeleton by the very ordinary data of 70 cm focal and 20 cm object—film-distance. If tubes with 3 mm focal diameter are used, the corresponding values, however, are 4.5 and 1.2 mm, which are surprisingly great.

In the usual reading of radiograph measurements, it is generally the case that also the rim-shadow is calculated. When this is added to both the limits of a linearly read measurement, the values in the tables must be calculated twice. This double share of the rim-shadow in the measurement of the X-ray projection is constant for given data and independent of the size of the object. It must consequently in all cases first be subtracted from the measurements of the picture before transformation to exact measurements by the aid of Table 1 can take place. The use in practice of Tables 2 and 3 appears from the instances given below.

Table 2.

Size of rim-shadow in mm by a tubus with 1 mm focal diameter.

Focal distance \ Object-film distance	5 cm	10 cm	15 cm	20 cm	25 cm	30 cm
50 cm	0.11	0.25	0.43	0.67	1.00	1.50
60 »	0.09	0.20	0.33	0.50	0.71	1.00
70 »	0.08	0.17	0.27	0.40	0.56	0.75
80 »	0.07	0.14	0.23	0.33	0.45	0.60
90 »	0.06	0.13	0.20	0.29	0.38	0.50
100 »	0.05	0.11	0.18	0.25	0.33	0.43
120 »	0.04	0.09	0.14	0.20	0.26	0.33
150 »	0.03	0.07	0.11	0.15	0.20	0.25
200 »	0.03	0.05	0.08	0.11	0.14	0.18

Table 3.

Size of rim-shadow in mm by a tubus with 3 mm focal diameter.

Focal distance \ Object-film distance	5 cm	10 cm	15 cm	20 cm	25 cm	30 cm
50 cm	0.33	0.75	1.29	2.00	3.00	4.50
60 »	0.27	0.60	1.00	1.50	2.14	3.00
70 »	0.23	0.50	0.82	1.20	1.67	2.25
80 »	0.20	0.43	0.69	1.00	1.36	1.80
90 »	0.18	0.38	0.60	0.86	1.15	1.50
100 »	0.16	0.33	0.53	0.75	1.00	1.29
120 »	0.13	0.27	0.43	0.60	0.79	1.00
150 »	0.10	0.21	0.33	0.46	0.60	0.75
200 »	0.08	0.10	0.24	0.33	0.43	0.53

An outline of the heart, photographed with an ordinary 6 kW tube (accordingly a focal spot with 3 mm diameter) at 50 cm focal distance and with 20 cm object-film-distance, encloses, according to Table 3, a rim-shadow of 2 mm breadth. This measure is to be added, *e. g.* to its transversal diameter, on both the left- and right-hand sides: the share of the rim-shadow is therefore $2 \times 2 = 4$ mm. This value is first to be taken from the transversal diameter measured on the picture. Only then can this be multiplied by its projective coefficient of correction, which in the case now in question was 0.60. (See Table 1.) As this value is independent of the size of the object, it is the same for any body by these given projective data, even for a small foreign body.

The use in practice of the above-mentioned correcting system naturally presupposes knowledge of the factors necessary for its

use. For the determination of the projective enlargement this thus applies to the focal and the object-film-distances, for the rim-shadow again to the focal distance. Of these data the focal distance is naturally known from the photographing. The object-film-distance again can be approximately estimated with sufficient precision by confrontation with the anatomical relations in question. In many cases there is besides a projection in two planes of the object, at right angles to each other, resulting in correspondingly greater exactitude in the judging of the measurements under examination. Finally, the focal diameter depends on the model of the X-ray tube. These three data, the focal- and object-distances, and focal diameter ought, with a little good will, to be noted down during the film treatment, at the same time as name, date and any other information. In this way one obtains an often unforeseen, but later highly appreciated possibility of commensurating pictures, photographed under varying picture-technical conditions.

Summary.

A table is given for direct correction to actual object size under ordinary photographic conditions of the varyingly magnified photographic measurements in the radiograph, due to different focal- and object-film-distances. Hereby one obtains even under varying conditions of projection exact and mutually commensurable measurements, which is desirable in regard to all statements of size-relations in medical X-ray diagnostics. Further, the relation between core- and rim-shadow is observed and measurements are given for its correction also. Finally, attention is drawn to the desirability of necessary projection data being entered on all films.

Zusammenfassung.

Die verschieden stark vergrösserten Masse im Röntgenbilde beruhen auf wechselnder Fokal- und Objekt-Filmdistanz und ermöglichen die Aufstellung einer Tabelle für direkte Umrechnung in die wirklichen Masse des Objekts bei den gewöhnlichen Verhältnissen bei Röntgenaufnahmen. Hierdurch erhält man auch bei wechselnden Projektionsverhältnissen exakte und untereinander vergleichbare Masse, was in der ärztlichen Röntgendiagnostik bei allen Angaben über Grössenverhältnisse anzustreben

ist. Ferner wurde das Verhältnis zwischen Zentral- und Randschatten beobachtet, und es werden Zahlen auch für die Korrektion desselben gegeben. Schliesslich wird hervorgehoben wie wünschenswert es ist, dass auf allen vorkommenden Filmen die nötigen Projektionsdaten verzeichnet werden.

Résumé.

Dans les conditions habituelles de prise de vues radiographiques, on obtient des images diversement agrandies du fait des variations de la distance focale de l'ampoule au film et de celles de l'objet au film. L'auteur donne une table permettant la réduction immédiate des images obtenues aux dimensions réelles de l'objet. Cette table permet même d'obtenir, dans des conditions variables de projection, des mesures exactes et comparables entre elles, desideratum des plus justifiés si l'on considère la multiplicité des données concernant les dimensions en usage dans le diagnostic radiographique médical. Deux autres tables sont relatives aux rapports existant entre l'ombre nucléaire et l'ombre marginale et fournissent aussi le moyen de les corriger. Enfin l'auteur souligne combien il serait désirable de noter sur chaque film les données nécessaires de projection.

References.

1. Bauer: ABC der Röntgentechnik, 1940. — 2. Eggert: Einführung in die Röntgenphotographie, 1936. — 3. Gerörer: Handbuch der Röntgenaufnahmetechnik, 1937. — 4. Herulf: On sources of error in radiographs of canine teeth of man, Lund, 1940. — 5. O'Sullivan: Radiographs and disproportion. British Medical Journal. 1941. P. 543. — 6. Sante: Manual of roentgenological technique. Ann Arbor. 1939. — 7. Wegelius: Untersuchungen über die Möglichkeiten einer dreidimensionalen röntgenographischen Abgrenzung innerer Organe des menschlichen Körpers. — 8. Wegelius: The difference between radiological and anatomical measurements in determining the size of the foetus' skull. Acta obstetricia et gynecologica scandinavica, 1938. — 9. Wegelius: Concerning the differences between radiological and anatomical measurements. Acta radiologica, 1938.

From The Norwegian Surgical University Clinic A, Oslo.
(Chief: Prof. JOHAN HOLST.)

Closure of the Bronchus in Pneumonectomy and Lobectomy.

By

JOHAN HOLST.

In 1938 we worked out a simple technique for closing the bronchus after pneumonectomy. We have used the technique since then, but our work was interrupted from 1941—45, when the author was abroad on military duties. A preliminary report was made by one of the assistents in the clinic, Mr. John Rö, in 1942.[1]

Since my return the technique has been further developed, and we have used it in all cases of pneumonectomy and lobectomy:

After dissection of the bronchus a *solid clamp* (Fig. 1) is placed close to the bifurcation in pneumonectomies, close to the main bronchus in lobectomies, parallel to the opposite bronchus in pneumonectomies, and to the main bronchus in lobectomies (Fig. 1). Another clamp is applied on the pulmonary side, and the bronchus is cut between the clamps.

A continuous, solid (no. 2 or 3) silk or linen suture is placed on the stump and over the clamp, which remains in situ (Fig. 2). As the clamp now is removed, both ends are tightened and tied to interrupted sutures at each end (Fig. 3). If the suture is properly tightened and tied, the suture-line will be airtight.

The next and most important step is now to get adequate cover for the suture-line.

Originally (1938) the pleura mediastinalis first was fixed to the suture line. In addition the stump was buried in the mediastinum and extrapleuralized. Having seen the work of TUDOR EDWARDS and PRICE THOMAS during the war I feel, that if the stump can be buried in the mediastinum and extrapleuralized, as it is possible

[1] Acta Chirurgica Scandinavica 1942, Vol. LXXXVI, p. 433.

in most cases of pneumonectomies, — covering with special flaps is unnecessary. I have come to the same conclusion as many others in later years, that it is the burying of the stump in the mediastinum, and the extrapleuralization which is the decisive point (Fig. 4). The type of suture does not seem to matter so much for reliable healing.

In one case of pneumonectomy we have buried and extrapleuralized a bronchial stump with not-airtight suture-line. The post-operative recovery was uneventful, without any signs of insufficiency. The same experience has been made in experimental work.

So it seems as if any suture of the bronchial stump will secure sufficient closure, if the suture-line is properly covered. On the other hand I do not think that any suture-technique, how elaborate it may be, will be safe if the suture-line is *not* properly covered with connective tissue and pleura.

The consequence must be to choose the simplest possible suture, which avoids opening of the bronchus and allows cutting the bronchus as close as possible to the trachea in pneumonectomies and to the main bronchus in lobectomies — and then, 'a tout prix' cover the suture-line.

If the lung, as in some of our cases, has been freed totally in the extrapleural layer — and the parietal pleura removed with the lung, it may be difficult even after pneumonectomy, to get sufficient tissue to cover the stump.

In such cases we have used *pedicled flaps* of pleura (Fig. 5) or, as I have seen Brocq do, of pleura and periosteum.

We have also used *free flaps of pleura.*

Since my return to Norway, we have used flaps in all cases of lobectomy.[1] We prefer to use pleural-flaps when we can get a somewhat thickened pleura. If the pleura is very thin, the flaps may be difficult to handle and a flap of rib-periosteum and pleura (Brocq) may be preferable.

Results.

We have used the described technique for closure of the bronchus in 11 cases of pneumonectomy, and in 7 lobectomies.

In the 10 *pneumonectomies* no case of insufficiency of the bronchial suture or of infection in the pleura occurred.

[1] Since my return we do all lobectomies by dissection as I learned in the "Brompton School" by Tudor Edwards, Price Thomas and Holmes-Sellors.

3 of the 10 patients treated with pneumonectomy died in the postoperative period: 2 of heart-failure, 1 of contra-lateral bronchopneumonia. The bronchial stump was examined at the post mortem, and found in order. In the 7 dissection lobectomies, where the bronchial suture was covered with flaps, no death occurred.

In 6 cases, the remaining lobe expanded nicely, filled the chest completely, and the postoperative course was uncomplicated.

In one case a small empyema developed medially over the diaphragm $1^1/_2$ week after the operation. The patient is now $1^1/_2$ month after the operation out of bed, apyrexia. The upper lobe has been expanded since the operation, and is now increasingly diminishing the cavity.

Signs of bronchial fistula to the empyema have not been demonstrated. But we had some difficulty in obtaining an adequate flap for covering the suture-line, and the stump proved not completely airtight by water test. It seems probable that the small empyema was due to some degree of insufficiency and infection from the bronchial stump.

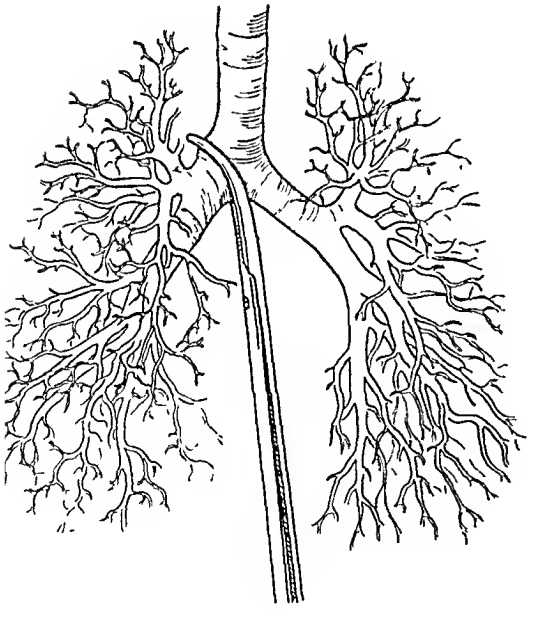

Fig. 1 a.

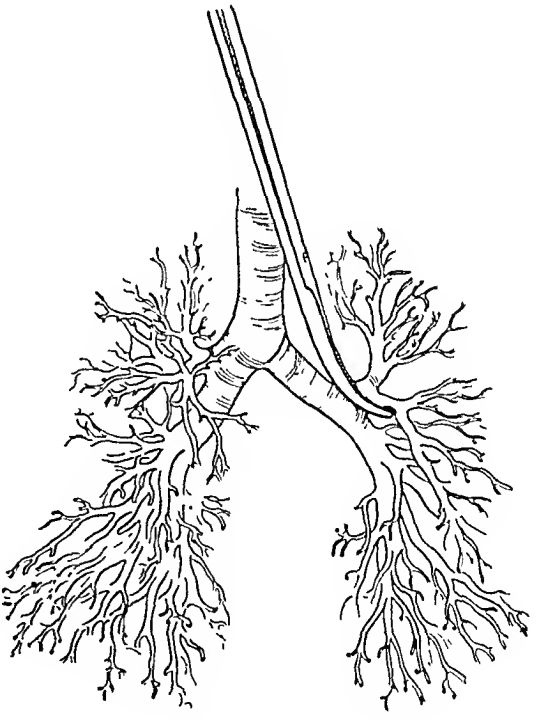

Fig. 1 b.

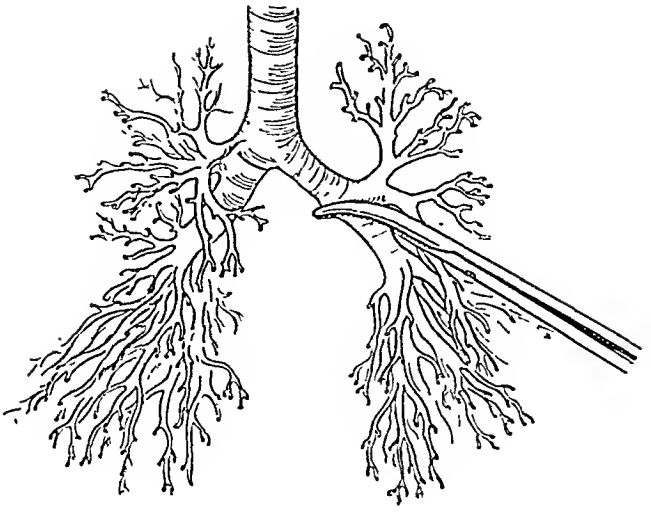

Fig. 1 c.

Fig. 1. Site of the clamp in pneumonectomy (a) and lobectomy (b, c) Clamp applied close to trachea in pneumonectomy and close to main bronchus in lobectomy to avoid cul de sacs, but not too close, causing strictures.

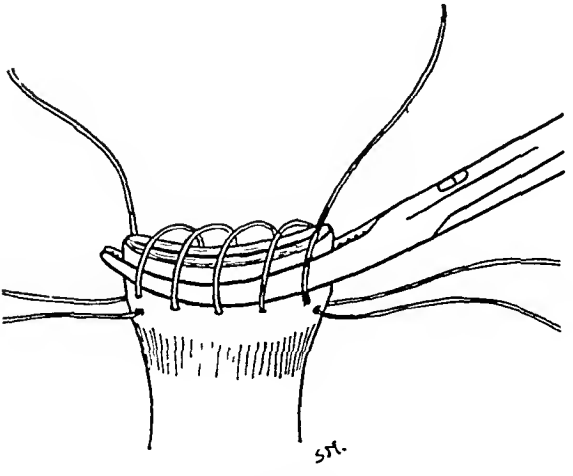

Fig. 2. Continuous silk-suture placed over the clamp.

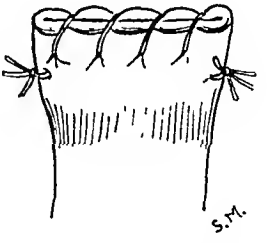

Fig. 3. Suture tightened and tied.

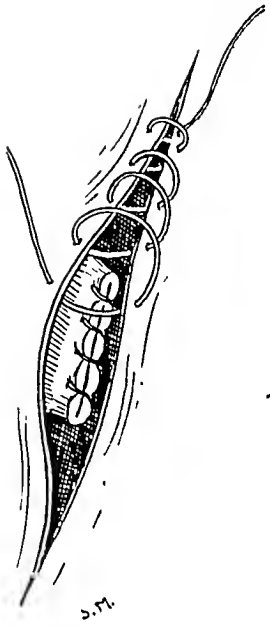

Fig. 4. The bronchial stump, buried in the mediastinum, is extra-pleuralized.

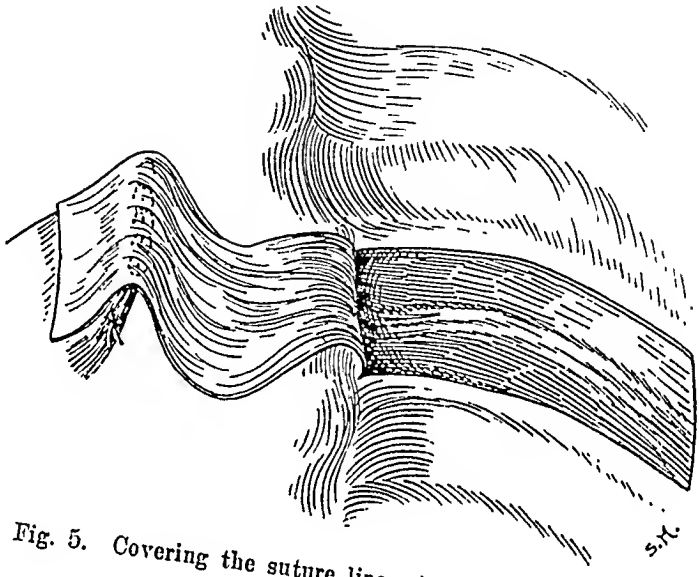

Fig. 5. Covering the suture line with pedicled flap.

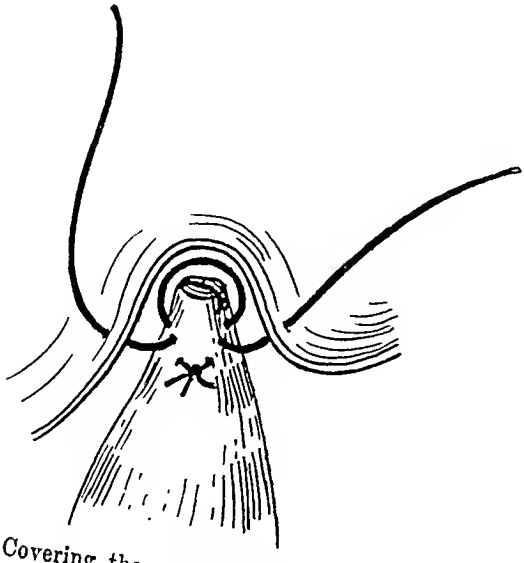

Fig. 6. Covering the suture line with free pleural flap.

Summary.

A curved, solid clamp, strong enough to *crush* the cartilages is used.

After dissection, the clamp is placed close to the carina and parallel to the opposite main bronchus for pneumonectomy. For lobectomy the clamp is placed close and parallel to the bronchus of the remaining lobe. The clamp should crush the cartilages.

Another clamp is applied on the pulmonary side, and the bronchus is cut between the two clamps as close to the central clamp as possible. A continuous silk suture is losely applied over the clamp. The clamp is removed, the continuous suture tightened and tied. The suture should be tied so tightly that the suture line is completely air-tight.

The most important point is adequate covering of the suture-line. This is done:

a) In regular pneumonectomies by burying the stump in the mediastinum and extrapleuralization.

b) In extrapleural pneumonectomies and lobectomies by covering the suture-line with pedicled or free pleural flaps.

10 pneumonectomies and 7 lobectomies have been treated with this technique.

In the *pneumonectomies* no case of insufficiency of the bronchial suture and no case of pleural infection occurred.

After 1 of the *lobectomies* a small empyema developed and had to be drained during the postoperative period. In the other cases the postoperative course was uneventful.

The technique has the following advantages: It is simple. The bronchus is not opened. No soiling occurs. It allows cutting the bronchus more central. It seems to be safe.

Zusammenfassung.

Eine gebogene, feste Klemme, die stark genug ist, die Knorpelringe zu *zertrümmern*, kommt zur Verwendung,

Bei Pneumonektomie wird die Klemme nach Freipräparierung dicht an der Carina, dem Hauptbronchus der Gegenseite parallel angebracht. Bei Lobektomie wird die Klemme dicht an dem Bronchus des zurückzulassenden Lobus und diesem Bronchus

parallel angebracht. Die Klemme muss die Knorpelringe zertrümmern.

Eine andere Klemme wird an der Lungenseite angebracht, und der Bronchus wird zwischen den beiden Klemmen, möglichst dicht an der zentralen Klemme durchtrennt. Eine fortlaufende Seidennaht wird lose über der Klemme angebracht. Die Klemme wird entfernt, die fortlaufende Seidennaht angezogen und verknotet. Die Naht muss so fest geknotet werden, dass die Nahtlinie völlig luftdicht wird.

Der wichtigste Punkt ist zweckmässige Deckung der Nahtlinie. Dies geschieht folgendermassen: a. Bei gewöhnlicher Pneumonektomie durch Versenken des Stumpfes in das Mediastinum und Extrapleuralisation. b. Bei extrapleuraler Pneumektomie und bei Lobektomie durch Decken der Nahtlinie mittels gestielter oder freier Pleuralappen.

Mit dieser Technik wurden 10 Pneumonektomien und 7 Lobektomien behandelt. Bei den *Pneumonektomien* ist kein einziger Fall von Insuffiziens den Bronchialnaht oder von Pleurainfektion vorgekommen. Nach einer der *Lobektomien* kam ein kleines Empyem zur Entwicklung und musste postoperativ drainiert werden. Bei den übrigen Fällen glatter postoperativer Verlauf.

Die Technik hat folgende Vorzüge: Sie ist einfach. Der Bronchus wird nicht eröffnet. Es findet keine Verschmutzung statt. Sie erlaubt ein zentraleres Durchtrennen des Bronchus. Sie scheint ungefährlich zu sein.

Résumé.

On utilise une solide pince courbe assez forte pour écraser les cartilages.

Après dissection, on place la pince près de la crête et parallèlement à la grosse bronche opposée, dans la pneumectomie. Dans la lobectomie, on place la pince dans le voisinage immédiat de la bronche du lobe restant et parallèlement à lui. La pince devrait écraser le cartilage.

On applique une autre pince du côté pulmonaire et la bronche est sectionnée entre les deux pinces aussi près que possible de la pince centrale. On fait une suture lâche à la soie au-dessus de la pince. Puis on enlève celle-ci, on serre la suture continue et on lie. Il faut lier la suture assez fermement pour que la ligne de suture soit complètement hermétique à l'air.

Le point le plus important est d'assurer une couverture parfaite de la suture. On y parvient: a) dans les pneumectomies régulières, par ensevelissement du moignon dans le médiastin et extrapleuralisation, b) dans les pneumectomies extra-pleurales et les lobectomies, en couvrant la ligne de suture au moyen de fragments pédiculés ou libres de plèvre.

Cette technique a servi dans 10 pneumectomies et 7 lobectomies. Dans les pneumectomies on n'a observé aucun cas d'insuffisance de la suture bronchiale ni aucun cas d'infection pleurale.

Dans une des lobectomies, il se développa un petit empyème qu'il fallut drainer durant la période post-operatoire. Dans les autres cas, la période post-opératoire se passa sans incidents.

Cette technique a les avantages suivants: elle est simple. La bronche n'est pas ouverte. Pas de souillure. Section plus centrale de la bronche. Haut degré de sécurité.

From the Surgical Clinic of Karolinska Sjukhuset, Stockholm.
(Chief: Professor J. HELLSTRÖM, M. D.)

Uretero-intestinal Implantation According to Coffey.

By

JOHN HELLSTRÖM and RAGNAR ROMANUS.

Introduction.

While interest in ureteral implantations in the intestine has been great abroad, especially in America, and has given rise to a copious literature, this operation seems to have been relatively little resorted to in the Nordic countries and has only been the subject of brief reports. Recently, however, SÖDERLUND published a material of his own, consisting of 15 cases, and gave a detailed account of the historical development of the methods for ureteral implantation, especially as regards exstrophy of the bladder. Since 45 cases have been operated according to Coffey's first method at the Surgical Clinic of Karolinska Sjukhuset from the opening of the hospital in February 1940 to November 15th 1945 (and since this time a further 3 cases) an account of this material is considered to be motivated, especially as a number of observations have been made upon the same, particularly as regards the dilatation of the ureter and the pelvis, that have hitherto not been generally known. The period during which our cases have been under observation is certainly short; but according to unanimous data in the literature the mortality rate is highest in connection with the operation and during the period immediately following, after which the states become rather stationary. Concerning the historical and similar aspects the reader is referred to SÖDERLUND's article. Only the data in the literature concerning the rate of mortality will be dealt with here, and some of the literature since 1937 that has become available will also be discussed.

Mortality in connection with the operation.

Since for the estimation of the value of an operative method it is of importance to know the risks connected with the same, and since the mortality statistics given in the literature are to some extent misleading, we have chosen to go into the question of the mortality rate in some detail. In comparing the mortality figures for different operative methods it is necessary to classify cases as benign or malignant, the latter group consisting chiefly of cancer vesicae, as the mortality in this group is often 2—4 times as high as among benign cases. The figures cited by SÖDERLUND from HINMAN & WEYRAUCH's exhaustive statistical tables published in the year 1937 should thus be divided up in a corresponding way, especially as implantation according to the methods of Maydl and of Bergenhem with retention of the ureteral orifices has only been resorted to in benign cases (exstrophy of the bladder). With submucous canal according to Coffey's various methods we thus find 143 benign cases with 15.5 % mortality; with the muscularizing principle (Stiles, Tichow and others) 92 cases with 19.5 % mortality and with the Maydl-Bergenhem methods 243 cases with 27.6 %. For corresponding malignant cases we find the following figures: submucosal implantation 110 cases with 48.2 % mortality, muscular canal 44 cases with 45.4 % mortality and no cases operated according to Maydl-Bergenhem.

In the literature there are frequent references to the material of the Mayo Clinic reported by WALTERS in 1931 and consisting of 76 cases of exstrophy of the bladder with only 3 deaths, *i. e.* 3.9 % mortality, all operated according to Coffey I, also called Coffey-Mayo. This figure is, however, misleading. On comparing it with earlier published accounts of the collected material of the Mayo Clinic one arrives at other figures. As early as 1919 we find 4 deaths (= 15.4 % mortality) among 26 cases of exstrophy of the bladder operated with ureteral implantation according to Coffey-Mayo, in 1921 7 deaths (= 19.4 % mortality) among 36 operated cases. In 1926 MAYO & HENDRICKS report 66 operated cases of exstrophy with 18 deaths, but here the diagnosis of exstrophy comprehends a number of different ailments, and many other operations than ureteral implantation had been carried out. Probably 8 deaths (= 13.6 % mortality) remain among 59 implantations. Also the account of the clinic's material in 1931

suffers from many defects (thus *e. g.* the tables in the German and the American versions respectively differ considerably, and the totals are in many places wrongly added up): WALTERS here reports 76 cases of ureteral implantation without catheters according to Coffey I-Mayo with only 3 deaths (= 3.9 % mortality). As in 1921 7 deaths were reported and in 1926 probably 8, the mortality should be calculated from at least these figures; but in the article an account is given of a further number of implantations besides the 76, which must thus also be taken into consideration; the total is then 82 implantations with 7 or 8 deaths (8.5 or 9.6 % mortality). The mortality can thus be calculated at practically 10 % in the clinic's material up to 1931. Of recent years a reduction of the mortality has evidently taken place, but no exact account of the material has been published. A part of the material of the Mayo Clinic comprises the 14 operated cases of exstrophy without any deaths published by CABOT in 1931. But it is not stated whether these cases are also included in the comprehensive account published by WALTERS in 1931, nor how the choice of the cases operated by CABOT was made. In 1931 WALTERS states his personal mortality in 20 cases as 5 %, in 1934 as 4 % in 25 cases.

HINMAN & WEYRAUCH's figures cited above refer to the collected statistics up to the year 1937. After this there is a clear tendency to a reduction of the mortality. But the statistics are as a rule not comprehensive enough to permit of any definite conclusions. Throughout, however, the C I method has a lower mortality than C II (with ureteral catheters).

In 1939 HINMAN & SMITH made a collection from the literature of exclusively malignant cases comprising 63 cases operated in one stage with 38 deaths (= 60 % mortality) and 74 cases operated in two or more stages with 15 deaths (= 20 %), making a total of 137 cases with 53 deaths (= 38 %). If, on the other hand, one considers only the publications after 1926 the figures arrived at are 75 cases with 19 deaths (= 25 % mortality). These figures, however, refer to ureteral implantations and cystectomy taken together, in which connection those patients who died after only implantation have not been included among the cases operated upon in two stages. If these are included, one arrives at a total mortality of about 30 % in radical operation of cancer vesicae. HINMAN's own material comprises 25 ureteral implantations + cystectomy with 10 deaths, and altogether in connection with

cancer vesicae 49 ureteral implantations with 28 deaths (= 57 %). In 1943 PRIESTLY & STROM published the material of the Mayo Clinic from 1910 to 1942 referring to 51 simultaneous bilateral implantations with 8 deaths (= 15.7 % mortality) (the majority according to Coffey I-Cabot), 13 bilateral implantations + cystectomy in the same stage with 8 deaths (= 61.5 %), *i. e.* a total of 64 cases with 16 deaths (= 25 % mortality). In addition there are 20 cases in which cutaneous implantations, nephrostomy and only unilateral implantation in the intestine have been performed, with 9 deaths. If all these are included we get 84 cases with 25 deaths (= 30 % mortality). But during the last three years the mortality at the clinic has sunk considerably, and 34 simultaneous bilateral implantations have been carried out with only 1 death (= 3 %). Bilateral implantation + cystectomy in the same stage has been carried out in 2 cases with 1 death, which makes a total of 36 cases with 2 deaths (= 5.6 % mortality).

Summarizing, it may be said that the operative mortality in connection with ureteral implantations for benign cases lies between 10 and 20 %, and for malignant cases between 25 and 60 %, but that a considerable reduction of the mortality seems of recent years to have taken place for both groups.

Authors' own material.

The material derives from the Surgical Clinic of Karolinska Sjukhuset during the period 1. 2. 1940 to 15. 11. 1945, and comprises 45 patients, 23 men and 22 women ranging from 4 to 78 years of age. Altogether 89 ureters have been implanted. Of these, 4 have been reimplanted; on 2 occasions double ureters have been implanted simultaneuosly; in 4 cases it was a matter of single kidney and in 3 cases only unilateral implantation has been carried out; the operation has here not been completed owing to the progress of the malignant process. (Since the material has been collected a further 3 patients with cancer vesicae have been operated upon with ureteral implantation where cystectomy had been carried out quite recently in 2 cases, while in one case the bladder was not removable.)

Indications.

On the whole the cases may be classified in two groups, namely, 1) congenital or acquired states of the bladder, with complete incontinence or very frequent and painful urinations, 2) primary or secondary tumours of the bladder that can only be radically treated by cystectomy or tumours where ureteral implantation as a palliative is indicated.

To the first group belong above all congenital malformations in the form of exstrophia vesicae and complete *epispadias* where continence cannot be brought about with plastic operations. With Young's operation for epispadia with incontinence perfectly satisfactory results have been obtained at the clinic during the same period (see Nord. Med. 1945: 25: 79—80). In another, similar case, that of a 7-year-old boy, a plastic operation was first performed on the vesical neck and the posterior urethra according to Young, and the patient was able, after the operation, to micturate with a good stream and even to control the same. Owing to his age, however, it was difficult to teach him to retain his urine, and he continued to be incontinent, and ureteral implantation was therefore carried out. Bearing in mind the favourable experience in the first-mentioned case, it is possible that good results might have been attained also here if the operation had been supplemented with a remodelling of the urethra and the penis. *Exstrophia vesicae* is the condition in which ureteral implantation was first and has since been most resorted to. In the material are here included 6 cases, 3 male (21, 29 and 35 years of age) and 3 female (4, 6 and 25 years of age). The majority of authors, with C. H. Mayo, consider that these patients should not be operated upon until they have attained the age of 3—4 years, when they have learned to control the movements of their bowels, but of recent years Hepler and Hinman, amongst others, have performed the operation in the child's first year, and Nesbit, Lower and Higgins have even operated upon children aged 3 months. They consider that the function of the rectal sphincter may well be judged on rectal palpation, and the coming continence thus be rightly assessed before the operation. According to them, an early operation is motivated by, amongst other things, the facts that the bacterial flora in the intestine of babies is less virulent than later in life, and that pyelites and obstruction of the lower end of the ureter with hydronephrosis

may appear before the age of 4 years, which might jeopardize the results of an ureteral implantation carried out later. Further, it may be of importance both for the physical and for the psychic development of the child that the operation be carried out as early as possible.

Among the acquired conditions in which an ureteral implantation may be indicated, *vesico-vaginal fistulas* play an important rôle. 8 cases are included in the material, 3 fistulas after trauma connected with delivery, 2 after operation (one an extirpation of the uterus owing to cancer and the other a lesion of a hypospadiac urethra in connection with dilatation of the uterus), 2 conditions resulting from the treatment of cancer colli uteri with radium, and 1 case of tuberculous contracted bladder with vesico-vaginal fistula and only one remaining kidney. In 2 cases an operative closing of the fistula was several times attempted but without success. In the other cases such an attempt was from the outset considered to be without any prospect of success, and ureteral implantation was therefore carried out primarily. 2 *contracted bladders* causing acute discomfort (severe dysuria and strangury with very little bladder capacity) have been operated upon, the one unspecific, the other tuberculous with only one kidney. The last case in the benign group is a woman, who had not had any trouble until after a normal partus at the age of 27, when she was afflicted with *incontinence with retention*. Soon, however, bilateral hydronephrosis with impaired renal function was observed, and the condition became worse. Bilateral reflux from the bladder into the ureters with pyelites appeared, and the bladder gradually contracted. Ureteral implantation was here carried out as a last desperate resort after the failure of other methods of treatment.

The second group, comprising the malignant cases, is made up chiefly of tumours of the bladder, and contains 26 cases. In one case it was a matter of very extensive but benign *papillomata* which despite fulguration and X-ray treatment recidivated and became still more extensive; in 2 cases it was a matter of papillomata that were clinically, and in the one case also histologically, suspected of cancer, in which, owing to the extent and localization, cystectomy was considered to be indicated. A *cancer prostatae* that was chiefly growing into the bladder and was clinically diagnosed as a primary tumour of the bladder is included in the material, as well as a *cancer vulvae* that had encroached upon

the urethra and the vagina and given rise to incontinence. Here, radical fulguration of the tumour was rendered possible by ureteral implantation. In 21 cases it has been a matter of actual *cancer vesicae* of such extent and with such a localization (near the orifices of the ureters or the urethra) that cystectomy has been considered to be indicated, or of cases in which, certainly, the cancer has not been removable but has led to obstruction of the ureters or to such severe subjective discomfort in the bladder that a palliative ureteral implantation has been considered indicated.

As has been remarked by, amongst others, ÅKESSON, on the basis of the material from Maria Sjukhus, the prognosis, especially in cases of infiltrating cancer vesicae, is very poor after partial excision with or without X-ray treatment. In the Surgical Clinic of Karolinska Sjukhuset we have therefore to an increasing extent resorted to ureteral implantation and cystectomy in such cases. In the greater part of this material, however, this method has been resorted to at a late stage of the treatment, after other methods of treatment have proved ineffective. The tumours have therefore often been much too extensive and have given rise to metastases, so that it has not been possible to perform cystectomy. In 3 cases, in fact, only unilateral ureteral implantation has been carried out owing to the fact that the cancer afterwards proved to be not removable.

It is only recently that cystectomy has been resorted to to any considerable extent and at an early stage of the disease, which in view of the final result must be considered to be definitely indicated.

In cancer vesicae the ureters are frequently considerably dilated, and a pronounced periureteritis not seldom occurs as a result of infection or X-ray treatment. In no fewer than 6 cases one kidney had completely stopped functioning before the implantation owing to the localization of the cancer. According to GRAVES & THOMSON, it is a bad prognostic sign if one of the ureters is blocked, for this often means that the cancer is spreading outside the bladder, which agrees with our experience from this material. In general it is stressed that ureteral implantation in cancer cases is in the main not a technical problem but a matter of choice — »selecting a risk» (MC COMB). A number of authors (*e. g.* PRIESTLY & STROM, the Mayo Clinic) consider that ureteral implantation as a palliative should not be performed

in cases of cancer vesicae. The condition of these patients is, however, often unbearable owing to the extremely severe bladder trouble, that is generally not relieved by X-ray treatment or cystostomy. As the mortality in connection with ureteral implantation is also so relatively low and the favourable effect on the subjective trouble so good, we consider it completely justified to undertake ureteral implantation even in cases of not removable cancer vesicae where the patient may be expected to live for a certain period.

Operative technique.

All operative cases *are prepared* 3—5 days before the operation with thorough purging with castor oil and enemata, the patients being kept on non-residue and later liquid diet. The day before the operation no laxative is given, but only two enemata and 10 drops of tinctura opii 3 times. No enema on the day of the operation but 20 drops of tinctura opii in the morning. On some occasions the intestine has during the operation been fairly full, but this does not seem to have had any prejudicial effect. In order to try to disinfect the urinary passages and the intestine, sulphatiazol has been given a couple of days before the operation and in the period immediately following, recently sulphaguanidine and phthalylsulphanilamidotiazol.

The operation is performed in spinal anaesthesia, in some cases combined with narcotal intravenously. The right ureter is as a rule implanted first, unless there is an obstruction of the left ureter with dilatation and possibly impaired kidney function rendering it desirable that this ureter be implanted as soon as possible. Generally a diagonal incision in fossa iliaca has been employed, and this should be sufficiently long (about 1 dm in adults) to enable an unhindered survey. After the peritoneum has been opened the patient is placed in the Trendelenburg position and the intestine is packed away with gauze, so that only flexura sigmoidea and colon pelvinum are visible. The peritoneum above the last part of the ureter is divided, the ureter is dissected out and lifted up with a thread of catgut that has been drawn around it and is traced as far down towards the bladder as one can get. The adventitia, especially if it contains vessels, should not be removed, but should be left undamaged on the ureter;

adipose tissue, on the other hand, is cut away. After packing with rivanol gauze the ureter is clamped and divided as peripherally as possible, after which the distal end is tied with catgut and the mucosa of the ureteral stump destroyed by fulguration. The clamped proximal ureteral end is turned upwards, and the peritoneal slit is stitched up. After this comes an important step, namely, the choice of the most suitable part of the intestine for the implantation. This should be performed in such a way that the implanted part of the ureter forms, on its diagonal passage through the intestinal wall, a direct continuation of the ureter in its longitudinal direction, so that no kinking or tension arises. In this connection the following points should be observed:

1) In choosing the place for the implantation, the intestine should be placed in the position it may be expected to assume when the patient is standing erect, and it must have sufficient free play to ensure that no tension arises in the implanted ureter. Nor must the intestine be twisted too hard in its longitudinal direction, so that there is a risk of tension and kinking.

2) It is not so important if in its passage through the intestinal wall the ureter runs in the longitudinal direction of the intestine or diagonally; what is important is that it should run in the longitudinal direction of the u r e t e r.

3) The length of the intraperitoneal part of the ureter may differ on account of the importance of avoiding kinks and tension. It is therefore best to have from the outset a long ureteral stump, which may then be shortened later if required.

When the most suitable place for the implantation has been chosen one packs carefully with gauze. The ureter is cut off diagonally just proximally to the clamp, and a fine thread of catgut is sewn through the tip, knotted, and the short end cut off. The other end, together with the needle, is placed on one side for the time. If the ureter is in a high degree dilated and the urine infected a coarse ureteral catheter or a fine Nelaton's catheter is passed up into the ureter, in some cases right up as far as the pelvis of the kidney. The urine is sucked out, and one rinses with potassium permanganate-boric acid solution, part of which is allowed to remain behind in the urinary passages. In these cases the ureter is temporarily clamped until the implantation has been carried out. One then makes on the previously selected place on the intestine, which has been marked with a tissue forceps or a traction loop, an incision 2.5—3 cm in length

through the peritoneal and muscular coats, after which this layer, at first sharply with scissors and scalpel and then bluntly with the help of small tampons, is loosened from the submucosa a good $^1/_2$ cm to each side, in which connection careful hemostasis is necessary. The ureteral bed thus prepared, forming a submucosal trough, must be made broader if the ureter is very much dilated. In the distal end of the often forward bulging intestinal mucosa one burns a small hole with a fulguration electrode, enlarging it bluntly with a hemostat. A director is then introduced through the hole into the intestine, and with the help of the director the needle with the knotted thread of catgut in the tip of the ureter is also passed through. A suitable needle is a rather big, curved, round intestinal needle (about $5^1/_2$ cm). The needle with the thread is then pushed out through the entire intestinal wall about 2 cm distally to the hole. By pulling the thread, coaxing with the director and in some cases drawing up the intestine distally to the implantation site the ureter generally glides without difficulty into the lumen of the intestine. By holding the thread taut the ureter is retained in this position, while with the needle one makes a small stitch in the serosa beside the place of exit of the thread and knots this anchoring suture. After this one sews together the loosened serosa and muscularis over the ureter with 3 or 4 interrupted sutures, of which at least one takes a bite of the adventitia of the ureter without penetrating the lumen. The implantation site is smeared with sulphatiazol powder, instruments and gloves are changed, and the packing is removed. The place of exit of the anchoring thread and the serosa-muscularis sutures are then invaginated with a second row of serosa sutures or are sewn over with adjacent appendices epiploici, in which connection one must see that no compression of the ureter takes place. As a rule, the ureter will run freely for a centimeter or so through the abdominal cavity from the peritoneal slit to the implantation site. If at the place of exit of the ureter the peritoneum seems taut, it should be eased by cutting. As a rule, the intestine is not nowadays anchored to peritoneum parietale, and no attempt is made to place the implantation site extraperitoneally. Closure of the abdomen without drainage, sulphatiazol powder being rubbed into the abdominal wall towards the peritoneal suture.

As has already been mentioned, one operates as a rule in two stages, taking the left ureter in the second stage. The operation on this side is generally more troublesome than on the right side,

owing to the anatomic conditions and a certain fixation of flexura sigmoidea to the right after the first implantation. It is above all a long and fatty mesosigmoid that renders implantation on the left side difficult, and gives rise to an increased tendency to kinking as compared with the right. Several authors have referred to the greater difficulties on the left side, and some have suggested making the implantation high up on the proximal part of colon sigmoideum or the distal part of colon descendens, or drawing the left ureter through a hole in the mesocolon over the medial line and implanting it on the right side distally in sigmoideum. In this material the ureter has in a couple of cases been drawn through meso-sigmoideum and then implanted in sigmoideum near the medial line on the left side, but the function has in these cases not been satisfactory later on. As a rule, however, it is an easy matter to dissect out the ureter to the left of meso-sigmoideum and make the implantation on the left side but rather higher up than on the right. In connection with the operation (preferably beforehand) one inserts a coarse rectal tube through the anus, and this is allowed to remain for 6 to 7 days with constant drainage. The tube is rinsed with a slight amount of lukewarm saline solution a couple of times a day to prevent blocking. The patient may drink immediately after the operation; where necessary one may also give extra fluid parenterally. The patient is kept on liquid diet until the tube has been removed. No cathartic is administered, but after the second implantation a moderate enema is ofted resorted to if the bowels have not moved spontaneously.

On an average 17 days have elapsed between the first and the second implantation (in about 80 % of the cases, where there have been no complications). Only in 2 cases have the implantations been made simultaneously.

One of these (page X, record 1512/42) was but slightly affected after the operation, and the secretion of urine commenced at once. The other one was a case of cancer vesicae (page VIII, record 1077/41), where both ureters were implanted and the bladder removed in one stage. This patient was considerably affected after the operation. The secretion of urine started after 48 hours, the non-protein nitrogen rose on the fifth day to 157, but returned to normal values rather rapidly.

In cases of exstrophia vesicae cystectomy has been performed 3 times, including once in connection with the second ureteral implantation. In cancer vesicae cystectomy was performed once

in the same stage as the bilateral ureteral implantation. In the remaining 11 cases of radically operated cancer vesicae cystectomy has been carried out from 7 to 40 days, on an average 22 days, after the last ureteral implantation. It is possible that in cases of cancer vesicae one might be able to implant both ureters simultaneously or to perform cystectomy in connection with the second implantation in a higher percentage of cases than in our material, which may be of importance in cases of rapidly growing cancers. The delay that through the division of the operations has arisen in our cases, 17 + 22 = 39 days, has probably not played any rôle, however, in the majority of cases. Especially as regards non-malignant conditions it is without doubt safest and best to perform the implantation in two stages.

On two occasions double ureters have been implanted simultaneously, once beside each other, while the second time the one ureter was placed above and somewhat to the side of the other. Only once have pronounced adhesions from the first implantation been troublesome in the second stage. As a rule there are no or only slight adhesions, despite the fact that it was only on the first occasions that the implantation site was placed extra-peritoneally.

The ureters have often been dilated; more than 14 times they were at least as wide as the little finger, and once as thick as the small bowel. Difficulties may arise in connection with the implantation if the ureter is very dilated or stiff and taut as a result of ureteritis. In one such case with a strongly dilated ureter (page XII record 320/43) a modification of Coffey's second method was employed, a narrow soft rubber catheter being introduced into the ureter, which was then tied firmly around the catheter. The catheter was now introduced into the intestine and drawn out through the rectum. When this catheter loosened on the tenth day, however, the patient showed signs of pyelitis, which is not uncommon when the catheter has loosened in connection with the Coffey II-method.

A number of authors (*e. g.* the Mayo Clinic) are of the opinion that strongly dilated ureters should not be implanted, but that it is better in such cases to perform a nephrectomy or nephrostomy in order to make the dilatation recede.

In a case published by HELLSTRÖM in 1936 (not included in this material) the right ureter was normal while the left one was in a high degree dilated and thickened. After a successful implantation on the

right side a nephrectomy on the left side was considered, but it was decided to implant also the left ureter and eventually to perform a nephrectomy later on. After the operation, however, urography showed that the ureter had contracted to almost normal width, and when later an ureteral stone appeared in the right side it was fortunate that there was a properly functioning kidney on the other side. (This patient is still alive and well, 13 years after the operation.)

Since this experience we have not on account of ureteral dilatation desisted from any implantation that has been planned before the laparotomy. Thus in one case an ureter as wide as the small bowel was implanted, which on inspection in connection with the implantation of the other ureter 12 days later proved to be well contracted with good peristalsis. Only in one case has nephrectomy been performed instead of ureteral implantation on account of a far-advanced pyelonephritis. Microscopic examination of ureteral fragments has in 29 out of 50 cases shown inflammatory changes and no such changes in 21 cases.

In the majority of cases the reaction to the operation has been moderate. In a fourth part of the cases the urine discharge into the rectum after the first implantation has begun already on the day of the operation, in half of the cases the following day and only in a fourth part of the cases later. Increase in the non-protein nitrogen is rather unusual after the first implantation; in 85 % of the cases in which this determination has been made (40 out of 45) it has not exceeded 45 mg %; only in a tenth of the cases has it been over 60 mg %. After the second implantation the general reaction is as a rule less pronounced, but an increase in non-protein nitrogen is more frequent; in scarcely half the cases, however, not over 45 mg % and in only a fourth part over 60 mg %.

Results.

The results of the ureteral implantations have been collected in a table (page 462), in which both the immediate and the later results are given for the different groups.

The case-histories of all the patients are also given in tabular form (page I—XIX). The case-histories of the deceased are here given first, according to the following schema:

I. Death in hospital A. from operative complications: 1) after ureteral implantation (1 case), 2) after cystectomy (1 case); B. from the original disease, cancer (2 cases). II. Death after dis-

charge A. from renal insufficiency or infection: 1) within 6 months after the operation (3 cases), 2) later (2 cases); B. from the original disease, cancer (8 cases).

Then follow those operated upon with merely palliative intention, still surviving (3 cases) and finally other patients still in life, classified according to the indications for operation: congenital malformations (5 cases), incontinence + retention after partus (1), benign vesicovaginal fistulas (4), non-tuberculous contracted bladder (1), papilloma vesicae (3), cancer vesicae (8), cancer vulvae (1).

Thus, as emerges from the table and the case-histories, 4 patients have died in hospital, of which number, however, only one (page II, record 407/45) can be said to have died as a direct consequence of the ureteral implantation — from pyelonephritis with uremia; but the urinary passages were already infected on the same side before the operation.

The second death (page II, record 1385/43) was a consequence of the cystectomy (for cancer), when a rectal lesion arose, while the implantations proceeded without complications.

In the two other cases certain complications arose after the implantations, but the main cause of death was the original disease, *i. e.* cancer.

In one of these (page II, record 167/42) the one ureter retracted and the uretero-intestinal anastomosis closed (see fig. 1); a moderate pyelonephritis appeared but no peritonitis. In the other case (page II, record 307/41) the cause of death was, besides cachexia, probably also renal insufficiency through bilateral pyelitis, which was, however, most pronounced on the non-implanted side.

A further 5 patients died after discharge from the consequences of the operation, *i. e.* renal failure or infection, including 3 cases within six months of the operation.

The two first (page IV, record 1370/44 and 165/43) proceeded as progressive renal insufficiency without signs of infection, and died soon after discharge. The third patient (page IV, record 367/45) died of pyelitis without definitely established obstruction in the ureter. One of the two patients who died later (page IV, record 2283/42) enjoyed a remarkably good general condition for over 2 years, despite non-protein nitrogen about 100. In the other case (page IV, record 364/41), on account of the clinical absence of excretion to the rectum, *reimplantation* of the left ureter was undertaken without improvement. Probably the reimplantation was not necessary, as according to urography the kidney was functioning satisfactorily, and the function

Figs. 1—4.

HELLSTRÖM and ROMANUS: Uretero-Intestinal Implantation.

Figs 5–8.

Figs. 9—12.

HELLSTRÖM and ROMANUS: Uretero-Intestinal Implantation.

was presumably rendered worse by the reimplantation. The patient died of impaction of ureteral calculus on the left side with uremia $3^1/_2$ years after the operation.

The course and the post-mortem findings in the other 8 cases may be seen from the tabulated case-histories (page VI—VIII). They all died of the original disease, cancer. In 5 of them the renal function was unchanged, in 1 case even improved after the implantation, in 3 cases it was slightly impaired and in 2 of these stone and gravel respectively appeared after the operation, but in all these cases there were changes before the implantation. It is worthy of note that in no case did peritonitis occur, though this has been rather common in many earlier statistics, especially where Coffey's second method has been resorted to. According to our experience, however, one scarcely needs to reckon with any risk of peritonitis if the right technique is used.

Besides in the above-mentioned case *reimplantation* of the ureter has been resorted to in a further 3 cases. The operation is technically relatively easy to perform, but has been of doubtful value in our cases.

One case (page XIV, record 1060/41) contracted pyelitis 5 days after the operation, and the excretion of urine ceased at the same time. Here, without doubt, nephrostomy, which has been recommended by HINMAN and others, would have been of greater value for the retention of the renal function; for this early obstruction often proves to be conditioned by edema and swelling in the ureteral stump and the anastomosis, and the passage may afterwards become free and the nephrostomy close of itself. Reimplantation was performed in this case 7 months after the first, and during the operation an adhesion was found that may possibly have caused a certain obstruction. The ureter was as wide as the little finger above the intestine, but no thicker than a slate-pencil in the submucosal canal, and microscopic examination showed chronic inflammation here. After the reimplantation there was still no excretion, but from a sigmoidoscope it was possible to get an ureteral catheter into the ureter, which resulted in a copious flow of urine and at the same time relieved the pain. After two such "dilatations" of the orifice urography showed a certain excretion again.

In the next case (page X, record 938/41) the reimplantation was performed on the wrong side owing to mistaken information after the X-ray examination, and probably led to a certain worsening. The ureter from the other kidney, which really did not function, was exposed two years after the implantation for eventual reimplantation; but after ureterotomy urine proved to be excreted at a normal rate from the kidney, so that it was considered sufficient to dilate the rather narrow orifice to the intestine with a bougie. After this the total renal function was somewhat improved.

In the last case (page XII, record 320/43) it was a strongly dilated ureter from a very badly functioning kidney that was implanted. A certain flow of urine to the rectum took place during the first days, but ceased altogether 4—5 days after the operation, and at the same time there were signs of pyelitis. Also in this case an immediate nephrostomy would have been better than the reimplantation that was undertaken 34 days after the implantation without definite improvement.

A further 6 "silent kidneys" (*i. e.* kidneys shown by urography to be not functioning) were operated upon with ureteral implantation, of which number one had shown slight excretion on urography afterwards but then ceased to function again. A couple of the others showed clinically a certain excretion but of only slight duration, and in at least some of these cases it might possibly have been better to perform nephrostomy before the implantation.

The greatest danger in connection with ureteral implantation in the intestine is undoubtedly constituted by a dilatation of ureters and the pelves, most frequently combined with infection and sometimes the formation of calculus. On one occasion it may be the dilatation, and on another the infection that is most prominent, but the result of both is renal insufficiency. The causes of the primary dilatation are many, such as operative edema, strituring and kinking, adhesions, inflammation of the ureteral wall, anemic necrosis of the latter and neurogenic factors in connection with the division and implantation of the ureter. Of these, probably the inflammatory edema and the infiltrate are the most important causes both of the dilatation and the ascending infection. As in other infections of the urinary passages, every obstructing factor is of importance both as regards the origin of an infection and inasmuch as it prevents the clearing up of an infection once it has arisen. If there is no obstacle to an outflow an infection may very well clear up, and also an initial dilatation may well recede. This is beautifully illustrated by one case (page XII, record 1882/43).

A moderate dilatation, before the operation, of both ureter and pelvis on the right side increased slightly after the implantation, and in the course of pregnancy the patient had several attacks of pyelitis on the same side. Plain X-ray 5 months after the implantation during the third month of pregnancy showed (fig. 2) air in the dilated right ureter and the pelvis. It is evident that the anastomosis between ureter and intestine was insufficient, so that air from the intestine had passed up into the ureter. On account of the patient's pregnancy no more careful examination with Barium enema was carried out. As DOBRZANIECKI and TILK have pointed out, the ana-

stomosis may sometimes be completely insufficient, so that one can get roentgen contrast from the colon up into the ureter. After normal partus she has had attacks of pyelitis now and then, but the renal function is normal, and urography shows (figs. 3—4), that the dilatation on the right side had almost entirely disappeared.

This case shows that the formation of a valvule in connection with the anastomosis is not necessary to prevent dilatation of the urinary passages, and supports the view that has of recent years been advanced by, amongst others, VERMOOTEN, HINMAN and REIMERS, to the effect that the advantage of Coffey's methods of implantation lies less in the formation of a valve than in the reliable anchoring of the ureter.

If as *post-operative symptoms of infection from the urinary passages* one includes all the cases in which pain, renal tenderness or fever have arisen after the operation, then such symptoms have within a month of the operation arisen after 13 implantations in those cases in which previous pre-operative symptoms of infection, positive bacterial findings in the ureteral urine on operation or inflammation in the ureter demonstrated by microscopic examination have been noted. Without such signs of previous infection 8 implantations have shown symptoms of infection. It should, however, be borne in mind that consistent examination of the urine and microscopic examination of the ureter in connection with the operation have not been carried out in all cases. Later attacks of infection, usually after discharge or at least more than two months after the implantation, have with previous symptoms of infection occurred after 10 implantations, of which 7, however, were very moderate, and without previous symptoms 10 times; but as regards the majority of these, symptoms of infection probably existed already before the operation. 30 implanted ureters have been completely free of infection after the operation, including 6 patients who during a period of observation of $^1/_2$—4 years have been entirely free of infection. Of these, one was an exstrophy of the bladder, one a vesico-vaginal fistula, one a papilloma of the bladder and 3 were cancers of the bladder. At least 4 of these patients had clear symptoms of infection before the operation.

In the majority of cases the renal function has been controlled with *excretory urography* before and several times after the implantations. Quite normal conditions before the implantation have been found in 49 ureters, pathological conditions in 35 ure-

ters. Of these 49 ureters, 21 showed slight dilatation after the operation, 18 moderate dilatation and 6 pronounced, while 3 excreted very poorly or not at all. During the subsequent course a clear improvement with complete or very marked recession of the dilatation was noted in almost half of these cases, as a rule appearing rather rapidly, though in one case not until after the lapse of 1 to 2 years, and continuing for $4^1/_2$ years. As *e. g.* in figs. 6—8. Approximately unchanged status occurs in 7 cases, the remainder are still uncertain. An impairment of the renal function without any considerable dilatation has been noted in 8 of the implantations. Of the 35 ureters that were pathological before the implantation an initial increase of the dilatation has occurred in 12 cases, but moderate in all of them. A clear improvement during the subsequent course on comparison with the preoperative urogram appeared in 8 cases, *i. e.* almost a quarter, including one case that had calculus simultaneously on both sides (figs. 9—10). As has already been mentioned, one case showed, in connection with pregnancy, air in the moderately dilated ureter, which afterwards disappeared, as did also the dilatation. In 6 cases there has been a worsening, but in many of these this has only been a continuation of the progressive worsening before the implantation. Examples of the course with considerable regression of preoperative dilatation may be seen on the roentgen pictures (figs. 11—12).

Of the 49 normal ureters one showed definite, one further very probable spontaneous passage of calculus after the implantation, and in still another case impaction of calculus with death from uremia occurred $3^1/_2$ years after the operation (see above). Of the 35 ureters with pathological urograms before the implantation, 4 showed calculus later, and one showed gravel on post-mortem. Post-operative formation of calculus has thus been observed in altogether 8 of the cases, and in one of these, through impaction of calculus in the ureter to the best functioning kidney, has constituted an essential cause of the patient's decease; but in other cases the formation of calculus seems, certainly, to have constituted a relative innocuous complication. (One patient (page X, record 2288/40) is operated on Jan. 1946 with nephrolithotomy.) In Grey Turner's material of ureteral implantations two exstrophia patients, for example, were operated upon for calculus, and both of them are still alive and in good health, one 25 years after the implantation, while the other has survived for 29 years and

has had three children. The formation of calculus should, of course, be counteracted as far as possible by combatting the urea-splitting organisms that are probably the most important cause of calculus, and by counteracting alkalization of the urine with acidifying agents.

As appears from the table (page 462) and the tabulated case-histories, 28 of the 45 patients operated upon are still living. Of those *surviving*, however, 3 suffer from cancer with poor prognosis who have not been radically operated upon, 2 have been operated on recently, while 23 have been under observation for at least six months. Of these, *11 are in splendid health* without any trouble from their kidneys, the majority controlled with urography. Of this number 2 are malformations, 4 vesico-vaginal fistulas, 2 papillomata and 3 cancers. One of the fistula patients is troubled during the daytime with reflectory diarrhoea 10—12 times, but can get through the night without needing to evacuate her bowels. *4 are well:* 2 malformations and 2 cancers. They have excellent renal function but symptoms of infection in the form of pyelites now and then, *5 show impaired renal function but are subjectively healthy*, including 2 malformations (one of these with only one functioning kidney), 1 papilloma (only one kidney functioning) and 2 cancers. *2 patients* show *impaired renal function*, but are subjectively in a fairly satisfactory condition, the one with a contracted bladder and the other described in the records as a case of incontinentia et retentio post partum. *One patient* with exstrophy of the bladder is pronouncedly *suburemic*, in a somewhat affected general condition. (Admitted to Karolinska Sjukhuset in Jan. 1946; renal function improved rapidly, general condition good. Nephrolithotomy and nephrostomy were performed on 15. 1. 1946.)

Thus in the majority of cases the *renal function* has been good; with normal excretion on urography even where there has been a certain dilatation, and non-protein nitrogen (NPN) has in most cases been normal. It is worthy of note that among the living, as also in one of the deceased (page IV, record 2283/42) (a patient who went about for 2 years with NPN approximately 100 but whose general condition was good), a heightened NPN has in some cases been noted although the general condition has been excellent and the patients in question have shown no actual uremic symptoms. It has been suggested that the heightened NPN in these cases might be due to a reabsorption of urine from

the intestine. This is very conceivable, since, as GREY TURNER has demonstrated, the whole of the large bowel serves as a reservoir for urine. In some of our cases it has been observed after urography that contrast-containing urine collects in the colon right up to the hepatic flexure, but it is noteworthy that on evacuation of the bowel only the rectum and flexura sigmoidea are evacuated, while contrast-containing urine may remain in descendens and transversum. REIMERS, amongst others, has shown (1935—1936) that the urine is resorbed from the ventricle and the small bowel on experimental bilateral implantation with rapid uremia as a consequence. On implantation to the colon, on the other hand, he found no definite changes in the chemistry of the blood with ordinary methods of examination. In our material, apart from the NPN value, the urea nitrogen in the blood has been determined separately several times, in which connection it has varied within ordinary limits both with normal NPN value, with heightened NPN and with a uremic condition.

A number of all the patients (total seven), chiefly those suffering from exstrophy of the bladder, have been troubled with incontinence at night, due to the fact that these patients often suffer from a congenital weakness of the anal sphincter and rectal prolapse that is sometimes in need of treatment. In cases of vesico-vaginal fistula after injuries sustained in delivery there is often at the same time an insufficiency of the rectal sphincter, and in these cases it is probably advisable, if possible, to operate on the sphincter before the ureteral implantation. The patient has generally needed to evacuate the bowel at intervals of two to four hours during the day and 0—3 times during the night (the majority not at all or only once). Very seldom occasional or chronic irritation of the rectal mucous membrane arises. Late intestinal changes (pseudomembranous proctitis) are frequent in patients with serious impairment of the renal function and uremia (see the post-mortem cases page II, records 407/45, 307/41, page IV, record 364/41), in one case after the implantation of only one ureter. Among the survivors in our material one woman with contracted bladder had severe intestinal trouble with hemorrhages due to colitis, without visible ulcerations. The colitis improved after local treatment, but a certain nightly incontinence arose three years after the implantation. Slight intestinal irritation has been noted in a further 2 cases, of which the one, however, had had X-ray treatment earlier. (See, for the rest, the tabulated case-histories.)

Comparison between different methods of implantation.

In the light of our own material and the data given in the literature an attempt will here be made to assess the different methods of implantation.

To judge from all the evidence the submucosal principle in implantation is best, even if a muscular canal according to Stiles has also proved to give good results. This is probably due to the good anchorage of the ureter obtained with this method by means of the so-called "anchoring suture" (which is also employed in Coffey I), in contradistinction to the Russian methods according to Tichow and others, where there is no such anchorage.

Coffey's third method or modifications of this according to FERGUSON, HIGGINS, REIMERS, JEWETT and others, where the ureter is implanted submucosally (intact), and communication with the intestine is brought about later with various methods, is, as also SÖDERLUND has pointed out, altogether too complicated, is not always technically feasible and can scarcely yet be considered to have passed the experimental stage. As a rule, the final anastomosis between the intestine and the ureter is here attained by means of a lateral slit, which has been shown by experiments on animals to have a strong tendency to contract.

Coffey's second method does not eliminate, as COFFEY himself considered, the risk of ascending infection, which often arises when the catheter is removed. The advantage is supposed to be that during the first period the flow is free, but experimental investigations by STEVENS & LORD show that in spite of this, one does find an initial increase of non-protein nitrogen of a kind similar to that found in Coffey I; and this increase can thus not be solely due to edema and obstruction in the anastomosis, but must be partly due to other causes. Not infrequently there is a blocking of the ureteral catheters, so that the flow is obstructed. This occurred no fewer than 8 times in COFFEY's own 66 ureteral implantations according to this method, so that in 5 cases ureterostomy or nephrostomy had to be performed. It has also proved that the ureter does not as a rule separate at the point marked for the purpose by the ligature around the catheter, but higher up instead, so that the ureter may slough even a good way up in the canal, with the risk of secondary stenosis. According to WALKER-TAYLOR and HINMAN, when a catheter is used an anemic

pressure-necrosis may easily arise in the wall, which may even lead to peritonitis. As COFFEY himself describes the technique, one makes in C. II a larger hole in the intestinal mucous membrane than in C. I, and this is closed by means of a suture passing through all the layers of the intestinal wall. This suture will thus not be aseptic, and there will therefore be a certain risk of contamination and progressive infection in the canal. The fixation of the ureter in the canal is even worse, and several cases are described in which the ureter has retracted into the abdominal cavity and peritonitis has arisen.

Among the advantages of *Coffey's first method* is a reliable fixation of the ureter by means of the so-called "anchoring suture", with which the ureteral stump is drawn into and fixed in the intestinal lumen. Thanks to this reliable fixation of the ureter there is no need for several rows of sutures, which may easily entail strangulation of the ureter and disturbance of the circulation with necrosis and infection as a consequence. A portion of the ureteral end projecting into the lumen probably always sloughs, and in Coffey's second method the length of this portion cannot be estimated. Also in Coffey I, if a more serious infection arises, a larger portion may necrotize, and there must therefore always be a certain minimum stump. But an all too long stump is not good either, since in this case circulatory disturbances may easily arise, with increased risk of infection and stenosis.

Peritonitis occurs, as HINMAN and others have demonstrated experimentally, very seldom through primary contamination in the course of the operation, which is also completely confirmed by our own experience, but instead through leakage after the operation through a tearing out of sutures or through necrosis. The risk of peritonitis with Coffey's first method is minimal, and there is therefore no reason to complicate the operation by performing it extra-peritoneally (as CABOT). The great risk is of ascending infection, whose causes have not been thoroughly investigated. One cannot make the large bowel sterile, even if the risk of infection is diminished by the use of sulfa-preparations. The necroses that always arise in the anastomosis undoubtedly favour infection. Of great importance, both as regards the arising and the continuation of infection, is the urinary stasis that from mechanical and perhaps also dynamic causes may appear in a greater or lesser degree in connection with all forms of ureteral implantation. There is nothing, however, to favour the assumption that

this risk is greater with Coffey I than with other methods, rather the contrary. As emerges from our own experience and that of others, and infection may very well clear up if the flow in the urinary passages is unhindered, *i. e.* if the new ureteral orifice and the ureter are not definitively stenosed.

One disadvantage of Coffey's first method, especially in malignant cases, is that the implantations should preferably be performed in two stages, though as a rule this probably does not play any very important rôle. With very dilated ureters one can combine Coffey's first and second methods by fixing the ureter to the intestinal wall in the usual way, and inserting in the same a soft rubber tube, which should not be so big as to press against the ureteral wall and not be fixed to the ureter, but allowed to lie loose, so that it may be easily drawn out. The tube then serves only as a support during the operation and ensures the outflow during the first days.

Conclusions.

Ureteral implantation according to Coffey's first method is an operation which, performed with the right technique, is combined with a very low primary operative mortality.

After the implantation there appears as a rule a more or less pronounced dilatation of ureters and pelves, but this dilatation often recedes, at least partially, which also applies to dilatations that have existed before the implantation.

In addition to the dilatation, and probably largely conditioned by this, there often appears an infection of the upper urinary passages, but in the majority of cases this is slight or transient.

In certain cases, however, owing to dilatation and infection, a renal insufficiency arises that may have a fatal issue. Because of this, and on account of the discomfort of more or less frequent evacuations of the bowel occurring in a number of the patients, an ureteral implantation must be regarded as a serious operation that should only be resorted to where it is definitely indicated.

According both to our own experience and to the data given in the literature, the ureteral implantation according to Coffey I does not give worse, but rather better, immediate and final results than other, as a rule more complicated, methods for ureteral implantation in the intestine.

	Deaths before discharge		Deaths after discharge		Results of ureteral implantation Observation period in years		
	from consequences of op.	from the original disease	from consequences of op.	from the original disease	Good	Satisfactory	Poor
Congenital malformations			1 ($3\frac{1}{2}$ y.)		4 ($\frac{1}{2}$, $2\frac{1}{6}$, $4\frac{1}{2}$, $4\frac{1}{2}$)	2 ($3\frac{1}{2}$, $3\frac{2}{3}$)	1 (5; well for 4 y.)
Incontinence & retention after delivery						1 ($\frac{1}{2}$)	
Contracted bladder non T. B. ..						1 ($<$ 4)	
Tuberculous contracted bladder (single kidney)			2 ($1\frac{1}{2}$ m, $2\frac{1}{4}$ y.)				
Benign vesico-vaginal fistulas ...			1 ($\frac{1}{2}$ y.)		2 ($2\frac{1}{2}$, 4)	2 ($\frac{5}{6}$, $1\frac{3}{4}$)	
Vesico-vaginal fistulas after cancer uteri				2			
Papilloma vesicae—cystectomy .					2 ($1\frac{1}{6}$, $3\frac{1}{2}$)	1 ($<$ $1\frac{1}{2}$)	
Carcinoma—cystectomy	1 (rectal lesion)		1 (3 m.)	2 ($\frac{1}{3}$, $\frac{1}{2}$ y.)	8 ($>$ $\frac{1}{2}$, $\frac{2}{3}$, $\frac{3}{4}$, $1\frac{1}{3}$, $2\frac{1}{4}$, 4) (2 recently op.)		
Carcinoma—not cystectomy.....	1 (pyelonephrit.)	2		4	2 ($\frac{1}{2}$, $1\frac{1}{2}$)		1 (incompletely op.)
Cancer vulvae					1 ($>$ $\frac{1}{2}$)		
Total	2	2	5	8	19	7	2 (one incompletely op.)

Summary.

Ureteral implantations according to Coffey's method I. have been performed on 45 patients: 3 children, the rest 20—78 years of age. The indications for ureteral implantation have been the following: exstrophia vesicae 6; epispadia totalis 2; incontinentia urinae p. part. 1: vesica urin. contr. 2; fistula vesico-vaginalis 8; papilloma vesic. urin. 3; cancer vesic. urin. 21; cancer prostatae 1; cancer vulvae et urethrae 1.

In all the cases except 2 the implantations have been performed in 2 stages, as a rule commencing with the right side. Ureteral dilatation, even when very pronounced, has not been regarded as a contraindication, rather the opposite.

In no case has peritonitis or serious wound infection arisen. 4 patients — all suffering from cancer vesicae — have died in hospital, 2 of the original disease, 1 of rectal injury in connection with the cystectomy and 1 of pyelonephritis. 13 patients have died after discharge, 8 of the original disease — cancer —, the other more or less due to the ureteral implantation, resulting from infection and dilatation of ureters and pelves. Infection and dilatation with impaired renal function have often existed, however, before the implantation. By means of repeated excretory urographies it has been found that the dilatation of ureters and pelves that as a rule appears after the implantation generally recedes more or less completely later on. The condition among the survivors is good in 17, satisfactory in 9 and poor in 2 cases.

Ureteral implantation according to Coffey I gives not worse, but rather better results — both immediate and later — than other often more complicated methods. It is, however, a serious operation, which should be resorted to only when it is definitely indicated. In cases of infiltratively growing cancers of the bladder in connection with cystectomy the method should, however, be resorted to at an earlier stage than it has as a rule been possible for us to do.

Zusammenfassung.

Ureterenimplantationen nach Coffeys I. Methode sind an 45 Kranken vorgenommen worden, 3 Kinder, die übrigen 20—78 Jahre alt. Die Indikationen der Ureterenimplantation waren fol-

gende: 6 mal Exstrophia vesicae, 2 mal Epispadia totalis, 1 mal Incontinentia urinae p. part., 2 mal Vesica urin. contr., 8 mal Fistula vesico-vaginalis, 3 mal Papilloma vesicae urin., 21 mal Cancer vesicae urin., 1 mal Cancer prostatae, 1 mal Cancer vulvae et urethrae.

Die Implantationen wurden in sämtlichen Fällen, ausser 2, zweizeitig vorgenommen, im allgemeinen zuerst rechts. Eine Ureterenerweiterung wurde, selbst wenn sie hochgradig war, nicht als Gegenindikation angesehen — eher umgekehrt.

In keinem einzigen Falle ist Peritonitis oder eine schwerere Wundinfektion aufgetreten. 4 Kranke — alle mit Blasenkrebs — sind in der Klinik gestorben, 2 von ihnen an der Grundkrankheit, 1 wegen Rektalverletzung bei der Blasenexstirpation und 1 wegen Pyelonephritis. Nach der Entlassung sind 13 Kranke gestorben, 8 an der Grundkrankheit (Krebs), die übrigen Todesfälle mehr oder minder direkt durch die Ureterenimplantation, infolge von Infektion und Erweiterung der Ureteren und Nierenbecken. Eine Infektion und Dilatation mit herabgesetzter Nierenfunktion war jedoch oft schon vor der Implantation vorhanden. Durch wiederholte Urographie fand man, dass die sogleich nach der Implantation in der Regel auftretende Erweiterung der Ureteren und Nierenbecken, später zumeist mehr oder weniger vollständig zurückgeht. Unter den überlebenden Fällen ist der Zustand bei 17 gut, bei 9 befriedigend und bei 2 schlecht.

Die Ureterenimplantation nach Coffey I gibt sowohl unmittelbare Ergebnisse als auch Spätresultate, die nicht schlechter, sondern eher besser, sind, als die der übrigen, oft komplizierten Methoden. Sie stellt jedoch einen ernsten Eingriff dar, der nur auf strenge Indikationen hin zu verwenden ist. In Verbindung mit Zystektomie bei infiltrativ wachsendem Blasenkrebs sollte die Methode jedoch in früherem Stadium Verwendung finden, als es uns zumeist möglich war.

Résumé.

On a pratiqué des transplantations d'uretère suivant la méthode Coffey I sur 45 malades. 3 malades seulement étaient des enfants, les autres étaient âgés de plus de 20 ans et le doyen de 78. Les indications ont été les suivantes: exstrophie de la vessie, 6 cas; épispadias total, 2; incontinence d'urine après accouchement, 1;

vessie contractée 2; fistule vésico-vaginale, 8; papillome de la vessie, 3; cancer de la vessie, 21; cancer de la prostate, 1; cancer de la vulve et de l'urèthre, 1.

Dans tous les cas sauf deux, les implantations ont été pratiquées en deux séances en commençant généralement par la droite. Une dilatation même très prononcée de l'uretère n'a pas été considérée comme une contre-indication, plutôt le contraire.

Dans aucun des cas on n'a observé de péritonite ou de graves suppuration de la cicatrice opératoire. 4 malades, tous atteints de cancer, sont morts à l'hôpital; 2 de la maladie initiale, 1 à la suite de lésions du gros intestin, consécutives à la cystectomie et 1 de la pyélonéphrite. 13 malades sont morts après leur sortie de l'hôpital, 8 de l'affection primaire, cancer, les autres plus ou moins par l'implantation des uretères suivie d'infections et de dilatation des uretères et des bassinets. Cependant on a fréquemment constaté la présence de l'infection et de la dilatation avec insuffisance rénale avant l'opération. Des urographies répétées ont permis de constater que la dilatation des uretères et des bassinets suivant immédiatement l'implantation, rétrocède dans la suite dans la plupart des cas. L'état des survivants est bon dans 17 cas, satisfaisant dans 9 et mauvais dans 2 cas.

L'implantation des uretères d'après Coffey I ne donne pas des résultats pires mais plutôt meilleurs, immédiats aussi bien qu'éloignés, que d'autres méthodes parfois plus compliquées. Mais c'est une intervention grave qui ne doit être utilisée que sur indications strictes. Dans les cancers infiltrants de la vessie avec la cystectomie c'est un procédé à utiliser plus tôt que nous n'avons pu le faire.

Bibliography.

Bergenhem, B: Eira 1895: 19: 265—275. — Cabot, H: New Engl. J. Med. 1931: 205: 706—711. — Coffey, RC: Brit. J. Urol. 1931: 3: 353—428. — Dobrzaniecki, W: J. d'urol. 1938: 45: 512—523. — Graves, RC & Thomson, RS: J. Urol. 1944: 52: 448—454. — Hepler, A: J. Urol. 1940: 44: 794—807. — Hellström, J: Ztschr. f. urol. Chir. u. Gynäk. 1935—36: 41: 522—528. — Higgins, CG: Surgery 1937: 2: 1—11. — Higgins, CG: J. Urol. 1943: 50: 657—666. — Hinman, F, Murphy, Wayman, McCorkle & Benteen: Surg. Gynec. & Obst. 1936: 62: 909—917. — Hinman, F & Weyrauch, J: Surg. Gynec. & Obst: Internat. Abstr. Surg. 1937: 64: 313—363. — Hinman, F & Smith, D: Surgery 1939: 6: 851—881. — Hinman, F & Weyrauch, J: Surg. Gynec. & Obst. 1942: 74: 129—136. — Lower,

WME: J. Urol. 1943: 50: 581—584. — MAYO, CH: Contributions to medical and biological research, N. Y. 1920, quoted by WALKER-TAYLOR. — MAYO, CH: S. Clin. North America 1921: 1: 1257—1266. — MAYO, CH & HENDRICKS, W: Surg. Gynec. & Obst. 1926: 43: 129—134. — McCOMB, RJA: J. Urol. 1942: 47: 240—248. — NESBIT, RM: Tr. Am. Genito-Urin. Surgeons 1943: 36: 286, reviewed in Arch. Surg. 1945: 50: 108—109. — PRIESTLEY, JT & STROM, GW: J. Urol. 1943: 50: 210—227. — REIMERS, C: Ztschr. f. urol. Chir. u. Gynäk. 1935—36: 41: 6—28, 29—51. — REIMERS, C: Ztschr. f. urol. Chir. u. Gynäk. 1941—43: 46: 71—110. — SHILOVTZEFF, SP: Lancet 1939: 237:412—415. — STEVENS, AR & LORD, JW: J. Urol. 1943: 50: 574—579. — SÖDERLUND, G: Acta chir. Scand. 1944: 91: 317—352. — TILK: Deutsche Ztschr. f. Chir. 1943: 257: 287—302. — TURNER, G GREY & SAINT, JH: Brit. J. Surg. 1935—36: 23: 580—597. — TURNER, G GREY: Brit. M. J. 1943: 535—538. — WALKER-TAYLOR, PN: Australian & New Zealand J. Surg. 1931—32: 1: 158—191. — WALTERS, W: Arch. f. klin. Chir. 1931: 167: 589—600 and Am. J. Surg. 1932: 55: 15—22. — WALTERS, W & BRAASCH, W: Am. J. Surg. 1934: 63: 255—270. — VERMOOTEN, V: J. Urol. 1934: 32: 261—265, 266—272. 273—277, 330—334. — ÅKESSON, N: Nord. Med. 1942: 14: 1967—1971,

From the Surgical Clinic of Karolinska Sjukhuset, Stockholm.
(Chief: Professor J. HELLSTRÖM.)

On the Treatment of Perforated Gastric and Duodenal Ulcer.

By

IVAR R. SANDBERG.

There would seem to be full agreement that the treatment of ulcus gastroduodenale perf. should be operative. On the other hand, the question of what surgical procedure is preferable as normal method has been the subject of wide discussion. Two different opinions may be broadly distinguished. One recommends primary resection, the other conservative operation with merely a stitching over of the ulcer or its excision with following suture, possibly combined with a gastrostomy or a gastro-enterostomy.

Among the reasons given for the radical operation are the following. Better late results are attained, depending on the fact that both the ulcer and the whole ulcer-bearing area are removed, thereby simultaneously effecting a reduction in the secretion of hydrochloric acid, a desirable result in these cases because, even if the hydrochloric acid does not directly contribute to the origin of the ulcer, it is considered to exercise a detrimental action on the healing conditions (YUDINE, RICHTER, etc.). There is a risk of peptic ulcer of the jejunum arising in cases treated with a gastro-enterostomy. The frequent multiplicity of the ulcers is also pointed out as well as the risk of new perforations (YUDINE, v. HABERER, BROCQ, etc.). Another point brought forward in defence of the radical method is that in kissing duodenal ulcers especially the anterior ulcer has a tendency to perforate, while the posterior one tends to penetrate into the pancreas. Then, too, there is the risk of cancerous degeneration of the ulcer and

of haemorrhage from it (PETERS, etc.). Moreover, YUDINE considers that a resection is technically easier to perform in perforated ulcer than in old, chronic *à froid* cases. Several of these active surgeons, however, decline to perform a resection on corpulent patients in late cases, as this operation is then fraught with great risks for the patient's life, and in these circumstances they recommend solely closure of the ulcer by suture (ABOULKER, BROCQ, FRIEDEMANN, RICHTER, YUDINE). HONKANEN considers that an accompanying disease of a nature such as tuberculosis, diabetes or lues is also a contra-indication to resection. On the other hand, he sees no contra-indication in peritonitis if this does not appear to be septic or combined with intestinal paresis. According to ULLAND, under favourable conditions (in town material) it ought to be possible to perform primary resection in about 50 % of the cases, but when the radical operation is contra-indicated he recommends solely suture for patients under 50 years, and suture with gastro-enterostomy for patients above this age.

The advocates of conservative surgical therapy maintain that a patient with a perforated gastric ulcer is in immediate danger of life, and therefore the operation employed should be simple and easy in technical execution. There is well established evidence, it is further claimed, that a number of those treated by the suturing method remain cured (BAGER, BRUUSGAARD, GELIN, GREVILLIUS and CEDERLUND, SCHILLING, SÖDERLUND, ZUCKSCHWERT and ECK), and hence this method enables a number of patients to escape an unnecessary resection. "It is not a matter of indifference to the patient whether he goes home with a whole or a half stomach, and if a resection can be avoided I consider it ought to be", says BOHMANSSON. BAGER in his great work comes to the conclusion that suture alone or, preferably, suture after excision of the ulcer, mopping of the abdomen, gastrostomy and primary closure of the abdomen (= the Maria method) ought to be the normal method. He considers the risk of a new perforation or of cancer degeneration to be so slight that it can be left out of account in the choice of the operative method, and that in any case it is not greater than the risk of peptic ulcer of the jejunum after gastro-enterostomy or resection. Respecting the risk of iterated perforations, BJÖRKROTH, supported by his own material and reports in the literature, writes that "there is no evidence of sufficient strength to motivate primary resection".

The crucial points in the discussion on the most suitable method of treatment are the primary operative mortality and the late results.

A comparison of the mortality figures of the active school with those of the more conservative school shows that both sides can present beautiful results. In several recent statistics the mortality is on the whole considerably lower than in works published only a few decades ago. Even if the figures are not fully comparable owing to the differences in several factors, such as the age and general condition of the patient as well as the time intervening between perforation and operation, it ought to be of interest to study some more recent works. See Table 1.

Table 1.

Primary Results of Some Authors.

Author	Years covered by the material	Number of cases	Total mortality in %	Number of resections	Mort. in resect. cases in %	Mort. in conserv. treated cases in %	Mean age
Bager.....	1911—25	1,495	32.8	89	29.2	34.3	
Björkroth..	1922—40	351	18.2	106	16	15.7	
Bruusgaard	1915—40	107	11.2	24	4.5	6.5	2/3 under 40
Cederlund and Grevillius ...	1925—39	189	21.7	29	10	23.1	
Gelin.....	1932—43	225	18.2				
	1932—41	150	20	9	11	20.5	45
Honkanen..	1929—38	66	22.7	39	15.4	33.3	High
Mc Creery .	1920—36	170	20.5	1			
Raw.....	1939—43	312	14.4	0		14.4	157 under 42, 155 over 42
Richter....	publ. 1944	134	18	120	13.3	57	45
Schilling...	1912—34	265	13.2	4	0	13.1	
Thompson...	1921—34	500	39.4	0		20	
Ulland.....	1929—42	134	11.2	57	3.5	22.8	3/4 between 20—50
Wakeley...	1924—34	103 mil.	8	0		8	32
		102 civ.	20			20	46
Yudine.....	1928—37	1,174	14.9	888	9.0	33.5	Rel. low

Yudine has personally operated on all his cases, and his figures are impressive, although they have their limited value. They show what results can be achieved by a man unusually experienced and skilled in the surgery of the stomach. Bohmansson also emphasizes that even if the primary resection mortality can

be kept low by experienced and skillful stomach operators, it is not permissible to generalize, seeing that the majority of operations for perforation are performed in Sweden at small hospitals and by less efficient operators. According to RICHTER, primary resection is performed in Sweden in 5 % of the perforated ulcer cases. At the annual meeting in 1944 of the Swedish Association of Surgeons it was, as a matter of fact, maintained by the majority of those who expressed an opinion that excision with suture or solely suture ought to be the most suitable method of treatment. Only the Finnish surgeon HÄMÄLÄINEN broke a lance in defence of primary resection.

Late results. YUDINE examined 83 resected patients 3—8 years after the operation and found excellent results in 75.5 %. Of 50 cases treated solely with suture, 22 % were without symptoms, though it should be added that these 50 cases belonged to the group pre-operatively selected as bad. HARSTAD followed up 78 of 87 patients discharged from the Trondheim hospital and found that 18 (= 34 %) of 53 patients treated solely with suture were free from recurrence. Suture with gastro-enterostomy gave non-recurrence in 16 cases of 22. The examination was made 1—26 years after the operation. HONKANEN, with a period of at least two years' follow-up observation, found 19 healthy among 25 resected patients, and 6 healthy among 18 patients who had undergone a palliative operation. Of SCHILLING's material, for which the normal method was suture and gastro-enterostomy, 88 were followed up at least two years after the operation, and 72 proved to be healed and 15 % improved. BRUUSGAARD presents very satisfactory results from the Maria method, which gave 65 % free from symptoms 1—4 years after the operation. GREVILLIUS and CEDERLUND report freedom from symptoms for 26.3 % of the sutured cases, 41.2 % for the patients treated with excision and suture, 41.7 % for the suture with gastro-enterostomy group and, finally, 66.7 % among the resection cases. Strong symptoms were shown in 53.7, 41.2, 25.0 and 23.8 per cent respectively of the different groups. Of ULLAND's material of 134 cases, 98 were followed up $1^1/_2$—14 years after the operation. Unsatisfactory results were obtained in 12 % after primary resection, in 56 % after suture with gastro-enterostomy, and in 79 % after solely suture. BAGER, in his follow-up of 318 patients treated by excision with suture or solely suture, found that 1—15 years after the operation 56.3 % were healed or improved.

Personal Material.

At the Surgical Clinic and Garrison Ward of Karolinska Sjukhuset altogether 110 patients were treated for ulcus gastroduodenale perf. from the time the hospital was opened in February, 1940, to the end of 1944. In 60 of the cases the ulcer was situated in the stomach and in 48 in the duodenum. On two occasions the operator could not determine whether the ulcer was located on the gastric or duodenal side of the pylorus.

Of the 110 patients, 63 were attended at the Clinic, 54 men and 9 women, and 47 patients, all men, in the Garrison Ward. Thus, 14 % of the Clinic's patients were women.

Age. The youngest patient was 18 years and the oldest 83. The age distribution is given in Table 2. As is seen, most of the patients belong to the age-groups 21—50 years. The mean age of the whole material is 40.8 years (of the Clinic patients 44.6 years, Garrison Department 35.8 years).

Table 2.

Age Distribution.

Age	11—20	21—30	31—40	41—50	51—60	61—70	71—80	81—90
No. of pat.	3	26	27	29	17	6	1	1

Ulcer history before the acute onset. On 108 case-cards it is stated if the patient had suffered from ulcer symptoms before. On the basis of the length of the previous history the material is divisible into the groups given in Table 3. In about 10 % there are no symptoms of ulcer disease and in 24 % the patient had symptoms no longer than 4 weeks. Fully one-half of the patients had a past history of more than one year.

Table 3.

Ulcer History before Acute Onset.

Time	0	1—7 d.	1—2 w.	2—4 w.	1—6 mo.	1/4—1 yr.	1—5 yr.	5—10 yr.	More than 10 yr.
No. of pat...	11	13	4	9	8	6	22	16	19

X-ray examination before the operation by general survey views was carried out in 86 cases, these showing free gas in the abdominal cavity 60 times (73 %) and no free gas 23 times (27 %). In the latter group of patients, however, in some cases X-ray examinations were performed and a positive diagnosis was obtained owing to the fact that a small amount of opaque medium given by mouth had passed out through the perforation-opening into the abdominal cavity. In 24 cases no X-ray examination was made.

Of the whole material, 105 patients were operated upon and 5 were not.

Three of the non-operatively treated five patients had so-called covered perforations, and in these the acute symptoms rapidly subsided. One was, however, operated on seven days later, and the other was transferred to the Medical Clinic for ulcer treatment, but was returned after ten months and operated upon for symptoms of stenosis. In both cases a Billroth II resection was done with good result. The third patient with a covered perforation was also transferred to the Medical Department and there underwent a course of ulcer treatment.

The other two patients not operated upon were a man of 83 years and a woman of 75. On admission to the hospital both were in such a poor state that surgical therapy was not considered possible. Both of them died. See Table 6.

Mortality. Of the whole material of 110 patients, 12 died, which gives a total mortality of 10.9 %. On the surgically treated material the mortality was 9.5 % (10 died out of 105). (See also the discussion below on the deaths.) Surgical cases below 50 years of age showed a mortality of 6.2 % (5 died out of 81 patients), while for those above 50 years the figure was 20.8 %. The average interval from perforation to operation was 12.6 hours for the younger group and 7.3 hours for 23 patients belonging to the older group. Belonging to this group there was also a patient with a 10-days' old perforation. However, as the unusually long interval in this case would have quite dislocated the average for the other 23 patients of this group, I have considered it most correct with this division.

Table 4.

Interval of Time between Onset and Operation.

Interval	No. of pat.	No. of deaths	Mortality
— 6 hr. ..	68	4	5.9 %
6—12 » ..	28	3	10.7 %
12—24 » ..	5	1	(20 %)
more than 24 » ..	4	2	(50 %)

A distribution of the material according to the interval from onset to operation is given in Table 4. With an interval of up to 6 hours the mortality was 5.9 % and with one of 6—12 hours it was 10.7 %. Although the groups with a longer interval are small, the figures emphasize the importance of early operation.

Excision with suture was carried out in 48 cases, with 3 deaths, and solely suture in 58 cases, with 5 deaths. In 92 of these 100 cases a gastric fistula was made by Witzel's method, and in 2 patients a duodenal tube was inserted nasally for constant drainage: in 6 cases neither a fistula nor a tube was used. Abdominal flushing was carried out in 10 cases: in the other cases only mopping.

Table 5.

Operation.

Excision + suture	48	pat.,	of	which	3	died
Suture	52	» ,	»	»	5	»
Exc. + suture + anterior G. E. + E. A.	1	» ,	»	»	1	»
Primary resection	3	» ,	»	»	0	»
Incision + drainage	1	» ,	»	»	1	»
Total	105	pat.,	of	which	10	died

Excision with suture and anterior gastro-enterostomy plus entero-anastomosis was resorted to once. The reason for the gastro-enterostomy was an intense contraction of the duodenum round the ulcer. The patient died 7 days after the operation. See case 6 in Table 6.

Primary resection according to Billroth II was undertaken in 3 cases two to four hours after onset, all with good results.

Solely incision was done on a 51-year-old man 10 days after onset and a downwardly demarcated abscess was opened. At the same time a jejunostomy was established for nutritive purposes. This patient underwent another laparotomy five days later for suspected mechanical ileus. He then had a diffuse peritonitis. There was no absolute obstruction, but there was a kink in the small intestine at the site of the fistula. As the lumen of the small intestine was rather constricted here, an entero-anastomosis was established between a loop above and below the constricted point. The patient died 18 days after admission. See case 10 in Table 6.

As indicated in Table 6, in addition to their ulcerous disease several patients had disorders that led to or strongly contributed to the lethal issue. Case 2 died six days after the operation and had a hepatic cancer with jaundice. The pathological examination of the excised gastric ulcer showed no signs of malignancy. No peritonitis at autopsy. In case 6 the liver was studded with metastases from a cancer maxillae, for which at the time of the acute ulcer onset the patient was being treated at the Ear, Nose and Throat Clinic. The patient died seven days after the operation, autopsy revealing a diffuse peritonitis in addition to the cancer metastases.

These two cancer cases constitute an abnormal load on the mortality in this material, since the cancer of these two patients must be regarded as the chief cause of death, and the perforating ulcer as only a contributive cause. A more correct picture of the mortality from ulcus perforans in this material is therefore obtained if these two cases are deducted, when the mortality in the surgical material will be 7.8 % (8 patients died of 103) and in the whole material 9.3 % (10 patients died of 108).

Case 3, a woman aged 27 years, was operated upon 5—6 hours after onset of her perforating ulcer of the stomach. Tubercle bacilli were present in expectoration. After 17 days, incision of a subphrenic abscess. The patient wasted away and died in a cachectic state 83 days after admission to the hospital. Autopsy showed, in addition to a pulmonar tuberculosis and a miliary tuberculosis of the pleurae, a left-sided

Table 6.

Causes of Death

(besides ulcus gastro-duodenale perf.).

Pat. operated on.				
—6 hr.	1)	Cl.	323/41, 58 yr.	Pneumonia + insuff. of bone-marrow with sec. anaemia.
	2)	»	426/43, 62 yr.	Cancer hepatis + icterus.
	3)	»	3218/43, 27 yr.	Subphren. abscess + T. B. pulm. et pleurae.
	4)	G. W.	999/43, 38 yr.	Abscessus subphrenicus et fossae Dougl. et cerebri + empyema pleurae + sepsis.
6—12 hr.	5)	Cl.	2378/41, 70 yr.	Large perf. ulcus on post. side of stomach opposite that operated on + subphren. abscess + diffuse peritonitis + sec. haemorrhage + bronchopneumoniae.
	6)	»	2446/41, 40 yr.	Whole liver studded with metastases from cancer maxillae + peritonitis + bronchopneumonia.
	7)	»	638/42, 42 yr.	Pneumonia bilat. + abscessus pulm. + renal insufficiency.
12—24 hr.	8)	G. W.	1943/43, 59 yr.	2 perf. ulcera ventriculi (besides the ulcus duodeni operated on) + abscess. subphren., retroperitoneal. et pelvis + bronchopneumonia + myocarditis.
more than 24 hr.	9)	»	2875/42, 44 yr.	Bronchopneumonia + pericarditis.
	10)	»	2716/43, 51 yr.	Abscess round perf. ulcus + diffuse peritonitis.
Pat. not operated on.				
	11)	Cl.	769/44, 83 yr.	Cancer buccae + cardiosclerosis + divertic. sigmoid. perf. + peritonit. diff. + bronchopneumoniae.
	12)	»	3814/43, 75 yr.	Peritonit. diff.

Cl. = Clinic; G. W. = Garrison Ward.

subphrenic abscess with perforation through the diaphragm to the pleura.

It is of interest to note that over and beyond the ulcer operated upon two patients were found at autopsy to have had a second perforated ulcer. One of them (case 5) was a man aged 70 years with a $6^1/_2$ hours' old perforation. He had an ulcer history of 16 years. The ulcer was only stitched over with primary closure of the abdomen. Neither a fistula nor a duodenal tube was inserted. A subphrenic abscess that developed postoperatively was incised 18 days after the first operation. Repeated blood vomits. In spite of several blood transfusions the haemoglobin fell from 85 % to 32 % and the number of R. B. C. from 4.76 to 1.8 millions. Autopsy disclosed a large perforating ulcer on the posterior wall of the stomach opposite the one operated upon, peritonitis, and haemorrhagic erosions in the stomach with blood-stained contents in the whole intestinal tube. The second of these patients (case 8), aged 59 years, had a stomach history of four years and was operated upon 15 hours after the acute onset. Raphi + fistula. Died on fortieth day. Autopsy showed two perforating gastric ulcers (be-

sides the duodenal ulcer operated upon) as well as multiple intra- and retro-peritoneal abscesses, bronchopneumonia and myocarditis. If primary resection had been performed in these cases, it is possible that the lethal issue might have been avoided, but in view of the high age of the patients it is probable, in any case as regards the older patient, that only a conservative operation would have been undertaken even if the normal method at the hospital had been primary resection.

Case 1, a man of 58 years, died after four days from a large right-sided pneumonia. He exhibited a peculiar blood reaction with leucopenia in spite of several blood transfusions and with nucleated red blood corpuscles, pointing to a bone-marrow inhyperfunction though nevertheless insufficient. Sulfapyridine was given on vital indications in spite of the leucopenia. Autopsy showed that no peritonitis was present.

The postoperative complications of the patients who did not die will be only briefly mentioned here. Abscess in the wound of the abdominal wall occurred twice, subphrenic abscess twice, biliary fistula once (in a primarily resected patient), bronchopneumonia four times, pleuritis once, pulmonary embolism twice and, finally, acute otitis once.

The duration of treatment in the hospital has shown a tendency to diminish for every year. For the year 1940 the mean time was 26.4 days and for the following years up to and including 1944 it was 25.1, 22.5, 21.6 and 15.1 days. These figures include all the patients, even those who died.

Follow-up Examination. The patients were examined 2—5 years after the operation. Of 54 possible cases data were obtained of 51, *i. e.* 93 %. Four patients had died. The causes of death were respectively coronal thrombosis, cancer palat. molle, cancer bronchiale, and catatonia acuta. Of the 47 followed-up patients, a few had visited the surgical outpatients' department of the hospital for control, while the majority either answered by letter a written inquiry concerning their state of health or gave an answer by telephone to the present writer.

The material has been divided into three groups.

Group I. Patients have been referred here who are completely healthy and can stand food of all kinds.

Group II. The patients in this group have some milder symptoms (do not feel well after eating certain foods) or are free of trouble on dieting. All of these are quite capable of working.

Group III comprises patients who after a period of freedom from symptoms have had a recurrence or who have never been free from symptoms after the operation. A number of these patients have later undergone another operation.

Group I. Of 47 patients 20 are quite healthy. Among these, 9 have been treated with suture alone, 9 with excision + suture, and 2 with primary resection.

Table 7.

Results of Follow-up Examination.

Operation	Free from symptoms	Mild symptoms	Severe symptoms		
			No medical-dietetic treatment	Medical-dietetic treatment	Re-operation
Suture	9	4	0	1	7
Exc. + suture ...	9	5	1	3	6
Resection	2	0	0	0	0
Total	20	9	1	4	13

Group II comprises 9 patients, 4 treated with suture and 5 with excision + suture.

To group III belong 18 patients. Of these, 13 have later undergone resection without deaths. Some of these operations were performed at Karolinska sjukhuset, some at another hospital. One patient was operated on according to Billroth I, 10 were radically operated upon by the Billroth II method, and in 2 cases palliative resection according to Billroth II was performed. On these secondarily resected patients suture had been performed seven times at the first operation and excision + suture six times. In the majority of cases the ulcer was found at the resection to be situated at approximately the same spot as at the perforation. But in two cases this was not the case. Of the 13 patients re-operated upon, 2 still have symptoms, while the others state that they feel well. However, the time during which these patients were under observation is too short to have any value in this connexion. Of the 5 patients not re-operated upon, 4 have undergone treatment for recurrence. One patient was healthy for 2 years but after that had fresh symptoms and X-ray examination shows a duodenal ulcer. This patient has not been under medical-dietetic treatment. For a certain period every year during the last three years she has had trouble.

Of patients with an ulcer history of not more than one year before perforation, 21 treated with suture or excision + suture have become healthy or only had mild symptoms, while 5 patients are to be referred to group III. On the other hand, if the morbid history was longer than one year, the corresponding figures resulting from the same treatment were 7 and 12 respectively. This corroborates, thus, the view that patients with

symptoms of longer standing have less chance of permanent cure by a conservative operation than those with a shorter history.

As a result of the follow-up examination it is thus seen that 40 % (18 patients of 45) have become free from symptoms as a result of suture or excision + suture. 20 % have mild symptoms but are fully capable of working, and 40 % show unsatisfactory results. Of these last-mentioned patients, about three-fourths have later undergone resection without deaths.

Discussion. From data in the literature and the experience gained from the present material treated at Karolinska sjukhuset the following conclusions ought to be justifiable concerning the treatment of perforated gastroduodenal ulcer.

Suture alone or preferably excision of the ulcer + suture together with covering with an omental flap, mopping of the abdomen as well as gastrostomy is to be recommended as the normal method, since the operation is easy to perform, seems to give a lower mortality than resection, and in about 40 % of the cases gives a good late result. By this procedure an unnecessary resection is avoided in rather a large number of cases. In the cases treated with suture alone a regular medical-dietetic treatment ought to follow. However, as a number of the patients have symptoms that persist or that recur after a period of quiescence, it is of importance for them to be under control in the future, when possibly a secondary resection will be found necessary. The simple primary operation can also be performed at places equipped for only simpler surgery (cottage hospitals and other small hospitals) and, if a resection should become necessary later, the patient, if this is considered suitable, may be sent to another hospital for operation. In certain cases, however, a primary resection is to be preferred, but the indications ought to be clear. A long ulcer history during which one or more medical-dietetic treatments have been undergone, a short interval between the perforation and the operation, a but little affected general condition in a rather young or middle-aged patient, who moreover does not present signs of another contra-indicating disease, are prerequisite conditions for a primary resection to be considered permissible, subject of course to the operator being a sufficiently experienced stomach surgeon. In duodenal ulcer or in gastric ulcer situated in the pyloric region Witzel's fistula or better a duodenal tube ought to be established. A gastro-enterostomy ought not to be done on account of the risk of a peptic ulcer

arising in the jejunum. However, should a primary gastro-enterostomy be considered as indicated on account of marked stenosis, a resection ought if possible to be performed at the same time in the case of young individuals. In elderly patients, *c. g.* above 50 years, where the risk of peptico-jejunal ulcer is less, a gastro-enterostomy alone may be regarded as permissible. Sulfathiazol treatment locally and intravenously is probably of value. Intravenous drip infusion as well as control of the fluid and salt balance is important.

If the diagnosis of perforated ulcer is clinically certain or highly probable, to save time operation ought to be undertaken immediately without a preceding X-ray examination. Should the latter be desirable for the purpose of differential diagnosis, however, if free gas is not visible on the general survey pictures, the examination should be supplemented by allowing the patient to drink a small quantity of opaque medium, whereby the diagnosis of perforation or non-perforation is made considerably surer without any risk to the patient.

Summary.

A review is given of especially the more recent literature on the subject, with special reference to the primary mortality and late results. During the years 1940—1944 110 patients (101 men and 9 women) were treated for perforating gastroduodenal ulcer at Karolinska Sjukhuset, 47 of the men at the Garrison Ward. The mean age was 40.8 years. Ten per cent of the patients showed no symptoms of ulcerous disease until the acute onset, and fully one-half had a history of more than one year. Free gas in the abdominal cavity could be demonstrated in 73 % of the cases examined by X-rays. 105 patients were operated upon and 5 were not. Of the last-mentioned, 3 were so-called covered perforations. The mortality for the whole material was 10.9 % and for those operated upon 9.5 %. After deducting 2 cases in which the chief cause of death must be considered to be primary hepatic cancer or hepatic metastases, the corresponding figures will be 9.3 and 7.8 % respectively. In 100 cases excision + suture or suture alone was undertaken, in 1 case in addition an anterior gastro-enterostomy + entero-anastomosis. Primary resection by the Billroth II method was done 3 times and only incision + drainage once. In 68 cases operation was performed within 6

hours of onset and in 28 the interval was 6 to 12 hours, with a mortality of respectively 5.9 % and 10.7 %.

The patients have been followed up 2—5 years after the operation. Of 54 possible cases data have been obtained concerning 51, *i. e.* in 93 % of the cases. Four patients died of another disease. Forty per cent of the patients have become free from symptoms as a result of suture alone or excision + suture. Twenty per cent have mild symptoms but are able to work. In 40 % the result is not satisfactory. Of the patients in this group, three-fourths have undergone resection secondarily without any deaths.

The investigation suggests that patients with long-standing ulcer symptoms have less chances of a good late result from conservative operation than those with a short history.

As a normal method excision + suture, possibly suture alone, is recommended, but under certain conditions a primary resection is to be preferred in selected cases. Chemotherapy locally or by intravenous drip infusion. Careful control of the fluid and salt balance.

Zusammenfassung.

Literaturübersicht, besonders über die diesbezüglichen neueren Arbeiten, unter besonderer Berücksichtigung der Primärmortalität und der Spätresultate.

Im Karolinischen Krankenhause waren in den Jahren 1940—1944 110 Kranke (101 Männer und 9 Frauen) wegen perforierendem ulcus gastroduodenale in Pflege, davon 47 Männer in der Lazarettsabteilung. Das mittlere Alter betrug 40.8 Jahre. 10 % der Kranken wiesen vor dem akuten Erkranken keinerlei Symptome der Ulkuskrankheit auf, und reichlich die Hälfte hatte eine Anamnese von mehr als 1 Jahr. — Freies Gas in der Bauchhöhle liess sich bei 73 % der röntgenuntersuchten Fälle nachweisen. — 105 Kranke wurden operiert, 5 nicht. Von den letztgenannten stellten 3 sog. abgedeckte Perforationen dar. Die Mortalität des Gesamtmaterials war 10.9 %, die des operierten Materials 9.5 %. Nach Abzug von 2 Fällen, bei denen ein primärer Leberkrebs oder Lebermetastasen als hauptsächliche Todesursache anzusehen sind, sind die entsprechenden Zahlen 9.3 bzw. 7.8 %. — Bei 100 Fällen wurde Exzision + Naht oder nur Naht vorgenommen, in 1 Falle ausserdem vordere G.E. + E.A. 3 mal wurde primäre Resektion nach Billroth II und 1 mal nur Inzision + Drainage

vorgenommen. — 68 Kranke wurden innerhalb von 6 Stunden nach dem Erkranken operiert und 28 nach 6—12 Stunden, und zwar mit einer Sterblichkeit von 5.9 bzw. 10.7 %.

Die Kranken wurden 2—5 Jahre nach der Operation nachuntersucht. Unter 54 Möglichen wurden von 51 Kranken, also 93 %, Angaben erhalten. 4 Patienten waren an anderen Krankheiten gestorben. — 40 % der Kranken waren durch Naht allein oder durch Exzision + Naht beschwerdefrei geworden. 20 % haben leichte Beschwerden, sind aber arbeitsfähig. In 40 % ist das Ergebnis nicht befriedigend. Von den Kranken in dieser Gruppe haben $^3/_4$ sekundär eine Resektion durchgemacht, und zwar ohne Todesfälle.

Die Untersuchung spricht dafür, dass Patienten mit langdauernden Ulkusbeschwerden geringere Aussichten auf ein gutes Spätresultat durch konservativen Eingriff haben, als diejenigen mit kurzer Anamnese.

Als Normalmethode wird Exzision + Naht, evtl. Naht allein, empfohlen, aber unter gewissen Bedingungen kann in ausgewählten Fällen eine primäre Resektion vorzuziehen sein. — Chemotherapie lokal und als intravenöse Dauerinfusion. Sorgfältige Kontrolle des Wasser- und Salzgleichgewichts.

Résumé.

Revue bibliographique du traitement de l'ulcère perforé de l'estomac et du duodénum traitant surtout des travaux récents sur le sujet, surtout en ce qui concerne la mortalité primaire et les résultats éloignés.

A l'hôpital Carolin à Stockholm, on a soigné entre 1940 et 1944, 110 malades (101 hommes et 9 femmes) d'ulcère gastro-duodénal, dont 47 hommes à l'hôpital militaire. Age moyen: 40.8 ans. Dans 10 % des cas, absence totale de symptomes avant l'attaque brusque et 50 % bien comptés ont une anamnese datant de plus d'un an. Dans 73 % des cas examinés radiologiquement, on a démontré la présence de gaz dans la cavité péritonéale. 105 malades opérés, 5 non opérés. Des derniers 3 étaient des perforations recouvertes. Mortalité des 110 cas, 10.9 %, des opérés 9.5 %. Si l'on retranche deux cas où la cause principale semble avoir été un carcinome primitif du foie ou des métastases cancéreuses du foie, les chiffres correspondants sont 8.3 % et 7.8 %. Dans 100 cas on a pratiqué l'excision et la suture ou simplement la suture,

dans 1 cas en outre g.-e. + e.-a., dans 3 cas la résection primaire suivant Billroth II et une fois l'incision suivie de drainage. Chez 68 malades on a pratiqué l'opération dans les 6 heures et dans 28 cas dans les 6—12 heures suivant les accidents de début avec des mortalités correspondantes de 5.9 et de 10.7 %.

Les malades ont été réexaminés de 2—5 ans apres l'opération On a obtenu des renseignements dans 51 cas sur 54 possibles, c'est-à-dire dans 93 %. 4 malades sont morts d'affection intercurrente. 40 % des malades ont été libérés de leurs symptômes à la suite de suture simple ou de suture + excision. 20 % souffrent de troubles légers mais sont aptes au travail. Dans 40 % des cas, le résultat n'est pas satisfaisant. De ce groupe de malades, les $^3/_4$ ont subi une résection secondaire. Mortalité nulle.

L'enquête semble prouver que les résultats éloignés sont moins bons chez les malades qui souffrent longuement à la suite du traitement conservateur que chez ceux dont l'histoire clinique est brève.

C'est la résection + suture ou la suture seule que l'auteur recommande comme méthodes normales, mais, dans certaines conditions, il faut préférer une résection primaire dans certains cas choisis. Chimiothérapie locale ou par goutte-à-goutte intraveineux. Contrôle sévère de l'équilibre azoté et minéral.

Literature.

1) Bager, B.: Acta Chir. Scand. 1929, vol. 64, suppl. XI. — 2) Björkroth, T.: Nord. Med. 1942, 894. — 3) Björkroth, T.: Nord. Med. 1945, 860. — 4) Bohmansson, G.: Nord. Med. 1944, 2198. — 5) Brocq, P. and Aboulker, P.: La Presse Médicale 1937, I, 231. — 6) Bruusgaard, C.: Nord. Med. 1942. 2409. — 7) Dahle, M.: Nord. Med. 1942, 2410. — 8) Eliasson, E. L. and Ebeling, W. W.: Ann. J. Surg. 1934, 24, 63. — 9) Friedemann, M.: Zbl. f. Chir. 1933, 16, 934. — 10) Geisthövel, W.: Münch. Med. Wschr. 1939, 86, 566. — 11) Gelin, L.-E.: Svenska Läkartidn. 1945, 1483. — 12) Gibbon, J. H.: Ann. of Surg. 1930, II, 616. — 13) Graham, R. R.: Surg., Gyn. and Obst. 1937, 64, 235. — 14) Grevillius, A. and Cederlund, H.: Arch. f. klin. Chir. 1941, 202, 479. — 15) v. Haberer, H.: Münch. Med. Wschr. 1935, 82, 1473. — 16) Harstad, K.: Nord. Med. 1941, 2827. — 17) Honkanen, P.: Nord. Med. 1941, 1307. — 18) McCreery, J. A.: Ann. Surg. 1938, I, 315. — 19) Noetzel, W.: Deutsche Zschr. f. Chir. 1931, 234, 782. — 20) Norrlin, L.: Dissert. Uppsala 1915. — 21) Odelberg, A.: Acta Chir. Scand. 1927, 62. 157. — 22) Peters, K. O.: Der Chirurg 1931, 3, 166. — 23) Petrén, G.: Lunds universitets årsskrift 1911, VI, 1. — 24) Petrén, G.: Nord. Med. 1942, 315. — 25) Raw, S. C.: The Lancet

1944, 1. 246. — 26) Richter, S.: Nord. Med. 1944, 2194. — 27) Schilling, H.: Acta Chir. Scand. 1935, 76, 249. — 28) Shelley, H. J.: Am. J. of Surg. 1932, 55, 277. — 29) Slany, A.: Wiener klin. Woch. 1942, 55, 171. — 30) Strandell, G.: Nord. Med. 1944, 2194. — 31) Söderlund, G.: Sv. Läkartidn. 1926, 1169. — 32) Thompson, H. L.: J. Am. Med. Ass. 113, 23, 2015. — 33) Ulland, G.: Acta Chir. Scand. 1943, 89, 195. — 34) Wakeley, C. P. G.: The Lancet 1944, 50, 11. — 35) Yudine, S.: J. internat. de chir. 1939, II, 219. — 36) Zuchschwert, L. and Eck, T.: Deutsche Zschr. f. Chir. 1931, 232, 299.

From Vestfold Fylkessykehus, Surg. Dept.
(Chief Surgeon: N. PAUS, M D.)

Arthrosis in the Knee after Meniscectomy.

By

LORENTZ NITTER.

The anatomy and function of the meniscus have been studied in a number of investigations (ANDREESEN, BIRCHER, EFSKIND, MANDL, TOBLER and others). Some of the main features shall here be briefly summarized. The meniscus consists of cartilage pervaded by elastic fibres, which enable it to change its form and to act as a kind of buffer in the joint. After injuries and owing to the wear and tear of years constantly more and more of the elastic tissue is being destroyed. In adults the blood vessels from a marginal artery penetrate only into the peripheral parts, while the central portion contains no vessels. Here, as in the other vessels, arteriosclerosis, with consequent degenerative changes, arises in the course of time. Calcifications, which X-ray examination occasionally reveals in a damaged meniscus, are indicative of the same process. These changes are often present from the age of fifteen, and after the age of 35—40 years a normal meniscus is seldom found (TOBLER).

Regenerative changes may also appear together with the degenerative. According to several authors, total regeneration after meniscectomy is a constant observation in animals. Also in man it has been claimed that such regeneration could be noted, for instance, on X-ray examination, but proof thereof through post-mortem examination of a large number of meniscectomized persons has not been furnished (EFSKIND). At any rate, the regenerated meniscus will be, both morphologically and functionally, an inferior product, which may be the seat of renewed rupture (ANDREESEN). That is one of the reasons why most surgeons perform total meniscectomy. Of recent years some have gone in for

partial resection. WEISBACH, among about 500 partially meniscectomized patients, has only in one case seen rupture of the remaining part of the meniscus. LAGERGREN and UEBERMUTH likewise, recommend that, except where the operation reveals a more peripheral rupture, the paracapsular part of the meniscus should be allowed to remain, as this part is of the greatest importance for an eventual regeneration. According to the advocates of partial resection, such regeneration of the meniscus is extremely important for maintenance of normal static conditions in the joint, which should thereby be rendered less susceptible to secondary arthrosis.

As regards the possibilities for the healing of a damaged meniscus, it is found, as was to be expected, that such restitution occurs only in the peripheral parts, which are supplied with blood. Hemarthron occurring one or some few hours after the injury would seem to indicate good vascularisation of the meniscus (SJÖVALL), although in some of the cases the cause thereof must be sought for in bleeding from the capsule of the joint. Under such circumstances one ought at first to be rather cautious about proceeding to an operation (LAGERGREN). Absence of exudation in the joint is said to be typical of spontaneous rupture (ANDREESEN).

Owing to the anatomical conditions the medial meniscus is far more frequently injured than the lateral, as is also evident from the present material (the ratio being 10 : 1). The lateral meniscus is of more circular shape, the anterior and posterior attachments lie closer to each other and the meniscus is comparatively loosely connected to the capsule. It is therefore called the movable meniscus, in contrast to the medial, which is also styled the fixed meniscus. This latter is C-shaped, is closely connected with the capsule and thus has little capacity of movement. Moreover, on flexion of the knee the medial sideligament relaxes less, while the lateral relaxes far more, which also contributes to enabling the lateral meniscus to follow more easily an unphysiological movement (ANDREESEN). From its position at full extension to that at maximum flexion the meniscus moves at least 1 cm over the articular surface of the tibia (SJÖWALL). On flexion the meniscus is drawn backwards into the joint, which first grips its foremost attachment and stretches it. According as the flexion increases the meniscus becomes more and more curved, the central part being now especially affected. Through a simultaneous outward rotation the posterior part of medial meniscus will especially be stretched.

Through inward rotation the lateral meniscus is most affected and particularly its posterior part. Furthermore, the outward rotation, which affects the medial meniscus, in man is a physiological phenomenon, as is strongly emphasized by MANDL. Thus, on account of this change of form and this movement of the meniscus, the normal function entails no slight demand upon the tenacity of the meniscal tissue. Even on ordinary flexion and rotation of the knee the physiological strain is already great. It is then clear that the typical injury-producing force is an abnormal flexion or rotation. As a rule, it is a question of a combination of these movements in abnormal degree.

The meniscus consequently plays a very important rôle in the articular mechanism, and it is naturally to be expected that an injured meniscus with subsequent meniscectomy may lead to certain changes, and then in the first place to post-operative arthrosis. As regards the time at which this arthrosis develops and the causative factors that come into play many possibilities may be imagined.

In the first place, the germ of an arthrosis may be supposed to arise from the trauma that occasions injury to the meniscus, as well as from the irritation caused to the joint by the presence of a damaged meniscus in the time before its removal. Continuous symptoms of blockade, as well as intermittent dropsy, often due to a mild synovitis, may be imagined to lead to arthrosis, which perhaps is not discovered until several years after the operation. A demonstrable monocondylar arthrosis, corresponding to the tibial condyle of the damaged meniscus before the operation, must be taken as a proof that the disease had already arisen prior to the operative treatment. On the other hand, we cannot, of course, preclude the possibility that the preoperative course may have some significance, even when arthrotic changes are not observable until later. We will then, however, be inclined to think of the meniscectomy itself as the principal causal factor. That an arthrotomy alone could lead to arthrosis is, according to ROUX and LANGE, not improbable. But that it should be exclusively monocondylar cannot well be explained without taking into account the meniscectomy itself.

It then seems rather natural to seek for the cause in faulty loading of the joint owing to removal of a buffer, such as the meniscus represents, as well as in the wear and tear to which the cartilage covering the tibial condyle is thereby subjected. Also

in the present material there has on re-examination of patients been many times seen only a very small reduction in thickness of the cartilage at the former site of the meniscus, with slight projection on the opposite side. As this may be seen immediately after the operation, and also in our material has been observed in a couple of cases, it is certainly not to be taken as expression for an arthrosis with reduced thickness of cartilage, but rather for a lower joint-space on one side, with consequent faulty loading of the joint. The static changes which thereby arise in the joint may be regarded as factors predisposing to arthrosis. EFSKIND has also thought that in his material he could note a slight outward gliding of the femoral condyle and he sees in this a proof that the meniscus has functioned as a kind of brake. Thereby might also arise a chronic irritation, and when we consider the small excrescences on the edge of the tibial condyle this latter explanation especially seems to be rather natural. Such gliding we have not in our material been able to observe with certainty. Although the matter is thus not quite clear, we may probably regard the altered conditions of loading after menisectomy as the principal cause of the occurrence of arthrosis.

Own Material.

The purpose of this work was primarily to investigate the frequency of arthrosis after total menisectomy, which was the method adopted in our hospital. First there shall be given a brief account of the material as a whole. Altogether 42 patients — 33 men and 9 women — were operated in the period from 1923 to 1943. In more comprehensive statistics (MANDL) the ratio of men to women was found to be 4 : 1, which also accords very well with our figures. Three of the patients had office work, when the others were engaged in manual labour, which for the most part could be classified as heavy work. Altogether there were removed 38 medial and 4 lateral menisci, whereof 29 with an injury chiefly due to an indirect trauma, while in 12 cases it was extremely probable that a direct trauma existed. In one case no trauma could with certainty be reported. This patient at the date of operation was 52 years old, an age at which the degenerative changes in the meniscus are so pronounced that a quite insignificant injury, which may be not even noticed by the patient, is sufficient to produce rupture. Otherwise injuries due to sport are

predominant, 24 of the ruptures having occurred during the practice of one or other form of sport — in 9 cases football. As regards the diagnosis, which I shall not enter further into here, the compression symptom was the most constant, being noted in 37 of the cases.

Only a small incision was employed in the operation. In half of the cases total luxation of the meniscus was noted, sometimes with longitudinal rupture. In 12 cases the anterior and in 7 the posterior part of the meniscus was found to be loosened. In two cases the description of the operation is somewhat vague as regards the site of the injury.

The post-operative course was for the most part uncomplicated. One patient got hemarthron in such degree that puncture was found necessary. Post-operative hemarthron is said to predispose to arthrosis (Erskind). This patient after an observation period of 8 years has shown no signs in that direction. Two patients got temporary phlebitis. No serious complication in the joint arose after the operation. The patients were allowed to get up from 16 to 20 days after being operated. The post-operative treatment has not followed any definite line, but some of the patients were given massage.

Patients Re-examined.

Thirty-five of the patients presented themselves for re-examination. Owing to the existing circumstances it was not possible to call up the remaining seven, several of whom were outside the limits of the country. These 35 patients have all been subjected to very careful clinical examination with subsequent X-ray examination of both knees.

Distribution according to age and sex.

Age	10—20	21—30	31—40	41—50	51—60	
Men	5	15	4	2	1	27 men
Women	1	4	2	1	—	8 women

From these patients 32 medial and 3 lateral menisci were removed. Twenty-five of them were absolutely free from clinical symptoms and had no subjective troubles of any kind. Four patients had now and then had insignificant rheumatic pains, without being in any way hindered in their work, and were also at

the time of examination free from demonstrable symptoms. Thus 29 patients, or 83 per cent, showed either an ideal or a good result of the operation. Of the remaining six patients the result was medium good in four cases, while in two cases it must be regarded as bad.

A more detailed account of these 6 cases is given in the following table:

No.	Sex	Age	Time before operation	Observation time	Post-operative arthrosis	Symptoms
10	F.	26	1 year	1 year	Neg.	Disagreeable sensation when she mounts on a chair. Clinical examination: Negative findings.
13	F.	16	4 mths	3 years	Neg.	Cautious about twisting her leg. Clinical examination: Negative findings.
14	F.	28	4 mths	12 years	Neg.	Gets sooner tired in the operated leg. Clinical examination: Negative findings.
35	M.	26	1½ mths	19 years	Rather severe arthrosis	A little pain when carrying something heavy. Moderate swelling after somewhat severe exertion. Clinical examination: Negative findings.
18	M.	35	4 years	9 years	Rather severe arthrosis	Often swelling. Considerable inconvenience during work. Sick-pay from State Insurance Fund. Clinical examination: Negative findings.
28	M.	22	2 mths	6 years	Rather severe arthrosis	Constant swelling. Considerable inconvenience, especially during work. Clinical examination: 90° flexion. Lateral mobility 5°.

The first four patients were in full work. The last two, who suffered considerable inconvenience from the disease, had been only partly at work in the last few years. X-ray treatment had had a good deal of effect in these two cases.

Several authors, who have partly re-investigated their material by means of inquiry forms, attach great importance to crepitation as an indication of arthrosis. Even though we must judge the roentgenological changes with discrimination, we will undoubtedly get too low a figure by paying too one-sided attention to crepitation. This symptom was found in only 3 of the 12 patients with

arthrosis (Nos. 5, 18 and 23). In one of the 23 with negative roentgenogram, who was otherwise quite symptomfree, this symptom was present. It is true that the first stages of arthrosis cannot be observed on the X-ray picture, but on the whole the roentgenological investigation yields far more information in a subsequent re-examination of meniscectomized patients.

In our material no signs of arthrosis were found before the operation in any of the patients. On the other hand, twelve of them showed on X-ray examination undoubted post-operative changes. (See the case-histories of these patients.) In 11 of the cases the changes were of typical monocondylar and monoarticular nature, so that on inspecting both knees it could easily be seen which meniscus had been removed. In one case the changes were bilateral, symmetrically localized to the medial tibial condyle (No. 30). When the operation on the right knee was performed this patient was 52 years old and the roentgenogram was then negative. On re-examination 14 years later there were found excrescences on the medial tibial condyle on both sides. In the last three years before the re-examination he had shown marked symptoms of meniscal luxation in the other knee, whereas the operated knee had been quite free from symptoms. His arthrosis must then be regarded as physiological for his age, 66 years, or possibly as a post-operative arthrosis on the right side and as the result of injury to the meniscus on the left side. Moreover, the X-ray treatment of the left knee had been quite ineffective. As he had reached the age of 52 years without getting arthrosis on either side, he will, for the sake of clearness, be assigned to the group with post-operative arthrosis, even though the case is doubtful.

The frequency of arthrosis is thus about 34 per cent. For comparison it may be mentioned that BRECHLING found 17.5 per cent, KEY and STRÖMBERG 25 per cent, with about the same degree of total restitution.

A comparison between these 12 and the 23 who showed no changes may be of some interest as regards the causative correlation of the arthroses.

	Neg. roentgenogram	Arthrosis
Average time before operation	2.1 years	2.4 years
» age at »	29 »	26.7 »
» observation time	5 »	10.1 »
» age at re-examination	34 »	36.8 »

Although the number of patients is unfortunately small, it is clearly to be seen from the table that the observation time plays a decisive rôle, seeing that it is twice as long for patients with arthrosis as for those without. Still more evident will be its importance if the material is examined exclusively with a view to this factor:

Observation time	1—5 years	6—10 years	11—15 years	Over 15 years
Total number of patients	16	11	6	2
Patients with neg. findings ..	15	6	2	0
Patients with arthrosis	1	5	4	2

It is seen that the frequency of arthrosis rises steadily with increasing time of observation. For one of the patients with roentgenological changes the observation time was only $1^1/_2$ years, for the others it was over 6 years. In view of the fact that the average observation period for patients without arthrosis was 5 years we can accordingly not expect to find changes before 7 or 8 years after the operation. With increasing observation time it is probable that constantly more patients will show roentgenological changes, although the increase will no doubt be far less marked than here, where the numbers are too small.

Especially in view of the danger of arthrosis, it is generally believed that the operation should take place as soon as the diagnosis is established with all probability. The average time before the operation is somewhat shorter for the negative group, and moreover for the two patients in this group who had an observation period of more than 10 years (namely 12 and 13 years) the illness had lasted only 3 and 4 months respectively before operation. Meanwhile, some of the patients with postoperative arthrosis had had their knee-trouble for a shorter time before the operation, so that the difference here is not of decisive significance. The age at the time of operation is, if anything, somewhat lower for the group with arthrosis. The supposition that the frequency of arthrosis should be influenced by the somewhat higher age of the patient at the time of re-examination is disproved by the following table, from which it is seen that arthrosis was found in only about 33 per cent of the patients over 40 years old, being thus no more frequent than in the rest of the material.

Age	10—20	21—30	31—40	41—50	51—60	61—70
Patients with neg. findings	2	10	5	5	1	—
Patients with arthrosis	—	3	6	2	—	1

Accordingly it must be deemed probable that it is primarily the operation itself with the consequent static changes that leads to the roentgenological signs of arthrosis and that these will be noted in a constantly increasing number of cases according as the observation time becomes longer.

Patients with post-operative arthrosis.

(All are men, except No. 29)

No.	Age at operation	Time before operation	Observation period	Clinical result	Roentgenological signs of arthrosis
1	20	4 years	1½ years	Ideal	Slight degree.
23	22	3 years	7 years	Ideal	Slight degree. Reduced thickness of cartilage (1 mm).
27	31	4 mths	7 years	Ideal	Slight degree.
5	24	1½ years	11 years	Good	Slight degree.
29	22	4 years	11 years	Ideal	Slight degree. Reduced thickness of cartilage (1 mm).
33	22	1½ years	11 years	Ideal	Slight degree. (Neg. roentgenogram 6 years after operation). Reduced thickness of cartilage (1 mm).
30	52	5 years	14 years	Ideal	Slight degree.
34	19	2 years	18 years	Ideal	Slight degree. Reduced thickness of cartilage (1 mm).
28	22	2 mths	6 years	Bad	Greater degree. Reduced thickness of cartilage (4 mm).
9	26	4 years	7 years	Ideal	Greater degree. Reduced thickness of cartilage (1 mm).
18	35	4 years	9 years	Bad	Greater degree. Further progression in 1945. Reduced thickness of cartilage (2 mm).
35	26	1½ mths	19 years	Medium	Greater degree. Reduced thickness of cartilage (2 mm).

Since, as already mentioned, the changes observed must be judged with caution, it is natural to investigate what importance

they have from a purely clinical standpoint. Of the twelve patients with undoubtedly positive roentgenological findings only three had knee-trouble. In all three of them the roentgenological changes were more marked and two of these belonged to the group with bad clinical results. Among the 23 with negative roentgenogram three had some very slight discomfort, but without influence on their ability to work. Even though the material is small, it is thus sufficient to show that the post-operative arthrosis affects the powers of restitution. It is true that in several patients the changes noted in the roentgenogram were very slight, but it must be presumed that in most cases they are progressive. Two of the patients, on being incidentally examined apart from the regular re-examination, also gave clear evidence of this.

In order to arrive at a fuller understanding of the importance of the post-operative arthrosis for the final result a continued control examination of a larger body of material would be of interest for the purpose of observing the further development when the roentgenological changes have existed for some years longer or when fresh alterations may have arisen in patients who previously had a negative roentgenogram. There is good reason to suppose that we would then come to the conclusion that the danger of arthrosis must be taken into account. This would perhaps lead to partial resection coming more into consideration in view of the consequent maintenance of the normal static conditions in the joint.

Summary.

After a survey of the anatomy and functions of the meniscus the various causes of post-operative arthrosis are discussed. Special attention is paid to the altered static conditions in the joint after menisectomy.

Thirty-five patients on whom total menisectomy had been performed were clinically and roentgenologically re-examined. Eighty-three per cent showed an ideal or at least a good result on clinical examination. The longest observation period was 19 years. Twelve of the patients showed roentgenological signs of post-operative arthrosis. According as the observation time is extended more and more patients show roentgenological changes, and in clinical respects these patients give worse results. A continued control examination of a larger body of material would be of interest in order to show the development when the arthro-

sis has existed for some years longer or when new cases of the disease have arisen. There is good reason to assume that this would lead to the conclusion that the danger of arthrosis must be taken into consideration. This might possibly result in more general adoption of partial resection, whereby the normal static conditions in the joint may be maintained.

Zusammenfassung.

Nach einer Übersicht über die Anatomie und Funktion des Meniscus werden die verschiedenen Ursachen zur postoperativen Arthrose besprochen. Besonderes Gewicht wird auf die veränderten statischen Verhältnisse im Gelenk nach einer Meniscektomie gelegt.

35 Patienten, bei denen eine Totalmeniscektomie vorgenommen ist, wurden klinisch und röntgenologisch nachuntersucht. 83 % zeigten klinisch ein ideelles beziehungsweise gutes Resultat. Die längste Beobachtungszeit war 19 Jahre. Bei 12 der Patienten zeigten sich röntgenologische Zeichen von postoperativer Arthrose. Bei verlängerter Beobachtungszeit werden röntgenologische Veränderungen bei ständig mehr Patienten gefunden, und auch rein klinisch ist das Ergebnis bei diesen schlechter. Fortgesetzte Kontrolle eines grösseren Materials wird von Interesse sein, um die Entwicklung zu sehen, wenn die nachgewiesenen Arthrosen noch einige Jahre weiter bestanden haben und evtl. neue hinzugekommen sind. Viel spricht dann dafür, dass man mehr mit der Arthrosengefahr rechnen muss. Möglicherweise wird es dazu führen, dass die partielle Resektion durch ihre Aufrechthaltung der normalen statischen Verhältnisse im Gelenk mehr in den Vordergrund treten wird.

Résumé.

Après un aperçu sur l'anatomie du ménisque et sa fonction, les différentes causes de l'arthrose postopérative sont mises en discussion. Des considérations spéciales sont faites sur le changement des conditions statiques de l'articulation après la résection du ménisque.

35 malades chez lesquels a été effectuée une résection totale du ménisque ont été objet d'examens cliniques et radiographiques espacés dans le temps. Dans 83 % des cas on constate à l'observation clinique un résultat excellent ou bon. La plus longue période

d'observation postopérative était de 19 ans. Chez 12 malades on a constaté des tâches radiographiques d'arthrose postopérative. En prolongeant la période d'observation on constate des changements radiographiques chez un nombre toujours croissant de malades. Même à l'examen simplement clinique on constate chez ces malades des résultats plus mauvais. Un contrôle continué d'un matérial plus copieux aurait intérêt pour suivre l'évolution quand les arthroses constatées ont duré encore quelques années et éventuellement des nouvelles s'y sont ajoutées. Il y a alors bien raison de croire que l'on parvienne à ce résultat: qu'il faut compter davantage avec le danger de l'arthrose. Il est possible que cela conduise à une plus grande actualité de la résection partielle qui permet le maintien des conditions statiques normales dans l'articulation.

References.[1]

ANDREESEN, R.: Ergeb. der Chir. & Orthopäd. 30: 24. 1938. — BRECHLING, SV.: Ugeskrift for Læger. 16: 426, 1942. — EFSKIND, L.: Acta Chir. Scand. 82: 499. 1939. — LAGERGREN, K.: Acta Orthopaed. 14: 280. 1943. — SJÖVALL, H.: Acta Orthopaed. 13: 153. 1942. — SOMMER, R.: Ergeb. der Chir. & Orthopäd. 22: 387. 1930. — UEBERMUTH, H.: Der Chirurg. 13: 329. 1941. — WEISBACH, K.: Der Chirurg. 7: 207. 1942.

[1] Complete bibliography prior to 1938: ANDREESEN and SOMMER.

From the County Hospital at Hudiksvall.
(Physician-in-Chief: KNUT HALLBERG.)

Unilateral Double Ureter with Partly Vaginal, Partly Normal Outlet.

Report of a Case.

By

PER OLOF ALMQUIST, M. D.

During the summer of 1943, a case of two ureters on the left side, one of which issued into the vagina, was treated at the County Hospital of Hudiksvall. This type of malformation is rare. Since only a couple of cases have been described in the Scandinavian literature, a detailed report of this case seems justified, particularly in view of the fact that treatment differed from that generally adopted.

The patient was a woman, 29 years of age. Her family history was irrelevant. Apart from the troubles which caused her admission on July 1st 1943 (Record No. 1808/43), she had previously been in good health. She had six children and her deliveries had all been free from complications. The immediate reason for her application was intermittent attacks of pain on the left side of the abdomen during the past three years. The pain had invariably been felt after exertion and lasted for approximately 10 minutes. These attacks were not accompanied by fever. *However, the patient admitted that she had had partial urinary incontinence for as long as she could remember.* During the day she usually urinated about once an hour and her underclothing was always damp. For the same reason, she had been compelled to wear a sanitary towel at night. She had to have a chamber-pot ready at hand whenever she got out of bed. However, she had become so accustomed to this condition that she had never considered consulting a physician. She had not noticed that some of the urine came from the vagina. Menstruation had been normal.

General condition: The general examination did not reveal anything of interest. At a *vaginal examination,* a slight quantity of fluid resembling urine was found in the vagina, the mucous membrane of which was

somewhat inflamed, but otherwise without any visible changes. In the anterior vaginal wall and a little to the left of the median line, a narrow fold, approximately 3 cm. long, was observed issuing from the anterior fornix in a distal direction. It slightly resembled the ureteral torus of the mucous membrane of the bladder. A small opening was found in the middle of it, from which a fine liquid jet rhythmically appeared. A ureteral catheter could be introduced 4 cm. Otherwise the genitalia showed nothing of note. The urinary test from the bladder and that from the vagina were also without interest.

In order to preclude the possibility of a vesico-vaginal fistula, the urinary bladder was filled with a methyl blue solution. No blue staining of the urine in the vagina was obtained.

At *cystoscopy*, the ureteral ostia were found to be normal and symmetrically arranged. The mucous membrane of the bladder showed nothing of interest. A compress was inserted into the vagina, whereupon 2 ml. of an indigo-carmine solution were injected intravenously. After 12 minutes, blue urine was obtained from the right ureteral outlet and, after 15 minutes, from the left one also. After the 15-minute period, the compress in the vagina was removed. It was also found to be stained a blue colour in the small part which had been close to the above-mentioned outlet into the vagina. Ureteral catheters were easily introduced 30 cm. on both sides from the bladder.

At *roentgen examination* (Figs. 1 and 2), *twice ureters were found on the left side, one of them issuing into the vagina*. Both the *kidneys* were of normal shape, size, and position. No concretions were observable in the urinary tract. *Intravenous pyelography:* On the *right* side excretion took place at a normal time. The renal pelvis seemed to be divided into two parts, viz. a superior one comprising the upper calyx and an inferior one the other calices. There was only a very narrow communication between these parts. On the *left* side, excretion did not take place until after 15 minutes. A double renal pelvis was found, the superior part including the upper calyx and the inferior part the other calices. The first-mentioned one was shaped like a calyx and was fairly large and awkward. The inferior one was of normal shape. The ureter from the superior renal pelvis could be followed to the apex of the transverse process of the fourth lumbar vertebra, while the ureter from the inferior pelvis could be observed during its whole course to the bladder. Both were of normal width. *Left-sided retrograde pyelography.* Only the inferior renal pelvis could be filled after the injection of contrast from the bladder. A fine ureteral catheter was introduced simultaneously into the vagina through the ostium. It could be inserted only 4 cm. Five ml. of a 25-percent solution of lithium iodide was injected through the catheter. In this way satisfactory filling of the superior renal pelvis also was obtained, of the same appearance as at intravenous pyelography. Moreover, the ureter leading to the superior renal pelvis could also be filled in its entire course. It was of normal width and ran close along the medial side of the ureter of the inferior renal pelvis up to the apex of the fourth lumbar vertebra. Here it crossed the ureter of the inferior renal pelvis, and

could then be followed lateral to this ureter to the inferior region of the sacro-iliac joint. After this, the two ureters again crossed one another.

Thus, a double renal pelvis and a double ureter were present on the left side. The ureter of the superior renal pelvis issued into the vagina while the inferior ureter issued normally in the bladder. The function of the right kidney was good, while that of the left kidney was slightly reduced. *No infection in the urinary tract was detected.* The surgical choices were as follows: 1) Implantation of the extravesical ureter in the bladder, 2) hemi-nephrectomy or nephrectomy, 3) simple ligation of the ureter issuing into the vagina. Since no urinary tract infection set in, the last-mentioned procedure was chosen as being the easiest one.

Operation was performed on July 11th, 1913 (HALLBERG/ALMQUIST) under spinal anaesthesia with nupercaine. Prior to operation, a ureteral catheter was introduced on the left side through the bladder towards the inferior renal pelvis. Left-sided kidney incision was done. When the peritoneum had been detached anteriorly, the two ureters could be distinctly observed lying next to each other. One of them contained the ureteral catheter, which could be clearly palpated. The fat capsule of the kidney was dissected and the ureter with the catheter was followed upwards to the inferior renal pelvis. The other ureter, which was of significance in this connection, could also be followed in the same way to its renal pelvis. The size and shape of the kidney were normal, and no lobation was noticeable. However, a groove was noted at palpation at the border between the upper and middle third part of the kidney. The ureter situated close to the kidney and lying in a medial direction (to the superior renal pelvis) was ligated about 7 cm, below its pelvis, partly with catgut and partly with silk thread. The fat capsule was replaced over the kidney. A tube was inserted in the event of a temporary hemorrhage and the renal incision was closed by stages per primam.

The convalescence was complicated by a mild infection of the urinary tract (rods), which rapidly disappeared after sulfathiazole medication. From the moment of surgical intervention, the urinary flow into the vagina ceased. The patient was discharged completely free from trouble 19 days after the operation. *It is noteworthy that the patient did not feel any tension or pain in the left renal region in the postoperative phase.* Cystoscopy, performed a day or two before discharge, revealed at a simultaneous indigo-carmine test the penetration of blue-coloured urine from the right as well as the left ureteral orifice after 8 minutes. At intravenous urography, normal excretory conditions were also obtained. However, in the left superior renal pelvis no excretion could be observed after as long a time as 30 minutes. Two years after the operation the patient still remained free from symptoms.

A ureter with an extravesical outlet is an exceedingly rare occurrence. Isolated cases have been described in the older literature in this field. The first compilation was made by J. P. HARTMAN (5) in 1913 concerning the 37 cases so far established.

Since then the number of cases described in the literature has increased rapidly. In the year 1922, FURNISS (3) found a total number of 51 cases, in 1926 KILBANE (4) collected 100 cases, and in 1928 THOM (4) reported 185, and finally FURNISS (4) had altogether 240 cases in the year 1937.

THOM, whose material has been the most adequately analysed, had 63 men and 117 women in his series of 185 cases. In five instances, the sex was not specified. The cases were almost equally distributed between the right and the left side. In the men, the extravesical ureter issued into

pars prostatica urethrae	in	33	cases
seminal vesicle	»	17	»
vas deferens	»	6	»
ejaculatory duct	»	5	»

In the women it issued into

vestibule of the vagina	»	45	»
urethra	»	37	»
vagina	»	32	»
uterus	»	3	»

In THOM's series of 185 cases

single ureters with an extravesical outlet of one of them occurred	in	58	cases
single ureters with an extravesical outlet of both occurred	»	6	»
unilateral twice ureter with an extravesical outlet of one of them occurred	»	96	»
unilateral twice ureters with an extravesical outlet of both occurred	»	2	»
bilateral twice ureters with an extravesical outlet of only one of them occurred	»	21	»
bilateral twice ureters with an extravesical outlet of all of them occurred	»	2	»

In women, the main symptom generally consists of incontinence since birth, while in men this symptom is usually lacking. Accordingly, cases without symptoms, which are therefore not diagnosed, are no doubt considerably more frequent among men than among women. This should, at any rate, partially account for the preponderance of women in THOM's series. In addition, the occurrence

Fig. 1. Left-sided double renal pelvis and double ureter.

Fig. 2. The ureter of the superior renal pelvis issues into the vagina, where the catheter is held with forceps, visible in the roentgenogram.

of pyuria is sometimes reported without any satisfactory explanation; the same applies to an increase in temperature without local signs and to pains in the renal region.

The diagnosis is, as a rule, arrived at by means of inspection, as well as by intravenous and retrograde pyelography. However, during the course of the latter proceedures, the injection of contrast fluid may entail fairly great difficulties. It may, even at times, be hard to detect the extravesical orifice of the ureter.

The position of the ureteral ostia in relation to one another appears to be constant. Thus, the orifice of the ureter from the cephalic part of the kidney has the more caudal position, while the ostium of the ureter from the caudal part has the more normal location. When the ureteral orifice is located in the urethra, it always has a dorsal position, and when in the vagina, it always lies in the anterior wall.

Before treatment, the following questions should, if possible, be decided: How great a part of the kidney is drained by the extravesical ureter? What is the functioning capacity of the two kidneys as well as of both parts of the kidney with twice ureters? Is the ureter with an extravesical outlet dilated? Is an infection of the urinary tract present?

In the cases mentioned herein, the following surgical interventions have been employed:

1. *Implantation* of the ureter in the bladder, either from the vagina or from the abdomen — both intra- and extraperitoneally — has been the operative proceedure most commonly adopted. The operation has, as a rule, been technically successful. Cystopyelitis has been a usual complication of this operation. In the majority of the cases subjected to after-examination, the new ostium has been found to be constricted and out of function. Therefore, the result of the operation has no doubt, in the majority of cases, been hydronephrosis of the part of the kidney drained by the extravesical ureter. — A somewhat better result seems to have been achieved by the application of an anastomosis between the dilated ureter and the bladder, performed either from the latter organ or from the vagina, with ligation of the distal part of the ureter.

2. *Anastomosis* between the inferior part of the superior renal pelvis and the superior part of the inferior renal pelvis with ligation of the ureter, has been done only once (STAMMLER, 1). Apart from the special anatomic conditions required for the suc-

cess of this intervention, it is essential that no infection is present. This case was not, apparently, submitted to after-examination. Accordingly, the result cannot be judged.

3. *Resection* of the part of the kidney drained by the ureter with an extravesical outlet is strongly recommended by a number of workers (FURNISS, 4, and others). Simultaneous ureterectomy is unnecessary. The operation is considered rarely to offer any very marked technical obstacles. However, nephrectomy may have to be resorted to on account of technical difficulties, in which case it should be used as a last recourse and only, of course, when the other kidney is absolutely healthy. This is a prerequisite also in the event of heminephrectomy. The result appears to have been favourable, with the exception of one case (HUNNER, 4) where the remaining part of the kidney ceased to function after heminephrectomy.

4. *Ligation* of the ureter has only been performed in a few cases. The prerequisite of this intervention is that the urine be free from infection. The ligation should be carried out with silk or some other non-absorbable material. In order to prevent the occurrence of a dilated hydro-ureter, the ligation should be made high up. In one instance (NOVÉ-JOSSERAND, 2), where the ureter was ligated only with catgut, the urinary flow was resumed after five days. Nephrectomy was then performed. In the other cases, the result was satisfactory. Restricted hydronephrosis of part of the kidney concerned followed.

Thus, there are several surgical methods to choose from in every individual case. When an uninfected case is concerned, simple ligation of the ureter is advised. Implantation of the ureter in the bladder is a considerably more extensive intervention but the result, viz. hydronephrosis, no doubt usually occurs with both these surgical methods. Accordingly, the former method is to be preferred. However, when the only ureter on one side has an extravesical outlet and normal kidney is present on the other side, implantation of the ureter in the bladder should be attempted. Further, when a comparatively large part of the kidney is drained by the extravesical ureter, a fairly rare occurrence, a large, localized hydronephrosis appears. In such cases and when urinary tract infection is present, heminephrectomy or, possibly, nephrectomy may be taken into consideration, provided function of the kidney on the opposite side is good.

Summary.

A report is given of a case of a double renal pelvis and a double ureter on the left side in a 29-year-old sexipara. The ureter of the superior renal pelvis issued into the vagina. The principal symptom was partial urinary incontinence since birth. At the operation, only ligation of the ureter was performed with both catgut and silk. The convalescence was, on the whole, uneventful. At an examination two years after the intervention, the patient was still free from trouble. Some series of cases of ureters with an extravesical outlet have been reported from the literature. The treatment is discussed. The conclusion is drawn, chiefly from a study of the literature, that, as a rule, ligation of the ureter with silk should be performed in uninfected cases. When the only ureter on one side has an extravesical outlet, implantation of the ureter in the bladder should be attempted. When a comparatively large part of the kidney is drained by the extravesical ureter, a fairly rare occurrence, and also in infected cases, heminephrectomy or, possibly, nephrectomy should be taken into consideration.

Zusammenfassung.

Der Bericht bezieht sich auf einen Fall mit doppeltem Nierenbecken und Ureter auf der linken Seite, wobei der Ureter des oberen Nierenbeckens in die Vagina mündete, und zwar bei einer 29-jährigen Frau mit 6 Kindern. Das Hauptsymptom war partielle Urininkontinenz seit der Geburt. Bei der Operation wurde nur die Abbindung des Ureters ausgeführt, und zwar teils mit Katgut teils mit Seide. Der spätere Verlauf war im grossen und ganzen komplikationsfrei, und bei einer Untersuchung 2 Jahre nach der Operation hatte die Patientin immer noch keine Beschwerden. Es werden einige Zusammenstellungen aus der Literatur über extravesikal mündende Ureteren gegeben. Die Behandlung wird ausführlicher diskutiert und der Verfasser kommt zur Schlussfolgerung, die sich hauptsächlich auf Literaturstudien basiert, dass bei nicht infektierten Fällen gewöhnlich die Abbindung des Ureters mittels Seide vorgenommen werden soll. Wenn der einzige Ureter auf der einen Seite extravesical mündet, muss Implantation des Ureters in die Blase versucht werden. Sollte ein relativ grosser Teil der Niere von dem extravesikalen Ureter drainiert werden,

was gewöhnlich nicht der Fall ist, und wenn infizierte Fälle vorliegen, muss Heminephrektomie oder evtl. Nephrektomie in Frage kommen.

Résumé.

L'auteur décrit un cas de double bassinet et d'uretère double du côté gauche chez une femme âgée de 29 ans et ayant six enfants. L'uretère du bassinet gauche débouchait dans le vagin. Le symptôme principal était une incontinence d'urine partielle depuis l'enfance. Lors de l'opération, on s'est borné à pratiquer la ligature double de l'uretère supérieur au catgut et à la soie. Les suites ont été normales et un nouvel examen pratiqué au bout de 2 ans n'a révélé aucun trouble. L'auteur rapporte en outre certains cas empruntés à la littérature concernant des uretères à débouché extra-vésical. Il discute en détail le traitement et — en se basant essentiellement sur la littérature relative au sujet — il arrive à la conclusion que dans les cas où il n'y a pas d'infection il faut, en règle générale, pratiquer la ligature de l'uretère à la soie. Lorsqu'il n'existe d'un côté qu'un seul uretère à débouché extra-vésical, il faut essayer l'implantation de l'uretère sur la vessie. Dans les cas où l'uretère à débouché extra-vésical dessert une portion importante du rein — ce qui est rare — et s'il existe une infection, il faudra envisager l'héminéphrectomie ou éventuellement la néphrectomie.

Literature.

Adrian, V. Lichtenberg, Ztschr. f. Urol. Chir. 1913. — 1. Albert, René, Über vollständige Ureterverdoppelung beiderseits. Berlin 1926. — Baum, P., Arch. f. Gynäk. Berlin 1892. — Engström, O., Finska Läkarsällskapets handlingar Bd. 59, 1917. — 2. Franco, Primo B., La Duplicité Uréterale envisagée au point de vue patologique et chirurgicale. Paris 1922. — 3. Furniss, H. Dawson, The Journ. of Urol. vol. 7, 1922. — 4. Furniss, H. Dawson, The Journ. of Urol. vol. 37, 1937. — 5. Hartmann, J. P., Ztschr. f. Urol. 1913. — Hayward, The Journ. of the Am. Med. Ass. vol. 79, 1922. — Judd, E. S., Surg., Gynec. and Obstetric vol. 27, 1918. — Pallin, Gustaf, Nord. Med. Ark., vol. 50, 1917. — Sachs, Ztschr. f. Geburtshülfe und Gynäk. vol. 89, 1925. — Samuel, Kern, Sachs, Surg., Gynec. and Obstetric, vol. 35, 1922.

Aus der chirurgischen Abteilung des Seraphimerlazaretts in Stockholm.
(Vorstand: Prof. G. SÖDERLUND.)

Die Senkungsreaktion beim Hypernephrom.

Erfahrungen von 109 operierten Fällen.

Von

THORE OLOVSON.

Dass das Hypernephrom zu derjenigen Gruppe von Krankheiten gehört, bei welchen man die extrem hohen SR-Werte findet, ist ja allgemein bekannt. Werte über 100 mm, bis gegen 150 mm, sind nicht allzu selten. Diese Erkenntnis hat sich dem ärztlichen Bewusstsein in so weitem Umfang eingeprägt, dass das Hypernephrom wohl diejenige Affektion ist, an welche man bei Fällen mit hoher SR und sonst unklaren Erscheinungen gern zuerst denkt. Dieser Umstand, dass die SR beim Hypernephrom äusserst hohe Werte liefern kann, scheint die allgemeine Anschauung in der Richtung beeinflusst zu haben, dass das Hypernephrom so gut wie immer mit einer mehr oder minder stark erhöhten SR einhergehe. Tatsächlich kann aber beim Hypernephrom die SR niedrig oder sogar normal sein. Dies wissen wir u. a. durch einige der einschlägigen schwedischen Arbeiten aus den letzten Jahren. Offenbar sind die niedrigen SR-Werte nichts ganz Ungewöhnliches. Ich halte die Kenntnis hiervon für so wichtig, dass ich etliche bereits bekannte Untersuchungen auf diesem Gebiete anführen und über eine eigene Zusammenstellung berichten möchte. Die wesentliche Veranlassung hierzu waren zwei Fälle, die wir vor kurzem in der hiesigen Abteilung unmittelbar nacheinander operiert haben. Bei beiden waren die SR-Werte normal: bei dem einen 4, bei dem anderen 6 mm.

Ausländische Untersuchungen über die SR beim Hypernephrom sind recht dünn gesät. Nach DAMM (1931) ist die SR stets erhöht. SMIRNOFF (1928) gibt an, dass normale Werte vorkommen können. Die schwedischen Untersuchungen über die SR beim Hyper-

nephrom, welche ich gefunden habe, sind in Arbeiten von LJUNGGREN (1930), BERGENDAHL (1935), HELLSTRÖM (1943) und S. JOHNSSON (1945) veröffentlicht. LJUNGGREN gibt die SR bei 5 Fällen an. Bei einem derselben war der Wert 22 mm, bei den übrigen 52, 70, 87 und 156 mm. Bei BERGENDAHL findet man Angaben über 14 Fälle; bei einem von diesen war der Wert 15, bei einem anderen 20 mm. Die restlichen 12 hatten Werte zwischen 39 und 158 mm. HELLSTRÖM berichtet über die SR bei 22 Fällen. Von diesen hatten 3 normale Werte. Bei 6 Fällen lag die SR über 100 mm. In dem Material von Lund war nach JOHNSSON bei 83 operativ verifizierten Nierengeschwülsten (Art der Tumoren nicht näher angegeben) die SR bei 10 Fällen normal.

Die von mir zusammengestellte Reihe enthält 109 operierte, pathologisch-anatomisch bestätigte Hypernephromfälle. Zu diesen Fällen gehören neben denjenigen aus dem Seraphimerlazarett (41 Fälle) noch diejenigen aus dem St.-Göran-Krankenhaus (40 Fälle) sowie aus dem Krankenhaus Sabbatsberg (28 Fälle).

Tabelle 1.

SR bei 109 Fällen von Hypernephrom.

Normalwerte	20	(18,3 ± 3,7 %)			
Normalwerte—20	14		34	(31,2 ± 4,4 %)	
21—30	12		21		65 (60 ± 4,7 %)
31—40	9				
41—50	10		22		
51—60	12				
61—70	2		5		
71—80	3				
81—90	6		10	27	
91—100	4				
101—110	2		10		44 (40 ± 4,7 %)
111—120	8				
121—130	3		4	17	
131—140	1				
141—150	1		3		
151—160	2				

In Tabelle 1 findet man das ganze Material. Was die Normalwerte anlangt, so habe ich nach REICHEL die obere Grenze für Männer bei 10, für Frauen bei 13 mm gezogen. Aus der Tabelle geht hervor, dass unter diesen 109 Fällen die SR bei 20 Fällen normal war, d. i. ein Prozentsatz von 18,3 ± 3,7 %. Bei 14 Fällen lagen die Werte zwischen der Norm und 20 mm. Nehmen wir 20 mm als obere Grenze für eine sehr niedrige SR, so kommen

nicht weniger als 34 Fälle, d. s. 31,2 ± 4,4 %, in diese Gruppe. In bezug auf die sonstige Verteilung finden wir, dass die Anzahl der Fälle in Richtung auf sehr hohe und höchste Werte abnimmt. Wenn man 50 und 100 mm als Gruppengrenzen festsetzt, dann ergibt sich: 65 Fälle unter 50 mm, 27 Fälle zwischen 50 und 100 und 17 Fälle über 100 mm. Wird die obere Grenze für eine mässige Erhöhung der SR bei 50 mm gezogen, so finden wir 65 Fälle (60 ± 4,7 %) darunter und 44 Fälle (40 ± 4,7 %) darüber. Bemerkenswert ist, dass Fälle mit normaler SR zahlreicher sind als solche mit extrem hoher, d. h. über 100 mm.

Bei der weiteren Analyse der SR bei diesen Geschwülsten richtet sich die Aufmerksamkeit dann zunächst auf die Beziehung zur *Grösse*. In dem vorliegenden Material ist diese in den meisten Fällen durch das Gewicht des Operationspräparats, Niere + Tumor, gekennzeichnet, oder durch schätzungsweisen Vergleich.

Tabelle 2 a.

Beziehung zwischen SR und Grösse (Gewicht).

Niedrige SR und Gewicht.

Fall Nr	SR	Grösse
43	2	675 g
64	2	380 »
39	3	Apfelsinengross
31	4	Reichl. faustgross
7	4	Faustgross
4	8	Kindskopfgross
56	9	360 g
44	12	610 »
65	12	1200 »
99	14	Faustgross
3	15	Kindskopfgross
59	16	750 g
47	17	910 »
52	18	950 »
20	20	Mannskopfgross
58	23	1200 g
79	25	1500 »
105	25	1700 »

Aus Tabelle 2 a wird das Verhalten von Grösse oder Gewicht bei einer Anzahl von Fällen (18) mit *niedriger* SR ersichtlich. Man bemerkt hier Tumoren von bis 1200 g mit normaler SR. Bei drei Geschwülsten mit dem Gewicht 750, 910 und 950 g waren die SR-Werte 16 bzw. 17 und 18 mm. Bei zwei Tumoren von 1500 bzw. 1700 g war der Wert der gleiche, 25 mm.

Tabelle 2 b.

Beziehung zwischen SR und Grösse (Gewicht).
Hohe SR und Grösse.

Fall Nr	SR	Grösse
6	112	Doppelt faustgross
30	114	Hühnereigross
8	120	Faustgross
46	126	550 g
51	120	550 »
109	130	Apfelgross
27	155	Doppelt faustgross
1	157	Faustgross
48	102	1400 g

In Tabelle 2 b sind etliche Fälle mit *extrem hoher* SR zusammengestellt. Mit Ausnahme eines Falles (Fall 48) sind die Dimensionen der Tumoren durchweg kleiner als in der vorigen Tabelle.

Tabelle 2 c.

Beziehung zwischen SR und Grösse (Gewicht).
SR bei sehr grossen Tumoren.

Fall Nr	SR	Gewicht
105	25	1700 g
79	25	1500 »
71	148	1800 »
65	12	1200 »
63	60	1100 »
58	23	1200 »
48	102	1400 »
50	25	1155 »
53	74	1450 »

Tabelle 2 c gibt Aufschluss über die SR bei einer Reihe der grössten Geschwülste, d. h. bei solchen mit einem Gewicht über 1000 g. Wie man sieht, sind es von diesen 9 Fällen nur 2, welche eine SR über 100 mm haben. Bei den übrigen Fällen war die SR niedrig oder mässig erhöht.

Unter den kleinsten Tumoren, welche das Material enthält, finden sich 4 von Mandarinengrösse. Die SR-Werte waren bei diesen 41, 54, 55 und 42 mm; mithin bei keinem Falle eine niedrige SR.

Zusammenfassend ist über die Beziehung der SR zur Tumorgrösse zu sagen, dass keine direkte Proportion besteht. Der Sachverhalt erscheint vielmehr in dem Sinne deutbar, dass bei sehr grossen Geschwülsten die SR oft relativ niedrig ist. Bei Tumoren von bis 1200 g kann die SR normal sein.

Das Ergebnis dieses Vergleichs ist der bestimmte Eindruck, dass der Faktor, das Agens, welches die SR bedingt, nicht an quantitative Eigenschaften des Tumors gebunden ist, sondern in der Sonderart des letzteren seinen Grund hat. Wahrscheinlich spielen wohl Zerfallsvorgänge in der Geschwulst eine gewisse Rolle.

Überaus interessant wäre es, in der Analyse einen Schritt weiter zu gehen und die Beziehung der SR zur Bösartigkeit und Prognose zu ermitteln. Eine Voraussetzung hierfür wären eingehendere pathologisch-anatomische Studien der Fälle sowie eine Nachuntersuchung des Materials.

Der eigenartige Charakter der Hypernephrome offenbart sich ja u. a. auch in dem Verhalten der *Temperatur*. Fieber ist beim Hypernephrom eine ziemlich häufige Erscheinung. Man könnte sich denken, dass derselbe Faktor, dasselbe Agens, sowohl die Temperatur wie die SR beeinflusst, was sich womöglich in einer gewissen statistischen Beziehung zu erkennen geben könnte.

Bei 40 von den 109 Fällen des Materials kam Fieber vor. Von diesen hatten jedoch 9 Anzeichen einer Infektion der Harnwege und sind daher bei der Zusammenstellung beiseite gelassen worden, um den Tumorfaktor nach Möglichkeit sozusagen »reinzuzüchten«. Die übrigen 31 Fälle sind in Tabelle 3 aufgeführt.

Tabelle 3.

SR bei Fällen mit Fieber.

Fall Nr	Fiebertypus	SR	Grösse des Tumors
15	Subfebril	120	Faustgross
16	»	83	Doppelt faustgross
18	»	27	Faustgross
21	»	51	Kindskopfgross
29	»	76	»
30	»	114	Hühnereigross
49	»	81	900 g
53	»	74	1450 »
57	»	65	730 »
63	»	60	1110 »
68	»	54	Mandarinengross
70	»	30	230 g
72	»	32	515 »
73	»	75	800 »
102	»	116	Doppelt faustgross
74	»	84	320 g
76	»	53	Walnussgross
94	»	132	Sehr gross
109	»	130	Apfelgross

25	Continua 38—39°	97	Hühnereigross
27	»	155	Doppelt faustgross
84	»	52	Kindskopfgross
85	»	40	Mannskopfgross
8	Unregelmässig	120	Faustgross
37	»	48	Kindskopfgross
40	»	6	Hühnereigross
61	»	111	—
62	»	92	—
71	»	148	1800 g
36	»	41	Mandarinengross
45	»	107	—

Bei 19 der Fälle bestand die Temperatursteigerung in länger dauernder Subfebrilität. 4 Fälle hatten eine hohe Continua, und bei den 8 anderen war die Temperatur unregelmässig, schleudernd. Bis auf einen Fall (40) hatten sämtliche eine erhöhte SR. Der niedrigste Wert war 27 mm (Fall 18). Bei der grossen Mehrzahl der Fälle war die SR ziemlich stark erhöht. Es scheint also zwischen SR und Fieber eine gewisse, allerdings nicht stark ausgeprägte, Beziehung zu bestehen.

Bei 5 der oben in Tabelle 3 zusammengestellten Fälle war die SR vor der Operation mehrere Male untersucht worden. Interessant ist die Feststellung, wie die SR-Werte während der einzelnen Zeitabschnitte schwankten. Das Auftreten derartiger Schwankungen erinnert an gewisse Unregelmässigkeiten der Temperatur bei einem Teil der Hypernephromfälle. Der geringe Umfang des Materials in dieser Beziehung gestattet keine bestimmteren Schlussfolgerungen hinsichtlich eines etwaigen Zusammenhangs.

Tabelle 4.

Schwankungen der SR-Werte.

Fall Nr	S R — Werte
37	104—125—130—129—56—48 3 W. 7 T. 6 T. 3 M. 2 W.
49	72—81—51—80 2 T. 2 W. 3 T.
51	105—120—91 4 T. 1 M.
82	65—125—101 4 T. 4 T.
85	89—65—40—70 10 T. 7 T. 5 T.

Die Zahlen zwischen den SR-Werten bezeichnen die Zeitabstände (T. = Tage, W. = Wochen, M. = Monate).

Interesse besitzt ferner das Verhältnis der SR zum *Alter* der Geschwulst. Selbstverständlich lässt sich dieses schwer angeben.

Die Grösse des Tumors ist naturgemäss ein zu unsicherer Ausdruck. Einen gewissen Massstab für die Dauer des Leidens liefert uns der Zeitpunkt der ersten Hämaturie. Diese Bestimmung ist natürlich nur eine ganz annähernde und lediglich dort brauchbar, wo es sich um lange Zwischenzeiten handelt. In dem vorliegenden Material ist mit blossem Auge sichtbare Hämaturie bei 60 der Fälle angegeben. In Tabelle 5 sind diese nach dem Zeitpunkt der ersten Blutung in Gruppen geordnet.

Tabelle 5.

Beziehung der SR zum Zeitpunkt der ersten Blutung.

24 Stunden	30, 2, 17, 18, 25, 16, 55
48—96 Stunden	44, 50, 20
1 Woche	35, 25, 56, 37
1 Monat	24, 41, 3, 60, 12, 30, 75, 53, 20
2 Monate	20, 116, 112, 13, 49, 130
3 »	4, 51, 85, 4, 2, 42
½ Jahr	8, 157, 8, 83, 50, 60, 37, 26, 30
1 »	76, 67, 65, 18, 111, 2
2 Jahre	42, 11
5 »	4, 16
7 »	20
8 »	22, 27
10 »	16, 51

Es fällt auf, dass die extremen SR-Werte, über 100 mm, ausschliesslich bei Fällen vorkommen, wo die erste Blutung innerhalb eines Jahres aufgetreten war. Dagegen finden wir eine ziemlich niedrige SR bei Fällen, bei denen die erste Blutung länger zurückliegt, 2—10 Jahre. Es ergibt sich somit eine gewisse Übereinstimmung zwischen Alter und Grösse des Tumors, indem die SR-Werte bei sowohl sehr grossen wie auch sehr alten Geschwülsten verhältnismässig niedrig sind.

An Hand der SR zu beurteilen, ob *Metastasen* vorhanden sind, ist selbstverständlich nicht möglich, namentlich da schon der Primärtumor als solcher zu wechselnden Werten führen kann. Im vorliegenden Material sind Metastasen bei 11 Fällen festgestellt worden, bei 7 in den Lungen und bei 4 im Knochengerüst. Die SR war bei allen diesen Fällen beträchtlich erhöht, bei 3 Fällen über 100. Wichtig sind in diesem Zusammenhang zwei Fälle, die erkennen lassen, dass eine niedrige SR Metastasen nicht ausschliesst. Bei dem einen handelte es sich um einen 68jährigen Mann, der wegen einer Fraktur infolge einer Metastase im Femur in das

1. Bei fast $^1/_3$ der Fälle (31,2 ± 4,4 %) war die SR niedrig, unter 20 mm.

Fälle mit normaler SR waren häufiger (20 Fälle = 18,3 ± 3,7 %) als solche mit extrem hoher SR, über 100 mm (17 Fälle).

2. Die SR ist nicht der Grösse des Tumors proportional. Nicht selten findet man bei sehr grossen Geschwülsten eine niedrige SR. Es sind Tumoren von 1200 g mit normaler SR vorgekommen. Kleine Geschwülste können mit einer hohen SR einhergehen.

3. Bei alten Tumoren ist die SR oft ziemlich niedrig.

4. Bei Fällen mit Fieber (ohne Harninfektion) ist die SR gewöhnlich wesentlich erhöht. Die SR bei Fieberfällen kann im Laufe der Entwicklung stark schwanken.

5. Die SR ist bei Metastasen in der Regel beträchtlich erhöht, es kann aber eine niedrige SR vorkommen.

Summary.

The occurrence of an extremely high ESR in hypernephroma ought to be generally known. Less known is the circumstance that a low or even normal ESR can exist. The author considers that the knowledge of this is important and gives an account of the ESR in 109 cases of operated, patho-anatomically verified hypernephromata. The results of the examinations can be summarized as follows:

1. Nearly one third of the cases, 31.2 ± 4.4 %, showed a low ESR under 20 mm. Cases with normal ESR were more numerous (20 cases = 18.3 ± 3.7 %) than cases with extremely high ESR, above 100 mm (17 cases).

2. The ESR is not proportional to the size of the tumor. Not infrequently does one find a low ESR in very large tumors. Tumors weighing 1200 gm having a normal ESR have occurred. Small tumors can have a high ESR.

3. Old tumors have a rather low ESR.

4. Cases with fever (without infected urine) usually have a considerably raised ESR. The ESR value in cases with fever can often vary considerably during their development.

5. The ESR in cases with metastases is usually raised considerably but a low ESR can also occur.

Résumé.

L'existence de valeurs très élevées de la vitesse de sédimentation dans les cas d'hypernéphrome sont notoires. Mais il semble qu'on connaisse moins le fait qu'on puisse observer une VS peu élevée ou normale. L'auteur estime important qu'on le sache et a étudié la VS dans 109 cas d'hypernéphrome histo-pathologiquement confirmés et opérés. On peut ramener les résultats de son étude aux points suivants:

1. Dans près d'$^1/_3$ des cas (31.2 ± 4.4 %), VS basse au-dessous de 20 mm.

Les cas présentant une VS normale ont été plus nombreux (20 cas = 18.3 ± 3.7 %) que ceux présentant une VS très haute, au-dessus de 100 mm (17 cas).

2. La VS n'est pas proportionnelle au volume de la tumeur. Il n'est pas rare de trouver une VS basse accompagnant une tumeur très volumineuse. Il a observé des tumeurs de 1200 gr. avec VS normale. De petites tumeurs sont parfois accompagnées d'une VS élevée.

3. Les vieilles tumeurs ont souvent une VS assez basse.

4. Les cas fébriles (sans infection urinaire) ont souvent une VS assez élevée. Dans ces cas VS peut présenter de grandes variations dans leur développement.

5. Dans les cas de métastases, l'élévation de VS est d'ordinaire considérable, mais une VS basse n'est pas exclue.

Schrifttum.

Bergendahl: Acta chir. scand. *77*, 563 (1935). — Damm: zit. n. Ljunggren. — Hellström: Acta chir. scand. *80*, Suppl. 52 (1937). — Nord. Med. *18*, 653 (1943). — Jonsson: Nord. Med. *27*, 1633 (1945). — Ljunggren: Acta chir. scand. *66*, Suppl. 16 (1930). — Reichel: Blutkörperchensenkung. Wien 1936. — Smirnoff: zit. n. Ljunggren.

(From the Kuopio County Hospital: Prof. M. HÄMÄLÄINEN, and a Field Hospital Service: T. GUNNAR NYSTRÖM, Lic. Med.)

Rupture of Kidney Tumours and Hydronephroses.

By

T. GUNNAR NYSTRÖM.

Introduction.

Subcutaneous or open rupture of the kidney constitutes the dominant feature in renal traumatology. But a break in the kidney can occur also — often when the trauma is relatively slight — when the organ is the seat of advanced pathological changes. In my paper, "Über bösartige Nierentumoren bei Kindern" (Acta chir. scand., vol. 84, p. 531) I mentioned a case of ORTH's, a 4-year-old child suffering from rupture of a malignant tumour of the kidney. In 1941. GRAUHAN & HELLRIEGEL described 2 cases of lipoangiosarcoma of the kidney with dangerous spontaneous haemorrhage as the result of rupture of the tumour. They maintained that lipoangiosarcomatous tumours, because of their structure, seem to rupture more easily than other new-formations in the kidneys. ODES in 1934, and SCHREIBER in 1936, reported a case of rupture in connection with unilateral polycystic changes in the kidney. WEICHEL mentioned a similar case in 1937.

Another feature — although an uncommon one — of the clinical picture in kidney tumours, in addition to enlargement of the kidney, haematuria, pain, fever, and a high sedimentation rate, is rupture of the tumour, this being sometimes the first sign of the disease.

As is well known secondary infection of a hydronephrotic cyst is the commonest complication in this disease. Rupture of the cyst, either spontaneously or after a trauma of greater or lesser severity, is unusual, although not so unusual as rupture of a tumour.

Fig. 1. The renal pelvis and ureter on the right side are clearly visualized. On the left side the contrast fluid appears as an irregular shadow, the size of a closed fist, where the renal pelvis is normally situated. No definitely distinguishable kidney shadow is visible. Signs of excretion in the upper segment of the ureter. The contrast fluid is less dense than on the right side.

Fig. 2. Normal conditions on the right side. On the left, the renal pelvis is not visualized; the contrast fluid is passing through the ureter as far as the pelvis but no further.

was closed by exact approximation over a rubber drain. After the intervention the patient's condition was slightly affected. Saline solution was injected intravenously and a blood transfusion (500 cc.) was done. By March 9th she was showing improvement. The drain was removed. Her evening temperature was around 38°C. On March 15th the convalescence was still proceeding smoothly. A little pus was exuding from the operation wound. Some of the stitches were removed. On March 18th the remaining stitches were removed. Haemoglobin, 51 percent (Sahli). On March 22nd roentgen examination revealed that there was no metastasis to the lungs. Blood pressure, 130 mm. Hg. On March 26th the pathologico-anatomical diagnosis was: A typical malignant tumour of the kidney of Grawitz's type. On March 27th it was recorded that the diuresis had been good during the whole period, having varied between 800 and 2,000 cc. She was discharged, convalescent. In the autumn of 1937 she died from general metastasis.

Epicrisis. The case was that of a woman aged 51 who had earlier had symptoms of high blood pressure. She had been treated by a doctor for "kidney trouble". In March 1937 she fell down in the street and knocked her left side against the pavement edge. She was admitted to the hospital as an acute abdominal case with peritoneal irritation, pains, and tenderness in the left infra-costal angle, where an indistinct tumour was palpated. There was microscopical but no macroscopical evidence of haematuria. Because of suspected rupture of the spleen explorative laparotomy was first carried out, and following that, nephrectomy on the left side, through a lumbar incision. A ruptured malignant tumour of the kidney, as large as a child's head, which had not grown into the renal vein, was removed. P.A.D.: A typical Grawitz's tumour. The patient died six months later from general metastasis.

Discussion.

Three features are of especial interest in this case, viz. the statement in the anamnesis that the patient was believed to have had a high, or a raised, blood pressure, the absence of macroscopical signs of haematuria, and the insignificant injury which caused the rupture. First, as regards the blood pressure, some of the earlier investigators believed that kidney tumours excreted adrenalin. In recent years, however, this view has been abandoned. LJUNGGREN's experiments, for instance, seem to point in another direction. In his material of Grawitz's tumours the blood pressure was raised about as often as it was normal. He says: "Infolge dessen kann meiner Ansicht nach ein erhöhter Blutdruck nicht als ein charakteristisches Zeichen eines Grawitztumors betrachtet werden." Nor did the blood pressure, in his series, show a tendency to drop postoperatively. In the light of the more recent investigations, however, this conception must be slightly modified, or at least we must look at the problem of a possible hypertonia in

kidney tumours from a somewhat different point of view. As is known, there are now several proofs of the fact that the blood pressure rises in connection with various types of unilateral renal processes and that a nephrectomy causes it to revert to normal or to a lower level. The problem of renal hypertonia does not seem as yet to have been fully solved.

The patient under discussion had had earlier symptoms of, and had received treatment for, high blood pressure. She was 51 years old, however, and had entered upon the menopause, and no information is available as to the severity and the nature of her hypertonia. Consequently, the case is not very informative. Nor is the statement that the blood pressure was 130 mm. Hg after the nephrectomy of any great significance, since the patient had lost blood and was in shock. The statement is worth placing on record, however.

As is well known, haematuria is an extremely significant sign in Grawitz' tumours. In LJUNGGREN'S monograph, blood in the urine was observed in 84.5 per cent of the cases, in BERGENDAL'S publication in 72 per cent. An established or probable penetration of the tumour to the renal pelvis was the cause of the bleeding in the majority of LJUNGGREN'S patients. In other cases, the haematuria was a sign of stasis or inflammatory changes in the kidney tissue or the renal pelvis. In SCHREIBER'S two cases and ODES' case of ruptured polycystic kidney, haematuria was present. A study of the anatomic specimen from my patient revealed that there was no penetration to the pelvis or the calices. The tumour had grown outwards, penetrated the capsule, and then broken into the renal sinus. This was why there was no macroscopically demonstrable bleeding. Probably also, this constitutes the explanation why the tumour ruptured so easily and why the patient died so soon after the operation. True, BERGENDAL wrote, because in two of his patients there had been perforation of the kidney capsule and infiltration into the adjoining tissue and yet, despite this the final result had been excellent, "that the prognosis may be favourable in spite of tumour infiltration of adjacent tissues". However, the prognosis must be different in cases where the tumour ruptures and particles from the growth flood the entire renal sinus.

The diagnosis in ruptured tumour of the kidney is obviously more difficult to make than when an ordinary renal tumour is present. There is seldom time thoroughly to examine and follow

the patients. Urographic examination is undoubtedly a better aid in the differential diagnosis in these cases than it is in other subcutaneous intra-abdominal injuries. Unfortunately no urographic examination was made in my case. As a rule it seems necessary to do a laparotomy first, in ruptured kidney tumours and cystigerous kidneys (SCHREIBER, ORTH). This measure was employed in the present case also. The usually pronounced anaemia indicates intra- or extraperitoneal bleeding. In the absence of haematuria liver and spleen ruptures can be suspected.

The prognosis is unfavourable. According to ODES, ruptured, unilateral cystic kidneys show a 30 per cent mortality; in the case of a burst kidney tumour it is certainly higher. Strangely enough one of GRAUHAN & HELLRIEGEL's patients is still alive, 6 years after the operation.

Case 2. E. I., born March 4th, 1917, a sergeant, Pudasjärvi. The patient was admitted to a field hospital on September 25th, 1942 on a diagnosis of haematuria and suspected tuberculosis of the kidneys. In December 1941 the patient had had angina, but had otherwise been in good health. A week before his admission he became ill with acute abdominal pain and a headache. The urine was dark, and reddish. He had had no micturition pain and no fever, cough, or other pains. His general condition was good, his temperature normal. Lungs and heart normal. Nothing of interest from the abdomen. No tenderness or rigidity in the kidney regions. No oedema. Blood pressure, 125/60 mm. Hg. Sedimentation rate, 10 mm. in 1 hour. In a sample of $^1/_2$ sterile urine there were abundant erythrocytes, no bacteria, and no rods. On October 13th, 1942 he was transferred to a military hospital for a thorough examination. In sterile urine the picture was as follows: Yellow, acid, turbid; albumin present; in the sediment there were numerous red blood cells, a few leukocytes, and epithelial cells. No bacteria or tubercle bacilli. Culturing yielded no growth. On October 24th, *cystoscopic examination* revealed that the mucous membrane of the urinary bladder was slightly reddened, the apertures of the ureter normal. From both openings of the ureter clear urine was obtained. Analysis of urine from the bladder yielded no tubercle bacilli, and culturing gave a negative result. In urine from each of the kidneys there were no tubercle bacilli, and culturing results were negative. On November 4th, *urographic examination:* The right kidney shadow was normal as to size and shape. The psoas shadow was clearly distinguishable. The renal pelvis and ureter on the right side were distinctly visualized. On the left side the contrast fluid formed an irregular shadow larger than a closed fist at the site of the renal pelvis. There was no clearly visualized kidney shadow. There were traces of excretion in the upper segment of the ureter. The contrast substance appeared less dense than on the right side. (Fig. 1.) On November 5th, *pyelographic examination:* On the right

the picture was normal. To the left the renal pelvis had not filled. The contrast substance was filling the ureter as far down as the renal pelvis, where the ureter appeared to be constricted. (Periureteritis?) (Fig. 2.) The diagnosis made at the military hospital was haematuria, possibly periureteritis. The patient was transferred to the Home Front for six months.

On July 11th, 1943 he was again admitted to a field hospital. While pole-jumping on the morning of the same day the patient had fallen to the ground several times and he had then experienced pains in the back, in the region of the left kidney. He continued the exercises, however, and fell again, experiencing this time an intense, tearing pain in his back. He began to feel ill, became white-faced, and was sent to the field hospital. His general condition was then slightly affected. He was pale, but the pulse was good. Palpation over the left kidney revealed marked tenderness and slight rigidity. The urine was very bloody. On a diagnosis of *rupture of the left kidney* he was put to bed with an ice-bag over the left kidney. Towards evening his condition improved, his pulse was good, the urine cleared and the tenderness had subsided. On July 12th, in the morning, his condition was still satisfactory, the urine showed only traces of blood. The temperature and pulse were normal. He had no pains. The abdominal tenderness was less than before. At 5 o'clock there was a sudden temperature rise and he became rapidly pale and was sweaty and chilled. He complained of intense pain. His pulse was small and rapid. The tenderness had increased again noticeably. The urine was dark red, the colour of Bordeaux wine. An operation was immediately undertaken. As the patient had been treated at a military hospital for some form of kidney complaint, and as the injury he had sustained during the pole-jumping seemed to have been mild, it was believed before the intervention that he might be suffering from rupture of a diseased kidney. On July 12th, at 6 p.m., *nephrectomy of the left kidney, and a blood transfusion* were carried out. (Ether narcosis. Nyström and Fabritius.) The usual lumbar incision on the left side was made. The renal sinus was seen to be filled with fluid and coagulated blood. The left kidney was the size of a child's head, and transformed into a flabby, fairly thin-walled sac which was full of fluid blood and clots. The cyst had ruptured posteriorly, and a fissure about 6 cm. in length extended through the wall of the cyst. An extra artery as thick as a match passed from the anterior surface of the inferior kidney pole over the anterior side of the ureter at the junction with the pelvis. The cyst was excised in the usual manner, the kidney vessels and aberrant artery were ligated, the ureter was also ligated and severed. The wound was closed by exact approximation over a rubber drain. After the intervention the patient received 700 cc. of blood. His condition was satisfactory. On July 16th the convalescence was proceeding uneventfully. The drain was removed. The urine was clear, the diuresis good. The wound was clean. On July 18th he received 700 cc. of blood for his anaemia. All the sutures were removed on July 22nd, and the patient was then feeling better. On August 2nd he was sent back to the military hospital for continued treatment. On August 12th the sedimentation

rate was 10/22 mm. Rest nitrogen, 32.5 mg%. On September 20th the patient was re-drafted to the Home Front, cured.

When the anatomic specimen removed at operation was studied it was found that the kidney parenchyma formed a layer only 1 cm. thick around the cyst. The ureter was of normal width and there were no strictures, or signs of periureteritis. No concrements were observed. There was no definite indication that the ureter was fixed to the pelvis; the passage was clear. Unfortunately, it was not possible to make a pathologico-anatomical analysis of the hydronephrotic cyst.

Epicrisis. This patient was a man of 23 who had previously been treated at a military hospital for haematuria. Re-examination of the roentgenograms indicated that he had a large hydronephrosis on the left side. Nine months later, after a pole-jump, he was admitted to a field hospital presenting signs of renal rupture. The urine contained much blood. At operation (nephrectomy), a large ruptured hydronephrosis was found. The rupture was situated in the lower portion of the posterior wall of the cyst. The ureter, which was of normal width, with no strictures or narrowings, passed out from the lowest point of the pelvis. There were no signs of periureteritis. An extra artery, of a match's thickness, ran from the anterior surface of the lower kidney pole over the front of the ureter at the junction with the pelvis. The patient was discharged as cured. Microscopical examination was not undertaken.

Discussion.

Occurrence, age, sex, etc. In his publication entitled "Traumatic Rupture of Hydronephrosis" HAUGSETH refers to MOTZFELD'S and ROSCHER'S investigations on autopsy material from Rikshospitalet in Oslo between the years 1899 and 1930, from which it was ascertained that 2 per cent of the cases were congenital anomalies of the kidney and urinary passages. Of these, one-fourth were hydronephroses, or one-half per cent of the whole material. On the other hand, it is difficult to determine how large a proportion of the hydronephroses generally lead to rupture. The percentage cannot be very high; a proof of this statement is the fact already mentioned, that up to the year 1934 SKARBY had only found 70 cases mentioned in the literature. It is to be wondered why a hydronephrosis ruptures so seldom. The often large, distended cyst ought, it would seem, to be easy game for an injury. And it is a fact that in the cases where the hydronephrosis has ruptured the provoking trauma has often been exceedingly slight. The only possible answer is that the protected position of the kidney, its movability, and the elasticity of the hydronephrosis all help the cyst to escape rupture. ÖSTLING, in his study of the genesis of hydronephrosis, established that there is often a considerable

increase in the elastic tissue of the cyst wall. As is well known, hydronephrosis formation is commoner in the right kidney; ruptures, on the other hand, occur approximately twice as often in the left kidney as in the right. The more exposed position of the left kidney must be the reason for this. OEHME, and later BUTIN (cited by SKARBY), have pointed out the relatively young age at which ruptured hydronephrosis generally occurs. Of SKARBY's 71 cases, 44 were between 10 and 40 years of age. Men are more often exposed to traumatic influences than women. Hydronephrosis is encountered in men and women in a ratio of 2 : 3, but a rupture, on the other hand, is commoner among the male sex. Relatively speaking, rupture of a hydronephrosis is not infrequently encountered in children (HAUGSETH, ROBERTSON), and HINMAN (cited by TOLSON) has described a congenital rupture. Further, cases of ruptured, infected hydronephrosis have been reported by, among others, ROBERTSON and SCHMIDT.

Type of rupture, mode of origin. When a hydronephrosis ruptures it can be assumed that a) a *partial* rupture with a tendency to heal has arisen, or a secondary traumatic cyst formation originating from the hydronephrosis develops, or b) a *total* rupture has occurred. The total rupture can be classified into three different types, viz. 1) ruptures extending to the capsula fibrosa, with a perirenal pseudohydronephrosis as the result; 2) those embracing also the capsula adiposa, resulting possibly in a pararenal pseudohydronephrosis; and 3) the commonest type of rupture, where the wall of the sac consists of a single layer and the rupture penetrates out to the renal sinus. A retroperitoneal outflow then occurs. This occurred in my patient also. In a few cases the hydronephrosis has been closely adherent to the peritoneum. When a rupture occurs the peritoneum is also rent and the picture is then that of a diffuse peritonitis. CHAPUT (cited by SKARBY) reports a case where the hydronephrosis ruptured into the caecum.

I have already pointed out that a hydronephrosis can rupture even when the trauma is comparatively slight. An example of this is a case of WOOD's (cited by HAUGSETH), where the rupture arose when the patient jumped in his bed. The higher the pressure in the hydronephrosis cyst, the more distended this will become, and the thinner the wall the smaller the insult which is necessary to cause rupture. It has been suggested that a so-called hydraulic explosive effect under high internal pressure might be in question. This explanation seems to me to be rather strained, however.

It is hardly necessary to depart from the current, known physical laws to account for the rupturing of hydronephrosis. The same rules which apply to ruptures of internal parenchymatous organs can also be applied to hydronephroses. KROGIUS and HÄMÄLÄINEN, in their illuminating studies, attempted to prove that most ruptures of organs are brought about by compression or bending. In the case of the former, the ruptures run in the direction of the applied force, in the case of the latter at an angle to the direction from which the force is applied. If the hydronephrotic cyst is compressed from above downward, ruptures will occur either in the rear or the front wall; if it is pressed together from side to side, or from the front in a backward direction there will arise a rupture in the superior or inferior portion of the cyst. A rupture from compression is commoner than one due to bending. It very often happens that a hydronephrosis ruptures after a fall from a height. Here we have an example of compression from above downward. We must consequently expect that the majority of these ruptures will be found in the posterior or anterior wall. And this is what actually happens. SKARBY obtained information as to where the rupture was situated in 38 patients. There were 27 ruptures in the rear or front wall as against 11 in the lower or upper portion of the cyst. A rupture will, of course, only occur on condition that the alteration in shape is such that the organ's elastic capacity is exceeded. HÄMÄLÄINEN states that in cases where an organ ruptures all three dynamic effects can be expected, viz. the organ will acquire mobility, it turns around its axis, and it changes its shape. Obviously, the more distended a hydronephrosis is, the more readily will the limit of its elastic capacity be reached; in other words, a comparatively small injury will precipitate a rupture. According to HÄMÄLÄINEN also, the muscular contractions play an important part in connection with ruptures of organs. Most authors maintain that the rupture in hydronephrotic cysts is usually situated in the posterior wall of the cyst and often in the inferior pole of the renal pelvis, especially after falls from a height. REHBEIN (cited by SCHEELE) presumed this to be due to the fact that the velocity of the fluid in the cyst increases as the fall takes place, causing the pressure on the pelvis to increase, particularly towards the bottom of the pelvis, at the moment when the body reaches the ground. A more likely explanation is, however, that here also compression, with its consequent characteristic rupture, must be in question. In a fall from a height, the organ,

besides being compressed, is also bent, this leading to a combined rupture in the posterior wall of the cyst.

The fact that the rupture of the hydronephrosis in my patient occurred after a pole-jump with its typical mechanism furnishes in my opinion an excellent opportunity for a study of how the acute increase in pressure in a hydronephrosis arises and how the rupture can conceivably occur. When a person is doing a pole-jump the abdomen-pressure increases considerably during the run-up. The pressure in a hydronephrosis increases. At the moment when the body is swung up to clear the rail it rotates on its long axis, and the kidney falls forward. As the psoas muscle and the vertebral column prevent it from swinging backwards the organ consequently rotates in a forward direction also. If the ureter is fixed in abnormal contact with the pelvis, such as ÖSTLING has proved occurs in most hydronephroses, this fixation will be made more secure through the rotation, the pelvis cannot empty, and a state of acute retention arises. As the jumping is continued the renal pelvis becomes more and more dilated, and the tension in the cyst increases until finally the point is reached when compression occurs as the patient descends to the ground and the hydronephrosis ruptures. The pain experienced by my patient during the jumping is strong evidence in favour of the theory of ever-increasing pressure in the hydronephrosis. The extra kidney vessel must have played the part of a contributory factor, to a certain extent helping to increase the pressure and aggravate the dilatation since the kidney, on its fall forward, as it were overrode the vessel. In support of this interpretation of my case, which in my opinion furnishes a beautiful proof of the correctness of HÄMÄLÄINEN's view on how ruptures of organs arise, I would refer the reader to ÖSTLING's publication (Acta chir. scand. vol. 86, suppl. 72, p. 96), mentioning 2 patients in whom he was able to follow by means of pyelography the mechanism occurring in acute attacks of hydronephrosis. Subcutaneous rupture of a kidney is not a common occurrence after an ordinary pole-jump, but as the patient had earlier complained of discomfort from the kidneys and had been examined for haematuria at a hospital, the suspicion that he might be suffering from rupture of a diseased kidney had already arisen before the operation.

Symptomatology and diagnosis. If I now pass on to a brief discussion of the signs and symptoms in ruptured hydronephrosis the objection might be made that this will depend wholly on the

clinical type of rupture which may be in question. First we have the cases, among others my patient, where the signs and symptoms are in perfect agreement with those of the common, subcutaneous kidney ruptures of traumatic origin. The largest and most important group comprises the cases in which, after a trauma, a rapidly developing tumour arises at the site of the kidney, or in which a growth already in existence, precipitated originally by a blow, quickly enlarges. SKARBY had 32 cases of this type among his 71 patients. In 75 per cent of these there were signs and symptoms — haematuria, anuria — which pointed directly to kidney disease. WEICHEL's case is an illustration of this category. A man aged 23 was kicked by a horse in the upper portion of the abdomen. Since then he had had a tumour on the left side. A few years later he was kicked again in the same region. A hydronephrosis ruptured. Signs of perforative peritonitis form the dominant feature in some instances, or so-called "pseudoperitonitis". In these patients there is no tumour, and often no hameaturia. The cyst of the hydronephrosis has adhered closely to the peritoneum and ruptured directly into the peritoneal cavity. The retroperitoneal tissue and the mesentery of the colon are seen at operation to be considerably oedematous. Direct irritation of the peritoneum and irritation of the autonomic nerves in the retroperitoneal space, with secondary circulatory disturbance as the result, are believed to be the cause of the oedema. Finally we have a group of patients who have lost their acute symptoms but who begin to have pain indicative of a slowly developing tumour after a more or less symptom-free latent period.

Among the direct signs of kidney disease haematuria and anuria should be mentioned. SKARBY has pointed out that mortal renal haemorrhage is not common. In my patient, however, such a dangerous degree of haematuria was present that nephrectomy had to be undertaken without delay. LARDENNOIS (cited by SKARBY) found blood in the urine in 95 per cent in patients with contused normal kidneys. Haematuria is not so often observed in ruptured hydronephrosis. This may be due to the fact that the break has passed through parenchyma-free walls or that the outflow into the retroperitoneal space is so extensive that the ureter becomes compressed. If the trauma has been violent the ureter may, of course, also be severed. BERGENDAL, in his work on kidney vessel variations in hydronephrosis, reported that in 62 patients in whom the vessel had been resected grossly visible renal haem-

orrhage occurred in only 2 while in 6 there was fairly extensive microscopical evidence of it. In my case the presence of haematuria was the reason why a more exhaustive investigation was undertaken. It is only to be expected that haematuria should be more often associated with a ruptured than with an undamaged hydronephrosis. Statements are found in the literature to the effect that a burst hydronephrosis had produced complete anuria and that the patients died without the diuresis having started again. This has been interpreted as a so-called reflex anuria. In his interesting study on reflex calculous anuria, WULFF has expressed a doubt, which he defends in a convincing manner, as to whether such a condition as reflex calculous anuria really exists. In view of the fact that bilateral hydronephrosis not infrequently occurs in conjunction with cyst formation in the kidneys there seems in my opinion to be reason for suspecting that it is not a question of so-called reflex anuria, in ruptured hydronephrosis, but rather that the other kidney, being in a diseased condition, has been incapable of secreting urine in an amount sufficient to maintain life.

VON SÅR (cited by HAUGSETH) classifies the symptoms occurring in ruptured hydronephrosis under the following seven headings: 1) general malaise, 2) muscular tension and rigidity in the abdomen, 3) pains, tenderness, and tumour on one side, 4) meteorism, 5) peritoneal irritation, vomiting, hiccough, nausea, 6) abnormal matters in the urine, 7) fever and an abnormal pulse rate. HAUGSETH added the typical oedematous swelling of the mesentery and the retroperitoneal tissue observed at laparotomy. It is my belief that all these symptoms are seldom if ever present. One or more of them are usually lacking, and they occur in different combinations according to the clinical type of ruptured hydronephrosis which is present in the individual cases.

As the foregoing discussion has shown, it is by no means easy to make the diagnosis in ruptured hydronephrosis. If the anamnesis contains nothing to indicate a hydronephrosis, and if the patient has become ill after an injury, with pains in the side, tenderness, swelling in the kidney region, and haematuria, it is natural that we should first suspect subcutaneous rupture of a kidney. But if the injury has been disproportionately slight, and if the patient has received treatment on a previous occasion for a kidney complaint or felt a tumour in the abdomen, the possibility that a hydronephrosis is in question should be considered. It should also be suspected if the patient has previously sustained a trauma in the

kidney region. The differential diagnosis from traumatic ruptured cyst of the spleen can be difficult to make, however, if there is no blood in the urine, and if the complaint is located on the left side. An ordinary kidney rupture is also encountered after very slight abdominal injuries. LARDENNOIS (cited by SKARBY) describes a case where a kidney rupture occurred in a married woman while she was dancing a waltz. A ruptured hydronephrosis often displays a confusing similarity to an acute attack of renal calculus with severe colic (PIZZAGALLI). In women, a ruptured hydronephrotic cyst with signs from the peritoneum is difficult to distinguish from a torsive ovarian cyst or ruptured extra-uterine pregnancy. In patients with characteristic symptoms of peritonitis only, all acute abdominal diseases can come into question. In these cases, as in all cases of unaccountable abdominal complaints, urographic examination is of great assistance, if the patient's condition allows it. If my patient had been operated upon at an earlier stage on the evidence of the urographic finding he would have been spared his subsequent perilous illness.

Treatment and prognosis. A few words on the treatment and prognosis in ruptured hydronephrosis are perhaps called for. When the signs and symptoms and the diagnosis point directly to a kidney complaint lumbar nephrectomy seems to be the only effective therapy. There seems to be little advantage, as a few surgeons suggest, in operating in two sessions, in other words to do first a nephrostomy and then extirpation. On the contrary, in my opinion there is every reason for radically eradicating the trouble as soon as possible in such a serious illness. If owing to diagnostic difficulties laparotomy has been undertaken and a ruptured hydronephrosis is discovered, I would recommend a procedure which I have used successfully in connection with a shell wound accompanied with haematuria and peritoneal symptoms. The peritoneum is closed, and then, as in lumbar sympathectomy, from the same incision extraperitoneal exploration into the renal sinus is done, after which the ruptured organ is extirpated.

The mortality in connection with ruptured hydronephroses is fairly high. OEHME (cited by HAUGSETH), in 1907 had 4 deaths in 8 patients operated upon (3 operated upon transperitoneally, 4 through a lumbar incision, and 1 by a combined procedure); thus, a 50 per cent mortality. Since then, of course, the prognosis must have become more hopeful, but a ruptured hydronephrosis must still be regarded as an extremely serious condition.

Summary.

1. The author describes two rare cases of kidney rupture, the first a ruptured malignant tumour of Grawitz's type, the second rupture of a hydronephrosis. No case of ruptured kidney growths has previously been published in Scandinavian literature. The case was that of a 51-year-old woman who knocked her left side against a pavement edge, after which a Grawitz's tumour ruptured. There were slight microscopic traces, but no gross signs of haematuria. Nephrectomy was performed. The patient died six months later from metastasis. A short discussion on the significance of haematuria and hypertonia in kidney tumours follows the case report. The signs and symptoms, diagnosis, and therapy in ruptured tumour of the kidney receive brief mention.

2. The other case was that of a man aged 23 in whom rupture in the posterior wall of a hydronephrotic cyst occurred during a pole-jump. A high degree of haematuria was present. Lumbar nephrectomy was performed. The patient recovered.

3. In connection with this case a fairly detailed discussion is appended on the different types of rupture occurring in hydronephroses, the clinical picture, the diagnosis, and the treatment. The author suggests that the signs and symptoms and the clinical picture are wholly conditioned by the types of rupture. It is not possible to set up any general rules as regards symptomatology and clinical signs for the recognition of ruptured hydronephroses. The diagnosis is as a rule difficult to make. Most of the acute abdominal diseases can be confused with a ruptured hydronephrosis. The great value of urography is stressed. The treatment should be nephrectomy, carried out in one session. If a laparotomy has been done owing to difficulties in diagnosis, and a ruptured hydronephrotic cyst is then discovered, the author recommends an extraperitoneal procedure from the incision used for the laparotomy.

4. The most important part of this paper is devoted to an analysis of the mechanism of the hydronephrosis rupture. These ruptures arise as the result of the same physical laws as those applying in rupture of internal parenchymatous organs. (*Cf.* Krogius and Hämäläinen.) As a rule the break is located in the posterior or anterior wall. In the majority of cases, perhaps in all, they are due to compression. In the author's case (rupture during a pole-jump) the mechanism forms a beautiful illustration of how

all three of the dynamic forces, viz. the direction of the force, the turning about an axis, and the alteration in shape, are involved in producing the rupture. The significance of the muscular contractions is stressed. The author believes that a purely physical explanation of the mechanism in hydronephrosis ruptures is the only natural and correct one to adopt. All other attempts at interpretation are illogical and strained (as, for example, the theory of a hydraulic bursting effect, or an increased velocity mechanism). In its way, the case constitutes a proof of the correctness of ÖSTLING's conception as to the mode of origin of the acute phase of hydronephrosis.

Zusammenfassung.

1. Der Verfasser beschreibt zwei seltene Fälle von Nierenruptur. Jener ein rupturierter, maligner Nierentumor, dieser eine rupturierte Hydronephrose. In nordischer Literatur ist nicht früher Fälle von rupturiertem Nierentumor beschrieben worden. Eine 51-jährige Frau schlug ihre linke Seite gegen den Randstein, wobei ein Grawitz-tumor rupturierte. Keine makroskopische wohl aber mikroskopische Hämaturie. Nephrectomie. $^1/_2$ Jahr später gestorben an universeller Metastasierung. Im Anschluss des Falles wird die Bedeutung der Hämaturie und Hypertonie bei Nierentumor ein wenig diskutiert. Die Symptome, die Diagnose und die Therapie bei rupturiertem Nierentumor wird in aller Kürze besprochen.

2. Der Zweite Fall war ein 23-jähriger Mann, der bei Stabhochsprung eine Ruptur in der hinteren Wand einer Hydronephrose erhielt. Ausgesprochene Hämaturie. Lumbale Nephrectomie. Gesund entlassen.

3. Im Anschluss des Falles wird recht eingehend die verschiedenen Rupturtypen bei Hydronephrose, das klinische Bild, die Diagnose und die Therapie diskutiert. Der Verfasser betont, dass der Rupturtypus bestimmt, welche Symptome und welch klinisches Bild wir im einzelnen Falle erhalten. Man kann nicht ein gemeingültiges Schema für die Symptomatologie und Klinik der rupturierten Hydronephrosen aufstellen. Die Diagnose ist in der Regel schwer zu stellen. Die meisten akuten Baucherkrankungen können mit einer rupturierten Hydronephrose verwechselt werden. Die grosse Bedeutung der Urographie wird betont. Die Therapie soll Nephrectomie in einer Sitzung sein. Wenn man, auf Grund diagnostischer Schwierigkeiten, Laparotomie gemacht hat und eine

rupturierte Hydronephrose vorliegt, empfehlt der Verfasser ein extraperitoneales Vorgehen aus der Laparotomiewunde.

4. Der wichtigste Teil der Arbeit wird der Analysierung des Mechanismus der Hydronephroseruptur gewidmet. Die Ruptur entsteht nach denselben fysikalischen Gesetzen, die bei Rupturen von inneren, parenkymatösen Organen geltend sind. In der Regel ist bei rupturierter Hydronephrose der Riss in der vorderen oder hinteren Wand des Sackes. Die Rupturen sind allermeistens, vielleicht immer, Kompressionsrupturen. Der Mechanismus im Falle des Verfassers (Ruptur bei Stabhochsprung) illustriert sehr schön wie alle drei dynamischen Kraftwirkungen bei der Entstehung der Ruptur eine Rolle spielen: Die Richtung der Kraft, die Drehung der Achse, die Veränderung der Form. Die Bedeutung der Muskelkontraktionen wird auch erörtert. Der Verfasser betont, dass eine *rein* fysikalische Betrachtungsweise die einzig richtige ist, wenn vom Mechanismus der Hydronephroseruptur die Rede ist. Übrige Deutungsversuche sind gesucht und gerade unlogisch (zum Beispiel der von einer hydraulischen Sprengwirkung oder der von einem Accelerationsmechanismus etc.). Der Fall des Verfassers ist, in seiner Art, ein Beweis dafür, dass Östling recht hat in seiner Auffassung wie eine akute Hydronephroseattacke entsteht.

Résumé.

1. L'auteur décrit 2 cas rares de rupture rénale. L'un est une tumeur maligne rupturée — type Grawitz —, l'autre une rupture d'hydronephrose. Des cas d'une tumeur rénale rupturée n'ont pas été auparavant publiés dans la littérature nordique. Dans le cas premier il s'agit d'une femme de 51 ans ayant heurté son côté gauche contre le bord d'un trottoir; à cette occasion une tumeur-Grawitz a rupturé. Pas d'hématurie macroscopique mais bien microscopique. Néphrectomie exécutée. $^1/_2$ année après l'opération, la malade est morte en métastases. A propos de ce cas, l'auteur discute l'importance de l'hématurie et l'hypertonie pour les tumeurs rénales. Il résume les symptômes, le diagnostic et la thérapeutique d'une tumeur rénale rupturée.

2. L'autre cas concerne un homme de 23 ans. Une rupture dans le mur postérieur d'une hydronéphrose avait été causée par un saut à la perche. Une hématurie prononcée a été constatée. Néphrectomie lumbale a été exécutée. Guérison.

3. A propos de ce cas, l'auteur discute assez en détail les types différents de rupture d'hydronéphrose, l'image clinique, le diagnostic et la thérapeutique. L'auteur souligne que c'est le type de rupture qui détermine entièrement les symptômes et l'image clinique obtenus. On ne saurait établir un schéma de valeur générale pour la symptomatologie et la clinique des hydronéphroses rupturées. En règle générale le diagnostic offre des difficultés. La plupart des maladies ventriculaires aiguës peuvent être confondues avec une hydronéphrose rupturée. L'auteur souligne la grande importance de l'urographie pour le diagnostic. Le traitement doit consister dans une néphrectomie en séance unique. Si, à cause de difficultés diagnostiques, on fait une laparotomie et découvre une cyste d'hydronéphrose rupturée, l'auteur recommande un procédé sous-péritonéal par l'incision de la laparotomie.

4. La partie la plus importante du travail est consacrée à l'analyse du mécanisme de la rupture d'hydronéphrose. Cette rupture naît selon les mêmes lois physicales que les ruptures d'organes intérieurs parenchymateux. La rupture est à l'ordinaire localisée dans le mur antérieur ou postérieur de l'hydronéphrose. Ce sont, le plus souvent, peut-être toujours, des ruptures compressionnées. Dans le cas de l'auteur (rupture due au saut à la perche) le mécanisme illustre parfaitement comment les trois forces dynamiques, la direction de la force, la torsion de l'axe et le changement de forme, jouent chacun son rôle pour la naissance de la rupture. L'auteur souligne l'importance des contractions musculaires. Il met en relief qu'une considération purement physicale est la seule, qui soit bonne et naturelle en ce qui concerne le mécanisme de la rupture d'hydronéphrose. Toute autre explication est affectée et illogique, par exemple celle d'un brisement hydraulique, d'un mécanisme d'accélération etc. Le cas fournit une preuve de ce que la conception d'Östling est juste en ce qui concerne la naissance d'une crise d'hydronéphrose aiguë.

References.

Bergendal, S.: Acta chir. scand. 77: 563, 1935. — Bergendal, S.: Ibid. 79: supp. 45. Lund 1936. — Grauhan & Hellriegel: Ztschr. f. Urol. 35: 409 (1941). Ref.: Nord. Med. 16: 3147 (1942). — Haugseth, K.: Acta chir. scand. 76: 451, 1935. — Hämäläinen, M.: Acta Soc. med. fenn. duodecim. Vol. 6, part 3, Helsingfors 1925. — Krogius, A.: Nord. Med. 51 (I). — Ljunggren, E.: Acta chir. scand. Suppl. 16, 1930. — Nyström, T. G.: Acta chir. scand. 84: 527, 1941. —

ODES, L.: Vestnik khir. 36: 86 (1934). Ref.: Z-org. ges. Chir. 77: 62 (1936). — ORTH, O.: Zentralbl. f. Chir. 63: 382 (1936). — PETERS, K. O.: Ztschr. f. urol. Chir. 39: 28 (1934). Ref.: Z-org. ges. Chir. 67: 308 (1934). — PIZZAGALLI, L.: Boll. Soc. piemont. Chir. 2: 884 (1932). Ref.: Z-org. ges. Chir. 60: 67 (1933). — ROBERTSON, J., and LEE, A. B.: Urologic Rev. 38: 243 (1934). Ref.: Z-org. ges. Chir. 68: 666 (1934). — SCHEELE, L.: Zentralbl. f. Chir. 61: 1883 (1934). — SCHMIDT, A.: Z. Urol. 25: 93 (1931). Ref.: Z-org. ges. Chir. 56: 823 (1932). — SCHREIBER, K.: Zentralbl. f. Chir. 63: 2652 (1936). — SKARBY, H.-G.: Acta chir. scand. 73: 361, 1934. — TOLSON, H.: Urologic Rev. 39: 768 (1935). Ref. Z-org. ges. Chir. 78: 375 (1936). — WEICHEL, M.: Chirurgija, 12: 136 (1937). Ref.: Z-org. ges. Chir. 89: 326 (1938). — WULFF, H. B.: Lund 1941. Håkan Ohlssons Boktryckeri. — ÖSTLING, K.: Acta chir. scand. Vol. 86, supp. 72, Stockholm 1942.

From the Surgical Services of the Västervik Hospital
(Physician-in-Chief: Dr. E. MICHAËLSSON),
and the Hälsingborg Hospital
(Physician-in-Chief: Dr. E. BRATTSTRÖM, M. D.).

Displacement of the Kidney Consequent upon Spontaneous Perirenal Hematoma.[1]

By

HANS EKMAN.

Spontaneous perirenal hematoma is a rather rare disease. As far as can be ascertained, the total number of cases mentioned hitherto in the literature comprises about 300. (*Cf.* DOLL, POLKEY and VYNALEK, LAEWEN, KAIJSER, and others.)

As the name implies, spontaneous perirenal hematoma is a spontaneously arising accumulation of blood in the immediate vicinity of the kidney — in the kidney bed. A number of observers (HÜBNER, for instance) use the term perirenal hematoma or perirenal hemorrhage only when the kidney or the tunica fibrosa is the source of the bleeding. Similar hematomas in the kidney bed can also arise, however, as the result of hemorrhage from extrarenal sources. HÜBNER describes the latter type of bleeding not as a perirenal but as a retroperitoneal hematoma. It is not an easy matter, however, to classify hematomas in the kidney bed in this manner, especially since the source of the bleeding is often not known in the individual cases. This system of classification has therefore not been used in the present paper; I have instead applied the term perirenal hematoma to accumulations of blood located in the immediate vicinity of the kidney and to a greater or lesser degree completely surrounding the kidney. Thus, perirenal hematoma is an anatomic conception.

Among the causes of spontaneous perirenal hematomas, different affections of the kidneys and the kidney vessels, such as

---

[1] Thanks are due to Prof. J. HELLSTRÖM, Prof. Å. ÅKERLUND, and Dr. S. WIKANDER, of Stockholm, for kindly placing hospital records and roentgenograms at my disposal.

hydronephrosis, glomerulitis, tuberculosis of the kidney, aneurysm, atheroselerosis, hypertension, thrombosis of the kidney vessels, renal infarction, periarteriitis nodosa, and renal tumors, form an important group.

Retroperitoneal tumors and pathologic conditions in the retroperitoneal vessels are important extrarenal causes of perirenal hematomas.

In both of these groups the pathogenesis of the hemorrhage is fairly clear. It is related to structural change in the blood vessels.

Diseases of the blood (purpura, hemophilia, and leukemia) form a smaller group of causes. According to POLKEY and VYNALEK this is the cause in about 4—5 per cent of the total number. In these cases the pathogenesis of the bleeding is traceable to changes in the vascular walls and in the blood — hemorrhagic diathesis.

In 15—20 per cent of the patients with perirenal hematoma no acceptable explanation of the hemorrhage has been discovered — in these it is termed "essential" perirenal hematoma. With regard to this group the discussion on the possible mechanism of the bleeding has been particularly lively. RICKER considered that paralysis of the vasomotor nerves of the kidney and the tunica fibrosa is in question and that this functional disturbance leads to vascular stasis and hemorrhage through diapedesis. LAEWEN strongly opposed this theory of RICKER's, maintaining instead that ruptures of blood vessels (hemorrhage through diaresis) must be the cause of the perirenal hematomas. An animated scientific battle has been waged on this question. HÜBNER, reasoning from the results of experimental studies, also formed a different theory on the pathogenetic aspect of the bleeding from that of RICKER. On the other hand, HEILMANN, in an investigation of a somewhat later date, reported that he was inclined to agree with some of RICKER's views. The problem of the essential mechanism of the bleeding in these conditions is, however, as far from solution as, for instance, the true explanation of cerebral hemorrhage. KAIJSER has asserted that the cause of this unaccountable bleeding, which has up to the present avoided discovery, in all probability is to be sought in many instances in structural change in the vessels which has escaped notice when the kidneys have been examined. For my part, I believe also that demonstrable causes of the bleeding will be discovered more often than has hitherto been the case if in the future we submit patients suffering from perirenal hematoma to a thorough examination of the kidney, its

tunica fibrosa and capsula adiposa, the retroperitoneal vessels, and the blood. The cases of idiopathic perirenal hematoma will then without doubt decrease in numbers.

The opening stage of spontaneous perirenal hematoma is often dramatic. The classical symptoms are pain, the development of a mass in the kidney region, and signs of internal hemorrhage (LENK). The symptomatology shows a fair amount of diversity, however. Vomiting, abdominal pain, tenderness, muscular rigidity, and distention are sometimes the dominant symptoms and in these cases ileus, appendicitis, or a perforating ulcer seem the obvious conditions to suspect.

Roentgen examination, which has been found to be of great value in the diagnosing of acute abdominal complaints, especially among Scandinavian workers (LAURELL, PETRÉN, HELLMER, WULFF, FRIMANN-DAHL, and others) is also of assistance in diagnosing perirenal hematomas.

The hemorrhagic effusion into the perirenal fat is visualized in plain roentgenograms as a shadow of increased density in the kidney region with more or less complete obliteration of the outlines of the kidney and psoas major muscle. So long as the kidney function is relatively intact, however, the true kidney outline will be visualized fairly clearly by means of urography. The presence of small hematomas or subcapsular hematomas (*i. e.* those situated between the kidney and the tunica fibrosa) sometimes causes the "kidney shadow" to appear enlarged. In such cases its outlines are more or less irregular. Lumbar scoliosis with the concavity towards the affected side is sometimes observed. The diaphragm on the affected side is in some cases elevated with limited excursion. A little effusion is sometimes observed in the pleural cavity. Meteorism in the colon is also seen. These roentgenologic signs have been described by, among other authors, LAURELL, HULTÉN, and HASSELSTRÖM. Similar roentgenograms are seen in periparanephritis, and in urinous infiltration of the tissues adjoining the kidney (LAURELL).

In the case of large perirenal hematomas with a greater accumulation of blood on one side of the kidney than on the other the kidney is likely to become displaced. When such displacements are being assessed it should be remembered that the position of the kidneys varies individually. The deviations are especially great in the case of congenital heterotopia. It is sometimes difficult, therefore, to decide whether an observed abnormal location of a kidney is

due to the perirenal hematoma or whether it is a reflection of congenital heterotopia. Consideration must also be paid to the fact that the kidney changes its position with the respiration and with different positions of the body.

The author of the present paper has had the opportunity to study two cases of spontaneous perirenal hemorrhage where the roentgenexamination revealed an abnormal location of the kidney. In one of these patients there was a distinct lateral displacement of the kidney on the affected side. In the other patient. the perirenal hematoma seemed to have caused moderate displacement of the kidney in a lateral direction.

Case Reports.

Case I. Record no. 1568/1939. Treated July 2—29, 1939 at the Surgical Service of the Västervik Hospital. A man aged 78. In 1908 posterior gastrojejunostomy because of a duodenal ulcer. During 1932 and 1933 he went through a period with loss of weight, fatigue, bleeding from the gums, and intestinal bleeding. His condition improved after internal therapy. In 1937 he had repeated attacks of renal calculus both on the right and the left side. The concretions were passed with the urine.

Urographic examination (Åkerlund). April 3, 1937. Despite numbers of scybala and intestinal loops distended by gas both kidney shadows appeared to be normal in shape and size. No stones opaque to the roentgen ray were visualized in the urinary tract. . . . Excretion urograms were made 9, 20, and 60 minutes after the intravenous injection of jodairal, and again after 2 hours. As in the preceding examination, the flow of contrast fluid was tedious in output on both sides. On the *right side,* the renal pelvis appeared to be of normal size whereas on the left side it was noticeably wider and the calyces were less contracted. The ureters were poorly visualized on both sides.

During the following years he had periodical attacks of renal calculus.

On *July 1, 1939, he became ill* without a precipitating trauma, with pains of moderate severity in the lower part of the abdomen on the right side. The pains did not radiate downwards toward the bladder and they did not resemble the pains experienced during his previous attacks of renal calculus. There was no tenesmus. No vomiting. Normal defecation on July 1.

Physical examination. July 2, 1939. General condition unaffected. Temperature, 37.6° C. Pulse rate 64 per minute. *Abdomen:* Intense tenderness in the right half of the abdomen, lateral to McBurney's point. Slight rigidity. The tenderness diminished in intensity towards the back and in a forward and downward direction in the abdomen. Tenderness was also present over McBurney's point. Examination through the rectum revealed nothing of interest.

Roentgen examination. On his admission a plain roentgenogram was taken on the suspicion of right-sided renal or ureteral calculus. No convincing evidence of this was found, however. (A urographic examination was not made in the acute stage.)

As the tenderness over McBurney's point increased in intensity during the morning and afternoon, the possibility of appendicitis could not be excluded, and it was decided to do a laparotomy.

Operation (WAHLÉN). July 2, 1939. When the grid-iron incision was made the subperitoneal fat was found to be saturated with blood. There was a slightly abnormal amount of clear fluid in the peritoneal cavity. The appendix was not inflamed and was therefore not removed. The peritoneum lining of the posterior part of the abdominal wall was bluish and was bulging forward over a large retroperitoneal hematoma on the right side. The hematoma, which was at its largest around the kidney, continued downward towards the inlet of the pelvis minor and upward as far as it could be followed. The blood imbibition continued anteriorly into the ascending mesocolon. Following this exploration, the abdomen was closed without drainage of the hematoma.

Re-examination of the roentgenograms from July 2, 1939 (LÖNNERBLAD). Fairly pronounced meteorism was present. It was not possible to determine the position of the ascending colon or the relations of the flank fat. Possibly, however, the caecum and the ascending colon were displaced in a medial direction. The kidney shadows were not distinguishable. The outlines of the left psoas muscle were visible, but not those of the right.

The patient's condition improved.

Roentgen examination (LÖNNERBLAD). July 13, 1939. The right arch of the diaphragm was relatively high; its mobility was not tested. There was moderate meteorism in the colon. Slight scoliosis in the lumbar region, with the concavity to the left. The outline of the left psoas muscle was visualized but that on the right side was obliterated.

Urographic examination (LÖNNERBLAD). Excretion urograms were made in the supine position, with compression, at intervals of 5, 10 and 15 minutes after injection, and in the prone position, without compression, 20 minutes after injection. In the 5-minute film only very faint and imperfect opacification of the renal pelvis was obtained; in the 10- and 15-minute films, on the other hand, the graceful outlines of the two renal pelvises came out clearly. No obstruction to the flow was detected. It was difficult to interpret the urograms owing to the colon meteorism which still persisted. The lower half of the left kidney shadow was distinguishable, however. Its inferior pole was on a level with the highest point of the iliac crest. The upper half of the right kidney shadow was visualized on a film taken with the patient lying prone. The outline of its inferior pole, on the other hand, was unclear. Judging by the opacified renal pelvis it was situated at the normal level but was *dislocated for about $1^1/_2$ cm in a directly lateral direction*, in views taken both in the supine and the prone position. (Fig. 1.)

Blood. July 15. Hemoglobin, 75 per cent. Red blood corpuscles, 4,090,000. Whites, 38,000. Platelets, 168,000. Differential count: meta-

tion could be referred to the hemorrhagic diathesis occurring in leukemia.

The subsequent course confirmed the diagnosis of leukemia. According to the report received from the patient's physician his health gradually declined and he died in August 1941 from leukemia.

The perirenal hematoma in this patient caused a lateral displacement of the right kidney. A study of the roentgenograms from Apr. 3, 1937, July 13, 1939, and Nov. 6, 1940 brought out the interesting fact that the lateral displacement seen in the films from 1939 had entirely disappeared in the final roentgenograms taken, the kidney having then resumed a more normal position which seemed to coincide with its position in 1937.

Case II. Record no. 2417/42. Treated Sept. 19 to Dec. 4, 1942 at the Surgical Service of the Hälsingborg Hospital. A man aged 48. Two days before his admission to the hospital he had become ill, with pains in the left side of the abdomen radiating to the back.

Physical examination. General condition relatively satisfactory. Temperature, 38.6° C, and pulse rate 100 per minute. *Abdomen:* There was tenderness and rigidity all over the left side. The tenderness was most intense over the left renal region. On palpation, the impression was gained that a mass was present.

Roentgen and urographic examinations (A. SCHOLANDER). Sept. 28, 1942. No scoliosis. A normal psoas shadow on the right side. On the left side the psoas muscle was not distinguishable. The right kidney shadow was clearly outlined, of normal size, and in the normal position. The left kidney shadow was considerably enlarged both as to length and breadth. It was 11 cm wide and was *slightly displaced in a lateral direction*. Its inferior pole, which was difficult to distinguish, reached to below the iliac crest. The distance from a line through the middle of the lumbar vertebrae to the left kidney pelvis was about $6^1/_2$ cm. The same distance to the right kidney pelvis was 4 cm. (These figures were measured on roentgenograms made without compression.)

Urography revealed that there was no delay in function on the right side and no obstacles to the flow. The calyces and renal pelvis were well filled and normal in appearance. On the other hand, on the left side poor filling of the calyces and renal pelvis were obtained.

Retrograde pyelography was therefore tried on Sept. 29. The right renal pelvis and calyces were normal. On the left side the inferior calyces were strictured. The superior calyces were also poorly filled. The picture was suggestive of tumor of the kidney.

Operation (BRATTSTRÖM). November 2. Nephrectomy of left kidney. A "dark" tumor the size of a child's head in which the left kidney was enclosed was removed. It was difficult to remove, owing to the presence of firm fibrous adhesions. The peritoneum tore but was stitched, and the wound was closed with drainage.

Examination of the specimen revealed that the upper part was composed of normal kidney tissue while at the inferior pole the tissue was tumorous. Around the inferior pole of the kidney there was a large hematoma which extended upward along the sides of the kidney. *It was relatively large on the medial aspect of the kidney.* (Thus, the large kidney shadow visualized on the roentgenogram corresponded in reality to the kidney, the tumor, and the perirenal hematoma.)

Pathologico-anatomic diagnosis (HJALMAR SJÖWALL). In one half of the kidney there was observed under the fibrous capsule and facing outwards towards the hemorrhage in the fatty capsule a circumscribed hypernephroma as large as a hen's egg and largely necrosed. Under the microscope, the finding was verified through the presence of a thin layer of living, typical fat-bearing tumor cells close to the fibrous capsule.

The patient was discharged as cured on December 4.

Epicrisis. In this patient it was a question of a hypernephroma the size of a hen's egg in the left kidney as well as a spontaneous perirenal hematoma. The kidney was moderately displaced in a lateral direction. The acute illness was precipitated by the hemorrhage into the kidney bed.

After this encounter with two cases of spontaneous perirenal hematoma with displacement of the kidney, I have searched the literature for cases where this roentgenologic sign is mentioned. This feature was stated by LOEWENEK in 1935 and by SIMON in 1938 to be a roentgenologic sign of perirenal hematoma. (*A few* earlier authors have described cases of perirenal hematoma where the roentgen examination revealed a displacement of the kidney, but no particular attention was paid to the displacement.)

That the kidney becomes displaced when spontaneous perirenal hemorrhage is present can be directly observed at operation or at postmortem examinations. Thus, LAEWEN, in 1912, described the autopsy findings in a hemophiliac who died after a perirenal hemorrhage. A large perirenal hematoma which formed a large bulge into the abdominal cavity was present on the right side. "Auf der Höhe dieser Vorwölbung, die den ganzen Raum zwischen seitlicher Brustwand und Wirbelsäule ausfüllt, fühlt man vorn die Niere durch." The kidney had thus been displaced in a *ventral* direction. SCHLOSS also, in 1926, described a case of perirenal hematoma in which the kidney was found at laparotomy to have moved noticeably in a ventral direction.

It is difficult to furnish a definite answer to the question of how often there is a demonstrable alteration in the position of



Fig. 1. Case I. Urograms of the kidneys taken with the patient lying prone, without compression. Exposure 20 minutes after injection. Right kidney is displaced laterally. The inferior pole is not clearly visualized. The arched right ureter is also plainly outlined.

the kidney or the renal pelvis as the result of a spontaneous perirenal hematoma. Only a few cases have been examined by urography or retrograde pyelography. Dislocations of the kidney appear, however, to be a commoner occurrence than has previously been supposed. In 10 out of 18 cases submitted to urographic or pyelographic examination which I have assembled from the literature it was mentioned that the kidney was displaced. With the exception of case 9, all of the patients were proved either at operation or at autopsy to have been suffering from perirenal hematoma. When plain roentgenograms only were made, and urography or pyelography was not used, it was in most instances not possible to gain an exact idea of the position of the kidney on the affected side. In these cases the kidney silhouette was either unclear or entirely obliterated. Therefore, in the review of cases from the literature which now follows, I have not included patients from whom plain roentgenograms alone were obtained.

In the following 5 cases (nos. 1—5) of spontaneous perirenal hematoma collected from the literature the kidney was apparently not displaced to any noticeable extent. The patients were examined by urography or pyelography, or by both methods. In some instances, the descriptions of the urograms or the pyelograms are rather brief, but the authors in question obviously did not observe displacement. Only in the case of patients 1 and 4 are illustrations appended. To judge from these, the kidneys were in the normal position. In patients 2 and 5 subcapsular hematomas were present but the tunica fibrosa was intact. In these there can hardly have been a dislocation of the kidney, since hematomas below the capsule do not become very large. As regards ASCOLI's case, it is particularly stated that the kidney's position was normal.

1. (BONTHIUS.) A woman aged 55 with a large perirenal hematoma on the left side. Pyelographic examination of the left kidney was carried out and the calyces and renal pelvis were seen to be normal. The renal pelvis was situated in the upper half of a soft tissue shadow extending from the eleventh rib to a little below the crest of the ilium and measuring about 20 cm. (The large soft tissue shadow on the roentgenogram was produced by the kidney and the perirenal hematoma.) Judging by the location of the renal pelvis in the roentgenogram reproduced, the kidney was in all probability in its normal position. Nephrectomy of the left kidney was done. There were no changes in the excised kidney which could account for the hemorrhage.

2. (COPPRIDGE.) A woman aged 38. Urographic examination revealed a large, somewhat irregularly outlined kidney shadow on the

right side but in all other respects the roentgenogram showed normal conditions. Nephrectomy of the right kidney. A subcapsular hematoma with an intact fibrosa was present. Signs of glomerulitis were observed under the microscope.

3. (Ascoli.) Left-sided perirenal hematoma. Pyelographic examination revealed that the left kidney was in the normal position. The calyces and renal pelvis were not dilated. The calyces were rather long and the inferior calyx was irregular in shape. At a urographic examination carried out a few days later the flow was seen to be rather weak and delayed. Only the superior calyx was clearly visualized. The middle and lower calyces were only faintly visualized but the outlines seemed to be normal. Nephrectomy of the left kidney and delivery of the hematoma. The hemorrhage had in all probability originated in the suprarenal gland.

4. (Secrétan.) A man aged 26. The patient had a hydronephrosis on the left side with the extremely rare complication of a perirenal hemorrhage. The hydronephrotic renal pelvis on the left side was revealed by means of retrograde pyelography but no other abnormal features were observed. Nephrectomy and delivery of the partially organized hematoma. There was a rupture in the hydronephrotic sac from which the bleeding had originated.

5. (Haebler.) A woman aged 34. Plain roentgenograms and pyelograms showed normal conditions. At operation a subcapsular hematoma with the fibrous capsule intact was found on the right side. The hematoma was drained and the patient recovered.

In the following 10 cases of spontaneous perirenal hemorrhage (nos. 6—15), examined by pyelography or urography, the kidney on the affected side deviated from the normal position. In cases 7, 10, 14 and 15 the respective authors furnished no roentgenograms to illustrate the displacement of the kidney.

6. (Loewenek.) A 46-year-old woman with hypertonia. A mass developed at the site of the right kidney within a fortnight, and at the same time she had intermittent attacks of pain in the lumbar region. A plain roentgenogram revealed a dense shadow, and obliteration of the psoas major outline on the right side. There was no scoliosis. Pyelography disclosed that the right kidney was considerably dislocated in a medial direction. The renal pelvis was partially situated in front of two of the middle lumbar vertebrae with the point where the ureter leaves the pelvis approximately in the midline of the body. The position of the renal pelvis in front of the lumbar vertebrae was an indirect indication of the fact that the kidney had also been displaced ventrally. (No lateral views were taken.) There was also a moderate degree of rotation of the kidney around a sagittal axis. The superior pole of the kidney was more laterally situated than the inferior pole. At operation, a large hematoma was discovered. The patient recovered.

7. (WEVER and PERRY.) A man of 29, who was suffering from hypertension, with repeated attacks of pain in the kidney regions. Pyelography (right side) was done after an attack of pain in the right kidney region. According to the authors, this revealed lateral displacement of the renal pelvis. The renal pelvis also displayed diminished mobility on alterations in the position of the body. An operation was performed on a diagnosis of acute purulent perinephritis. This diagnosis was found to be incorrect, a perirenal hematoma being discovered instead. Nephrectomy was performed. The patient died some time later. Autopsy and histologic examination proved that he had periarteriitis nodosa.

8. (NAVRÁTIL.) A man aged 48 who became acutely ill with intense pains over the right kidney. A large ballotable mass was palpated in this region. A plain roentgenogram showed a homogeneous shadow at the site of the kidney. The silhouettes of the psoas muscle and the kidney on the right side were not distinguishable. By means of retrograde pyelography the right renal pelvis was established as normal in shape but both it and the proximal portion of the ureter were seen to be displaced a considerable distance in a lateral direction. In the operating room a large perirenal hematoma was found on the right side. Grayish yellow tumor masses were present at the site of the right suprarenal gland. Under the microscope these were seen to be of the nature of bronchial metastatic cancer. There were no metastases in the kidney. Considering the size of the hematoma the lateral displacement of the kidney was probably due in large measure to the hemorrhage, although the tumor must have been a contributory factor.

9. (JASIENSKI.) A hemophiliac aged 39. His illness started with severe pains in the right kidney region. At the same time a mass developed in this area. The patient was examined by urography and retrograde pyelography about one month after he fell ill. (At that time the mass was still present in the right kidney region.) Retrograde pyelography revealed slight deformation of the right renal pelvis and the calyces and moderate upward displacement of the right kidney. The patient recovered without an operation. The case was therefore not definitely confirmed but there seems every likelihood that it was a question of perirenal hemorrhage in a hemophiliac. The mass (the hematoma) became absorbed spontaneously within about 2 months.

10. (VON LACZKOVICH.) A woman aged 56. She became suddenly ill with nausea and severe pains in the right half of the abdomen. A diffuse mass was palpated at the normal site of the right kidney. Retrograde pyelography proved that the kidney and renal pelvis on the right side were displaced medially to such an extent that they were lying in front of the vertebral column. (This location is an indirect proof of the fact that the kidney had also been dislocated in a ventral direction.) The kidney was also rotated. At operation a few days later, a perirenal hematoma the size of a man's head was found on the right side as well as a tumor measuring 10 × 10 × 9 cm and intimately attached to the kidney pole. The kidney and the tumor were excised

downwards and that a kink has formed on the proximal part of the ureter. Beyond this kink the ureter is situated rather far towards the medial aspect and anterior to the outer parts of the lumbar vertebral bodies. Thus, it is displaced both medially and ventrally. Nephrectomy and delivery of the hematoma were carried out.

14. (HECKENBACH.) A man aged 51, who suddenly began to have pains in the right kidney region. A mass was palpated in this area. At the pyelographic examination it was found that the right kidney was displaced in a medial direction. The calyces were compressed. An operation was performed and the hematoma delivered. The patient died of anuria 3 days after the intervention. At autopsy a small Grawitz's tumor was found in the right kidney.

15. (T. B. MALLORY.) A 42-year-old man. He became acutely ill with pains in the right kidney region and hematuria. Retrograde pyelography revealed filling defects in the right renal pelvis. Urograms made 3 days later showed enlargement of the kidney shadow on the right side (especially the inferior pole). The right kidney and ureter were dislocated laterally. Nephrectomy was performed. The cause of the bleeding was found to be a small tumor in the inferior pole of the right kidney. Pathologico-anatomic diagnosis: Adenocarcinoma.

16. (CARVER. Case 1.) A man aged 43. A case of right-sided hydronephrosis with severe perirenal hemorrhage. Urographic examination showed no flow on the affected side. Only the right ureter was visualized in the pyelogram. According to CARVER's description the right ureter was displaced a considerable distance medially. Nephrectomy was difficult to carry out because of adhesions.

In two cases, nos. 17 (COUNSELLOR and EMMETT) and 18 (CARVER, Case 2), urographic examination revealed no flow of contrast fluid on the side where the perirenal hematoma was situated. In COUNSELLOR and EMMETT's case the cause was a hydronephrotic renal pelvis which had spontaneously ruptured. In CARVER's case hemorrhage in the suprarenal gland was the cause of the perirenal hematoma. (CARVER did not, however, continue the investigation for longer than 45 minutes.)

In some of the cases (8, 10, 14 and 15) and in the present author's second case the cause of the bleeding was obviously a primary tumor or metastases. These tumors, however, were not of such a size as to entirely explain the dislocation of the kidney; it must have been wholly or in part due to the perirenal hematoma. Cases of perirenal bleeding occurring in association with tumors so large that the size constituted the main reason for the displacement (*e. g.* PELS-LEUSDEN's case) have not been included in this review.

When perirenal bleeding occurs, the blood spreads readily through the loose layer of fat surrounding the kidney. The manner in which the blood becomes distributed and the place where the largest amount of blood accumulates, is decided by the location of the source of the bleeding (or the bleeding area), the size and rate of flow of the hemorrhage (the blood pressure is important), the thickness and structure of the fatty capsule, and the anatomy of the renal fasciae. It is these fasciae which constitute the chief obstacle to the spread of the effusion. In purulent perinephritis the pus spreads in a similar manner, although not at the same speed.

MITCHELL has studied the problem of the spread of effusions in the renal regions in experiments on cadavers. He injected a fine barium emulsion under a pressure of about 75 to 100 mm Hg. In one set of experiments the point of the needle was inserted between the fibrous capsule and the renal fascia and in another set between the posterior layer[1] and the fascia covering the front of the quadratus lumborum and the psoas major muscles (*i. e.* in the paranephric fat). He was able to follow the spread of the barium emulsion during the injection, on a radiographic screen. He then dissected the kidney region. An experimental investigation on cadavers does not correspond exactly to the conditions in living subjects but it can nevertheless yield valuable information.

In the first set of experiments, which is the most interesting from the standpoint of perirenal bleeding, the following observations were made. The contrast medium accumulated first in the loose fatty layer around the kidney and then spread without hindrance between both layers of the renal fascia, reaching as far as the diaphragm in an upward direction and extending down towards the true pelvis. The diffusion became more irregular in the loose tissue in the small pelvis. The anterior and posterior layers of the renal fascia unite at a definite point lateral to the kidney. This junction did not constitute any particular barrier to the spread of the contrast fluid in a lateral direction, the medium sometimes being pressed out into the abdominal wall between the transversus muscle and the transversalis fascia. Spread in a medial direction seemed to proceed with more difficulty. The contrast fluid could not be pressed over the midline to the

[1] The fascia renalis consists of an anterior and a posterior layer. They are termed in RAUBER-KOPSCH's textbook prae- and retrorenal fasciae.

opposite side (except low down at the inlet of the pelvis). Thus, there existed a strong barrier to the spread of fluids in a medial direction from the kidney bed. According to the findings of this investigation the investment of fascia surrounding the kidney is only open in a downward direction, not medially, upwards, or laterally. MITCHELL also found that the anterior layer of the renal fascia becomes attached to the vertebral bodies and intervertebral discs a short distance in front of the attachment of the posterior layer. The attachment of the anterior layer of the fascia is firm and in all probability constitutes the real barrier to the spread of fluids in a medial direction.

On the other hand, according to statements in a number of textbooks of anatomy, the investment of fascia surrounding the kidney is open both medially and caudally. It is stated that the anterior layer of the renal fascia in front of the great vessels (aorta, vena cava caudalis) unites with the anterior layer on the opposite side.

In RAUBER-KOPSCH's Lehrbuch und Atlas der Anatomie des Menschen (vol. II, p. 202—203, ed. 16, 1941), for instance, the following statement is made: "Da die Fascia retrorenalis medianwärts zusammenhängt mit der Psoasfascie und die Fascia praerenalis über die grossen Gefässe hinwegzieht, ist der von beiden Fascien gebildete 'Fasciensack der Niere' medianwärts und kaudalwärts offen."

In VON BARDELEBEN's Handbuch der Anatomie des Menschen (vol. 7: 1, p. 22—24) a similar statement is made by DISSE: "Demnach umschliesst die Fascia renalis eine oben und lateralwärts gut abgeschlossene, medianwärts und nach unten hin geöffnete Tasche, in der die Niere enthalten ist."

In CUNNINGHAM's Textbook of Anatomy, 1922 Edition, London, the same opinion is expressed: "This fascia (Renal Fascia) surrounds the kidney and a considerable amount of its fatty capsule in the form of a loose sheath, in which may be distinguished anterior and posterior walls. The sheath is open inferiorly and medially, but closed above and to the lateral side of the kidney by the apposition of its walls."

MITCHELL's presentation of the matter seems the most correct one, however. Additional evidence in support of it is the clinical observation that pus, in the case of perinephritis, or blood, in perirenal hemorrhage, rarely spreads across the midline to the opposite side.

Statements regarding the distribution and borders of perirenal hematomas are not very full in the surgical notes and autopsy records which have been published. It has not always been possible to locate the source of the bleeding with certainty. When it is known, a large accumulation of blood and clots is found in the vicinity. From this, the hematoma spreads into the fatty capsule of the kidney and envelops the kidney on all or several sides. *It should be stressed here that an especially large accumulation of blood is often encountered on the dorsal side of the kidney, without the source of the bleeding necessarily being situated dorsal to the kidney,* while smaller quantities collect between the anterior aspect of the kidney and the peritoneum. This is due partly to the fact that the layer of fat is thicker on the dorsal side of the kidney than on the anterior aspect and partly to the fixation relations between the kidney and the peritoneum. Further, it should be remembered that the hematoma can sink in a dorsal direction in these patients, who are often seriously ill and confined to bed for a considerable period. (SKARBY.) The hematoma can spread upwards and downwards for a long distance between the two layers of the renal fascia. The spread can take place without difficulty in a lateral direction also, since the union between the anterior and posterior layers of the renal fascia lateral to the kidney is not difficult to force. On the other hand, diffusion in a medial direction, across the midline, is rare. The renal fascia, however, does not constitute an absolute barrier; it can be broken through. The hematoma then continues to spread in a new space. In the case of the subcapsular hematomas the blood accumulates under the tunica fibrosa of the kidney. (This type of hematoma appears on the roentgenogram as an irregular kidney shadow.) If the size of the hematoma increases the fibrous capsule finally breaks and the hemorrhage continues out into the fatty capsule of the kidney.

The kidney does not always become displaced as the result of perirenal hemorrhage. (No alteration in position takes place in the case of the small bleedings, for instance.) But a dislocation very often does occur. If the source of the hemorrhage is situated on the dorsal side of the kidney the most likely direction for the displacement will be towards the ventral aspect. When the bleeding area is located ventrally there will be no particular dorsal dislocation since this is made impossible through the anatomic relations. If the bleeding point is on one of the sides of the kidney we find the kidney displaced medially, laterally, upwards, down-

wards, or in a combination of these positions, such as cranio-laterally. As, also, a large part of the hematoma sometimes collects dorsal to the kidney the displacements of the kidney in the frontal plane can be combined with a dislocation towards the ventral aspect. The alteration in position can also be complicated by rotation of the kidney. It is not only the size and distribution of the hematoma which plays a part in deciding the kidney's changes in position; the attachment apparatus of the kidney (*e. g.* fasciae and blood vessels) is also a factor of importance. If the kidney is attached by perinephritic adhesions it will become dislocated to a lesser degree and possibly also in a more atypical fashion. *In a case of perirenal hematoma, the displacement of the kidney to a certain extent furnishes a guide to the location of the source of bleeding, since the kidney generally becomes displaced away from the bleeding point.* (The occasional tendency of perirenal hematomas to accumulate dorsal to the kidney, even when the source of bleeding is not located dorsally, should be borne in mind, however.) When the cases mentioned in the literature, with alterations in the position of the kidney consequent upon perirenal hemorrhage (cases 6—15), were being studied, it was found that rotation of the kidney was mentioned in two instances (cases 6 and 10). The kidney was also displaced medially and ventrally in these two cases. Most of the displacements in the frontal plane were lateral (cases 7, 8, 12, 15 and my own 2 cases) or medial (cases 6, 10, 11 and 14). In case 13 there was a displacement medially of the ureter. The renal pelvis, on the other hand, could not be definitely established as being displaced medially or laterally. In one instance (case 16) the ureter only was visualized, and this was displaced towards the medial aspect. In 2 of these cases the displacement of the kidney had taken place upwards (case 12) or downwards (case 13). Finally, a moderate, purely upward displacement of the kidney was described in one case (case 9). Although the material is small, yet it is surprising that the number of cranio-caudal displacements of the kidney reported should be so small in comparison with those occurring in a medial or lateral direction. This is perhaps partly due to the fact that more notice is taken of a lateral or medial displacement of the kidney than of one where the shift has been in an upward or downward direction. Even under normal conditions the position of the kidney is subject to a considerable amount of variation upwards and downwards (as, for instance, when the different

respiratory phases are being followed or the body changes position). It is therefore more difficult to decide when an upward or downward displacement is to be regarded as abnormal. But it is also possible that medial or lateral dislocations really *are* commoner occurrences.

As a rule, anteroposterior views only were used in the examination of the cases under discussion. In one instance (case 12) lateral views were also taken. These furnished an admirable illustration of a considerable ventral dislocation not only of the kidney and the renal pelvis but also of the ureter, which was arching over the ventrally and anteriorly bulging soft tissue shadow. In at least two other cases (cases 6 and 10) it can be indirectly assumed that the kidney had been displaced ventrally. In case 11 the upper part of the ureter at least was dislocated in a ventral direction, and in case 13 also, the ureter showed partial ventral displacement. If lateral views had been taken in other cases, ventral dislocation of the kidney would undoubtedly have been discovered in many instances. The clinical observations of LAEWEN and of SCHLOSS, that a ventral displacement of the kidney takes place in connection with perirenal hematoma, are worthy of mention here. As has already been mentioned, in these five cases there had occurred, in addition to the ventral dislocation of the kidney or the ureter, displacements in the frontal plane.

Alterations in the position of the kidney have also been described in connection with perinephritis. (LAURELL, PEACOCK, MATHÉ, DEUTICKE, BARETZ, and others.) Especially in the case of the purulent forms when there is a considerable amount of pus collected around the kidney, displacements of the kidney similar to those occurring in connection with perirenal hemorrhages can be expected. PEACOCK, DEUTICKE, and BARETZ have all mentioned a ventral displacement of the kidney in these conditions. PEACOCK also maintains that abscesses are rarer on the anterior aspect of the kidney than on the posterior aspect.

Dislocation of the kidney in various directions occurs as the result of retroperitoneal tumors, suprarenal gland tumors, pancreatic cysts, subphrenic abscesses, scoliosis, and other pathologic states. Rotation of the kidney occurs especially often in connection with retroperitoneal tumors. A downward or medial displacement of the left kidney is common in connection with splenomegalia. It is not my intention, however, to discuss the displacements occurring in these conditions in the present paper.

Large perirenal hemorrhages are often found in traumatic conditions of the kidney. In recent years these conditions have been made the subject of urographic and pyelographic study to a greater extent than hitherto. (HAMMEL, DEUTICKE, HAREIDE, LJUNGGREN, and others.) Dislocations of the kidney are encountered in connection with these states also. These alterations in position have, however, not been accorded as much interest as the other roentgenologic findings in ruptures of the kidney.

Summary.

A report is made on two cases of spontaneous perirenal hematoma. In one instance the patient had chronic myeloid leukemia and in the other a tumor of the kidney (hypernephroma). The perirenal hematoma had caused the kidney to become dislocated in both patients. In connection with the description of these two patients, the author reviews other published cases of spontaneous perirenal hematoma where displacement of the kidney had resulted. The various ways in which the dislocations usually take place are also reviewed. The mode of spread and distribution of the hematoma in the kidney bed and retroperitoneal space are discussed, and in this connection reference is made to MITCHELL's experimental investigation on the spread of fluids in the kidney region.

From the practical point of view, it is of value in a case of spontaneous perirenal hematoma that a certain amount of information regarding the approximate location of the source of bleeding can be obtained by studying the displacements of the kidney.

Zusammenfassung.

Bericht über zwei Fälle von spontanem perirenalem Hämatom. Im ersten bestand eine chronische myeloische Leukämie, im anderen ein Nierentumor (Hypernephrom.) Das perirenale Hämatom hatte in beiden Fällen eine Verschiebung der Niere verursacht. In diesem Zusammenhang wird über veröffentlichte spontane perirenale Hämatome berichtet, bei denen eine Veränderung der Nierenlage stattgefunden hat. Es wird eine Zusammenfassung davon gegeben, in welchen Weisen die Verschiebungen gewöhnlich vorgehen. Die Verbreitung des Hämatomes im Nierenlager und im

Retroperitoneum wird diskutiert. Hier wird auf MITCHELLS experimentelle Untersuchung über die Ausbreitungsweise der Flüssigkeiten im Nierenlager verwiesen.

Von praktischer Bedeutung ist, dass man in einem Falle von spontanem perirenalem Hämatom aus der Dislozierung der Niere eine gewisse Auskunft über die ungefährliche Lage des Ausgangspunktes der Blutung erhält.

Résumé.

Voici deux cas d'hématome périrénal spontané. Dans le premier cas il s'agit d'une myelose leucémique chronique et dans le second d'une tumeur rénale (hypernephrome.) L'hématome périrénal dans les deux cas donnait lieu à un déplacement du rein. Après un compte rendu des cas publiés d'hématome périrénal spontané, dans lesquels un déplacement du rein a eu lieu, suit une discussion de la manière dont ces déplacements se produisent. Nous discutons le mode de propagation de l'hématome et son étendue dans l'espace périrénal et rétropéritonéal. Nous citons les recherches expérimentales de MITCHELL concernant la propagation des liquides dans la région rénale.

Il y a d'importance pratique qu'on peut obtenir, dans un cas d'hématome périrénal spontané, du déplacement du rein un certain renseignement concernant le siège approximatif de l'hémorragie.

References.

ASCOLI, R.: Arch. ital. di chir. 49: 225, 1938. — BARETZ, L. H.: Urol. & Cutan. Rev. 43: 399, 1939. — BONTHIUS, A.: J. A. M. A. 96: 523, 1931. — CARVER, J.: Proc. Roy. Soc. Med. 32: 547, 1938/39. — COUNSELLOR, V. S. and EMMETT, J. L.: Proc. Staff Meet., Mayo Clin. 11: 44, 1936. — COPPRIDGE, W. M.: J. Urol. 39: 733, 1938. — CUNNINGHAM's Textbook of Anatomy, 5th ed. London 1922. — DISSE (v. Bardelebens Handbuch der Anatomie des Menschen) vol. 7: 1. — DOLL, K.: Bruns' Beitr. z. klin. Chir. 147: 503, 1929. — DEUTICKE, P.: Ztschr. f. Urol. 34: 89, 1940. — Idem: Ibid. 34: 165, 1940. — FRIMANN-DAHL, J.: Röntgenundersökelser ved akutte abdominalsykdommer. Oslo 1942. — HAEBLER, H.: Deutsche med. Wchnschr. 54: 1078, 1928. — HAMMEL, H.: Ztschr. f. urol. Chir. 41: 502, 1935. — HAREIDE, I.: Acta radiol. 21: 292, 1940. — HASSELSTRÖM-HULTÉN: Uppsala Läk.förenings förh. 34: 229, 1928. — HECKENBACH, W.: Ztschr. f. Urol. 26: 395, 1932. — HEILMANN, P.: Centralbl. f. allg. Path. u. path. Anat. 40: 185, 1927. — Idem: Virchow's Arch. f. path. Anat. 277: 258, 1930. — HELLMER, H.:

Acta radiol. 16: 51, 1935. — Idem: Nord. Med. 3: 2891, 1939. — HERITAGE, K.: Proc. Roy. Soc. Med. 27: 1105, 1933/34. — HÜBNER, A.: Arch. f. klin. Chir. 145: 338, 1927. — JASIENSKI, G.: J. d'urol. 44: 487, 1937. — KAIJSER, R.: Uppsala Läk.förenings förh. 44: 283, 1939. — KJELLBERG, S. R.: Acta radiol. 19: 273, 1938. — KOLBENHEYER, Z.: Ztschr. f. urol. Chir. 44: 90, 1938/39. — v. LACZKOVICH, A.: Bruns' Beitr. z. klin. Chir. 168: 24, 1938. — LAEWEN, A.: Deutsche Ztschr. f. Chir. 113: 369, 1912. — Idem: Ibid. 118: 374, 1913. — LAURELL, H.: Uppsala Läk.förenings förh. 26: 23, 1921. — Idem: Ibid. 43: 239, 1938. — Idem: Om röntgen vid akuta bukfall. Uppsala 1939. — LENK, R.: Deutsche Ztschr. f. Chir. 102: 222, 1909. — LJUNGGREN, E.: Ztschr. f. Urol. 30: 650, 1936. — LOEWENECK, M.: Deutsche Ztschr. f. Chir. 244: 209, 1935. — MACKENZIE, D. M.: J. Urol. 23: 535, 1930. — MALLORY, TR. B.: New England J. Med. 218: 685, 1938. — MATHÉ, CH. P.: Am. J. Surg. 38: 78, 1937. — MITCHELL, G. A. G.: Brit. M. J. 4118: 1135, 1939. — NAVRÁTIL, J.: Zentralbl. f. Chir. 64: 1758, 1937. — PEACOCK, A. H.: Surg. Gynec. & Obst. 48: 757, 1929. — PELS-LEUSDEN, F.: Zentralbl. f. Chir. 61: 1559, 1934. — POLKEY-VYNALEK: Arch. Surg. 26: 196, 1933. — RAUBER-KOPSCH: Lehrbuch der Anatomie des Menschen. Leipzig 1941. — RICKER, G.: Deutsche Ztschr. f. Chir. 114: 287, 1912. — SCHLOSS, W.: Wien. klin. Wchschr. 39: 1306, 1926. — SECRÉTAN, M.: Schweiz. med. Wchnschr. 60: 247, 1930. — SIMON, O.: Fortschr. a. d. Geb. d. Röntgenstrahlen. 59: 178, 1939. — SKARBY, H. G.: Personal communication. Uppsala 1944. — WEVER, G. K. and PERRY, I. H.: J. A. M. A. 104: 1390, 1935.

(Exhaustive lists of references are supplied in DOLL's and in POLKEY-VYNALEK's publications.)

From Diakonissestiftelsen, Copenhagen, Surgical Department B.
(Chief Surgeon: M. FENGER, M. D.)

Ectopic Course of the Ureter Attended with Hydronephrosis.

By

POUL LYKKE GREGERSEN.

Hydronephrosis caused by aberrant renal vessels has been known since RAYER described it in "Traité des maladies des reins" of 1841.

The last decades have brought a new series of reports on hydronephrosis also arising from an anomaly of the vessels, an anomaly which, however, appears as an ectopic course of the ureter to the observer.

The only Danish literature on the subject is contained in a work on aberrant renal vessels by STRANDGAARD who mentions one of the following cases reported by foreign authors (v. GIERKE) without, however, distinguishing it further from the group of aberrant vessels.

Considering the clinical interest attached to this extremely deviating course of the ureter, the writer below reports the first case observed in Denmark, supplemented with a survey of earlier cases published in other countries.

Writer's Case.

A 51-year-old married woman, admitted for observation for nephrolithiasis. She had been healthy in her youth, had had 6 natural deliveries and 3 abortions and was now in her climacteric.

At the age of 33 the patient had been admitted to the Sundby Hospital under a diagnosis of cholelithiasis and pancreatitis. While lying there she voided a number of small gall stones. Conservative

treatment was applied, and the patient has not been troubled by this disease since.

Microscopic examination of the urine at that time failed to reveal any pathologic features.

2 years prior to her present disease a mild diabetes mellitus had been diagnosed and treated with diet.

Present disease: 2 months before her admission she had been taken ill with mild, bilateral pain in the loins accompained by frequent and painful urination. The temperature rose to 39° centigrade. Following treatment with sulfonamide the patient remained symptomless for a fortnight, whereupon pain and dysuria recurred, this time attended with gross hæmaturia.

On admission the hæmaturia had ceased and the patient only complained of mild, bilateral pain in the loins.

Objective examination: The patient is extremely adipose, but otherwise of healthy appearance. No tenderness in the kidney regions and the kidneys are impalpable.

Microscopic examination of the urine: + erythrocytes, + leucocytes, ÷ albumin, ÷ sugar.

Blood urea 21 mg. per cent., blood pressure 160/80, fasting blood sugar 138—187 mg. per cent.

Intravenous pyelography: Natural excretion on the left side. On the right side the excretion is rather slow. The pelvis is greatly dilated and the calyces enlarged. Filling of the ureter is not definitely demonstrable, but immediately below the pelvis there is a suspicion of a roundish, plum-sized shadow which possibly represents a segment of the ureter.

Just below the linea terminalis on the right side there is a shadow, the size of a large orange seed, which might suggest a calculus. We are not prepared to say whether the shadow actually is in the ureter, but the localization is indicative of such a situation (sd. V. Finsen).

On the basis of the view of a hydronephrosis caused by occlusive ureteral calculus, an operation was suggested to the patient who agreed.

Operation: Under spinal percaine anæsthesia an oblique incision was made on a level with the right crest of the ilium, thus approaching the ureter which was found immediately.

The ureter was of a completely normal thickness, but the presumed concretion was not to be found, and therefore the course of the ureter was followed upwards.

The ureter proved to course medialward across the anterior side of the inferior vena cava whereupon it passed posterior to the vein.

A prolongation of the incision upwards exposed the greatly distended renal pelvis and tracing of the ureter downwards confirmed that *the ureter actually did pass posterior to the inferior vena cava.*

There was some fibrous tissue at the crossing, but no constriction and no distention of the segment of the ureter above the crossing. Since, furthermore, a quite appreciable amount of renal tissue remained, nephrectomy was not considered to be indicated, but it was deemed sufficient to detach the ureter from the fibrous tissue. This procedure left a small hole on the inferior vena cava which, however, was closed immediately by knotted suture. On account of the patient's condition a plan of correcting the ureter by a plastic operation had to be abandoned because of hæmorrhage and the risk of the detachment (sd. M. FENGER).

The post-operative course was uneventful and the patient was feeling well on discharge.

On ambulant after-examination 9 months later the patient was completely well and had had no pain since the operation.

Intravenous pyelography revealed the hydronephrosis to be unchanged.

Micr. examination of the urine: : erythrocytes, + leucocytes, -: albumin.

Blood urea 40 mg. per cent., blood pressure 160/90.

Summary of the Case.

A 51-year-old woman was admitted, believed to be suffering from renal calculus. Roentgenograms showed a right-sided hydronephrosis and indicated an occlusive ureteral calculus. The operation failed to reveal a stone, *but the right ureter was found to coil around the vena cava* and to be embedded in fibrous tissue.

A control roentgenogram 9 months later revealed that the detachment of the ureter had been of no effect on the size of the hydronephrosis, but the operation had relieved the patient of pain.

Review of All Reported Cases.

Reviewing the literature the writer succeeded in finding 27 similar cases. This review is, however, only complete up to 1938, the reports of three cases — published after that time — not having been accessible on account of the war. For the same reason the writer has only had access to a limited part of the world literature after 1940.

About two-thirds of the cases have been observed during the last decade, which is an increase so considerable that this form of anomaly seems to be a factor to be taken into consideration as a differential diagnosis in cases of hydronephrosis of an obscure ætiology.

A common feature in all such cases is the coiling of the ureter around the inferior vena cava or another large venous branch acting as the inferior vena cava, since more profound abnormalities do occur.

The ectopic course only affects the abdominal portion of the ureter. From a position medial to the vein the ureter crosses it laterally, as a rule in order to take a normal course in the pelvis.

It is evident from the schematic representation that hydronephrosis has been an attendant condition in the majority of cases.

Exceptions are formed by two children, one of whom was stillborn and the other a few weeks of age. But in adults too, the condition has been observed without an attendant hydronephrosis, so presumably the coiling of the ureter only is a predisposing factor, whereas infection and ptosis have a releasing effect on the formation of hydronephrosis, considering that one of these factors almost invariably has been present in the cases observed clinically.

Unfortunately only one author refers to a stricture at the crossing, but the pathologic significance of the anomaly is distinctly indicated by its extremely frequent occurrence in connexion with hydronephrosis as well as the decrease in hydronephrosis demonstrable after surgical correction of the course of the ureter.

Only one author (ÜBELHÖR) has expressed a doubt, referring to the numerous incidental observations of hydronephroses, in his opinion, of a doubtful size. His doubt has not, however, prevented him from performing a plastic operation correcting the course of a ureter.

So far the anomaly most frequently has been observed in males, but the small number of cases does not justify a conclusion as to the absolute frequency, and a sex difference does not seem likely when we consider the mode of origin.

Moreover, the anomaly has only been observed on the right side, once on both sides, but never on the left side only.

An explanation of this phenomenon is given under the heading "Ætiology".

15 cases have been discovered in the course of routine autopsy or dissection, and 9 during operations performed on the basis of other diagnoses.

Finally, 3 cases cannot be classified, since the literature is inaccessible.

Table I.

Name of Author	Year	Sex	Age	Found by	Side	Hydro-nephrosis	Clinical sign.
Hochstetter	1893	M	a few weeks	Dissection	right	÷	÷
Gladstone	1905	M	stillborn.	Dissection	bilateral	÷	÷
Kolisko	1909	M	55	Autopsy	r	+	÷
Gladstone	1911	M	48	Dissection	r	+	÷
Jacobson	1927	M	72	Autopsy	r	+	÷
Jacobson	1927	M	1	Autopsy	r	÷	÷
Wicke	1927	M	58	Autopsy	r	÷	÷
Kengyel	1928	F	57	Autopsy	r	+	÷
Gierke	1928	M	16	Autopsy	r	+	÷
Skamnakis	1931	M	50	Autopsy	r	+	÷
Kimbrough	1934	M	20	Operation	r	+	+
Rotter	1935	?	?	Autopsy	r	÷	÷
Rotter	1935	M	49	Operation	r	+	+
Randall & Campbell	1935	F	25	Operation	r	+	+
Randall & Campbell	1935	F	55	Operation	r	+	+
Derbes & Dial	1936	?	adult adult	Dissection	r	+	?
Derbes & Dial	1936	?		Autopsy	r	+	?
Übelhör	1936	F	34	Operation	r	+	+
Berbes & La Nasa	1937	F	42	Operation	r	+	+
Shih	1937	M	44	Operation	r	+	+
Wren	1937	M	adult	Autopsy	r	÷	÷
May	1938	M	17	Operation	r	+	+
Antopol & Yelin	1939	?	?	?	?	?	?
Pick & Anson	1940	?	?	?	?	?	?
Harriel	1940	M	46	X-ray & Operation	r	+	+
Harbach	1940	?	?	?	?	?	?
de Carlo	1941	M	60	Autopsy	r	÷	÷
Own Case	1944	F	51	Operation	r	+	+

Review of All Reported Cases in Chronologic Order.

Classification.

The cases are divisible into 4 groups according to the development of the inferior vena cava. The largest group comprises all cases in which the appearance of the inferior vena cava is indistinguishable from the normal.

These cases have been published by Hochstetter, Gladstone, Kolisko, Kengyel, Jacobson, Skamnakis, Kimbrough, Randall & Campbell, Randall & Campbell, Derbes & Dial, Derbes & Dial, Derbes & La Nasa, Shih, Wren, May, and

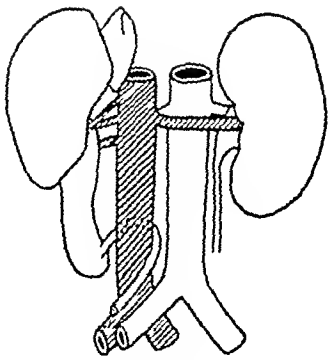

Type I.

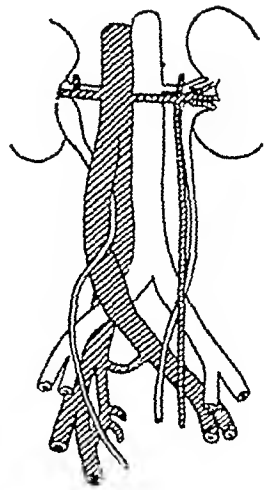

Type II.

Type III.

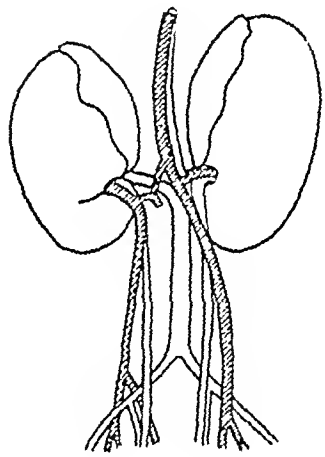

Type IV.

Types I, II and III anterior aspect, Type IV posterior aspect.

Fig. 1. Typical representatives of the 4 groups reproduced from H. ROTTER.

DE CARLO (in chronologic order). The writer's case also belongs to this group.

The 2nd group includes the cases in which the function of the inferior vena cava, up to the inosculation of the venae renales, rests with two thin, interlaced, mutually anastomosing veins, so the ureter is surrounded by a venous circle.

WICKE, v. GIERKE, and ROTTER have described this kind of anomaly.

In the 3rd group too there are two venous branches below the inosculation of the venae renales, which branches, however, take a course which makes a right and left inferior vena cava in contradistinction to the 2nd group which presented a right-sided duplicate.

ROTTER and HARRILL have each reported one case.

Group 4 is represented by one case, so far the only one exhibiting a right and left inferior vena cava, each with a retrocaval ureter.

The observation was made by GLADSTONE in the case of a fetus acardiacus.

Operations.

Plastic operations correcting the course of the ureter have been performed in 4 of the 9 operated cases, resulting in the disappearance or decrease of the hydronephrosis in 3. In one case the hydronephrosis remained unchanged, but the ureter was passable at the site of the suture and the patient was relieved of pain.

Stricture has in no case been observed after the operations, one of which was followed up for 2 years. The briefest follow-up was 7 months.

At the operations the ureter has been cut either at the crossing or at its departure from the renal pelvis. After freeing the ureter from the vena cava and establishing a normal course, end to end anastomosis is made around a catheter leading out through a nephrostomy, pyelostomy, or through the bladder. The catheter is removed on the 6th to 14th post-operative day.

One of the authors (HARRILL) points out the importance of avoiding a rotation of the ureter and of abstaining from cleaning a larger portion of the ureter than necessary, especially when freeing it from the vena cava. Comparing these 4 operations with the experience gained in other fields of ureteral plastic either in clinical practice (ABRAHAMSEN, WILDBOLZ, ÖSTLING) or in experimental surgery (WILDBOLZ), retrocaval course of the ureter too must be considered as belonging to conservative renal surgery in cases where the diagnosis has been passed early enough to save functional renal tissue. In cases where the inferior vena cava is substituted by two thin venous branches it is an easy matter to ligate and resect the branch encircled by the ureter.

When trying to free the ureter from a solitary vena cava, it is a reassuring knowledge that, facing an irreparable injury to the vein, one may ligate the vena cava below the venae renales without disastrous consequences (BÖTTGER, WHITTENBERG & HUGGIN).

Diagnosis.

The syndrome apparent in the clinically observed cases does not differ from what is known of other forms of hydronephrosis.

The main symptom consists of periodical or more constant pain, as a rule localized to the same, less frequently to the opposite lumbar region, radiating to a varying extent towards the external genitals or the thigh. In rare cases the pain is localized to the right iliac fossa or below the right costal border.

The pain as a rule is dull — like a permanent feeling of fatigue — pricking or colicky.

The most common attendant symptoms are pollakiuria, vesical tenesmus, or hæmaturia, which may be a conspicuous symptom in connection with pyuria.

An objective examination often reveals tenderness in the kidney region and sometimes the lower pole of the enlarged kidney is palpable.

It is, however, the roentgenogram alone, especially the retrograde pyelogram revealing the ureter in its entirety, which affords a possibility of passing or at least surmising the diagnosis.

On the characteristic, retrograde pyelogram the ureter is directed medially towards the spine in a backward convex arch after leaving the pelvis, and the upper third of the ureter is situated considerably more to the medial side than usual, a small portion reaching beyond the midline.

In the lateral plane the upper segment of the ureter is projected in front of the corpora vertebrarum, whilst the usual projection falls on the lateral surfaces of the corpora.

HARRILL, the only author who has placed the diagnosis preoperatively, maintains that it is possible to decide from stereoscopic roentgenograms whether the radius of the ureteral curvature is great enough to include the vena cava.

Difficult ureteral catheterization by some authors is taken as a support for the diagnosis, but it can hardly be attributed with real significance in differential diagnosis.

Ætiology.

The explanation of the ectopic course of the ureter obviously must be traced to the embryo, but it was not until embryologic studies were made of the development of the inferior vena cava that an explanation was arrived at.

The fundamental investigations were made by HOCHSTETTER whose work usually is quoted. In principle his theories and those advanced by later investigators are not conflicting. As mentioned above, the *essential cause of the anomaly is to be sought in an abnormal development of the inferior vena cava and not in an anomaly of the urinary tract* which one might be tempted to assume when bearing in mind the ascension of the kidney in fetal life.

The venous system in the lower part of the body of an embryo of only 4 mm. is differentiated into 3 pairs of longitudinal venous branches, mutually connected by transverse anastomoses. Taken from the lateral aspect the veins are: vena cardinalis posterior, vena supracardinalis, and vena subcardinalis. Vena supracardinalis is of a more dorsal position than the other two. The anlage to the kidney which develops later, grows from its original location in the pelvis through this anastomosis plexus towards its future site in the lumbar region. Therefore, the kidney and ureter of a 15 mm. fetus are surrounded by a venous circle placing the kidney dorsomedial to the vena cardinalis posterior.

During normal development the segment of the v. card. post. situated anterior to the kidney and ureter atrophies and is substituted by the postrenal segment of the vena supracardinalis which thus forms part of the inferior vena cava.

Failing this atrophy of the prerenal segment of the vena cardinalis posterior, the result is an anomaly like the one described, *i. e.* like the cases classed in group I. The reason for this failure must be sought in the fact that the atrophy normally occurs at a late date, which facilitates deviations from the normal.

The phenomenon that the anomaly almost exclusively has been encountered on the right side is considered to be due to the fact that the atrophy occurs later on the right side which, therefore, becomes still more exposed to disturbances in the normal development.

In case the atrophy fails to appear on both sides, the result is an anomaly like the one observed by GLADSTONE, the only representative of group IV.

A venous circle around the ureter, as seen in group II, is a consequence of a lacking atrophy and the persistence of the right vena supracardinalis as another main route for the blood stream.

The type known from group III, on the other hand, owes its existence to the persistence of the left vena supracardinalis as well as a lacking atrophy of the posterior vena cardinalis.

Normally, vena supracardinalis as well as vena subcardinalis atrophy or persist only in the form of veins of a small calibre.

A total of 7 variants of the inferior vena cava have been encountered in man, but only the 4 mentioned above involve the possibility of the ectopic, retrocaval ureter.

Summary.

The writer reports a case of ectopic, retrocaval ureter attended with hydronephrosis.

Mention is made of earlier observations reported in the literature, and the possibility of diagnosis and treatment is dealt with.

Zusammenfassung.

Ein Fall von mit Hydronephrosebildung verbundenem, ektopischem, retrokavalem Ureterenverlauf wird beschrieben.

Frühere Beobachtungen sowie die Möglichkeiten einer Diagnose und Therapie werden besprochen.

Résumé.

L'auteur décrit un cas de parcours ectopique de l'uretère dans la partie postérieure du cavum, accompagné d'hydronéphrose.

Il rapporte des observations antérieures et étudie les possibilités de diagnostic.

References.

1. Abrahamsen, H.: Ugeskr. f. Læger. 98: 1936, 261. — 2. Antopol, W. & G. Yelin: Urol. & cutan. rev. 43: 1939. Inaccessible, quoted in Z.blatt f. die ges. Chir. 1940. — 3. Broman, I.: Die Entwicklung des Menschen vor der Geburt. — 4. Böttger: Der Chirurg. 13: 1941, 84. — 5. Carlo, J. de.: Journ. of Urol. 45: 1941. Inaccessible, quoted in Z.blatt f. die ges. Chir. 1941. — 6. Derbes, V. J. & M. J. La Nasa: Urol. & cutan. rev. 41: 1937, 172. — 7. Derbes, V. J. & Dial, J.:

Journ. of Urol. 36: 1936, 279. — 8. GIERKE, E. v.: Ztschr. f. Urol. 25: 1928, 279. — 9. GLADSTONE, R. J.: Journ. of Anat. & Phys. 45: 1911, 225. — 10. HARBACH, F. A.: N. Y. State J. Med. 44: 1940. Inaccessible. — 11. HARRILL, H. C.: Journ. of Urol. 44: 1940, 450. — 12. HOCHSTETTER, F.: Morph. Jahrbuch 20: 1893, 543. — 13. JACOBSON, V. C.: Arch. of Pathology 3: 1927, 203. — 14. KENGYEL, H.: Ztschr. f. Urol. 25: 1928, 415. — 15. KIMBROUGH, J. C.: Journ. of Urol. 33: 1935, 97. — 16. KOLISKO, F.: Anat. Anz. 34: 1909, 520. — 17. MAY, F.: Ztschr. f. Urol. 32: 1938, 316. — 18. PICK, J. V. & B. J. ANSON: Journ. of Urol. 43: 1940. Inaccessible. — 19. RANDALL, A. & E. W. CAMPBELL: Journ. of Urol. 34: 1935, 565. — 20. ROTTER, H.: Ztschr. f. Anat. und Entwickl. 104: 1935, 456. — 21. SHIH, H. E.: Journ. of Urol. 38: 1937, 61. — 22. SKAMNAKIS, N. S.: Anat. Anz. 1931, 50. — 23. STRANDGAARD, H.: Hosp. Tid. 73: 1930. — 24. ÜBELHÖR, R.: Ztschr. f. Urol. 30: 1936, 769. — 25. WHITTENBERG, J. L. & C. HUGGIN: Arch. of Surgery, 41: 1940, 1331. — 26. WICKE, A.: Ztschr. f. Anat. & Entwickl. 84: 1927, 524. — 27. WILDBOLZ, E.: Ztschr. f. Urol., Chir. & Gyn. 45: 1931, 31, — 28. WREN, J. C.: Anat. Record 68: 1937, 389. — 29. ÖSTLING, K.: Acta chir. scand. 83: 1939, 74.

From the Red Cross Hospital of Finland.
(Physician-in-Chief: Docent AARNO SNELLMAN),
and the Finnish Athletic Medical Association
(Chairman: Professor S. A. BROFELDT †).

Elbow Injuries of Javelin-Throwers.

By

WILLE WARIS.

Behind the unparalleled achievements of present-day athletics lie many years of hard training. The continued practice of such a special form of athletics as javelin-throwing results in exceptional strain on the limbs and particularly the joints which are used in the act of throwing. In addition, the limbs are subjected to repeated injuries.

In consequence, javelin-throwers are as I shall attempt to demonstrate in the following, subject to certain chronic conditions which are comparable to occupational diseases and the knowledge of which is useful to the physician and essential to the surgeon. Besides, the pathogenesis of these changes in the joints is of particular interest. The question is: should they be regarded as the results of repeated traumas or of continuous wear and strain?

Historical survey.

WILHELM BAETZNER (1936), in his study on the common ailments and changes in the joints of athletes, discovered three kinds of articular changes as revealed in the roentgenograms:

1. Acular projections on the margin of the articular surfaces.
2. Para-articular areas of ossification.
3. Intra-articular free bodies.

He identified these changes in the joints caused by athletics in young persons with these changes in the joints resulting from hard work in certain occupations (*e. g.* pneumatic-drillers) and

with arthritis deformans in elderly persons. According to BAETZNER all the changes he noted were not either caused by accidents or the results of non-coordinated effort, but were the sum total of a lasting hyperphysiologic exertion. He even compared these changes to march fractures. In his opinion, the constant battle to break records waged by the athletes of today makes hyperphysiologic demands on the motor organs. A disproportion arises between the wear on the organism and its physiologic regeneration, a disproportion which is first manifested in the cartilage surfaces of the joints. The more one-sided and limited the training and competition, the sooner these changes appear and the more severe form they take.

In 1934 F. HEISS published a study on the elbow joints of athletes. He found elbow changes in 30 percent of 930 athletes, who had been examined roentgenologically. Forty-one of those examined were javelin-throwers, whose average record was about 50 metres. Roentgenologic changes were noted in 27 but only 10 of them had pains in the joints and 4 experienced a considerable limitation in extension. Six had small loose ossified bodies at the tip of the olecranon, 3 had a spurlike projection at the insertion of the triceps brachii extensor and 10 had small areas of ossification below the coronoid process. Fourteen had intra-articular changes at the edge of the trochlea humeri. On the basis of his research, HEISS fully agreed with BAETZNER's theory concerning the origin of changes in the joints.

The opposite point of view was stated emphatically by KNOLL and MATHIES, who regarded these changes as the after-effects of injuries and accidents. In their investigations they found the changes in the joints in athletes, which according to BAETZNER could be considered as diseases resulting from sport (Sportschäden) in only about three percent of the cases examined. In Germany this matter was a subject for discussion, both points of view having their adherents. I have not found the subject discussed in the English or the Scandinavian literature.

Present investigation.

As Finland is the home of about 80 percent of all the javelin-throwers whose record have exceeded 70 metres, I was tempted to make a study of the changes in the elbow due to javelin-throwing among the athletes who had achieved such high records.

Material.

My series comprises seventeen accomplished javelin-throwers, each of whom had his record near the world record of the time or broke it (the average record was 70.29 metres). In order to determine the later changes, I included four such record holders who were champions twenty to thirty years ago. A study which I conducted 1939—40 and completed during the last war, included in addition to an athletic history and a description of each subject's type of physique, a clinical and roentgenologic examination of both elbows and shoulder of the arm used in throwing. The data in the various cases is presented in Table 1.

Results of the Examination.

Facts revealed by the athletic history.

All the subjects began to express their talent for throwing when they were young, they could throw stones and balls farther than other boys of their age. They did not begin to compete until the age of twenty, and not until after six to nine years of competition did they achieve their best results.

What all of them had in common was that after the first year of competition, the elbow joint was so painful, that it was necessary to abstain from javelin-throwing for some time. The same kind of injury recurred in most of the cases just as severely two or three years later. All of them described this soreness as the result of a particular unsuccessful throw, *i. e.* it resulted from an accident rather than from a gradually increasing ailment or over-exertion. They considered that the soreness was due to a lack of preliminary training, or at least insufficient preparatory training.

They all described the soreness in the same way: A shooting pain is felt in the elbow while the javelin is being thrown and immediately thereafter swelling develops over the whole joint or in the inner bend of the elbow. Many victims stated that they were unable to extend the arm to its full length and that rotation of the forearm also was painful. The swelling and the tenderness usually passed off in a week or two, but as a rule, it was necessary to give up the sport for three to five weeks; in four cases more than one year's abstention was necessary. The shoulder was

Table 1.

Case	1	2	3	4	5	6	7	8	9	10	11	12	13	14	15	16	17
Height in cm	181	186	180	177	179	186	180	184	190	180	179	175	177	178	181	170	178
Weight in kg	79	76	78	78	82	78	80	85	82	72	85	76	67	73	82	60	74
Age at which competitive activity was started	19	20	19	17	19	20	18	20	17	18	20	18	18	16	18	19	20
Age at which record was broken	24	27	25	26	23	29	23	26	25	28	24	24	23	28	21	24	32
Year of competitive activity in which first elbow injury occurred	1.	1.	1.	2.	1.	1.	1.	1.	1.	2.	1.	1.	4.	1.	1.	1.	11.
Year of recurrence of injury	5.	2.	—	3.	2.	3.	3.	5.	5.	9.	3.	2.	6.	9.	2.	2.	13.
Year of best performance	5.	7.	6.	9.	4.	9.	5.	6.	8.	10.	4.	5.	5.	12.	3.	5.	13.
Record in metres	78.70	77.23	77.01	73.50	72.16	72.79	72.15	71.73	71.22	70.51	67.52	66.84	65.92	67.00	65.50	64.64	60.45
Functional changes in elbow-joint	—	+	—	—	—	—	—	—	—	—	—	—	—	—	—	—	—
Roentgenologic changes in olecranon	+	+	+	+	+	—	—	+	—	+	—	+	+	+	+	—	—
Other roentgenologic changes	—	—	—	—	—	—	—	—	+	—	—	—	+	—	—	—	—

sprained in four cases, in two of which the sprain caused discomfort every time the patient threw the javelin thereafter.

Almost all of the javelin-throwers examined had one thing in common: having injured their elbows two or three times, having suffered the pains resulting from these injuries and having taken the compulsory rest, they finally reached the point where their elbows were so benumbed that no kind of strain whatsoever seemed to have any effect on them, and were able to practice their sport endlessly without any more pain.

Thus, in the athletic history of all the javelin-throwers I examined, there was a definite trauma during the first year of competition followed by a few weeks during which the victim could not throw. In most of the cases the complaint recurred and the elbow joint eventually became so insensitive that even strenuous throwing was endurable.

Physique.

All the javelin-throwers were tall and robust (average height, 180.5 centimetres; average competition weight, 76.9 kilograms). The bones and joints were of heavy build, the muscles of the upper extremities well-developed and symmetrical. No difference whatsoever could be ascertained between the physique of those in whose elbows the clinical and roentgenologic changes were noted and of those whose joints were free from symptoms. Thus there were no factors in the physique of the patients that would indicate a disposition to changes in the elbows.

In all the cases I examined the period between the first contest and the medical examination was enough to permit any changes that possibly might have arisen during that time to have become manifest.

Clinical changes in the elbow.

Limitation of extension of about 30 degrees was observed in only one case (No 2), which also showed an even thickening around the whole joint. Thickening extending from the medial epicondyle toward the bend of the elbow was observed in four cases. Neither palpating nor handling the joint evoked tenderness in any case and cracking was noted in one case only. Thus, clinical examination revealed only a few very minor changes, which in no way

incapacitated the subjects in their daily work and hardly even in competitive throwing.

Roentgen changes.

1. No intra-articular changes were observed in any case.
2. Changes in the olecranon were seen in 12 cases.
   These form a series of changes of different stages in the olecranon:
   a) Transverse fracture of the olecranon, which had healed into a dislocated position (Case 2). Total pseudarthrosis had been noticed in this case in 1936 and now, as mentioned above, a 30 degree limitation of extension. (Fig. 1.)
   b) Complete detachment of the triangular tip of the olecranon. (Cases no 1 and 15, Fig. 2.)
   c) A detached clear shadow blot with bone design at the tip of the olecranon. (Cases 3, 4, 8 and 13, Fig. 3.)
   d) Tip of the olecranon irregular and rough. (Cases 5,9, 10, 12 and 14.)
3. Other roentgen changes:
   A calcium shadow with bone design beside the medial epicondyle. (Case 9, Fig. 4.)

In five cases the roentgenologic findings were negative. The changes visualized by the X-ray consisted of traces of apparent avulsion rupture fractures in bones and of splinters at different stages, which in general, were extra-articular. In short, ruptures of the olecranon and the ligaments of the joint, as well as of the capsules, apparently caused by, for example, such mechanisms as striking, twisting and distortion and their subsequent scars and calcification.

Comparison of the results of examination.

	Examination by Heiss	Examination by the writer
Number of cases examined	41	17
Average records in metres	50	70
Pains in the joint	10	—
Limitation of extension in degrees	4	1
Roentgen changes:		
Total	27	12

Olecranon fractures	—	1
At the tip of the olecranon	6	10
At the insertion of triceps brachii extensor	3	—
At the border of the trochlea humeri (intra-articular)	14	—
In the medial border of the articular surface of the ulna	15	—
In the coronoid process	12	—
On the distal aspect of the medial epicondyle	10	1

About twenty-five percent of the men examined by HEISS had pains in the joint, whereas none of my cases exhibited this symptom. Both series contain approximately the same number of cases with roentgen changes. (HEISS, about 65 percent, my series about 70 percent.) But the essential difference is, that I was not able to verify intra-articular changes in any single case, whereas HEISS found them in fourteen cases.

The rôle of the elbow in throwing the javelin.

In order to explain the changes ascertained in my examination, there is perhaps reason to make a closer examination of the function of the elbow in javelin throwing and these typical strains to which the elbow is subjected in this sport.

Style.

The best results have been attained by the so called over-shoulder throw (bent-arm carry) which is nowadays most commonly employed and which has been devised and developed by Finnish javelin-throwers. The straight-arm carry devised by MYYRÄ in his time and the hop form used by the Americans actually only differ from the bent-arm carry in the running start, the footwork and the delivery of the javelin during the initial run, but in all these *the ordinary throw and the arm action are quite similar.* And although every good thrower has individual characteristics and small specialities in his own style, the formative mechanism of changes of the elbow may nevertheless be regarded on the whole as the result of the same kind of a throw without going into detailed explanation of the throw.

The function of the elbow and the strain applied to it.

The appreciable improvement of the results in javelin-throwing is due to a great extent to the fact that the effective use of the running start, as well as the coordination of the whole body, its vigorous turning at the point of delivery and the jump after the javelin, have been learnt. The task to the arm is to perform the arm action, which is closely connected with the motion of the body and of the right shoulder. The ordinary throw begins with the vigorous forward bending of the body. During the throw the right shoulder is turned forward, followed by the arm, the elbow of which is flexed and foremost. In the meantime, the elbow moves along the side in a curve, in doing which the centrifugal force has a tendency to swing the forearm with the javelin out towards the right, and at the same time the weight of the javelin in the hand tends to flop the forearm backwards, the javelin at the time still being in slower motion than the upper arm.

Thus, the elbow does not act here as a hinge joint, instead a considerable twist and trip-up occur which entails a special strain on the inner edge of the joint, the medial ligament (lig. collaterale ulnare) and the pronator muscle (m. pronator teres).

This strain upon the inner edge of the elbow can be appreciably alleviated by the proper delivery of the javelin. What is most important is for the thrower to bring the javelin and the hand sufficiently close to the side of the face and to get the body well under the javelin by simultaneously starting with the left foot forward and to the right. The swinging of the forearm towards the right is prevented and the arm action can be performed straight ahead in the throwing direction effectively to the end. By changing the hold of the javelin from the usual forefinger hold to the middlefinger hold (in doing which the forefinger is extended underneath the javelin and the middlefinger behind the binding), the hand can be brought at the start into a position which is twisted more inwards, thereby reducing the strain on the medial collateral ligament of the elbow.

The last shove to the javelin is given by the arm action, *i. e.* the straightening of the elbow, which happens in the last phase of the delivery when the hand is above the shoulder about as at the level of the ear, at which movement it should occur as suddenly and completely as possible in order to give the javelin maximum

Fig. 1. A complete fracture of the olecranon, which has healed into a dislocated position (Case 2).



Fig. 2. Complete detachment of the triangular tip of the olecranon (Case 1).

Fig. 3. A detached clear shadow blot with bone design at the tip of the olecranon (Case 8).



Fig. 4. A calcium shadow with bone design beside the medial epicondyle (Case 9).

Fig. 5. The exchampion in the act of throwing. The picture clearly reveals the wrenching and trip-up of the elbow.

initial velocity. This sudden forcible straightening of the elbow does not stop until the tip of the olecranon strikes the olecranon fossa (a momentary hyperextension). As the distance of the throw becomes longer, the initial velocity of the javelin increases and the forcible straightening of the arm is also quicker. Hence the stroke of the tip of the olecranon in the olecranon fossa becomes all the more violent.

The numerous changes found at the tip of the olecranon are best explained by this effect of the stroke.

The force of this stroke is modified, however, by the fact that in the final phase of straightening, the arm twists forcibly inwards (pronation) in doing which the flexor muscles and the pronator muscle (m. pronator teres) act as a brake. The trip-up effect mentioned earlier and this pronation provide the best explanation of the tender callosities or calcifications near the flexor sometimes

shown in the roentgenograms. (The subsequent scars or sprains and ruptures of the ligaments.)

All the changes that I have found have been extraarticular, manifesting the after-effects of traumas, fractures and sprains. I have never observed intra-articular changes.

The fact that HEISS found from his own material intra-articular changes in fourteen cases of the fortyone he examined is perhaps due to several factors. In the first place, his 50-metre throwers, the majority of whom still undoubtedly have an insufficient throwing-technique, cannot be regarded as more than mediocre throwers, considering the present standard of results. Therefore ruptures and strains of the medial collateral ligament would occur very easily, and as a result of the latter the pressure against the trochlea humeri or its edges might become so uneven due to the wrench and trip-up action in the throw that a fragment could be broken off or a crack ensue. Even a very small crack or line of a fracture extending to the surface of the joint frequently causes local changes which are of the arthritis deformans type, but are localized and secondary by nature in the surface of the joint.

In addition, all childhood diseases and chondromatosis, osteochondropathy, osteochondritis dissecans, etc., the frequency of which may depend upon geographical, racial and other factors, should be taken into consideration. Furthermore the subjects of HEISS' mass examination certainly had not specialized exclusively in javelin-throwing, but might have injured their elbow-joints earlier while participating in other forms of athletics.

On the basis of my research, I have, however, come to the conclusion that *the roentgenologic and clinical changes of the elbow which I ascertained in champion javelin-throwers are extra-articular and the after-effects of definite traumas.* Moreover, I have never observed any changes resembling those mentioned in BAETZNER's arthritis deformans theory.

Summary.

The subjects of my study were 17 selected javelin-throwers (average record, 70.29 metres) the examination of whose elbows revealed the following:

1. During the first year of competition, the elbow of the throwing arm had in every case become so painful that the subject was compelled to give up this sport for a period varying from a few

weeks to one year. The injury recurred after two or three years. Finally, in most cases the elbow became so insensitive after repeated injuries that the subject was able to stand all the strain caused by throwing without pain.

2. The clinical changes in the elbow are very slight.

3. Fourteen out of seventeen of the subjects showed roentgenologic changes. The majority of these consists of the changes of the tip of the olecranon (11 cases). These form a series of fractures of different stages of the olecranon and ruptures of its tip:

a) a complete fracture of the olecranon, which has healed into a dislocated position.

b) the rupture of the triangular tip of the olecranon (2 cases).

c) a free calcium shadow blot at the tip of the olecranon (4 cases).

d) rough, irregular outline of the tip (5 cases).

One case showed a bone-like area of calcification beside the median condyle. Intra-articular changes were not seen in any case.

4. When the elbow is suddenly straightened during the last stage of javelin-throwing, the tip of the olecranon strikes its fossa and stops the extension movement. This violent blow is no doubt the cause of the changes in the olecranon. The calcifications near the medial epicondyle undoubtedly represent the subsequent scar formations of the ruptures of the medial collateral ligaments and capsules.

The changes found in the elbow were all extra-articular after-effects of a definite trauma, and no changes resembling those mentioned in BAETZNER's arthritis deformans theory could be found.

Zusammenfassung.

Bei der Untersuchung der Ellbogengelenke von 17 der hervorragendsten Speerwerfer Finnlands (Durchschnitt der Höchstleistung 70.29 m) habe ich folgendes feststellen können:

1. Schon im Verlauf des ersten Wettkampfjahres wurde das Ellbogengelenk des Wurfarmes aller Speerwerfer derart beschädigt, dass eine Zwangspause im Speerwerfen eingeschoben werden musste, deren Länge von einigen Wochen bis zu einem Jahr schwankte. Die Beschädigung trat nach zwei bis drei Jahren von neuem auf. Zuletzt war das Ellbogengelenk der meisten Speerwerfer nach wiederholter Beschädigung so abgestumpft und unempfindlich,

dass es alle Anstrengungen beim Werfen ohne Schmerzempfindung vertrug.

2. Die objektiv wahrzunehmenden Veränderungen bei der klinischen Untersuchung erwiesen sich als sehr gering.

3. Von 17 Untersuchten habe ich bei 14 röntgenologische Veränderungen des Gelenkes feststellen können. Zum überwiegenden Teil handelt es sich bei diesen Fällen um Veränderungen der Ellbogenspitze (11 Fälle). Diese bilden eine Reihe verschiedenartiger Ellbogenbrüche und Risse der Ellbogenspitze:

a) vollkommener Ellbogenbruch, der sich in dislozierter Stellung konsolidiert hat.

b) Abriss des Spitzendreieckes (2 Fälle).

c) getrennte Aufhellung der Spitze unter Beibehaltung der Knochenstruktur (4 Fälle).

d) unebene und zackige Zeichnung der Spitze (5 Fälle).

Hierzu kommt noch in einem Falle eine Verkalkung mit Knochenstruktur neben dem medialen Epicondylus. Intraartikuläre Veränderungen waren bei keinem Falle festzustellen.

4. Während des letzten Abschnittes des Speerwurfes bei der heftigen Ausstreckung des Armes stösst die Ellbogenspitze gegen den Boden der Fossa olecrani und stoppt die Streckbewegung. Dieser heftige Stoss dürfte die Ursache der Schädigungen der Ellbogenspitze sein. Die Verkalkungen neben dem inneren Epicondylus sind wohl als Narbenbildungen nach Kapselrissen oder Rissen der Seitenbänder aufzufassen.

5. Die beobachteten Veränderungen des Ellbogengelenkes sind in ihrer Art extra-artikuläre Folgezustände eines einmaligen Traumas. Veränderungen entsprechend der Arthritis deformans-Theorie von BAETZNER sind nicht festzustellen gewesen.

Résumé.

L'auteur a étudié 17 lanceurs de javelot (moyenne des records 70.29), et a noté ce qui suit au cours de son étude de leurs articulations du coude:

1. La première année des concours, tous les athlètes ont éprouvé des douleurs si violentes à l'articulation du coude du bras produisant l'effort, qu'ils ont été obligés d'interrompre leurs lancers durant un laps de temps allant de 2 semaines à 1 an. Les douleurs se sont renouvelées pendant 2—3 ans. Finalement, chez la plupart, les articulations du coude sont devenues si indolores que tous les

efforts nécessités par le lancer du javelot ont pu être réalisés sans douleur.

d°) Les modifications de l'articulation du coude notées durant l'observation clinique, sont insignifiantes.

3. L'examen radiologique a démontré la présence de modifications chez 14 athlètes en tout sur 17 observés. La majorité (11) de ces modifications siège à la pointe de l'olécrâne. Elles consistent en une série de ruptures de divers degrés de l'olécrâne et de fêlures de la pointe:

a) rupture complète de l'olécrâne avec fragment guéri en position de dislocation.

b) fêlure de la pointe du triangle (2 cas).

c) tache séparée de la pointe et présentant une structure osseuse (4 cas).

d) image de la pointe irrégulière et rugueuse (5 cas).

En outre, dans un cas, calcification en dehors de l'épitrochlée. On n'a noté dans aucun cas des modifications intra-articulaires.

4. Dans la dernière phase du lancer du javelot, lors de l'extension subite de l'articulation du coude, la pointe de l'olécrâne heurte le fond de la fosse olécranienne et arrête le mouvement d'extension. Ce choc violent semble être la cause des modifications pathologiques de l'olécrâne. Les calcifications observées en dehors de l'épitrochlée semblent être des produits posthumes dans des cicatrices consécutives à des ruptures des capsules articulaires et des ligaments latéraux.

5. Les modifications de l'articulation du coude observées ont toutes le caractère de séquelles extra-articulaires à un traumatisme bien défini et on n'en a noté aucune rappelant l'arthrite déformante (théorie de BAETZNER).

Bibliography.

BAETZNER, W. Sport- und Arbeitschäden. Leipzig, G. Thieme, 1936. — BAETZNER, W. Dtsch. Med. Klinik. 1928, II, p. 1905—1906. — BLENCKE, H. Zbl. Chir. 1930, 116—117. — BREITNER, B. Sportschäden und Sportverletzungen. (Neue dtsch. Chir. Bd. 58), Stuttgart, Ferd. Enke 1937. — HEISS, F. Leibesübungen, 1931. — HEISS, F. Dtsch. Z. Chir. 1934, 242, H. 5 & 6. — HIGGS, S. L. Brit. M. J. 1938, 189. — KNOLL W., u. MATHIES, TH. Arch. klin. Chir. 1931, 163. — MUSTAKALLIO, S. and LAITINEN, H. Acta radiol. 1933, 20, p. 427—437. — ROSTOCK, P. Arch. orthop. Chir. 1933, 33. — SCHMITH, O. Zbl. Chir. 1933, 19.

Books received.

J. Creyssel et P. Suire: Choc Traumatique. Étude Clinique, Physio-Pathologique et Thérapeutique. Masson & Cie, Éditeurs. 1944.

D. Petit-Dutaillis et S. de Séze: Sciatiques et Lombalgies par Hernie postérieure des Disques intervertébraux. Masson & Cie. 1945.

P. Mallet-Guy et P. Maillet: Hypoglycémies spontanées. Le Traitement Chirurgical de l'Hyperinsulinisme. Masson & Cie. 1944.

INDEX AUCTORUM.

Pag.

Fridrik Einarsson (København): On the Treatment of Dupuytren's Contracture 1

H. Frostad (Ålesund, Norway): Sacral Dermoid Cysts. Especially with a View to their Treatment 23

H. Frostad (Ålesund, Norway): Rupture in the Aponeurosis of the Shoulder Joint, Particularly Referring to its Treatment 33

K. H. Koster and Dyre Trolle (København): Investigations of Postoperative Shock: Haemoconcentration, Plasma Protein and Blood Electrolytes after Gastrectomy 51

Leif Efskind (Ullevål, Oslo): Liver Changes in Surgical Conditions . . . 81

G. af Björkesten (Helsinki): Position of Fingers and Function Deficiency in Ulnar Paralysis 99

O.-E. Cederberg (Helsinki): Beiträge zur Kenntnis über das Vorkommen von Echinokokkus-Fällen in Finnland 111

Aarre Ellonen (Helsinki): L'effet de la sympathectomie sur le fantôme douloureux d'un amputé 131

Harry Elving (Åbo): Einige Worte über die Spondylolisthesis und deren Behandlung 146

Sten Friberg and *Carl Hirsch* (Stockholm): On Late Results of Operative Treatment for Intervertebral Disc Prolapses in the Lumbar Region . 161

Lars Hagelstam (Helsinki): On the Deformities of the Spine in Multiple Neurofibromatosis (von Recklinghausen) 169

O. Hultén (Uppsala): Über Prolapsus recti bei Erwachsenen 194

Martti Hämäläinen and *Bror-Åke Söderlund* (Kuopio, Finland): On the Surgical Treatment of Scleroderma 201

K. R. Inberg (Tampere, Finland): Indefinite Pain in the Right Flank and its Origin — a New Symptom of Ileitis 213

K. E. Kallio (Helsinki): Sur les opérations plastiques du pouce 231

A. R. Klossner (Åbo): Sur l'endométriose se présentant dans l'anse sigmoïde 254

Aulis Korhonen (Helsinki): Sur les Epididymites aiguës non spécifiques . 270

A. Langenskiöld (Helsinki): Gustatory Local Hyperhidrosis Following Injuries in the Parotid Region 294

L. J. Lindström (Vasa, Finland): On Repositioned Luxation Fracture of the VI Cervical Vertebra with Transverse Paralysis of the Spinal Marrow 307

Pehr Malm (Helsinki): Über einen Fall von Paragangliom mit seltener Lokalisation 315

P. E. A. Nylander and *K. Kivikanervo* (Helsinki): On Extrapleural Pneumolysis in Pulmonary Tuberculosis 325

T. Gunnar Nyström (Kuopio, Finland): On the Treatment of Periappendicular Abscesses, Particularly with Regard to their X-Ray Therapy 344
Aarne Pelkonen (Helsinki): Über die Prostatamyome 352
Erkki Saarenmaa (Helsinki): On Clostridia Infections in War Wounds on the Carelian Isthmus 363
Torsten Sandelin (Helsinki): Processus Pyramidalis in Struma Operations . 386
Erik Severin (Stockholm): Arthrography in Sequelae to Acute Infectious Arthritis of the Hips of Young Children 389
E. Tiitinen and *K. Wahlfors* (Helsinki): Vertebra Plana Osteonecrotica (Calvé) 396
P. I. Tuovinen (Helsinki): Splanchnectomy by Megacolon Congenitum . . 404
Johannes Wahlberg (Helsinki): On the Practical Importance of the Clinical Determination of the Basal Metabolic Rate in Thyrotoxicosis 410
G. Wallgren (Helsinki): Treatment of the Congenital Flat-Foot 417
Carl Wegelius (Helsinki): Tables for Calculation of Exact Measurements of Radiographed Objects 424
Johan Holst (Oslo): Closure of the Bronchus in Pneumonectomy and Lobectomy 431
John Hellström and *Ragnar Romanus* (Stockholm): Uretero-intestinal Implantation according to Coffey 439
Ivar R. Sandberg (Stockholm): On the Treatment of Perforated Gastric and Duodenal Ulcer 467
Lorentz Nitter (Vestfold Fylkessykehus, Norway): Arthrosis in the Knee after Meniscectomy 483
Per Olof Almquist (Hudiksvall): Unilateral Double Ureter with Partly Vaginal, Partly Normal Outlet 495
Thore Olovson (Stockholm): Die Senkungsreaktion beim Hypernephrom . . 503
T. Gunnar Nyström (Kuopio, Finland): Rupture of Kidney Tumours and Hydronephroses 513
Hans Ekman (Hälsingborg): Displacement of the Kidney Consequent upon Spontaneous Perirenal Hematoma 531
Poul Lykke Gregersen (Copenhagen): Ectopic Course of the Ureter Attended with Hydronephrosis 552
Wille Waris (Helsinki): Elbow Injuries of Javelin-Throwers 563

Supplementum 105. *Paavo Castrén* (Helsinki): Über subcutane Leberrisse und das hepatorenale Syndrom.

Supplementum 106. *Erik Oskar Unonius* (Helsinki): Iodine Determinations and Diagnosis in Hyper- and Hypothyreosis.

List of Authors.

Almquist, P. O. 495

af Björkesten, G. 99

Cederberg, O.-E. 111

Efskind, L. 81
Einarsson, F. 1
Ekman, H. 531
Ellonen, A. 131
Elving, H. 146

Friberg, S. 161
Frostad, H. 23, 33

Gregersen, P. L. 552

Hagelstam, L. 169
Hellström, J. 439
Hirsch, C. 161
Holst, J. 431
Hultén, O. 194
Hämäläinen, M. 201

Inberg, K. R. 213

Kallio, K. E. 231
Kivikanervo, K. 325
Klossner. A. R. 254
Korhonen, A. 270
Køster, K. H. 51

Langenskiöld. A. 294
Lindström, L. J. 307

Malm, P. 315

Nitter, L. 483
Nylander, P. E. A. 325
Nyström, T. G. 344, 513

Olovson. Th. 503

Pelkonen, A. 352

Romanus, R. 439

Saarenmaa, E. 363
Sandberg, I. R. 467
Sandelin, T. 386
Serverin, E. 389
Söderlund. B.-Å. 201

Tiitinen, E. 396
Trolle, D. 51
Tuovinen, P. I 404

Wahlborg, J. 410
Wahlfors, K. 396
Wallgren, G. 417
Waris, W. 563
Wegelius, C. 424